

# Comparison Perioperative Factors During Minimally Invasive Pre-Psoas Lateral Interbody Fusion of the Lumbar Spine Using Either Navigation or Conventional Fluoroscopy

Yue-Hui Zhang, MD<sup>1,2</sup>, Ian White, MD<sup>3</sup>, Eric Potts, MD<sup>3</sup>,  
Jean-Pierre Mobasser, MD<sup>3</sup>, and Dean Chou, MD<sup>1</sup>

## Abstract

**Study Design:** Retrospective clinical study.

**Objectives:** The aim of this study was to compare intraoperative conditions and clinical results of patients undergoing pre-psoas oblique lateral interbody fusion (OLIF) using navigation or conventional fluoroscopy (C-ARM) techniques.

**Methods:** Forty-two patients (22 patients by navigation and 20 by fluoroscopy) underwent the OLIF procedure at 2 medical centers, and records were reviewed. Clinical data was collected and compared between the 2 groups. Patients were followed-up with a range of 6 to 24 months.

**Results:** There were no significant differences on demographic data between groups. The navigation group had zero radiation exposure (RE) to the surgeon and radiation time compared to the C-ARM group, with total RE of  $44.59 \pm 26.65$  mGy and radiation time of  $88.30 \pm 58.28$  seconds ( $P < .05$ ). The RE to the patient was significantly lower in the O-ARM group ( $9.38$  mGy) compared to the C-ARM group ( $44.59 \pm 26.65$  mGy). Operating room time was slightly longer in the navigation group ( $2.49 \pm 1.35$  hours) compared to the C-ARM group ( $2.30 \pm 1.17$  hours;  $P > .05$ ), although not statistically significant. No differences were found in estimated blood loss, length of hospitalization, surgery-related complications, and outcome scores with an average of 8-month follow-up.

**Conclusions:** Compared with C-ARM techniques, using navigation can eliminate RE to surgeon and decrease RE to the patient, and it had no significant effect on operating time, estimated blood loss, length of hospitalization, or perioperative complications in the patients with OLIF procedure. This study shows that navigation is a safe alternative to fluoroscopy during the OLIF procedure in the treatment of degenerative lumbar conditions.

## Keywords

navigation, oblique lumbar interbody fusion, fluoroscopy, radiation exposure, lumbar spine, OLIF

## Introduction

In recent years, minimally invasive surgical (MIS) approaches for spine surgery have become an alternative for many surgeons. The minimally invasive lateral transpsoas approach to the lumbar spine, also known as lateral lumbar interbody fusion (LIF), is being used increasingly as an option compared to traditional anterior or posterior procedures. The access to the lumbar spine in LIF is directly via the retroperitoneal space and psoas muscle through a direct lateral approach. The advantages of LIF compared with conventional posterior procedures include minimally invasive access to the lumbar spine, the

ability to restore disc height, significant indirect decompression of the neural foramen, and less blood loss. It also avoids disturbing dura and nerve roots, which leads to less risk of

<sup>1</sup> University of California San Francisco, CA, USA

<sup>2</sup> Xin Hua Hospital, Shanghai Jiao Tong University, Shanghai, China

<sup>3</sup> Goodman Campbell Brain and Spine, Indianapolis, IN, USA

### Corresponding Author:

Dean Chou, 505 Parnassus Ave, Box 0112, San Francisco, CA 94143, USA.  
Email: Choud@neurosurg.ucsf.edu



durotomy, scar tissue formation, and also subsidence by implementing a large anterior graft resting on the epiphyseal ring.<sup>1</sup> However, the transpsoas approach in LIF incurs the added risk of injury to the lumbar plexus and is associated with several complications including anterior thigh/groin pain, numbness, and weakness.<sup>2</sup> Therefore, real-time electromyography monitoring is frequently used during the operation to avoid the risk of lumbar plexus injury.<sup>2</sup> In addition, the approach in LIF can be difficult at L4-5 and is not currently an option for L5-S1.

The pre-psoas approach, also known as the oblique lateral interbody fusion (OLIF), was introduced to gain the access to disc using an anterior approach between the aorta and psoas instead of through the psoas itself in order to avoid injury to the lumbar plexus. Coupled with direct visualization, or “shallow docking,” where the intraabdominal structures are directly visualized during the approach, OLIF has shown several potential advantages including avoidance of the lumbar plexus, direct visualization of important structures such as sensory nerves, the ureter, great vessels, the lymphatics, and the sympathetic trunk. Because the OLIF is performed through a triangle that is devoid of a neurovascular structures, there is often a silent electrophysiologic window, and many surgeons have performed the operation without real-time electrophysiologic monitoring.<sup>3,4</sup> In addition, access to the L4-L5 level in cases involving a high-riding iliac crest is possible because of the slightly anterior approach, and it is also possible to reach L5-S1 in the lateral positions.<sup>5-7</sup>

However, the advantages of navigation compared with conventional fluoroscopy in the OLIF procedure have yet to be determined. The purpose of this study was to compare navigation and conventional fluoroscopy for oblique lumbar interbody fusion in the treatment of lumbar degenerative diseases and assess perioperative factors and complications.

## Materials and Methods

### Patients

The study protocol was approved by the University of California San Francisco Institutional Review Board and the St. Vincent Hospital in Indianapolis Institutional Review Board. From July 2011 to October 2015, we retrospectively analyzed 42 patients who underwent OLIF with or without posterior fixation. The patients were divided into 2 groups depending on whether navigation or C-ARM was used. The navigation group (22 patients) underwent the OLIF with an O-arm (Medtronic, Memphis, TN) based intraoperative computed tomography, and the navigation registration was carried out with Stealth (Medtronic, Memphis, TN). The C-ARM group (20 patients) underwent intraoperative conventional fluoroscopic guidance. Demographic information was recorded including gender, age, weight, smoking, chronic obstructive pulmonary disease, diabetes, and Parkinson's disease. The inclusion criteria in this study included all patients admitted to the 2 institutions presenting with lumbar degenerative conditions such as foraminal stenosis, spondylolisthesis, adult scoliosis, radiculopathy, and

degenerative adult spinal deformity. Patients undergoing the procedure for tumor, trauma, infection, and other indications were excluded from this study.

Operating time, estimated blood loss, length of hospitalization, surgery-related complications, total radiation exposure (RE, mGy), and total radiation time (seconds) was collected. Operative time was obtained from the anesthesia record and was defined as the time from the first incision to closure of the incision. Surgery-related complications including vascular injury, retrograde ejaculation, impotence, retroperitoneal hematoma, kidney/ureteral injury, ileus, bowel injury, hernia, deep vein thrombosis, pulmonary embolism, respiratory failure, pneumonia, endplate fracture, graft subsidence, hardware fracture/failure, cerebrospinal fluid leak, and infection were noted. Detailed neurologic assessment including new radiculopathy, groin/thigh pain, sensory distribution numbness, and the presence of any weakness was performed by the treating surgeon before the operation and then compared to postoperative findings immediately after surgery as well as at 1 month, 6 months, and 1 year. Postoperative clinical functional recovery was assessed using the Smiley-Webster scale described as excellent, good, fair, or poor.<sup>8</sup>

SPSS software version 18.0 (IBM, Armonk, NY) was used for statistical analysis. Differences in the operating time, estimated blood loss, length of hospitalization, total RE (mGy), and total radiation time (seconds) were described as mean  $\pm$  standard deviation and were compared by *t* tests. The incidence of surgery-related complications was compared using the  $\chi^2$  test. *P* values  $<.05$  were considered significant.

### Fluoroscopic Technique

The patient was put in a true lateral decubitus position and a fluoroscopy was used to identify the affected disc level. A skin incision about 5 cm anterior to the center of the affected intervertebral levels was made in the lateral abdominal region parallel to the fibers of the external oblique muscle. By the dissection of the external oblique, internal oblique, and transverse abdominal muscles along the direction of their fibers, the retroperitoneal space was exposed by blunt dissection and the peritoneal contents were mobilized anteriorly. Then, the intervertebral disc was exposed through an open corridor between the psoas muscle and aorta. A blunt probe is first inserted into the disc space under fluoroscopic guidance followed by a Kirschner wire. A window of only about 1 cm in the annulus fibrosus was acquired by sequential dilation along Kirschner wire in the disc space. Before the procedure of interbody fusion, the disc material was excised sequentially and the cartilaginous endplate were prepared in order to expose the subchondral bone. A proper-sized cage filled with autologous bone graft and synthetic bone substitute was inserted vertically into the disc spaces. In this process, the fluoroscopy was used to confirm that the disc preparation instruments and implants were in proper position. The approach is always carried out on the left side because of location of the vena cava on the right side. For avoiding cage subsidence and loss of the disc height,

supplemental posterior instrumentation was percutaneously placed in the prone position after anterior procedure.

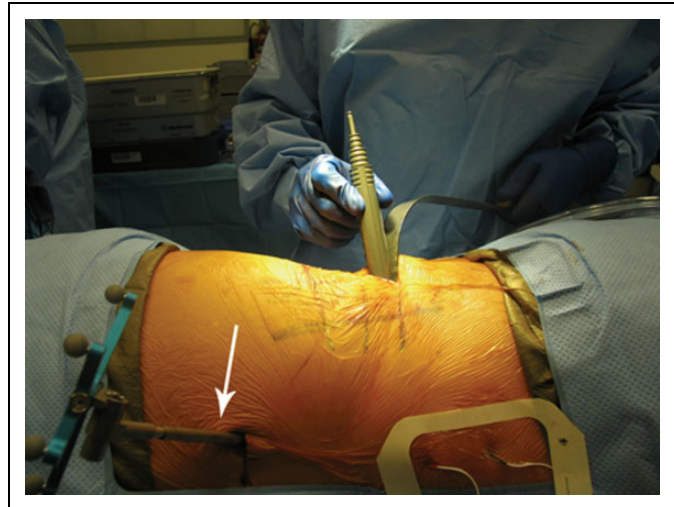### Navigation Technique

With regard to the pre-psoas procedure with navigation, the position is similar to the traditional fluoroscopy-guided procedure except that a larger area that includes the posterior iliac crest should be prepped and draped into the field. A reference arc (Figure 1) is placed into the iliac crest via a small incision. Then, a 3-dimensional intraoperative scan (O-Arm, Medtronic, Memphis, TN) is performed with navigation registration. Using navigation, an incision is planned 5 cm anterior to the midline of the spine. In order to avoid injury to the vena cava, the pre-psoas approach is always performed from a left anterior approach. Dissection is performed bluntly with direct visualization through external oblique, internal oblique, and transversus abdominus. The retroperitoneal fat is identified visually and swept ventrally with the ureter. The psoas muscle can be identified with direct observation. Then, the disc space can be cleanly exposed anterior to the psoas with a blunt dissector such as a Penfield. At this time point, navigation is used to identify the disc space and then a blunt probe is inserted into the disc space. Sequential dilation occurs over this blunt probe docked into the disc space. After sequentially dilated, the retractor and light source are placed. The disc removal is begun. One difference is that with navigation, the disc preparation instruments, the trial, and the cage itself are placed under navigation. A standard anterior-posterior and lateral radiograph is taken to confirm good position of the cage at the end of the procedure. Any bleeding is inspected and meticulous hemostasis is obtained. The retractors and the reference arc are removed, and the 2 incisions are closed in layers. Neuromonitoring is used at each step.

## Results

### Patient Characteristics

Demographic characteristics and preoperative variables of the patients are shown in Table 1. Forty-two patients (14 males, 28 females; mean age =  $66.4 \pm 7.1$  years) underwent OLIF in the treatment of degenerative diseases of the lumbar spine with or without posterior instrumentation. Navigation guidance was used in 22 patients (8 males, 14 females; mean age =  $64.4 \pm 6.8$  years; range = 58 to 82 years) and conventional fluoroscopy was used in 20 patients (6 males, 14 females; mean age =  $68.2 \pm 6.9$  years). In the navigation group, comorbidities included chronic obstructive pulmonary disease in 1 patient, diabetes mellitus in 2 patients, and smoking in 5 patients. In the navigation group, the OLIF procedure was performed from 1 to 3 levels for a total of 33 levels with posterior fixation in 19 patients and stand-alone in 3 patients. In the C-ARM group, comorbidities included Parkinson's disease in 1 patient and diabetes in 1 patient. In the fluoroscopy group, the OLIF procedure was performed from 1 to 3 levels for 31 levels



**Figure 1.** OLIF with navigation reference arc (arrow) on iliac crest.

with posterior instrumentation in 18 patients and Cage with anterior plate in 2 patients. The average weight was  $81.7 \pm 19.2$  kg (49-118 kg) in the navigation group and  $80.2 \pm 16.5$  kg (60-112 kg) in the C-ARM group ( $P > .05$ ). The diagnoses in the navigation group were the following: spondylolisthesis in 8 patients, foraminal stenosis in 6 patients, adult scoliosis in 7 patients, and flat back syndrome in 1 patient. In the fluoroscopy group, the diagnoses were the following: spondylolisthesis in 9 patients, foraminal stenosis in 6 patients, and adult scoliosis in 5 patients. There were no significant differences in age, gender, weight, operative level, and diagnosis between the 2 groups.

### Operative Factors

Comparative analysis in the operative records between navigation and fluoroscopy is summarized in Table 2. There was no significant difference in operating room time between the navigation group ( $2.49 \pm 1.35$  hours) and the fluoroscopy group ( $2.30 \pm 1.17$  hours;  $P > .05$ ). The average estimated blood loss was  $201 \pm 207.33$  mL in the navigation group and  $139.75 \pm 102.25$  mL in the fluoroscopy group ( $P > .05$ ). The length of hospitalization was  $4.55 \pm 2.93$  days in the navigation group and  $4.10 \pm 1.74$  days in the fluoroscopy group ( $P > .05$ ). The RE to the surgeon was  $44.59 \pm 26.65$  mGy, and the total radiation time was  $88.30 \pm 58.28$  seconds in the fluoroscopy group. Because the operating room staff left the room during the intraoperative O-arm spin, the navigation group showed “zero” in the total RE to the surgeon and room staff and total radiation time.<sup>9,10</sup> The RE to the patient in the C-ARM group ( $44.59 \pm 26.65$  mGy) was significantly higher compared to the navigation group in view of the average RE of a spin is about 9.38 mGy according to the procedure and instruction of O-arm ( $P < .05$ ). There were no differences in the overall incidence of surgery-related complications between the navigation group (32%) and C-ARM group (45%). Retroperitoneal hematoma was observed in 1 patient after operation in the navigation group; wound infection was observed in 1 patient in the C-

**Table 1.** Patients' Demographic Data.

	Navigation Group	C-ARM Group
Number of cases	22	20
Age, years	64.4 ± 6.8	68.2 ± 6.9
Gender (male/female)	8/14	6/14
Weight (kg)	81.7 ± 19.2	80.2 ± 16.5
Primary diagnosis, number of patients		
Spondylolisthesis	8	9
Foraminal stenosis	6	6
Adult scoliosis	7	5
Flat back syndrome	1	0
Fixation (SA or Cage + anterior plate/PSF), number of patients	3 (SA)/19	2 (Cage + anterior plate)/18
Fused segments, number of patients		
1 level	14	14
2 level	5	1
3 level	3	5
Fused disc level, number of patients		
L1/L2	1	0
L2/L3	5	6
L3/L4	13	12
L4/L5	13	12
L5/S1	1	1

Abbreviations: SA, stand-alone; PSF, posterior spinal fusion.

**Table 2.** Comparison of Surgery-Related Records Between the Navigation Group and the C-ARM Group for OLIF.

	Navigation Group	C-ARM Group
Operating time (hours)	2.49 ± 1.35	2.30 ± 1.17
Estimated blood loss (mL)	129 ± 117.35	139.75 ± 102.25
Length of hospitalization (days)	4.55 ± 2.93	4.10 ± 1.74
Total radiation exposure (mGy) <sup>a</sup>	0	44.59 ± 26.65
Total radiation time (seconds) <sup>a</sup>	0	88.30 ± 58.28
Surgery-related complications	36% (n = 8; 1 retroperitoneal hematoma; 7 hip/thigh pain)	45% (n = 9; 1 wound infection; 8 hip/thigh pain)

Abbreviation: OLIF, oblique lateral interbody fusion.

<sup>a</sup>T test used to determine significance ( $P < .05$ ).

ARM group. Transient hip/thigh pain occurred almost equally in 2 groups (32% [7/22] navigation group and 40% [8/20] C-ARM group) at 1-month follow-up and those neurological symptoms resolved at last follow-up in 100% of patients in both groups.

### Clinical Outcome

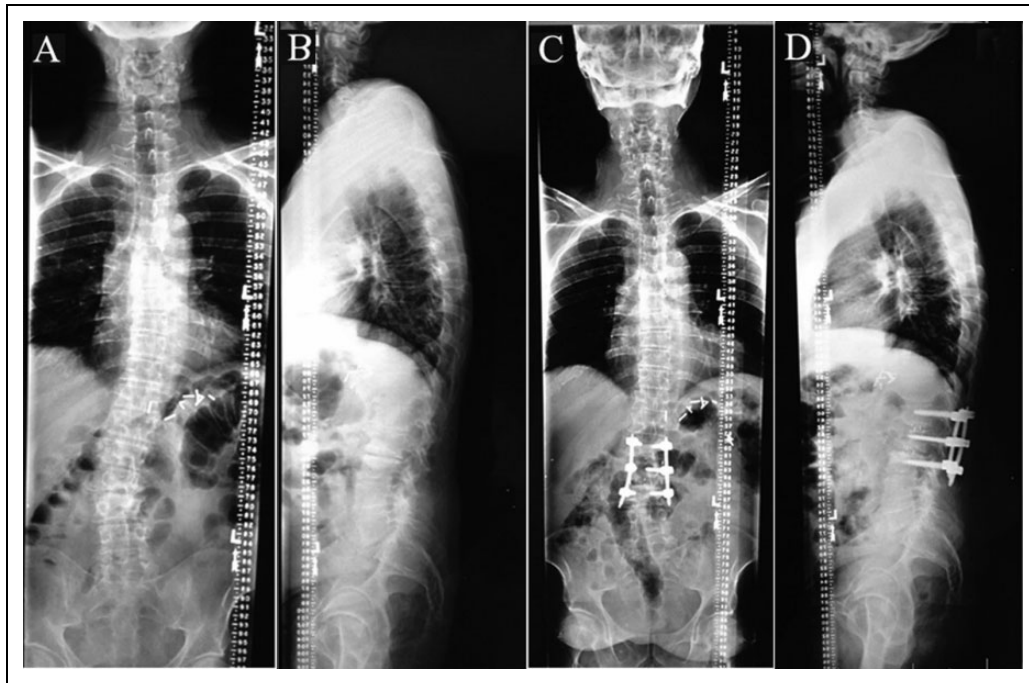
All the 42 patients were followed-up at 1 and 6 months after the operation and then every 6 months (average 8 months; 6-24 months). Functional recovery was assessed at postoperative 6 months according to the Smiley-Webster Scale; there were 15 "excellent" patients and 7 "good" patients in the navigation group compared with 14 "excellent" patients and 6 "good" patients in the C-ARM group ( $P > .05$ ; see Figure 2 and Table 3).

### Discussion

As an attempt to decrease neurologic complications with a transpsoas lateral approach, the OLIF was created via docking

anterior to the psoas instead of through the psoas. However, the complications cannot be completely eliminated. Silvestre et al<sup>11</sup> reported that the most common complications were incisional pain, lower extremity symptoms, and vascular injury (11% in 179 patients) in the OLIF procedure. In 2 recent studies, Ohtori et al<sup>3,4</sup> reported that the rate of thigh pain/numbness ranged from 11% to 25% and 75% of donor site pain was noted (8/12 patients) in the OLIF procedure. In our study, postoperative hip and thigh symptoms immediately after surgery were comparable between navigation (32%; 7/22) and fluoroscopy (40%; 8/20) with no significant difference. At last follow-up, the hip and thigh pain diminished in all the patients, comparable to previous studies.<sup>3,4,11</sup> Moreover, both groups had similar scores on the Smiley-Webster scale, indicating that either method appears to be equally effective in terms of clinical outcomes.

Although navigated cases were slightly longer than fluoroscopy cases (not statistically different), there is evidence showing the benefits of navigation. Studies have shown improved accuracy for pedicle screw placement in spine surgery when



**Figure 2.** A 60-year-old man with scoliosis and radiculopathy underwent OLIF and posterior MIS using navigation. Radicular pain completely gone and no laminectomy/foraminotomy. (A and B) Preoperative radiographs showing scoliosis and severe lumbar degenerative conditions. (C and D) Minimal effect in coronal and sagittal planes.

**Table 3.** Clinical Results Based on Smiley-Webster Scale in the 2 Groups.

Grades	Description	Navigation Group (n = 22), n (%)	C-ARM Group (n = 20), n (%)
I. Excellent	Patient returned to full-time work and/or activity as before onset of symptoms; no pain medication required	15 (68)	14 (70)
II. Good	Patient returned to full-time work and/or activity; occasional consumption of pain medication	7 (32)	6 (30)
III. Fair	Patient not able to return to former level of work and/or activity; occasional pain medication; improved over preoperative status	0 (0)	0 (0)
IV. Poor	Patient not able to return to work and/or former activity level; regular consumption of pain medication	0 (0)	0 (0)

using navigation.<sup>12-14</sup> In addition, it avoids RE to the surgeon.<sup>9,10,14,15</sup> Surgeons have voiced concerns about the radiation dose they receive over a career of spine surgery. The cumulative RE places the surgeon at risk for the development of malignancy. The incidence of thyroid cancer in spine surgeons was almost 40 times greater than the general population according to the Scoliosis Research Society Morbidity and Mortality Committee.<sup>16</sup> Navigation is one tool that may decrease this risk, with prior studies reporting navigation generating “0” or undetectable RE to surgeon and OR staff.<sup>9,17,18</sup>

Despite the use of navigation greatly improving the accuracy in screw placement in spine surgery, there is still debate regarding the RE to patients by O-arm.<sup>18,19</sup> The O-arm delivers a different dose of radiation, which ranged from 6 mGy to 66 mGy depending on the settings of the machine. When compared to C-arm, the difference of dose of radiation would be based on how long the C-arm was used during the surgery. In this study, the patient in navigation group received the average

dose of radiation is 9.38 mGy by one time spin of O-arm, based on the information obtained through our local radiation technologists. Compared to the C-ARM group, the RE to patients was significantly lower in O-arm group. Our results are coincidental to the previous report that RE to patients in whom the O-arm was used was less than a half that of C-arm in MIS lumbar fusion surgery<sup>18</sup>; however, they are in contrast to the recent report by Costa et al<sup>19</sup> that the O-arm exposed patients to a higher radiation dose than fluoroscopy in spine surgery. The possible reasons were as follows: as the teaching hospital, more C-arm shots were taken as part of teaching for residents and fellows; the other one was that since the trajectory was not direct as in a transpoas approach, there were times in which extra C-arm shots must be taken to assess the position of the instruments so as to avoid injury to the contralateral nerve root secondary to the oblique approach. In addition, there were cases included in this series that were early on, and thus, more radiation was used during the learning curve of this operation.

In our study, the average total operative time was statistically the same for the C-arm and navigation, similar to results reported by other studies in the spinal surgery.<sup>14,20</sup> Moreover, cadaveric studies have shown that the use of navigation did not cause an increase in operative time.<sup>10</sup> However, earlier studies have reported that the use of intraoperative 3D fluoroscopy increased the total operative time for the fixation of slipped capital femoral epiphysis<sup>21</sup> and artificial osteochondral talar lesions.<sup>22</sup> In these studies, in order to obtain detailed multiplanar images, the navigation system including the setup the software, the registered probe, and the reconstruction of 3D images all needed to occur in the operating room. Therefore, the mean preparation time tended to be longer when prior generations of navigation were used. However, with new generations of navigation systems and the institutional familiarity with the equipment, the shorter setup time of navigation has decreased the total operative time nearly to that of C-arm based surgeries.

There are several additional limitations in this study. The sample size was not large and potentially underpowered; the true differences of using navigation versus fluoroscopy may not have been detected. Another limitation is that heterogeneity existed between the both groups: the patients in the navigation group were selected from one medical center, and the patients in the C-arm group were selected from another. Moreover, this is a retrospective, nonrandomized study. Another factor is that because OLIF is a relatively new technique, the learning curve played a role in the operative times. Thus, the true operative time may be different after the learning curve has been passed. The duration of follow-up was also short and the average follow-up is only 8 months. However, this article was not meant to be a long-term outcomes study; rather, it was meant to focus mainly on the perioperative period after navigated or fluoroscopy based surgery.

## Conclusion

Performing the OLIF with either navigation or fluoroscopy did not appear to affect operative time, estimated blood loss, length of hospitalization, or other surgery-related complications, and there was no RE to the surgeon and low RE to the patient with navigated cases. Patient outcomes were not different regardless of which imaging modality was used.

## Declaration of Conflicting Interests

The author(s) declared no potential conflicts of interest with respect to the research, authorship, and/or publication of this article.

## Funding

The author(s) received no financial support for the research, authorship, and/or publication of this article.

## References

- Ozgur BM, Aryan HE, Pimenta L, Taylor WR. Extreme Lateral Interbody Fusion (XLIF): a novel surgical technique for anterior lumbar interbody fusion. *Spine J*. 2006;6:435-443.
- Lykissas MG, Aichmair A, Hughes AP, et al. Nerve injury after lateral lumbar interbody fusion: a review of 919 treated levels with identification of risk factors. *Spine J*. 2014;14:749-758.
- Ohtori S, Mannoji C, Orita S, et al. Mini-open anterior retroperitoneal lumbar interbody fusion: oblique lateral interbody fusion for degenerated lumbar spinal kyphoscoliosis. *Asian Spine J*. 2015;9:565-572.
- Ohtori S, Orita S, Yamauchi K, et al. Mini-open anterior retroperitoneal lumbar interbody fusion: oblique lateral interbody fusion for lumbar spinal degeneration disease. *Yonsei Med J*. 2015;56:1051-1059.
- Davis TT, Hynes RA, Fung DA, et al. Retroperitoneal oblique corridor to the L2-S1 intervertebral discs in the lateral position: an anatomic study. *J Neurosurg Spine*. 2014;21:785-793.
- Kanno K, Ohtori S, Orita S, et al. Miniopen oblique lateral L5-s1 interbody fusion: a report of 2 cases. *Case Rep Orthop*. 2014;2014:603531.
- Molinales DM, Davis TT, Fung DA. Retroperitoneal oblique corridor to the L2-S1 intervertebral discs: an MRI study [published online October 9, 2015]. *J Neurosurg Spine*. doi:10.3171/2015.3.SPINE13976.
- Webster FS, Smiley DP. End result study of a series of operations for herniated intervertebral lumbar discs. *Am J Surg*. 1960;99:27-32.
- Nottmeier EW, Pirris SM, Edwards S, Kimes S, Bowman C, Nelson KL. Operating room radiation exposure in cone beam computed tomography-based, image-guided spinal surgery: clinical article. *J Neurosurg Spine*. 2013;19:226-231.
- Tabaraee E, Gibson AG, Karahalios DG, Potts EA, Mobasser JP, Burch S. Intraoperative cone beam-computed tomography with navigation (O-ARM) versus conventional fluoroscopy (C-ARM): a cadaveric study comparing accuracy, efficiency, and safety for spinal instrumentation. *Spine (Phila Pa 1976)*. 2013;38:1953-1958.
- Silvestre C, Mac-Thiong JM, Hilmi R, Roussouly P. Complications and morbidities of mini-open anterior retroperitoneal lumbar interbody fusion: oblique lumbar interbody fusion in 179 patients. *Asian Spine J*. 2012;6:89-97.
- Aoude AA, Fortin M, Figueiredo R, Jarzem P, Ouellet J, Weber MH. Methods to determine pedicle screw placement accuracy in spine surgery: a systematic review. *Eur Spine J*. 2015;24:990-1004.
- Patton AG, Morris RP, Kuo YF, Lindsey RW. Accuracy of fluoroscopy versus computer-assisted navigation for the placement of anterior cervical pedicle screws. *Spine (Phila Pa 1976)*. 2015;40: E404-E410.
- Yang YL, Zhou DS, He JL. Comparison of isocentric C-arm 3-dimensional navigation and conventional fluoroscopy for C1 lateral mass and C2 pedicle screw placement for atlantoaxial instability. *J Spinal Disord Tech*. 2013;26:127-134.
- van Walsum T, van de Kraats EB, Voormolen MH, Verlaan JJ, Mali WP, Niessen WJ. Navigation with three-dimensional rotational radiographic data for transpedicular percutaneous needle introduction: feasibility and comparison with fluoroscopic guidance. *J Vasc Interv Radiol*. 2006;17:1511-1518.
- Wagner TA, Lai SM, Asher MA, et al. SRS surgeon members' risk for thyroid cancer: is it increased? Hibbs Award Nominee for

- Best Clinical Paper. Paper presented at: 41st Annual Meeting of the Sclerosis Research Society; 2006; Monterey, CA.
17. O'Donnell C, Maertens A, Bompadre V, Wagner TA, Krengel W 3rd. Comparative radiation exposure using standard fluoroscopy versus cone-beam computed tomography for posterior instrumented fusion in adolescent idiopathic scoliosis. *Spine (Phila Pa 1976)*. 2014;39: E850-E855.
  18. Kotani Y, Gonchar I, Matsumoto Y. Comparison of intraoperative radiation exposure for O-arm intraoperative CT vs C-Arm image intensifier in MIS lumbar fusion. Paper presented at: Minimally Invasive Surgery Symposium (MISS) Annual Meeting; Las Vegas, NV; 2014.
  19. Costa F, Tosi G, Attuati L, et al. Radiation exposure in spine surgery using an image-guided system based on intraoperative cone-beam computed tomography. *J Neurosurg Spine*. 2016;25: 654-659.
  20. Sasso RC, Garrido BJ. Computer-assisted spinal navigation versus serial radiography and operative time for posterior spinal fusion at L5-S1. *J Spinal Disord Tech*. 2007;20: 118-122.
  21. Bono KT, Rubin MD, Jones KC, et al. A prospective comparison of computer-navigated and fluoroscopic-guided in situ fixation of slipped capital femoral epiphysis. *J Pediatr Orthop*. 2013;33: 128-134.
  22. Citak M, Kendoff D, Kfuri M Jr, Pearle A, Krettek C, Hüfner T. Accuracy analysis of Iso-C3D versus fluoroscopy-based navigated retrograde drilling of osteochondral lesions: a pilot study. *J Bone Joint Surg Br*. 2007;89:323-326.