

# Late presentation of myocardial infarction (MI) during the COVID-19 pandemic

Chidambaram Chinniah,<sup>1</sup> Brian Conway,<sup>2</sup> Neil Yager<sup>2</sup>

<sup>1</sup>Albany Medical College, Albany, New York, USA  
<sup>2</sup>Cardiology, Albany Medical Center Hospital, Albany, New York, USA

**Correspondence to**  
Chidambaram Chinniah;  
chinnic@amc.edu

Accepted 16 March 2021

## SUMMARY

A 65-year-old man presented to emergency department with progressive worsening dyspnoea, which was preceded by crushing, substernal chest pain 3 weeks prior that lasted for over 2 days. At the time the patient thought that this was a symptom of COVID-19 so he stayed at home and self-quarantined, until his symptoms worsened to the point of needing hospitalisation. The patient was found to have had myocardial infarction, with coronary angiography showing 100% occlusion of the Left Anterior Descending artery (LAD). Medical management was recommended given late presentation and risk of reperfusion injury.

## BACKGROUND

Non-ST segment elevation myocardial infarction (NSTEMI) is the most common subgroup of acute coronary syndrome (ACS). The incidence of ACS in the USA is over 780 000, with approximately 70% of those having NSTEMI.<sup>1</sup> Recent retrospective studies found that 12% of patients with STEMI presented very late ( $\leq 12$  hours) after symptom onset. Oftentimes, these patients who presented very late were less likely to call 911 and be transported by ambulance, suggesting they did not perceive their symptoms to be an emergency. Clinically, these late presenters were found to have higher rates of heart failure and a significantly lower long-term survival. Furthermore these late presenting patients had longer hospitalisations and were less likely to be discharged home, and more likely to be discharged to rehab.<sup>2</sup> During this COVID-19 pandemic, an increasing number of patients have been deferring hospital visits for fear of contracting COVID-19 at the hospital further exacerbating outcomes of late presentations. Multiple studies worldwide have found that the incidence of hospitalisation for acute MI and admissions for most diagnoses have decreased by as much as 40%–50% during the pandemic,<sup>3,4</sup> and was especially pronounced in patients with NSTEMI.<sup>5</sup>

## CASE PRESENTATION

A 65-year-old man with a prior pulmonary embolism (PE) 10 years ago presented to the emergency department with progressively worsening dyspnoea, orthopnoea and leg oedema. Approximately 3 weeks prior to this presentation, he described an episode of crushing, substernal, 10/10 pain radiating to his left flank accompanied by diaphoresis that lasted over 2 days. He thought this presentation was a symptom of COVID-19, so he self-quarantined and suffered through the pain. Given his history of PE,

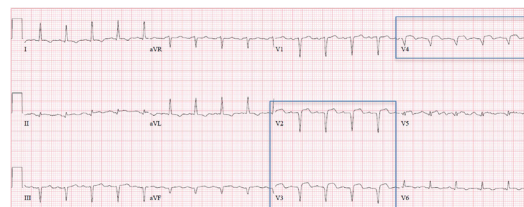
he tried breathing exercises to try to alleviate the pain; however, his breathing continued to worsen to the point of requiring emergency care.

## INVESTIGATIONS

Initial workup was significant for sinus tachycardia on electrocardiogram with evidence of an inferior MI, Q waves and ST-elevations in V2–V4, and T-wave abnormalities (figure 1). Troponin I peaked at 2.5. CT angiography of the chest (figure 2) showed a moderate-to-large pericardial effusion measuring 2.4 cm thickness, a small focal outpouching involving the left ventricular (LV) apex suggesting infarcted tissue with possible small aneurysm formation and a small left-sided pleural effusion with atelectasis. Pericardiocentesis was urgently performed given the patients ongoing chest discomfort resulting in significant relief. Follow-up echocardiography (figure 3) showed a reduced LV ejection fraction of 35%–39% with depressed systolic function, segmental wall motion abnormalities, and an apical aneurysm with layered LV thrombus. The patient was then taken for coronary angiography and was found to have 100% occlusion of the Left Anterior Descending artery (LAD) (figure 4).

## OUTCOME AND FOLLOW-UP

With this patient's late presentation, a treatment plan focusing on medical management was recommended. He was started on spironolactone, enalapril, furosemide, atorvastatin, aspirin and bridged from heparin to warfarin for his apical thrombus and discharged a few days later from the coronary care unit (CCU) to discuss viability testing as an outpatient. The patient was also started on a low-sodium and low-fat diet. The patient was seen outpatient for follow-up and was agreeable to enrolling in cardiac rehab at an external facility at that time.

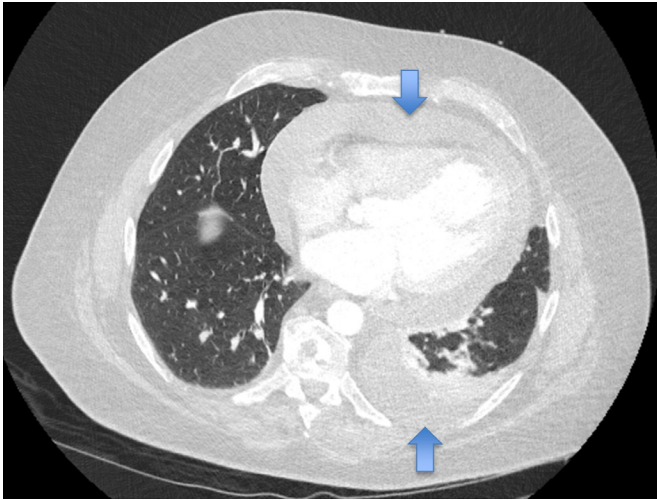


**Figure 1** ECG with evidence of an inferior myocardial infarction Q waves and ST-elevations in V2–V4 and T-wave abnormalities.



© BMJ Publishing Group Limited 2021. No commercial re-use. See rights and permissions. Published by BMJ.

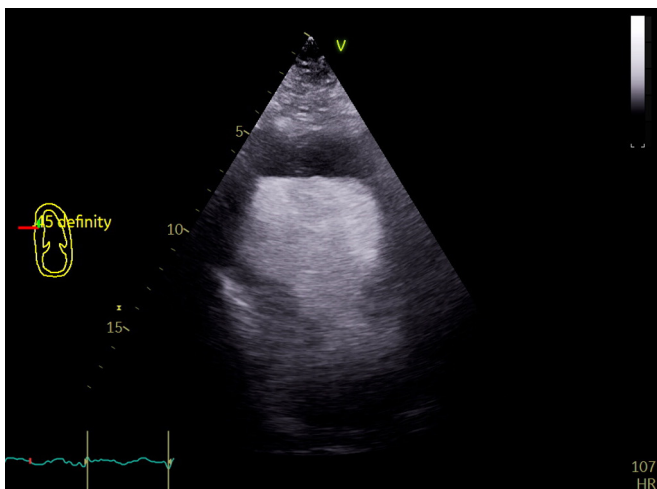
**To cite:** Chinniah C, Conway B, Yager N. *BMJ Case Rep* 2021;**14**:e240457. doi:10.1136/bcr-2020-240457



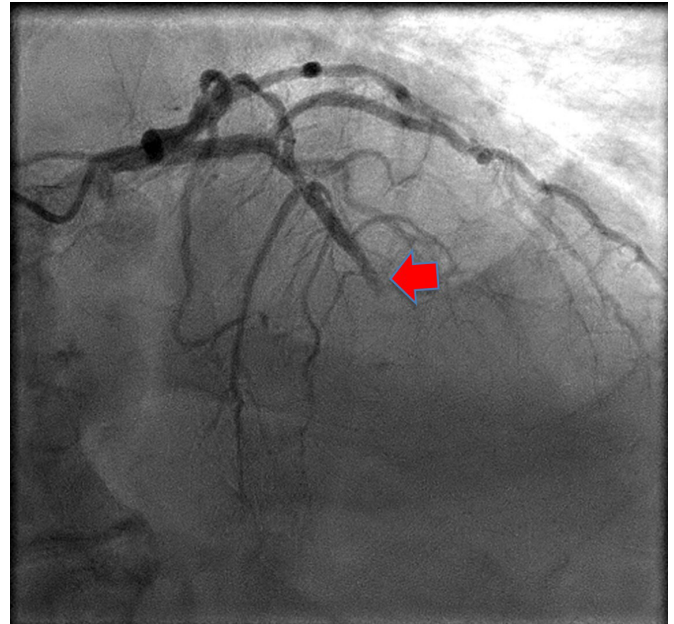
**Figure 2** Top and bottom arrows: pericardial and pleural effusion, respectively.

### DISCUSSION

Hospital admissions for other medical emergencies within cardiology, gastroenterology, neurology and urology have decreased since the start of COVID-19 protocols, with a combined 33.7% decrease in admissions from prepandemic rates.<sup>6</sup> Many patients have become reluctant to present to their local emergency room from fear of contracting other illness. This has led to an increasingly high rate of late presentation events, where intervention ceases to be effective. On investigating whether any social or geographical factors were at play, his biggest impact was likely that he is a retired male who lives alone in the suburbs of Albany, who relies on his friend for transportation. Otherwise, prior to hospitalisation the patient did not take any medications and he is a never smoker or drinker. The patient we present likely sustained an MI at the time of symptom onset, 3 weeks prior to presentation, which is suggestive of Dressler's syndrome. Dressler's syndrome, also known as postmyocardial infarction syndrome, is a form of secondary pericarditis with or without a pericardial effusion that occurs as a result of injury to the heart or pericardium. It can be seen in patients presenting with persistent malaise or fatigue, following MI or cardiac surgery, especially if symptoms present greater than



**Figure 3** Echocardiography.



**Figure 4** Complete LAD occlusion and multivessel disease. Red arrow=LAD occlusion. LAD, Left Anterior Descending artery.

2 weeks following the event.<sup>7</sup> Our patient fits all of these characteristics. Unfortunately for this patient, his delay in seeking medical care likely resulted in a significant portion of ischaemic myocardium that could have been recovered being left unrevascularised. The risk of reperfusion injury outweighed any benefit there may have been from further intervention and thus, medical management was recommended. Outpatient myocardial viability testing may be used to assess whether there may be any benefit of future revascularisation, which may provide improvement in LV systolic function, but such improvement has not been found to effect long-term survival.<sup>8</sup> This unfortunate case of acute coronary

### Patient's perspective

I thought the chest pain was related to COVID-19 and given my history of pulmonary embolisms I just did the breathing exercises I was taught and tried to walk around and deal with the pain until it subsided. The pain went away after 52 hours but my shortness of breath got worse and I had to come into the hospital.

### Learning points

- ▶ Reinforce that medical care should not be delayed, especially during a pandemic, and that all symptoms potentially concerning for acute coronary syndromes should be fully assessed, regardless of the situation.
- ▶ Continue to raise public awareness of COVID-19-related symptoms.
- ▶ Reassure patients that it is safe to come into hospitals for treatment.
- ▶ Dressler's syndrome is rare, affecting patients who have recently had a myocardial infarction and presents with similar symptoms.

syndrome during the COVID-19 pandemic fits the global picture of delayed presentations for emergent conditions. It remains imperative that hospitals and clinics strive for safety in this COVID-19 pandemic and to foster an environment that leaves no patient feeling unsafe visiting a hospital.

**Contributors** CC—original manuscript writer, created all figures, acquired patients consent. BC—helped review and revise the manuscript. NY—helped review and revise the manuscript, conceptualised the idea for the case report.

**Funding** The authors have not declared a specific grant for this research from any funding agency in the public, commercial or not-for-profit sectors.

**Competing interests** None declared.

**Patient consent for publication** Obtained.

**Provenance and peer review** Not commissioned; externally peer reviewed.

This article is made freely available for use in accordance with BMJ's website terms and conditions for the duration of the covid-19 pandemic or until otherwise determined by BMJ. You may use, download and print the article for any lawful,

non-commercial purpose (including text and data mining) provided that all copyright notices and trade marks are retained.

## REFERENCES

- 1 Damhoff TC, Huecker MR. Non ST segment elevation (NSTEMI) myocardial infarction, 2019. Available: <https://www.ncbi.nlm.nih.gov/books/NBK513228/>
- 2 McNair PW, Bilchick KC, Keeley EC. Very late presentation in ST elevation myocardial infarction: predictors and long-term mortality. *Int J Cardiol Heart Vasc* 2019;22:156–9.
- 3 Solomon MD, McNulty EJ, Rana JS, *et al*. The Covid-19 pandemic and the incidence of acute myocardial infarction. *N Engl J Med Overseas Ed* 2020;383:691–3.
- 4 De Rosa S, Spaccarotella C, Basso C, *et al*. Reduction of hospitalizations for myocardial infarction in Italy in the COVID-19 era. *Eur Heart J* 2020;41:2083–2088.
- 5 Maffham MM, Spata E, Goldacre R, *et al*. COVID-19 pandemic and admission rates for and management of acute coronary syndromes in England. *Lancet* 2020;396:381–9.
- 6 et al Oseran AS, Nash D, Kim C. Changes in hospital admissions for urgent conditions during COVID-19 pandemic, 2020. Available: <https://www.ajmc.com/view/changes-in-hospital-admissions-for-urgent-conditions-during-covid19-pandemic>
- 7 Leib AD, Foris LA, Nguyen T. *Dressler syndrome*. Treasure Island (FL): StatPearls Publishing, 2020.
- 8 Panza JA, Ellis AM, Al-Khalidi HR, *et al*. Myocardial viability and long-term outcomes in ischemic cardiomyopathy. *N Engl J Med Overseas Ed* 2019;381:739–48.

Copyright 2021 BMJ Publishing Group. All rights reserved. For permission to reuse any of this content visit <https://www.bmj.com/company/products-services/rights-and-licensing/permissions/> BMJ Case Report Fellows may re-use this article for personal use and teaching without any further permission.

Become a Fellow of BMJ Case Reports today and you can:

- ▶ Submit as many cases as you like
- ▶ Enjoy fast sympathetic peer review and rapid publication of accepted articles
- ▶ Access all the published articles
- ▶ Re-use any of the published material for personal use and teaching without further permission

### Customer Service

If you have any further queries about your subscription, please contact our customer services team on +44 (0) 207111 1105 or via email at [support@bmj.com](mailto:support@bmj.com).

Visit [casereports.bmj.com](http://casereports.bmj.com) for more articles like this and to become a Fellow