

Suprapatellar nailing of tibial fractures: surgical hints

Ole Brink, MD, PhD, MPA

Department of Orthopedic Surgery, Trauma Research Unit, Aarhus University Hospital, Aarhus, Denmark

ABSTRACT

Intramedullary nailing of the tibia with suprapatellar entry and semi-extended positioning makes it technically easier to nail the proximal and distal fractures. The purpose of this article was to describe a simple method for suprapatellar nailing (SPN). A step-by-step run through of the surgical technique is described, including positioning of the patient. There are as yet only a few clinical studies that illustrate the complications with this method, and there has been no increased frequency of intraarticular damage. Within the body of the manuscript, information is included about intraarticular damage and comments with references about anterior knee pain.

Key Words

tibia fracture, suprapatellar nail, surgical technique

INTRODUCTION

Today, intramedullary nailing seems to be the gold standard for the treatment of diaphyseal tibial fractures. Nailing ensures good fracture stability, safeguards against malalignments, and allows quick mobilization. An infrapatellar and patellar tendon splitting entry to the tibia with the knee joint flexed 90 degrees seems to be the preferred entry for tibial nailing. If the indications for nailing of proximal and distal tibial fractures are extended, this is a challenge for surgical techniques. With proximal fractures, there is a tendency for anterior malalignment of the proximal fragment from pull of the patellar tendon, and this pull is increased further when the knee is flexed during nailing.¹ With nailing in a conventional manner, there is a risk of poor repositioning, suboptimal reaming, and a poor placement of the nail. Tornetta and Collins¹ (1996) reported 25 patients in whom a partial medial parapatellar arthrotomy was performed with the knee in a semi-extended

position (15-degree bend of the knee joint), with two-thirds of the the retinaculum split. When the patella was subluxed laterally, the trochlear groove was used as a bed for the instruments and nail. The argument for this entry was that when the knee joint is maximally bent to 15 degrees, the pull of the patellar tendon on the proximal fragment is eliminated, and thus the fracture can be easily repositioned and fixed.

Morandi *et al.*² described a percutaneous lateral suprapatellar approach through a 1.5-cm transverse skin incision at the superolateral corner of the patella. Jakma *et al.*³ used a 1-2 cm incision just above the patella and in line with the tibial shaft. They used unreamed nails, and arthroscopy before and after the nailing revealed damage to the patellofemoral cartilage. A cadaver study has shown injuries to medial meniscus and intermeniscal ligament with a suprapatellar entry.⁴

Despite the challenges with different accesses and the risk of intraarticular damage, tibial nailing with the knee semi-extended through a suprapatellar entry appears to have become more widespread, and new instruments developed by different manufacturers have made the technique simpler and more secure. At our institution, we have used the technique for 4 yr with different systems. In the beginning, we used it for selected proximal fractures and later for distal tibial fractures and now also shaft fractures. The technique also has been found to be useful in patients with multiple fractures, such as ipsilateral femoral fracture and tibial-femoral fracture on the opposite leg, because all fractures can be operated without the need for manual traction or rearrangement. Although the suprapatellar entry has become more widespread during the past years, and the manufacturers have refined the equipment, many orthopaedists do not have personal experience with this approach.

The purpose of this article is to present a simple technique for suprapatellar nailing (SPN) of tibial fractures providing step-by-step instruction supplemented with relevant illustrations.

Financial Disclosures: The author reports no disclosures and no conflicts of interest.

Correspondence to Ole Brink, MD, PhD, MPA, Associate Professor, Consultant Surgeon, Department of Orthopaedic Surgery, Trauma Research Unit, Aarhus University Hospital, Aarhus, Denmark
Tel: +45 7846 4540; fax: +45 7846 4549;
e-mail: o.brink@dadlnet.dk.

1940-7041 Copyright © 2015 Wolters Kluwer Health, Inc. All rights reserved. This is an open-access article distributed under the terms of the Creative Commons Attribution-Non Commercial-No Derivatives License 4.0 (CCBY-NC-ND), where it is permissible to download and share the work provided it is properly cited. The work cannot be changed in any way or used commercially.

SURGICAL TECHNIQUE

Before the operation, it is recommended to examine patellar laxity on the injured leg, or as an alternative the healthy leg. If the mobility of the patella is sparse, it may complicate the instrumentation with the suprapatellar entry, and traditional infrapatellar entry should be considered. The alternative is to extend the suprapatellar dissection by slitting the retinaculum.

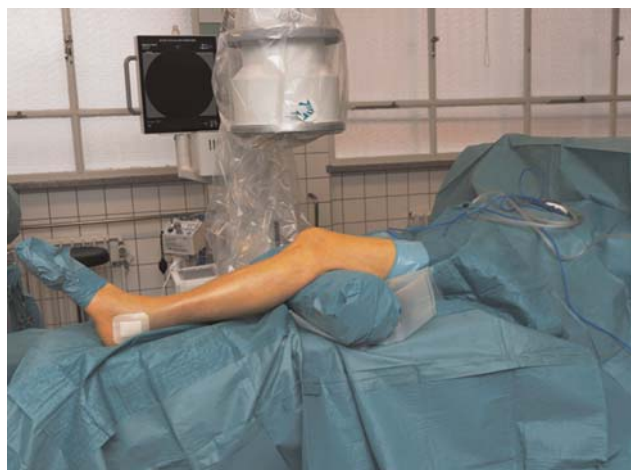

FIGURE 1. Patient is positioned supine with a roll under the knee joint, which is bent 20-30 degrees. If the healthy leg is lowered from the horizontal position, the C-arm can be brought easily into position for a lateral view without moving the damaged leg.

The patient is positioned supine on a radiolucent table (Figure 1), and the injured leg is positioned with a roll under the knee joint so that it is flexed 20-30 degrees. The C-arm is placed on the opposite side, and if the table allows split leg, the healthy leg is lowered 20-30 degrees from the horizontal position; the C-arm ensures optimal imaging in both anteroposterior and lateral views with no further movement of the injured leg.

The height of the sterile barrier close to the anesthesiologist is minimized so that it allows maneuvering of the long guide wire and reamers without making them nonsterile. A tightly stretched elastic bandage over the fracture can be a simple and quick method for gross manipulation of this.

As the leg is often malrotated because of the fracture, it is beneficial to outline the patella, joint lines, and tibial tubercle on the skin to assist with placement of the guide wire at the correct entry point (Figure 2). A 1.5-cm to 2-cm longitudinal skin incision is made 1 cm above the base of the patella. The quadriceps tendon is exposed by blunt dissection (Figure 3), and a longitudinal midline split is performed in the tendon. For optimal entry, it should be possible to run a finger easily under the patella and into the knee joint (Figure 4). If this is not possible, depending on the amount of patellar laxity, a second deep incision may be made through the superior two-thirds of the medial or lateral retinaculum. This allows for subluxation of the patella to one side, and the patella can be elevated enough for instrumentation.

Depending on the type of nail and manufacturer, the protecting entry tube may be inserted now, but it is much easier to start with the guide wire and place it "free-hand" on top of tibia (Figure 5).

The ideal entry point seen on anteroposterior view is located 9 mm in the lateral direction from the center of the tibial plateau and slightly lateral to the tibial tubercle (Figures 6 and 7).⁵ On the lateral view, the entry point is anterior to the anterior articular margin. In the tibial medullary canal, the guide wire must be directed towards the central position in both planes.

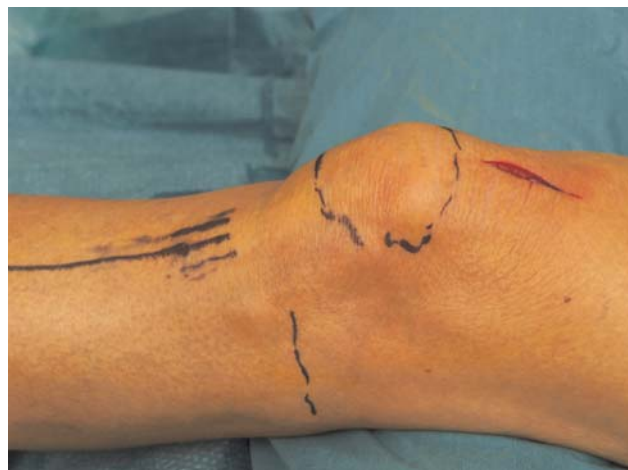

FIGURE 2. Drawing of the midline of the patella and tibia simplifies the subsequent insertion of the guide pin in the top of the tibia. A 1.5-2 cm long skin incision is made 1 cm above the patella.

When the correct position of the guide wire is verified by radiographic imaging in both anteroposterior and lateral views, the protection sleeve is inserted (Figure 8). With a blunt trocar, the sleeve can be carefully rolled over the guide wire and in under the patella to the top of the tibia. It is important to ensure under fluoroscopy that the sleeve "sits" on top of the tibia to prevent iatrogenic damage to the knee joint. In some systems it is possible to fix the sleeve with additional Kirschner wires to the tibia plateau (Figure 9), which is an advantage because without fixation the sleeve can be easily pulled upwards during reaming. If the sleeve is not fixed, it is important that its location is regularly checked during the reaming process. Through the sleeve over the guide wire, the medullary canal is now opened to a depth of 4-6 cm in the proximal tibia with a short reamer. If the guide wire is not centered in the canal or the reaming is too far down, there is a risk of penetrating the posterior cortex. Next the ball-tip guide can be inserted into the medullary canal and advanced past the fracture level and down to the distal tibia. Verify by radiographic imaging in both planes that the

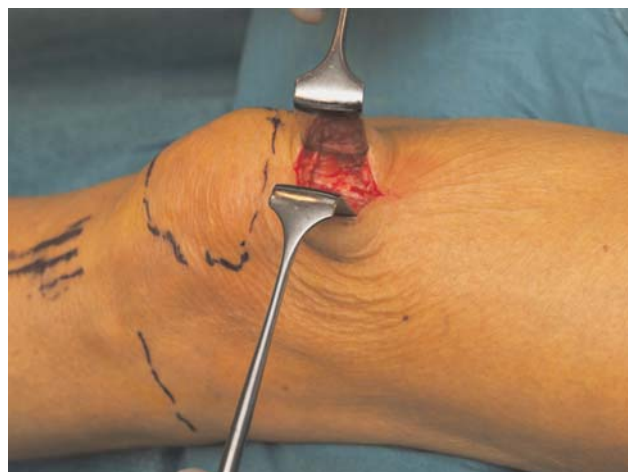


FIGURE 3. The quadriceps tendon is exposed, and a longitudinal incision is made.

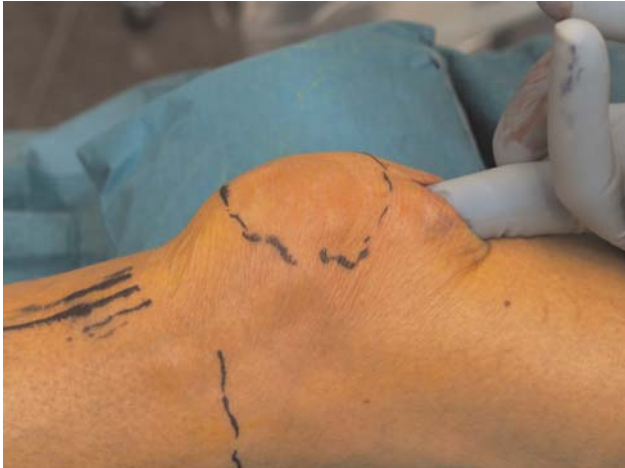

FIGURE 4. A finger should be able to fit easily into the joint below the patella. If it is too tight it can be difficult to instrument the joint and consideration should be given to expanding entry with a partial medial or lateral arthrotomy.

wire is within the medullary canal. In metadiaphyseal fractures, it is important to center the wire in the distal fragment in both the anteroposterior and lateral views.

Now the length of the nail is determined (or after the reaming process) using the proper measuring guide. Be careful not to overestimate the length. It is much easier to mount a longer end cap than to remove a nail protruding into the knee joint.

If guide systems are used for placement of the distal locking screws, it is then necessary for the probe that the nail is first locked distally, and in cases in which the fracture can be compressed further, there is a risk that the nail will migrate into the knee joint.

Before reaming, the fracture is reduced in the usual manner. A percutaneous reduction clamp might be useful in reducing oblique fractures to an anatomic or near-anatomic position during the reaming process. Positioning with the legs stretched makes it much simpler to reposition

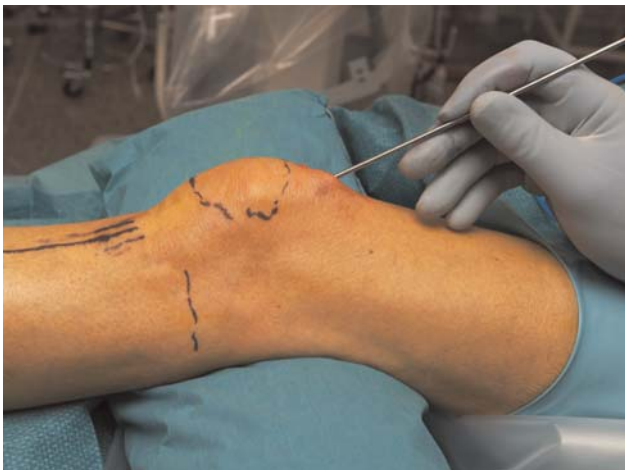

FIGURE 5. The guide wire is introduced into the knee joint and is placed on top of the tibia. If it is aimed at the drawn midline of the tibia, placing the guide wire correctly at the first attempt often is successful.

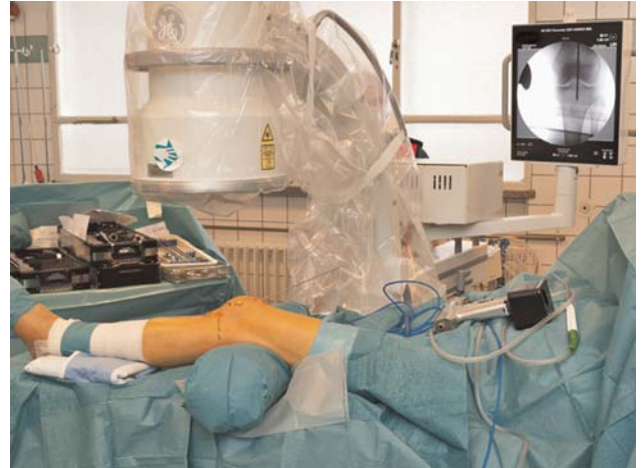

FIGURE 6. Correct placement of the guide wire is checked under fluoroscopy in both planes.

and fix until the nail is inserted. It is essential that the reaming is performed through the protection sleeve (Figure 10), and it is recommended that the correct position of the sleeve is checked radiographically several times during the process to avoid intraarticular damage. Be aware that, depending on the length of the tibia, there will typically be a need to use a reamer at the suprapatellar entry that is longer than the infrapatellar entry. The reaming then takes place as usual to a diameter that is 1 mm to 1.5 mm larger than the diameter of the nail.

Depending on the manufacturer of the nail, it will now often be necessary to remove the inner part of the sleeve protector before the nail is inserted (Figure 11). Ordinarily it should be possible, if necessary, before inserting the nail to place blocking screws in both planes, which can reposition and improve the stability of the fracture. The nail is locked proximally through the system's targeting device and distally by freehand technique (Figure 12).

A proper end cap is inserted (Figure 13), and under fluoroscopy it is then ensured in both planes that the nail does not protrude into the knee joint. With a finger in the

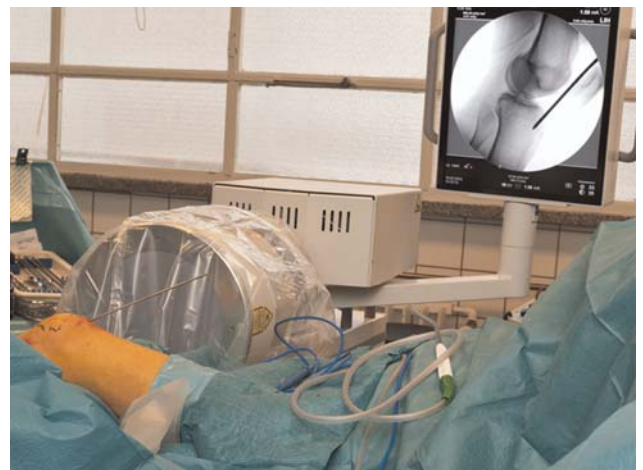

FIGURE 7. Correct placement of the guide wire.

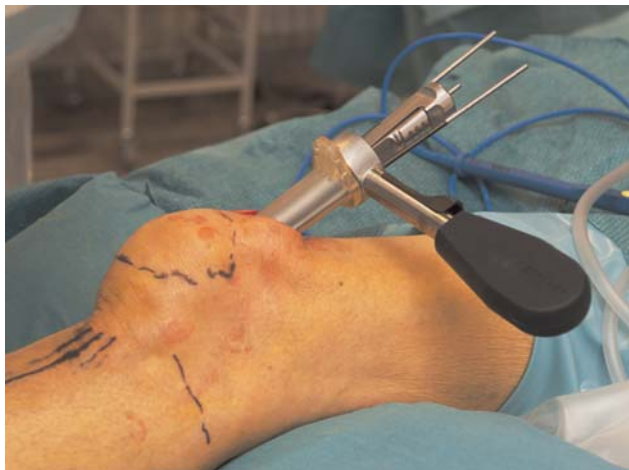

FIGURE 8. The trocar and drill sleeve are inserted along with an elastic nail insertion sleeve over the guide wire. This system allows the simultaneous fixation of the sleeves to the tibia plateau.

knee joint, an additional digital check is made that the nail cannot be felt, and simultaneously the cartilage on the patella and the femur can be checked for damage (Figure 14). The knee joint is flushed with saline to ensure that debris and blood is removed from the joint (Figure 15).

DISCUSSION

With SPN, it has become simpler to perform nailing of proximal tibial fractures. The indications for this technique are far more extensive, and it can also be used advantageously for shaft fractures and distal metaphyseal fractures. The method has significant advantages but also has potential risks that should be assessed.

The main advantages are the simple positioning of the patient and the injured leg, which simplifies reduction of the fracture and the retention of this during nailing. When the leg is positioned stretched on the table, it also is easier to install blocking screws and position the C-arm when the distal screws are to be inserted, with no need for rearrangement. From

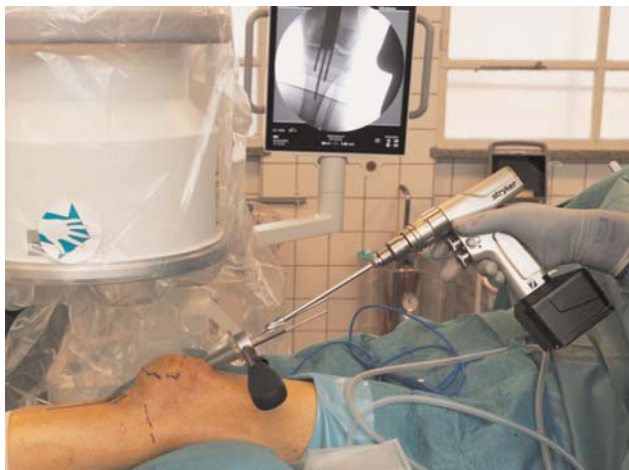

FIGURE 9. With the drill sleeve fixed to the tibia, an opening is made with a short reamer proximally in the tibia.

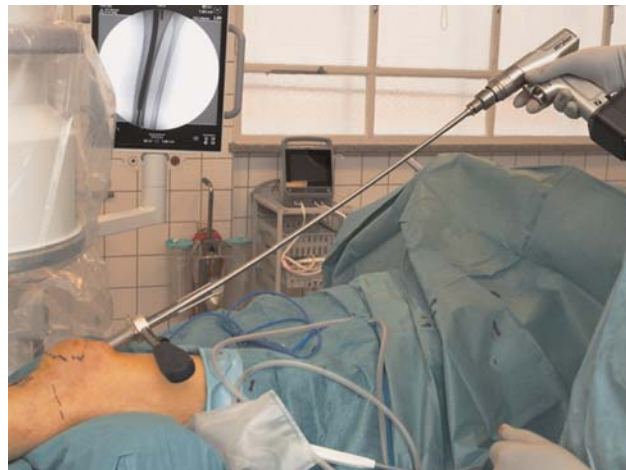

FIGURE 10. Reaming is performed through the drill sleeve as usual, while this is securely fixed to the top of the tibia. There may be a need for extra long reamers. Note the risk of compromising sterility when working close to the anesthesia barrier.

experience in this method of nailing, the soft tissue is exposed to far less intraoperative trauma compared with traditional positioning, and it is possible that the risk of compartment syndrome is thereby reduced. Further advantages of the method are reduced need for an assistant and a shorter operating time.

Concerns over the use of SPN include entry through a healthy knee joint and the risk of inflicting damage to the knee joint and, at worst, causing an infection in the joint. Despite this, today many retrograde femoral nailings and arthroscopies of the knee joint are performed without the same concerns. Jakma *et al.*³ operated on seven patients with SPN, four of whom had arthroscopy performed before or after nailing. In spite of the fact that unreamed nails were inserted and only the thinnest reamers were used to open proximally all showed signs of cartilage damage.³ In Tornetta and Collins'¹ original series of 25 patients, one patient developed postoperative hemarthrosis, and two patients had minor cartilage abrasion.¹ Later Ryan and Tornetta⁶ modified the method by nailing with the knee joint in 20-30 degrees flexion, changing the surgical

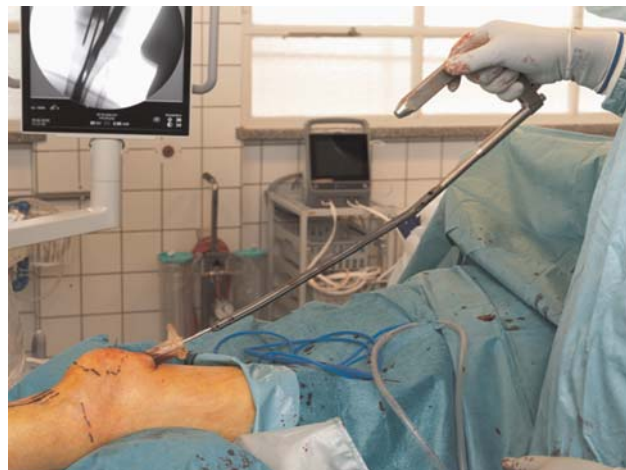

FIGURE 11. The nail is placed into the tibia over the guide wire and through the elastic nail insertion sleeve.

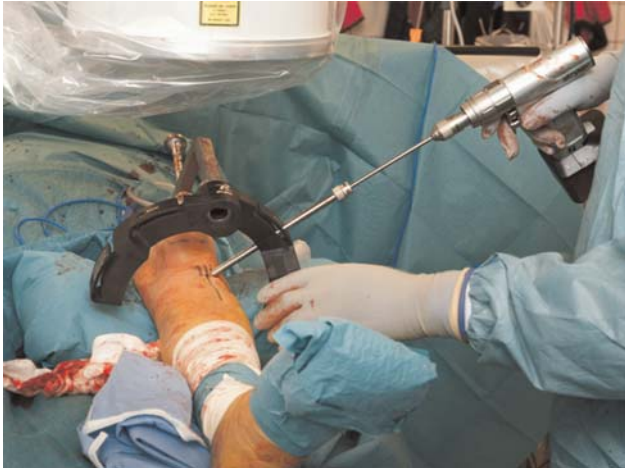

FIGURE 12. The nail is proximally locked using the system's targeting device.

entry to a smaller incision of 3-5 cm from the middle to the upper part of the patella, and performing the medial arthrotomy covering only the upper part of the retinaculum and 1-2 cm into the quadriceps tendon.⁶ Several manufacturers have now developed equipment for SPN in which protection sleeves protect against intraarticular damage. Sanders *et al.*⁷ operated on 55 patients with T2 (Stryker, Kalamazoo, MI) and Trigen (Smith and Nephew, Memphis, TN) nails with the suprapatellar approach. In 13 of 15 patients, arthroscopy was performed before and after nailing, and no cartilage changes were seen. One year after surgery, 33 patients had MRI performed with respect to cartilage damage, one had grade II patellofemoral changes and one had grade III changes, but there was no correlation between the arthroscopic changes, MRI scans, or the clinical examination.

In cadaver studies that examined the risk of intraarticular damage by the traditional infrapatellar entry, injury to the medial meniscus and the intermeniscal ligament has primarily been reported, but with less damage to the lateral meniscus and the footprint of the anterior cruciate ligament (ACL).⁵ Cadaver studies examining the injuries after nailing through a supra-

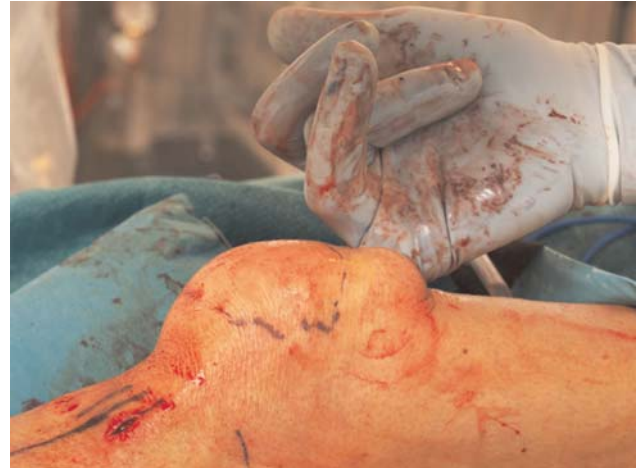

FIGURE 14. With a finger in the knee joint, the patella and femur are inspected for damage, and a final check is performed to make sure the nail cannot be felt inside the knee joint.

patellar approach have shown similar injuries to the intermeniscal ligament and medial meniscus, but no violations were observed to the articular surface, lateral meniscus, or ACL, although Beltran *et al.*⁴ reported that the nail insertion in six out of 15 patients were in close proximity to the ACL insertion. Gaines *et al.*,⁸ in a cadaver study, compared the suprapatellar approach with the standard medial parapatellar entry and demonstrated a smaller rate of intraarticular injuries when using the suprapatellar approach. The risk of injury to anterior knee structures seems to be reduced by using an entry point within the safe zone, where the center is located 9 mm ± 5 mm lateral to midline of the tibial plateau and 3 mm lateral to the center of the tibial tubercle, as described by Tornetta *et al.*⁵

A major side effect of tibial nailing is anterior knee pain, with a mean incidence of 47% after 2 yr.⁹ The reasons for knee pain remain unknown, but it is reasonable to assume that surgical entry by nailing may be of importance. A retrospective study comparing SPN with standard nailing found no differences in the level pain.⁶ In a study of 37 patients operated with SPN

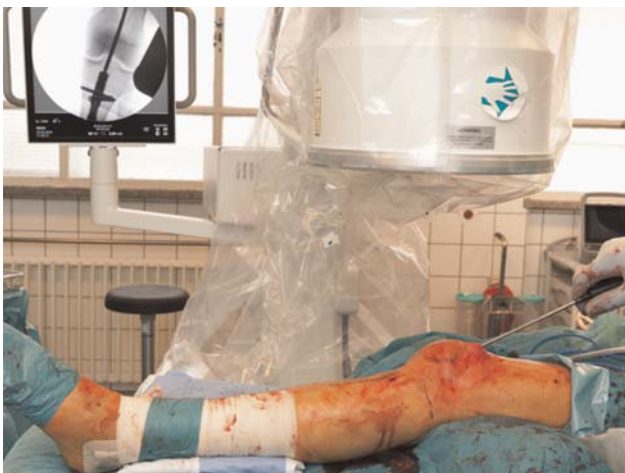

FIGURE 13. The end cap is inserted.

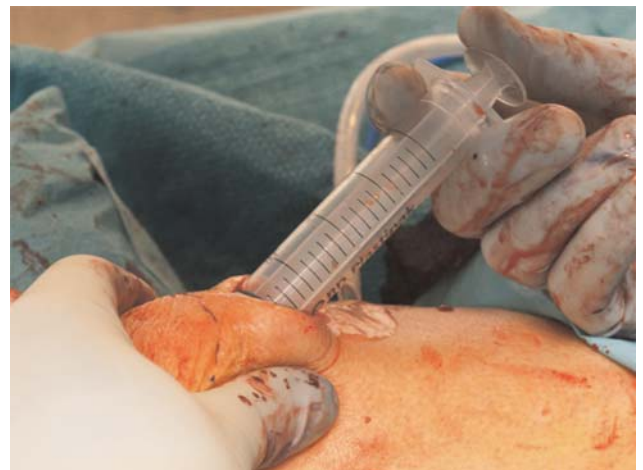

FIGURE 15. Before the end of the operation it is important to flush the knee joint carefully of blood and debris.

there were no patients with anterior knee pain at 1-year follow-up.⁷ Rothberg *et al.*¹⁰ compared 18 patients with semi-extended tibial nailing with a control group of uninjured patients, and at 1 yr there was no increased incidence of anterior knee pain in the fracture group.

Suprapatellar nailing of tibial fractures is a simple method with many advantages over traditional tibial nailing. The method is still new and not yet widely used. There is room for development of the method and improvement of instruments, thus increasing safety and indications.

CONCLUSION

This article describes an operation method, and in addition to the benefits, potential risks with the method are shown. The method appears to be safe with no greater rate of complications compared with the traditional method, but clearly further studies with longer follow-up are necessary and in particular randomized studies comparing it with the previous gold standard treatment.

REFERENCES

1. Tornetta PIII, Collins E. Semiextended position of intramedullary nailing of the proximal tibia. *Clin Orthop Relat Res.* 1996; 328:185–189.
2. Morandi M, Banka T, Gaiarsa GP, *et al.* Intramedullary nailing of tibial fractures: review of surgical techniques and description of a percutaneous lateral suprapatellar approach. *Orthopedics.* 2010; 33:172–179.
3. Jakma T, Reynders-Frederix P, Rajmohan R. Insertion of intramedullary nails from the suprapatellar pouch for proximal tibial shaft fractures. A technical note. *Acta Orthop Belg.* 2011; 77:834–837.
4. Beltran MJ, Collinge CA, Patzkowski JC, *et al.* Intra-articular risk of suprapatellar nailing. *Am J Orthop.* 2012; 12:546–550.
5. Tornetta PIII, Riina J, Geller J, *et al.* Intraarticular anatomic risks of tibial nailing. *J Orthop Trauma.* 1999; 13:247–251.
6. Ryan SP1, Steen B, Tornetta PIII. Semi-extended nailing of metaphyseal tibia fractures: alignment and incidence of post-operative knee pain. *J Orthop Trauma.* 2014; 28:263–269.
7. Sanders RW, DiPasquale TG, Jordan CJ, *et al.* Semiextended intramedullary nailing of the tibia using a suprapatellar approach: radiographic results and clinical outcomes at a minimum of 12 months follow-up. *J Orthop Trauma.* 2014; 28(Suppl 8):S29–S39.
8. Gaines RJ, Rockwood J, Garland J, *et al.* Comparison of insertional trauma between suprapatellar and infrapatellar portals for tibial nailing. *Orthopedics.* 2013; 36:e1155–e1158.
9. Katsoulis E, Court-Brown C, Giannoudis PV. Incidence and aetiology of anterior knee pain after intramedullary nailing of the femur and tibia. *J Bone Joint Surg Br.* 2006; 88:576–580.
10. Rothberg DL, Daubs GM, Horwitz DS, *et al.* One-year post-operative knee pain in patients with semi-extended tibial nailing versus control group. *Orthopedics.* 2013; 36:e548–e553.