

# First report of dabigatran reversal in iatrogenic pericardial tamponade during catheter ablation of atrial fibrillation



Jared D. Miller, MD, Jeffrey A. Brinker, MD, David D. Spragg, MD, FHRS

From the Division of Cardiology, Johns Hopkins University School of Medicine, Baltimore, Maryland.

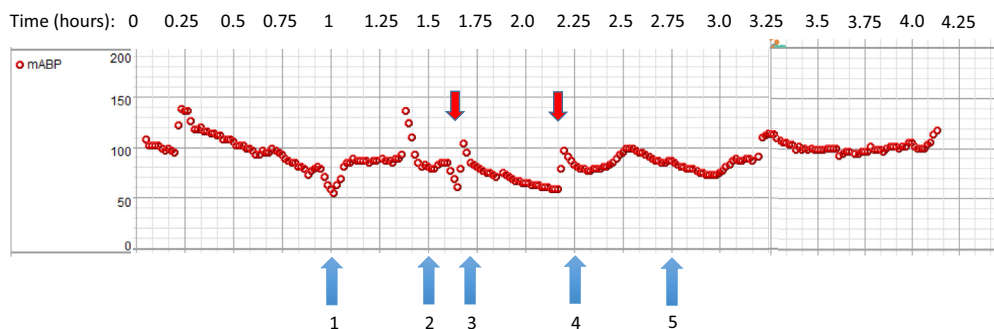
## Introduction

Catheter ablation of atrial fibrillation (AF) is recommended for the management of symptomatic paroxysmal or persistent AF.<sup>1,2</sup> Iatrogenic pericardial tamponade is a well-described potential complication of AF ablation. Pericardial tamponade has been reported to be a complication of 1%–2% of AF ablation procedures.<sup>3,4</sup> The recently published RE-CIRCUIT study supports the value of performing AF ablation on uninterrupted dabigatran to minimize bleeding and stroke risk.<sup>5</sup> Idaracizumab is an approved and widely available monoclonal antibody fragment that has been shown to bind dabigatran and reverse its anticoagulant effect.<sup>6</sup> Herein, we report the first use of idaracizumab to reverse the anticoagulant effect of dabigatran in the management of iatrogenic pericardial tamponade during AF ablation.

## Case report

A 59-year-old woman with obesity and symptomatic paroxysmal AF presented in normal sinus rhythm for pulmonary vein isolation ablation. She had been on Pradaxa 150 mg

(orally, twice a day) for the previous 4 weeks and no antiplatelet drugs. She took Pradaxa the morning of the procedure, approximately 4 hours prior to venous access. General anesthesia was administered and her blood pressure was 137/66 mm Hg without need for vasopressors. Three 8.5F sheaths were placed in the right femoral vein for placement of a coronary sinus catheter and planned double transseptal puncture. A 9F sheath was placed in the left femoral vein for placement of an intracardiac echocardiography (ICE) catheter, which was used to image the left atrial appendage and pericardium. The baseline activated clotting time was 184 seconds and 7000 units of heparin were administered with a follow-up activated clotting time of >400 seconds. Two transseptal punctures were performed under ICE and fluoroscopic guidance. We hypothesize that the second transseptal puncture resulted in the pericardial effusion, most likely during manipulation of the needle/sheath assembly while descending from the superior vena cava. Within less than 10 minutes, the patient developed hypotension to a blood pressure of 78/50 mm Hg (nadir). The hemodynamic course is outlined in Figure 1. The ICE catheter was manip-



**Figure 1** Mean arterial blood pressure in mm Hg over time during the case. At blue arrow (1), a diagnostic electrophysiology study on isoproterenol was completed. At (2), transseptal puncture was performed. At (3), hypotension was noted, effusion was observed, and protamine was administered. At (4), idaracizumab was requested from our pharmacy. At (5), idaracizumab was administered. Red arrows indicate administration of bolus doses of vasopressor agent.

**KEYWORDS** Atrial fibrillation; Catheter ablation; Anticoagulation (Heart Rhythm Case Reports 2017;3:566–567)

**Address reprint requests and correspondence:** Dr Jared D. Miller, Division of Cardiology, Johns Hopkins University School of Medicine, 1800 Orleans St, Zayed 7125, Baltimore, MD 21287. E-mail address: Jmill233@jhmi.edu.

ulated to demonstrate a 1.2-cm pericardial effusion posterior to the left ventricle (Figure 2). The effusion stayed at this size for the remainder of its visualization with the ICE catheter. The hypotension improved with intravenous fluid bolus and vasopressor administration. Protamine was administered to reverse the effect of heparin. Hypotension persisted despite

### KEY TEACHING POINTS

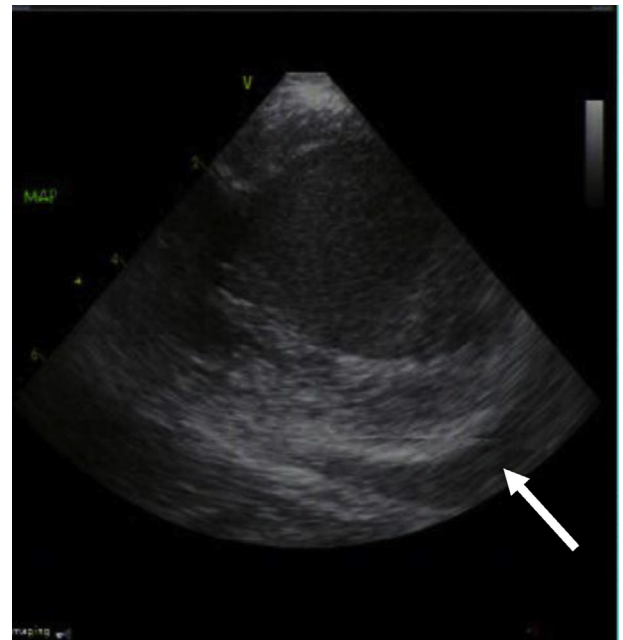
- Uninterrupted dabigatran is becoming more common in catheter ablation of atrial fibrillation.
- Pericardial tamponade remains a significant risk of catheter ablation of atrial fibrillation.
- In the setting of dabigatran use, anticoagulation during pericardial tamponade in the setting of catheter ablation of atrial fibrillation can be reversed using idaracizumab.

protamine administration and vasopressor and volume support; pericardiocentesis was attempted but was unsuccessful owing to the posterior location of the effusion. Cardiac surgery was consulted. Given increase in effusion size and ongoing need for vasopressor support, 5 g idaracizumab was administered as 2 boluses of 2.5 mg within a 15-minute interval. Idaracizumab was readily available and was administered within 20 minutes of the initial phone call to our pharmacy. Though the effusion may have stabilized with protamine infusion alone, the decision to give idaracizumab was made because of the acute development of hypotension, the need for ongoing and escalating vasopressor support, and the possibility of surgical intervention for a posterior pericardial effusion not easily amenable to pericardiocentesis. Blood pressure and effusion size stabilized. The patient was admitted to the Cardiac Care Unit. A transthoracic echocardiogram later that day revealed a stable pericardial effusion (stable at 1.2 cm). Two days after the procedure, she was discharged home and she continues to do well. Given her CHADS<sub>2</sub>-VASc score of zero (gender only), she was discharged off of dabigatran indefinitely.

### Discussion

Periprocedural anticoagulation remains a controversial and important topic in AF ablation. Although uninterrupted anticoagulation is important in reducing thromboembolic events, it comes at the potential risk of increased bleeding events, including pericardial tamponade.<sup>1</sup> Pericardiocentesis is the preferred method of managing tamponade, but it is not possible or sufficient in all cases. As high as 5% of pericardial tamponade cases in this setting have required surgical intervention.<sup>7</sup>

Uninterrupted dabigatran presents an attractive option for AF ablation, given the results of RE-CIRCUIT and its reversibility with idaracizumab. The other available novel oral



**Figure 2** Intracardiac echocardiography displaying a short-axis view of the left ventricle, and a posterolateral pericardial effusion (white arrow).

anticoagulants do not currently have approved reversal agents. Idaracizumab was not used in the RE-CIRCUIT study and to date its use has not been reported in the management of pericardial tamponade in the setting of AF ablation. The case reported herein demonstrates its potential effectiveness in managing pericardial tamponade and further informs the data supporting uninterrupted dabigatran as an ideal periprocedural anticoagulation strategy for AF ablation.

### References

1. Calkins H, Hindricks G, Cappato R, et al. 2017 HRS/EHRA/ECAS/APHS/SOL-AECE Expert Consensus Statement on Catheter and Surgical Ablation of Atrial Fibrillation. *Heart Rhythm* 2017;14(10):e275–e444.
2. Kirchhof P, Benussi S, Kotecha D, et al. 2016 ESC Guidelines for the management of atrial fibrillation developed in collaboration with EACTS. *Eur Heart J* 2016; 37:2893–2962.
3. Cappato R, Calkins H, Chen SA, Davies W, Iesaka Y, Kalman J, Kim YH, Klein G, Packer D, Sakines A. Worldwide survey on the methods, efficacy, and safety of catheter ablation for human atrial fibrillation. *Circulation* 2005;111:1100–1105.
4. Cappato R, Calkins H, Chen SA, et al. Updated worldwide survey on the methods, efficacy, and safety of catheter ablation for human atrial fibrillation. *Circ Arrhythm Electrophysiol* 2010;3:32–38.
5. Calkins H, Willems S, Gerstenfeld EP, et al. Uninterrupted dabigatran versus warfarin for ablation in atrial fibrillation. *N Engl J Med* 2017;376:1627–1636.
6. Pollack CV Jr, Reilly PA, Eikelboom J, et al. Idaracizumab for dabigatran reversal. *N Engl J Med* 2015;373:511–520.
7. Latchamsetty R, Gautam S, Bhakta D, et al. Management and outcomes of cardiac tamponade during atrial fibrillation ablation in the presence of therapeutic anticoagulation with warfarin. *Heart Rhythm* 2011;8:805–808.