

Tibial Cortex Transverse Transport Facilitates Severe Diabetic Foot Wound Healing via HIF-1 α -Induced Angiogenesis

Jie Liu^{1,*}, Xiajie Huang^{1,*}, Hongjie Su¹, Jie Yu¹, Xinyu Nie¹, Kaibing Liu¹, Wencong Qin¹, Yongxin Zhao¹, Yongfeng Su¹, Xiaocong Kuang², Di Chen³, William W Lu⁴, Yan Chen¹, Qikai Hua¹

¹Department of Bone and Joint Surgery, The First Affiliated Hospital of Guangxi Medical University, Nanning, Guangxi, People's Republic of China; ²Yulin Campus of Guangxi Medical University, Yulin, Guangxi, People's Republic of China; ³Research Center for Computer-Aided Drug Discovery, Shenzhen Institute of Advanced Technology, Chinese Academy of Sciences, Shenzhen, People's Republic of China; ⁴Department of Orthopaedics and Traumatology, The University of Hong Kong, Pokfulam, Hong Kong

*These authors contributed equally to this work

Correspondence: Yan Chen; Qikai Hua, Department of Bone and Joint Surgery, The First Affiliated Hospital of Guangxi Medical University, Nanning, People's Republic of China, Email cy003@connect.hku.hk; hqk100@yeah.net

Purpose: Management of severe diabetic foot ulcers (DFUs) remains challenging. Tibial cortex transverse transport (TTT) facilitates healing and limb salvage in patients with recalcitrant DFUs. However, the underlying mechanism is largely unknown, necessitating the establishment of an animal model and mechanism exploration.

Methods: Severe DFUs were induced in rats, then assigned to TTT, sham, or control groups (n=16/group). The TTT group underwent a tibial corticotomy, with 6 days each of medial and lateral transport; the sham group had a corticotomy without transport. Ulcer healing was assessed through Laser Doppler, CT angiography, histology, and immunohistochemistry. Serum HIF-1 α , PDGF-BB, SDF-1, and VEGF levels were measured by ELISA.

Results: The TTT group showed lower percentages of wound area, higher dermis thickness (all p < 0.001 except for p = 0.001 for TTT vs Sham at day 6) and percentage of collagen content (all p < 0.001) than the other two groups. The TTT group had higher perfusion and vessel volume in the hindlimb (all p < 0.001). The number of CD31⁺ cells (all p < 0.001) and VEGFR2⁺ cells (at day 6, TTT vs Control, p = 0.001, TTT vs Sham, p = 0.006; at day 12, TTT vs Control, p = 0.003, TTT vs Sham, p = 0.01) were higher in the TTT group. The activity of HIF-1 α , PDGF-BB, and SDF-1 was increased in the TTT group (all p < 0.001 except for SDF-1 at day 12, TTT vs Sham, p = 0.005). The TTT group had higher levels of HIF-1 α , PDGF-BB, SDF-1, and VEGF in serum than the other groups (all p < 0.001).

Conclusion: TTT enhanced neovascularization and perfusion at the hindlimb and accelerated healing of the severe DFUs. The underlying mechanism is related to HIF-1 α -induced angiogenesis.

Keywords: distraction osteogenesis, tibial cortex transverse transport, diabetic foot, HIF-1 α , angiogenesis

Introduction

The global diabetes prevalence in 20–79 year olds in 2021 was estimated to be 10.5% (536.6 million people), rising to 12.2% (783.2 million) in 2045.^{1,2} One of the most serious complications of diabetes is foot problems, which includes foot ischemia, ulcer, and infection.³ Of the diabetic patients, 19% to 34% will develop a foot ulcer in their lifetime.⁴ Diabetic foot ulcer (DFU) is a foot ulcer in person with currently or previously diagnosed diabetes and usually accompanied by neuropathy and/or peripheral artery disease, as defined by the International Working Group on Diabetic Foot (IWGDF).⁵ The current treatment for DFU is still challenging, although a number of traditional conservative and/or surgical treatments (debridement, revascularization, and flap and graft reconstruction) are available.^{6,7} Approximately 20% of patients with a DFU will have lower-extremity amputation, and 10% will die within 1 year of their first DFU diagnosis.^{4,8}

As DFU is mainly caused by peripheral arterial disease and the corresponding tissue ischemia, treatment aims to regenerate vessels and improve perfusion of the limb. Distraction osteogenesis, in which a corticotomy is performed followed by gradual distraction, can induce abundant new bone formation.^{9–12} Furthermore, distraction osteogenesis is accompanied by angiogenesis and increased perfusion of the bone and the surrounding tissues,^{13–18} suggesting a principle of distraction angiogenesis. Based on this, a new surgical technique, tibial cortex transverse distraction, or tibia transverse transport (TTT), in which a partial tibial corticotomy is created, followed by medial and lateral distraction, was recently developed to treat intractable DFU.^{6,18} This technique aids healing and limb salvage in patients with recalcitrant DFU.^{11,17,18} Moreover, increased neovascularization and perfusion of the foot that promoted ulcer healing and limb salvage were detected postoperatively.¹¹ However, as changes in neovascularization and perfusion were not detected in the control patients, the exact role of neovascularization and perfusion in the treatment of DFU using TTT is still unclear.

Owing to the limitations of neovascularization and perfusion detection in clinical studies, it is useful to investigate the mechanism of TTT in animal studies. Transverse tibial bone distraction was first created in canines by Ilizarov;⁹ then Matsuyama et al established a similar canine model and quantitatively analyzed osteogenesis and angiogenesis during transverse distraction.¹⁷ They suggested application of this technique to patients with small-diameter bones or massive bone defects. Recently, TTT was established in relatively small animal-rat.^{19,20} Yang et al established a rat model of TTT and assessed the effect of TTT on foot wound.¹⁹ However, the bone transport protocol used did not fully resemble a clinical TTT protocol and only simple non-diabetic traumatic foot wounds were created.¹⁹ Using a similar rat model of TTT, another study intended to evaluate the effect of TTT on DFU.²⁰ However, only minor DFUs (relative small wound size and without comorbidities such as ischemia) were established.²⁰ According to clinical studies, TTT is suggested to apply to severe DFU, rather than non-diabetic traumatic foot wounds or mild DFU, considering the cost-effectiveness of the technique.^{6,21,22} Thus, an animal model of severe DFU treated using TTT is needed for exploration of the underlying mechanism.

Tissue hypoxia, a critical driving force for angiogenesis, is controlled by the hypoxia-inducible factor 1- α (HIF-1 α) pathway. Hyperglycemia affects HIF-1 α stability and activation in the circulation and tissue biopsies in patients with DFUs.²³ Correspondingly, the expression of HIF-1 α target genes essential for wound healing, such as vascular endothelial growth factor (VEGF), platelet-derived growth factor BB (PDGF-BB), and stromal cell-derived factor 1 (SDF-1), were down-regulated in patients or mice with DFUs.^{24–28} Moreover, HIF-1 α stabilization or supplementation of the angiogenic factors VEGF, PDGF-BB and SDF-1 is sufficient to promote wound healing in a diabetic environment.^{23,29,30} Nevertheless, application of a single angiogenic factor to DFU has met with limited success in clinic,³¹ indicating that multiple angiogenic factors is an effective alternative.

On the other hand, studies of longitudinal distraction osteogenesis detected elevated expression of HIF-1 α in the distracted gap and in the serum.^{32,33} Moreover, expression of VEGF, PDGF-BB, and SDF-1 is increased in the distraction gap and the serum during longitudinal distraction osteogenesis.^{32,34–38} However, no studies have evaluated the changes in HIF-1 α and its downstream angiogenic factors and explored their role in treatment of DFU using TTT; and the potential mechanisms by which TTT promotes severe DFU healing remain unclear.

Thus, we aimed to establish a rat model of severe DFU treated using TTT and determine the changes in ulcer healing. We intended to identify the possible association between TTT intervention and ulcer healing, limb neovascularization and perfusion, expression of HIF-1 α and downstream multiple angiogenic factors. By determining the formation and secretion of HIF-1 α and multiple angiogenic factors, we hope to provide insight into the mechanism of TTT treatment of severe DFU. We hypothesized that HIF-1 α is induced in TTT treatment in response to hypoxic stress at the distraction site which in turn stimulates formation of VEGF, PDGF-BB, and SDF-1 to enhance angiogenesis; these factors travel to the site of DFU, resulting in increased angiogenesis and ultimately ulcer healing.

Materials and Methods

Animals and Study Design

A total of 48 male 12-week-old Sprague-Dawley rats (mean weight of 230g, standard deviation (SD) 13.4 g) (Animal Center of Guangxi Medical University, China) were used in this study. After induction of diabetes, the rats were divided into the control, sham, and TTT groups (Figure 1). In the control group, the femoral artery was ligated and the dorsal foot

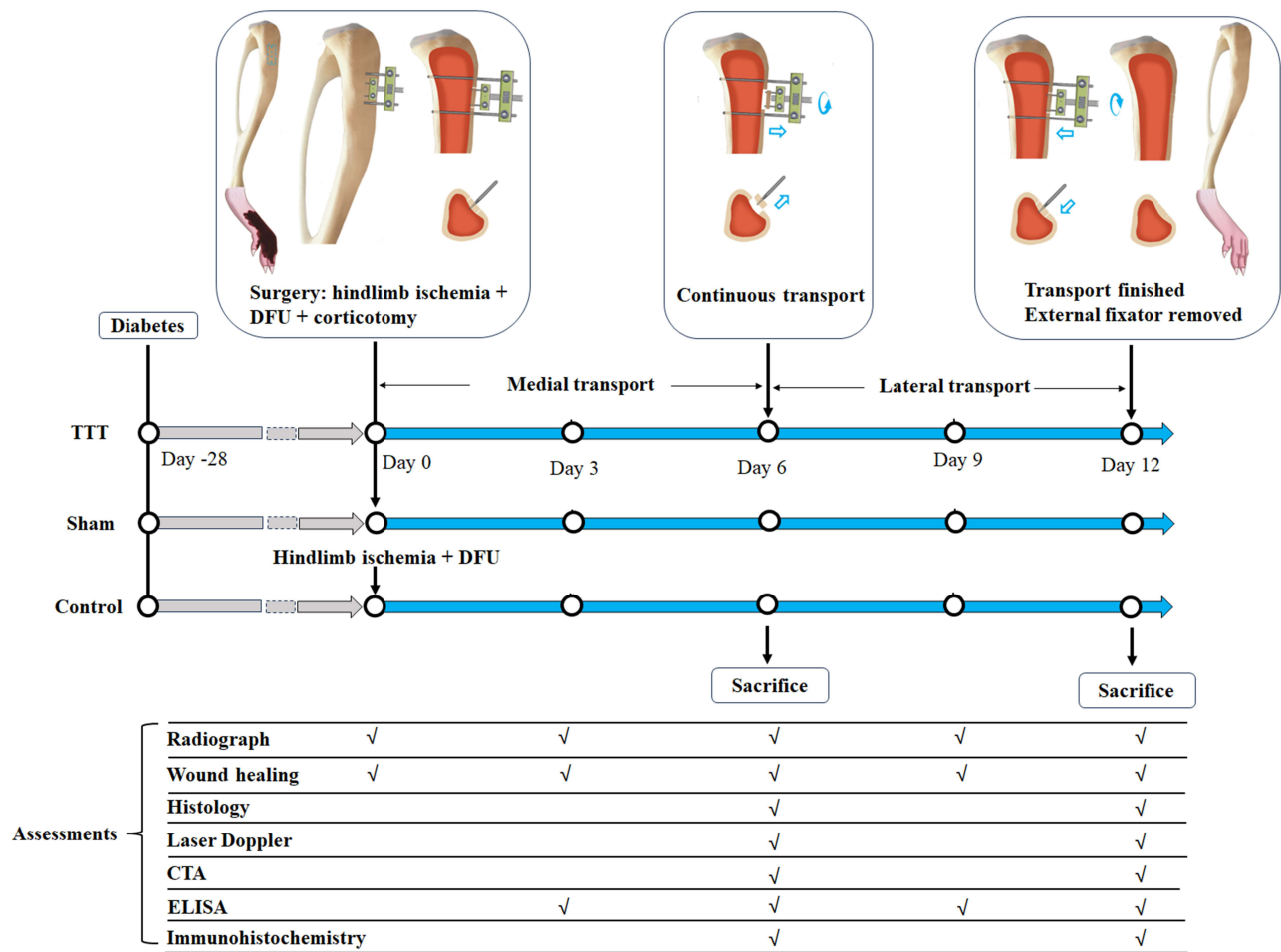


Figure 1 This schema shows the study design and the assessments at each stage. In the control group, surgery including induction of hindlimb ischemia and creation of DFU was performed 4 weeks after diabetes induction. In the TTT group, in addition to hindlimb ischemia induction and DFU creation, tibial corticotomy was performed, external fixator was attached, and the corticotomized segment was transversely distracted. The distraction phase consisted of 6 days of medial transport followed by 6 days of lateral transport. At the end of the transport, the corticotomized fragment returned to its original position and the external fixator was removed. In the sham group, all the procedures were the same as the TTT group except that the corticotomized segment would not be distracted.

Abbreviations: DFU, diabetic foot ulcer; TTT, tibial cortex transverse transport; CTA, computed tomography angiography; ELISA, enzyme-linked immunosorbent assay.

wound was created to mimic ischemic DFU; in the TTT group, in addition to femoral artery ligation and DFU creation, tibial corticotomy was performed, external fixator was assembled, and the corticotomized segment was transversely distracted; while in the sham group, all the procedures were the same as the TTT group except that the transport of the corticotomized segment was not performed (Figure 1). Animal research and conformed to National Institutes of Health guidelines for use of animals in research. All experiments were approved by the Animal Research Ethics Committee of Guangxi Medical University (Reference Number: 202008012).

Diabetic Rat Model

Diabetes was induced by a single intraperitoneal injection (100 mg/kg) of streptozotocin (STZ; Sigma-Aldrich) which was prepared in a 0.01 M sodium citrate (pH 4.3).^{39,40} On the third day following streptozotocin administration, blood samples were taken from the tail vein of the rats and blood glucose was measured using the Accutrend sensor (Roche Biochemicals, Mannheim, Germany). Blood glucose levels higher than 250 mg/dL (13.9 mmol/L) were regarded as indication of diabetes.⁴¹

Surgical Procedure

Surgery was performed 4 weeks after the induction of diabetes (Figure 1). The animals were anesthetized with 35 mg/kg of 2% sodium pentobarbital intraperitoneally.⁴² First, the femoral artery was ligated to induce hindlimb ischemia

(Figure 2A). Briefly, a 1-cm incision was made where the strongest pulsation of the femoral artery was palpable,^{43,44} then the subcutaneous fascia was retracted to expose the femoral artery. The femoral artery was separated and ligated with 4-0 silk and then dissected.⁴⁵ The incision was sutured.

Second, tibial corticotomy was performed using a protocol modified from our clinical protocol of TTT surgery.^{6,46} Briefly, a vertical rectangular corticotomy (10 mm in height and 4 mm in width) was performed on the proximal tibia, below the tibial tuberosity and medial to the tibial crest (Figure 1). A longitudinal 3-cm incision was made on the anteromedial aspect of the calf (Figure 2B). The soft tissue was retracted and the periosteum was exposed. The corticotomy was performed by drilling multiple successive unicortical holes (Figure 2C). Then, two 0.8-mm pins were inserted into the osteotomized fragment for transport while two 1.0-mm pins into the tibial shaft for mounting of the external fixator, which was custom-made according to the equipment used in clinical TTT (Figure 2D). The multiple drilling holes were connected using a small bone chisel, and the external fixator was assembled and the incision was sutured (Figure 2E). Finally, a rectangular wound (20 mm in length and 10 mm in width) was created using a sharp scissor on the dorsum of foot by removal of full-thickness skin and subcutaneous tissue, exposing the underlying tendons (Figure 2F–H). Radiographs of the hindlimb were taken immediately after surgery to confirm the sites of osteotomy and pins inserted (Figure 2I).

Transverse Transport of the Tibial Cortex

In the TTT group, the tibial cortex transverse transport was initiated at a rate of 0.1 mm every 12 hours at day 1 (Figure 1). The protocol consisted of 6 days of medial transport followed by 6 days of lateral transport. Thus, the corticotomized fragment reached its maximum displacement (1.2 mm) at day 6 and returned to its original position at day 12; and then the external fixator was removed.

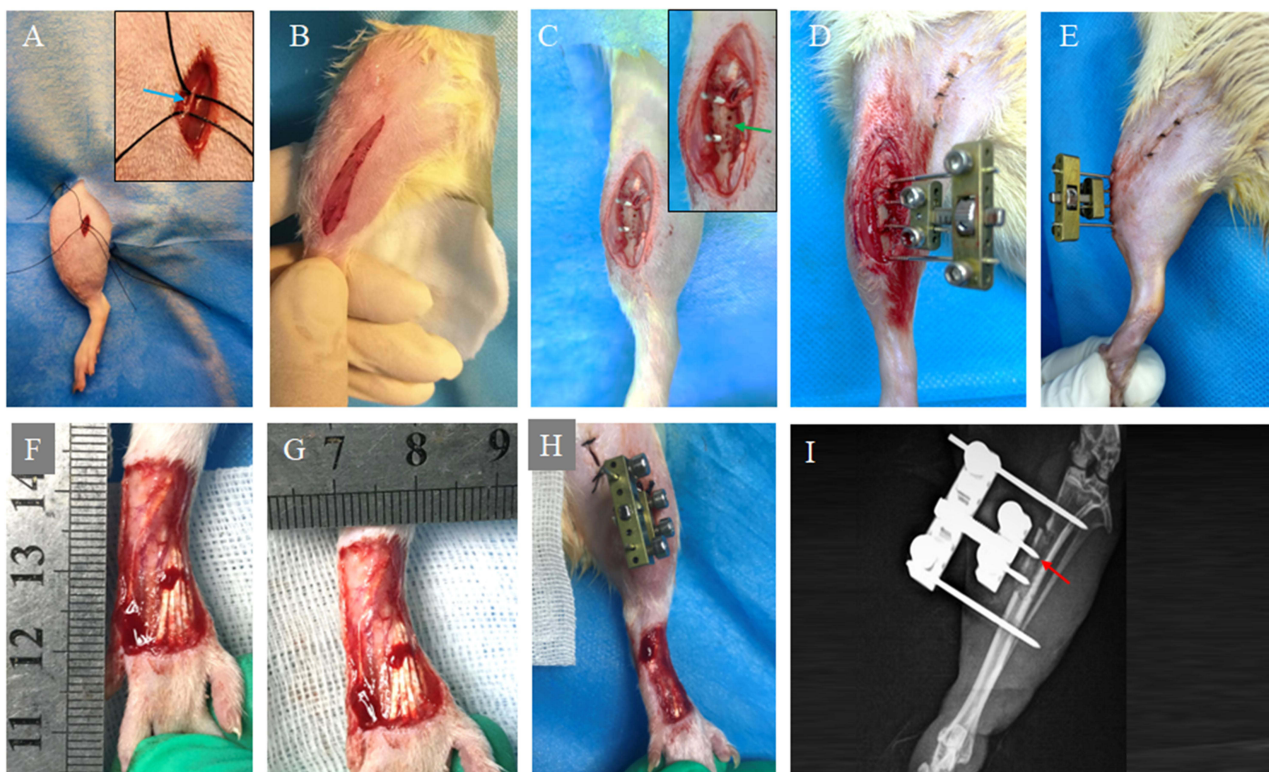


Figure 2 Procedure of TTT. (A) Four weeks after diabetes induction, the femoral artery (blue arrow) was exposed and ligated to induce hindlimb ischemia; and the incision was sutured. (B) A longitudinal 3-cm incision was made on the anteromedial aspect of the upper 1/3 of the calf, then the soft tissue was retracted and the periosteum was exposed. (C) Corticotomy (10 mm in height and 4 mm in width) was performed by drilling multiple successive unicortical holes (green arrow). Two 0.8-mm pins were inserted into the osteotomized fragment for transport while two 1.0-mm pins into the tibial shaft for anchor of the custom-made external fixator. The multiple drilling holes were connected using a small bone chisel to separate the cortex from the tibial shaft. (D and E) The external fixator was assembled and the incision was closed. (F–H) A rectangular wound (20 mm in length and 10 mm in width) was created by removal of full-thickness skin and subcutaneous tissues on the dorsum of foot. (I) Postoperative radiograph was taken to conform the sites of corticotomy (red arrow) and pins.

Radiographs

X-rays of the rat's hindlimb were taken at day 0 (immediately after the surgery), 3, 6, 9, and 12, respectively (Figure 1), to confirm the sites of the corticotomy and distraction of the corticotomized fragments.

Enzyme-Linked Immunosorbent Assay (ELISA)

Rats were anesthetized by inhalation of 3% isoflurane and blood was collected from rat-tail vein aseptically at day 3 and 9, respectively (Figure 1). While at day 6 and 12, blood was collected via cardiac puncture under anesthesia, followed by collection of wound samples and sacrifice. The blood was centrifuged at a low temperature at $3000 \times g$ for 10 min. The supernatant was collected and separated into 200 μL centrifuge tubes. The tested samples (100 μL) were incubated at 37°C and cleaned after 60 min. Serum levels of HIF-1 α , PDGF-BB, SDF-1, and VEGF were detected using ELISA according to manufacturer's instructions (HIF-1 α ELISA kit, ER0191; VEGF ELISA kit, ER0069; PDGF-BB ELISA kit, ER1242; and rat SDF-1 ELISA kit, ER1326; Quantikine, R&D Systems, Minneapolis, USA).

Wound Healing Evaluation

Photographs of the wounds were taken using a digital camera at day 3, 6, 9, and 12, respectively. The photographs contained an internal scale for the standard calibration of the measurements. The wound area was measured using ImageJ software (National Institutes of Health, Bethesda, MD, USA), and the values were expressed as percentages of the original wound size at different timepoints (calculated as the following formulation: wound area at day X / wound area at day 0 \times 100%).

Laser Doppler Perfusion Imaging

Measurements of hindlimb perfusion were performed at day 6 and 12, respectively, using Laser Doppler Perfusion Imaging (LDPI) (Moor Instruments). The rat was anesthetized by continuous inhalation of a 3% isoflurane, then placed supine and the operated hindlimb was selected for scanning. During measurements, all rats were kept in a double-glassed jar filled with 37°C water to keep the environment temperature at a constant level.

Computed Tomography Angiography (CTA)

CTA was used to assess the neovascularization of the rat's hindlimb at day 6 and 12, respectively, as that in DFU patients underwent TTT.^{6,21} After the rats ($n = 6$ for each group at each timepoint) were anesthetized, thoracotomy was performed. A needle was inserted into the left ventricle, the vasculature was flushed with heparinized saline (0.9% normal saline containing 100 U mL^{-1} heparin sodium), and 10% neutral buffered formalin was injected for pressure fixation and then flushed from the vasculature using heparinized saline. Then, we injected a contrast fluid (Microfil silicone rubber injection compounds CP-101, Ladd Research industries, Vermont, USA) into the vasculature. Rats were stored at 4°C for 24 h and part of hindlimb (from knee to foot) were then removed, fixed, decalcified and imaged by a micro-CT scanner (SkyScan 1076, Bruker, USA) with a resolution of 8.7 μm per pixel. Vascular volume was measured and analyzed.

Histology

Samples containing the entire area of the skin defect were collected after rats were sacrificed at day 6 and 12, respectively ($n = 6$ for each group at each timepoint), fixed in 10% formalin for 24 hours at room temperature, dehydrated in successively increasing alcohol concentrations, and embedded in paraffin. Sections of 5 μm thick were cut for Hematoxylin and eosin (H&E) and Masson staining and examined using a light microscope (Leica DMRB Microscope, Leica Microsystems GmbH, Germany). Epithelial thickness and collagen deposition were evaluated using Image-Pro Plus (version 5.0; Media Cybernetics, Inc.) as previously described.^{47,48} Briefly, at least five sections from each sample were stained for analysis. For each section, five areas were measured. All measurements were performed by the same operator who was blinded to the specimen's status.

Immunohistochemistry

Immunohistochemical staining was performed as previously reported.⁴⁷ The following antibodies were used: rabbit anti-rat CD31 (GB113151, China Service Organization, China; dilution 1:200); rabbit anti-rat anti-VEGFR2 (PA5-16487, Invitrogen, Massachusetts, USA; dilution 1:150); rabbit anti-rat anti-stromal cell-derived factor-1 (SDF-1, 14-7992-81, Invitrogen, Massachusetts, USA; dilution 1:100); and mouse anti-rat hypoxia-inducible factor-1 α (HIF-1 α ; ab64693, Invitrogen, Massachusetts, USA; dilution 1:100). After image capture, the number of positive cells was quantified as described by a blinder (MG).⁴⁷ Briefly, five sequential sections from each sample were stained and for each section, five areas were measured.⁴⁷

Statistical Analysis

Data are expressed as mean \pm standard deviation and tested for normality using the Shapiro–Wilk test. Comparisons among groups were performed using a one-way analysis of variance (ANOVA). If the results were statistically significant, further post hoc tests were performed. Statistical significance was set at $\alpha < 0.05$. SPSS (version 20.0; Chicago, IL, USA) was used for all statistical analyses.

Results

Radiographs

The sites of the cortectomy and the external fixators and the transport of the corticotomized fragments were confirmed on radiographs at day 0, 3, 6, 9, and 12, repetitively (Figure 3). No tibial fracture or osteomyelitis was found at the cortectomy site.

Ulcer Healing

The DFU in the TTT group appeared to heal faster than the control and the sham groups at day 3, 6, 9, and 12, respectively (Figure 4a). Analysis showed that the percentages of wound area were lower in the TTT group than in the control or sham groups at each timepoint (at day 3, TTT vs Control, $p = 0.033$, TTT vs Sham, $p = 0.041$; at day 6, TTT vs Control, $p < 0.001$, TTT vs Sham, $p = 0.0027$; at day 9, TTT vs Control, $p < 0.001$, TTT vs Sham, $p = 0.0031$; at day 12, TTT vs Control, $p = 0.0086$, TTT vs Sham, $p = 0.035$); Tukey's multiple comparison test (Figure 4b).

Histology

H&E staining showed that the newly formed epidermis of the DFU was discontinuous and uneven in the control and sham groups, whereas continuous epidermis was evident in the TTT group at day 6 and 12, respectively (Figure 5a). Some hair follicle-like tissue was present in the TTT group but hardly observed in the other groups. Analysis showed that the mean dermis thickness in the TTT group was higher than the other groups (at day 6, TTT vs Control, $p < 0.001$, TTT vs Sham, $p = 0.001$; at day 12, TTT vs Control, $p < 0.001$, TTT vs Sham, $p < 0.001$) (Figure 5b). In Masson trichrome staining, collagen was more obvious in the TTT group than the other groups (Figure 5c). Similarly, some hair follicle-like

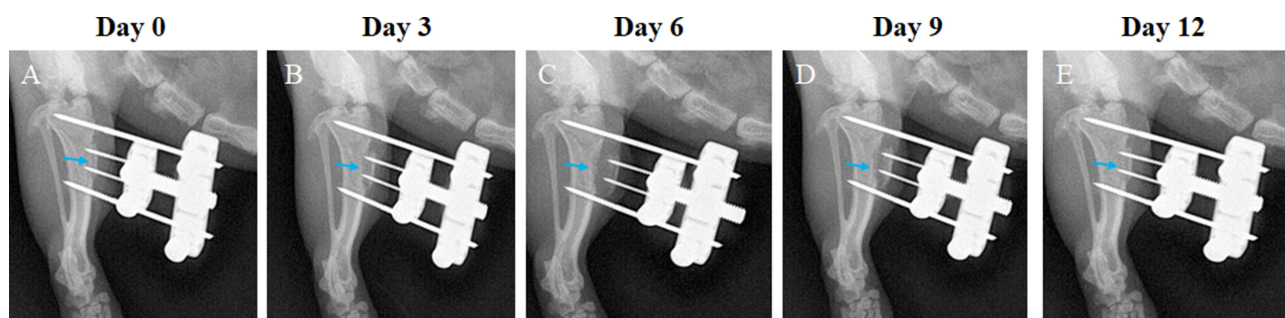


Figure 3 These postoperative radiographs show a tibia that underwent TTT. (A) The corticotomy and external fixator sites (arrow) were confirmed on radiographs immediately after surgery. (B) After 3 days of medial transport, the displacement of the corticotomized fragment was evident. (C) At day 6, the corticotomized fragment reached its maximum displacement. (D and E) This was followed by 6 days of lateral distraction, at the end of which (day 12) the corticotomized fragment returned to its original position and the external fixator was removed.

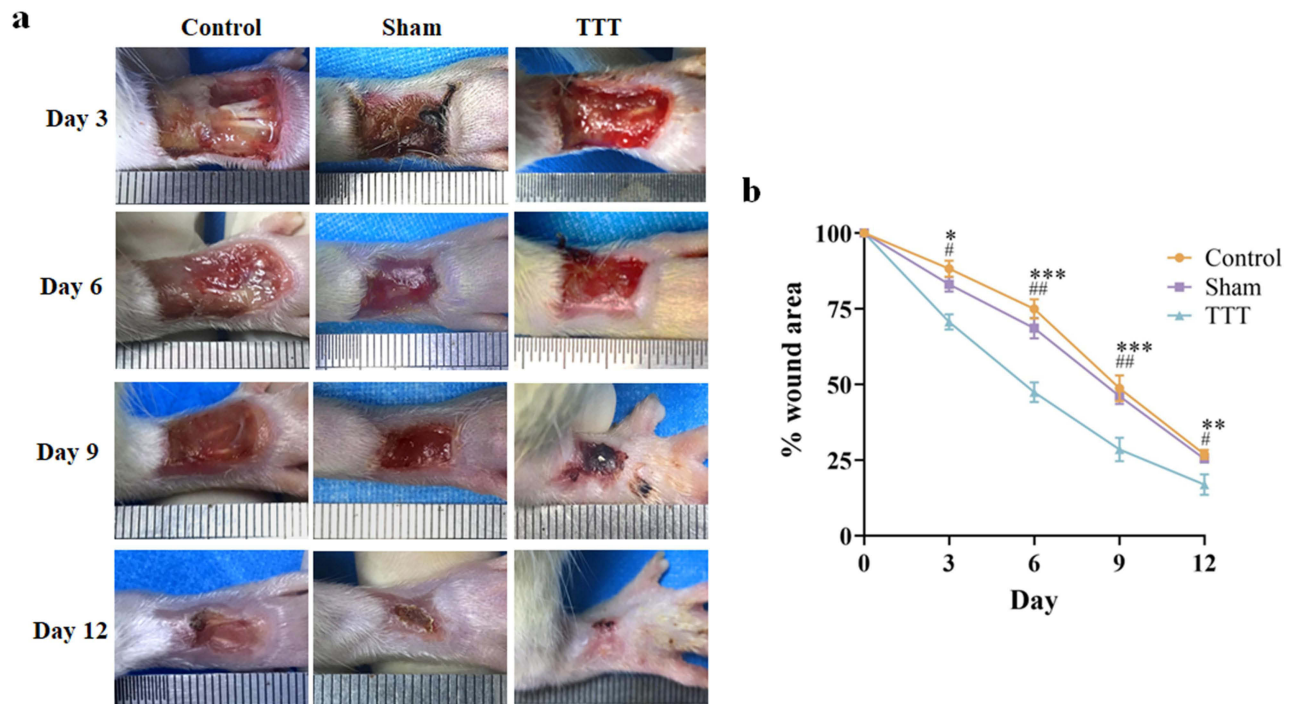


Figure 4 TTT promoted DFU healing. (a) Representative images of ulcer healing progress at day 3, 6, 9, and 12, respectively, for the three groups. (b) Mean area of DFU in the three groups during observation. * $p < 0.05$, ** $p < 0.01$, *** $p < 0.001$, TTT vs Control; # $p < 0.05$; ## $p < 0.01$, TTT vs Sham; Tukey's multiple comparison test. **Abbreviations:** TTT, tibial cortex transverse transport; DFU, diabetic foot ulcer.

tissue was observed in the TTT group while hardly seen in the other groups. Analysis showed that the TTT group had higher percentages of collagen content than the other groups (all $p < 0.001$ for TTT vs Control or TTT vs Sham, at day 6 or 12) (Figure 5d).

Laser Doppler Perfusion Imaging

The perfusion images demonstrated that the TTT group had higher perfusion in the hindlimb than the other groups at day 6 and 12, respectively (Figure 6a). This observation was confirmed in the analysis (all $p < 0.001$ for TTT vs Control or TTT vs Sham, at day 6 or 12) (Figure 6b).

Computed Tomography Angiography (CTA)

The vessel volume in the TTT group appeared to be higher than the other two groups, as demonstrated by CTA at day 6 and 12, respectively (Figure 7). This observation was confirmed in the analysis (all $p < 0.001$ for TTT vs Control or TTT vs Sham, at day 6 or 12).

ELISA

The ELISA data show that the concentration of HIF-1 α in the peripheral blood was higher in the TTT group than the other two groups at day 3, 6, 9, and 12, respectively (all $p < 0.001$ for TTT vs Control or TTT vs Sham, at day 3, 6, 9, or 12). (Figure 8A). Furthermore, the serum levels of PDGF-BB, SDF-1, and VEGF were higher in the TTT group than the other groups at day 3, 6, 9, and 12, respectively (all $p < 0.001$ for TTT vs Control or TTT vs Sham, at day 3, 6, 9, or 12) (Figure 8B–D).

Immunohistochemistry

The activity of CD31⁺ endothelial cells and VEGFR2⁺ cells were higher in the TTT group than the other two groups at day 6 and 12, respectively (for CD31⁺, all $p < 0.001$ for TTT vs Control or TTT vs Sham, at day 6 or 12; for VEGFR2⁺, at day 6, TTT vs Control, $p = 0.001$, TTT vs Sham, $p = 0.006$; at day 12, TTT vs Control, $p = 0.003$, TTT vs

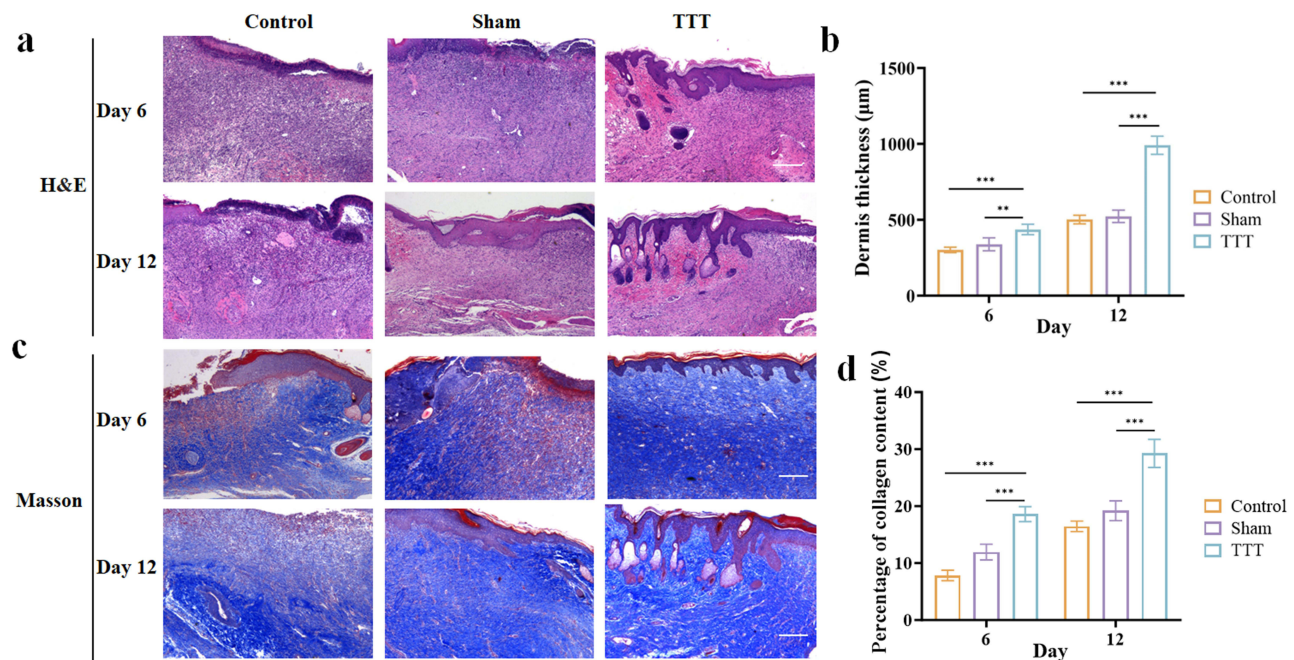


Figure 5 Representative histology images of the three groups at day 6 and 12, respectively. (a) In haematoxylin and eosin (H&E) staining, better continuous epidermis was observed in the TTT group than the other groups. Some hair follicle-like tissue was present in the TTT group. (b) Quantitative analysis showed higher dermis thickness in the TTT group than the other groups. (c) In Masson trichrome staining, more collagen was evident in the TTT group. Some hair follicle-like tissue was present in the TTT group, too. (d) Quantitative analysis showed higher percent of collagen content in the TTT group than that of the other groups. Scale bar 200 μm. Data were presented as means (standard deviations); ** $p < 0.01$, *** $p < 0.001$. TTT vs Control or Sham, Tukey's multiple comparison test.

Abbreviation: TTT, tibial cortex transverse transport.

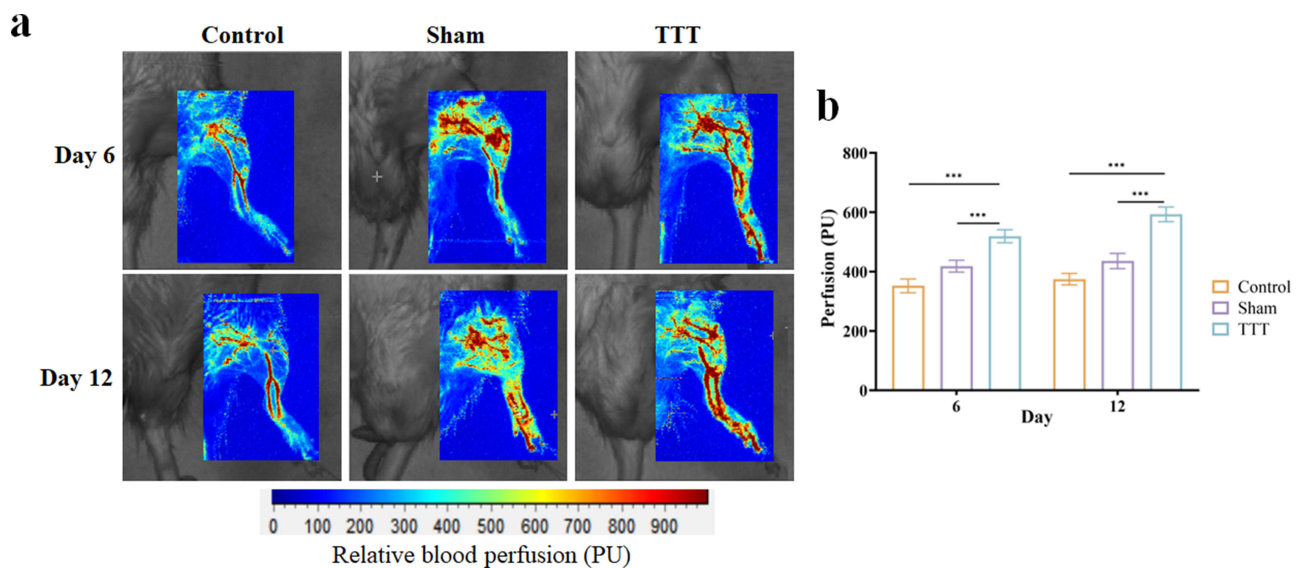


Figure 6 TTT elevated local perfusion. (a) The images demonstrated perfusion changes of the hindlimb after TTT at day 6 and 12, respectively. The color bar represents perfusion levels. (b) The TTT group showed the highest blood perfusion (perfusion unit, PU) among the three groups. *** $p < 0.001$ for TTT vs Control or TTT vs Sham, at day 6 or 12; Tukey's multiple comparison test.

Abbreviation: TTT, tibial cortex transverse transport.

Sham, $p = 0.01$; Figure 9). The expression of PDGF-BB, SDF-1, and HIF-1 α was higher in the TTT group than the other two groups at day 6 and 12, respectively (all $p < 0.001$ for TTT vs Control or TTT vs Sham, at day 6 or 12 except for SDF-1 at day 12, TTT vs Sham, $p = 0.005$; Figure 10).

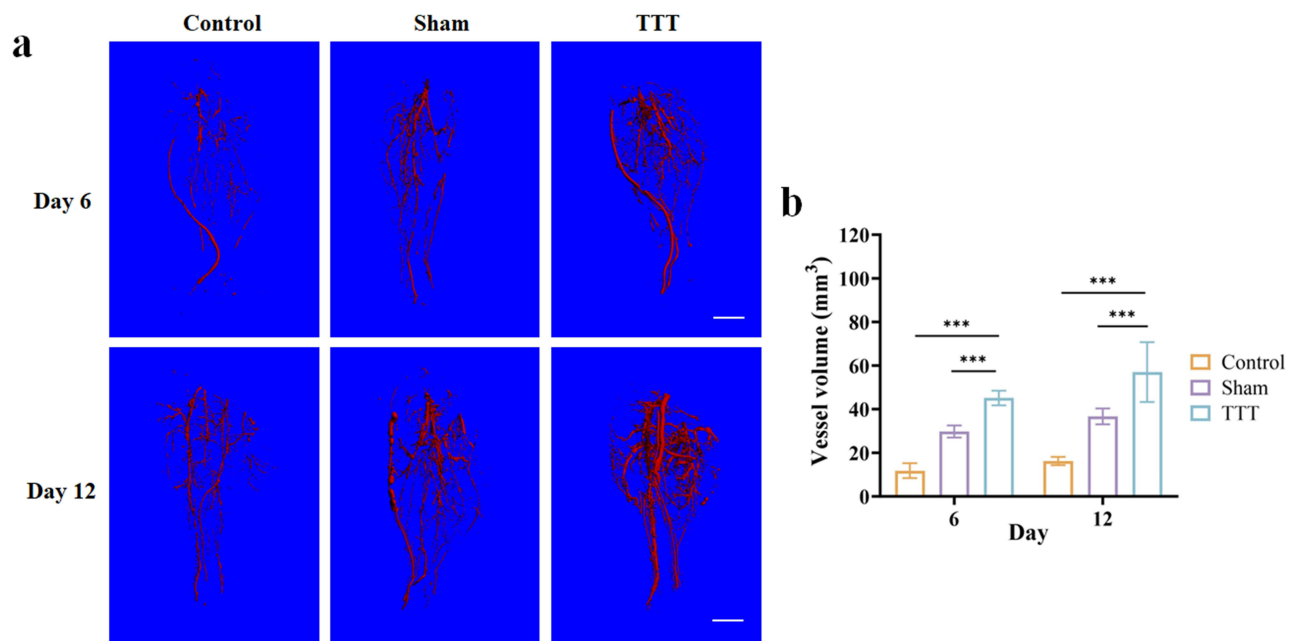


Figure 7 TTT promoted hindlimb neovascularization. (a) The images demonstrated changes in neovascularization of the hindlimb after TTT as detected using CTA at day 6 and 12, respectively. (b) The TTT group showed the highest vessel volume among the three groups. Scale bar: 5 mm. ****p* < 0.001.

Abbreviations: TTT, tibial cortex transverse transport; CTA, computed tomography angiography.

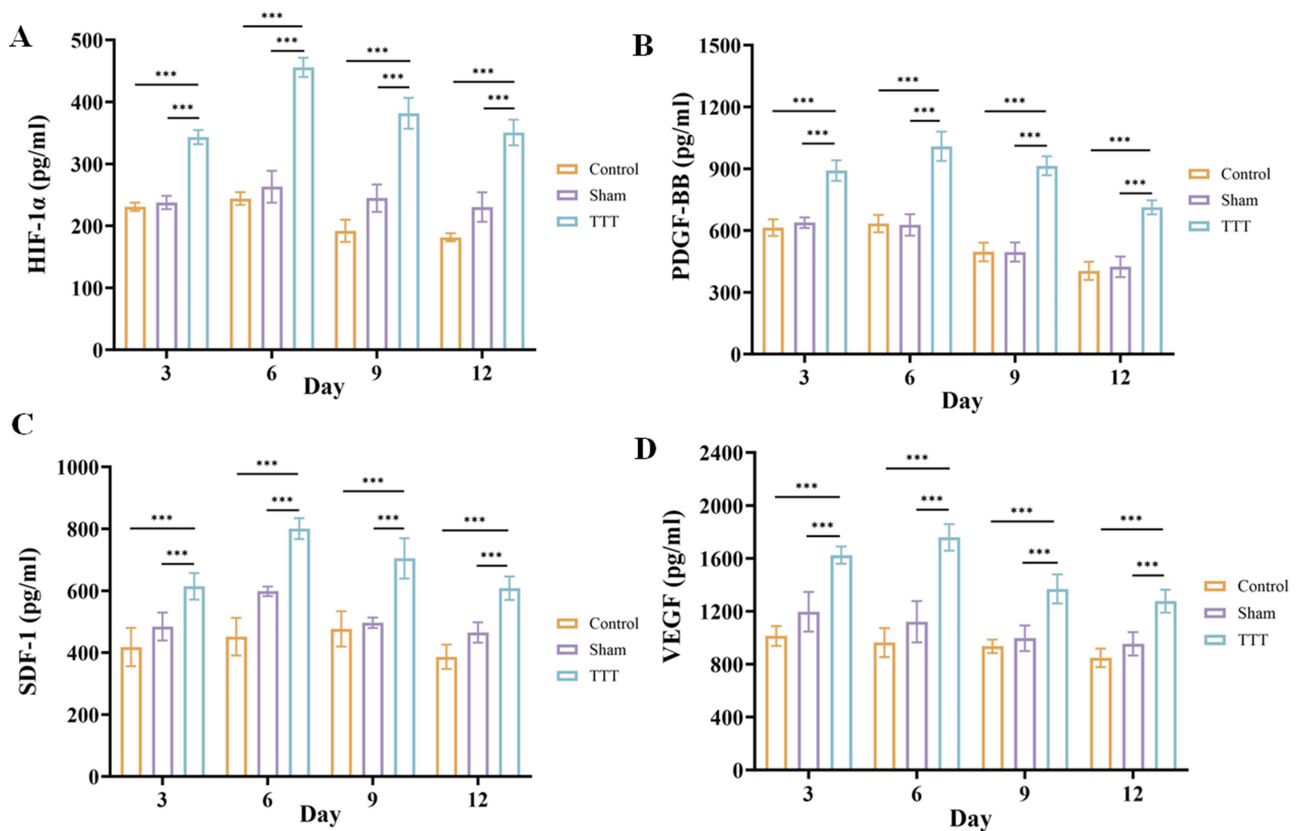


Figure 8 Concentrations of HIF-1 α and downstream angiogenic factors in serum after TTT. (A) The levels of PDGF-BB in the TTT group were higher than the other two groups at day 3, 6, 9, and 12, respectively. (B) The TTT group had higher concentrations of serum SDF-1 than the other two groups at day 3, 6, 9, and 12, respectively. (C) The levels of serum VEGF in the TTT group were higher than the other two groups at day 3, 6, 9, and 12, respectively. (D) The TTT group displayed higher concentrations of SDF-1 in serum than the other two groups at day 3, 6, 9, and 12, respectively. Data were measured as means (standard deviations). ****p* < 0.001, Tukey's multiple comparison test. **Abbreviation:** TTT, tibial cortex transverse transport.

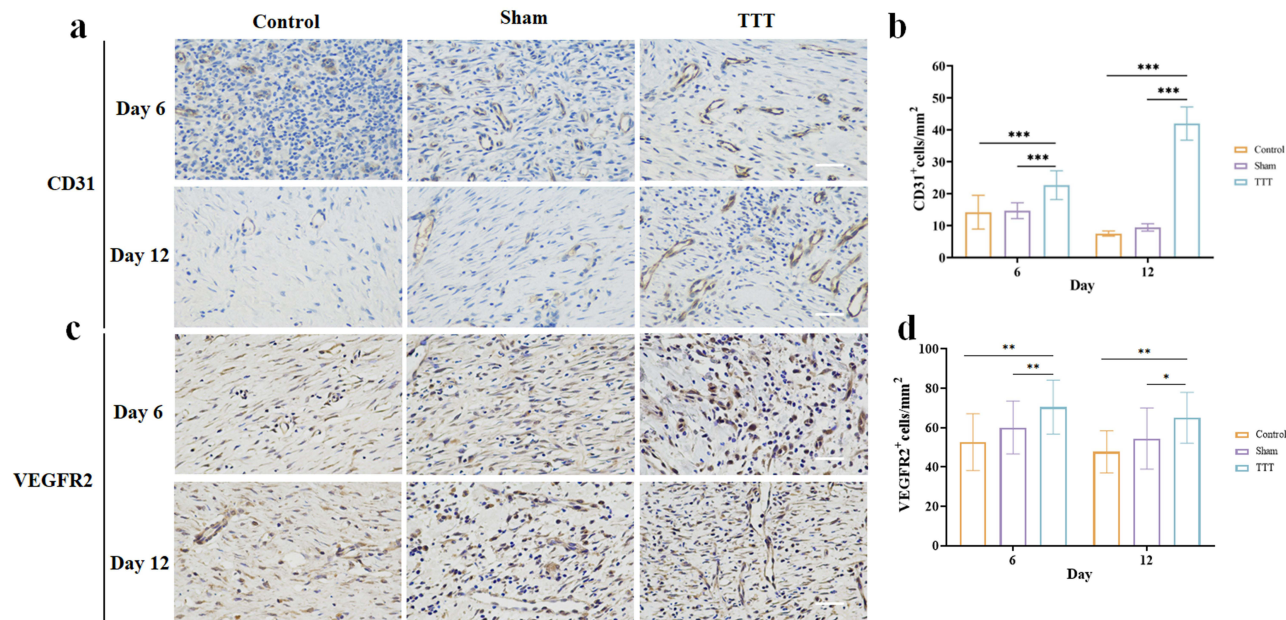


Figure 9 TTT promoted angiogenesis in the healing wound of DFU. (a) Representative immunohistochemistry images of CD31⁺ cells and VEGFR2⁺ cells in the three groups at day 6 and 12, respectively. (b) Quantitative analysis showed higher expression of CD31 in the TTT group than the other groups. (c) Representative immunohistochemistry images of VEGFR2⁺ cells in the three groups at day 6 and 12, respectively. (d) Quantitative analysis displayed higher expression of VEGFR2⁺ cells in the TTT group than the other groups. Scale bar 100 μ m. Data were presented as means (standard deviations), * $p < 0.05$, ** $p < 0.01$, *** $p < 0.001$. TTT vs Control or Sham, Tukey's multiple comparison test.

Abbreviations: TTT, tibial cortex transverse transport; DFU, diabetic foot ulcer.

Discussion

Peripheral arterial disease plays a vital role in the pathogenesis of DFU, leading to arterial occlusion, tissue ischemia, and eventually ulceration. We and other groups previously reported that TTT facilitates healing and limb salvage in patients with severe DFU, with vigorous neovascularization and increased perfusion at the foot after TTT.^{6,49,50} However, the exact role of neovascularization in DFU treatment using TTT remains unclear because we did not assess the arterial status in control patients. Furthermore, to our knowledge, no animal model of severe DFU treated using TTT that could be used to investigate the underlying mechanism has been examined. In this study, we established a rat model of severe DFU treated using TTT that is analogous to clinical TTT surgery and found that HIF-1 α -mediated angiogenesis plays an essential role in the treatment.

Transverse distraction of the tibial bone (a rectangular bone fragment) was first described by Ilizarov in canines.⁹ Using this animal model, he found that distraction osteogenesis was accompanied by angiogenesis. Also using a canine model of transverse tibial distraction, Matsuyama et al further reported that the average vessel volume ratio in the distraction area was more than three times higher than that in the intact contralateral tibiae.¹⁷ However, both studies focused on localized effect of this technique and suggested its application for bone thickening or treatment of bone defect.^{9,51}

Speculating that tibial cortex transverse distraction may be accompanied by distal angiogenesis, we developed TTT surgery and evaluated its effect in patients with severe and recalcitrant DFU.^{6,21} We found that TTT facilitated healing and limb salvage compared to conventional treatments including arterial reconstruction and flap transplants (ulcer healing rate: 96% vs 72%, $p < 0.001$; limb salvage rate: 97.1% vs 77.4%, $p < 0.001$).⁶ The positive effects were later confirmed by findings of other groups⁴⁹ and a guideline of treatment of severe DFU using TTT were developed.⁵⁰ Furthermore, we found notable neovascularization and increased perfusion in the foot after TTT.^{6,21} However, the underlying mechanism of TTT treatment is not fully understood and an animal model that simultaneously captures the features of TTT and severe DFU need to be established for mechanism studies.

Yang et al established a TTT model in rats that is easier to handle and more cost-effective than dogs, although the surgical procedure is more technically demanding because of the smaller size of the rat tibia.¹⁹ They examined the effect of TTT on acute traumatic foot wounds and reported accelerated wound healing.¹⁹ However, a simple acute traumatic foot wound without comorbid diseases, such as diabetes and/or lower limb ischemia, can generally heal evenly and

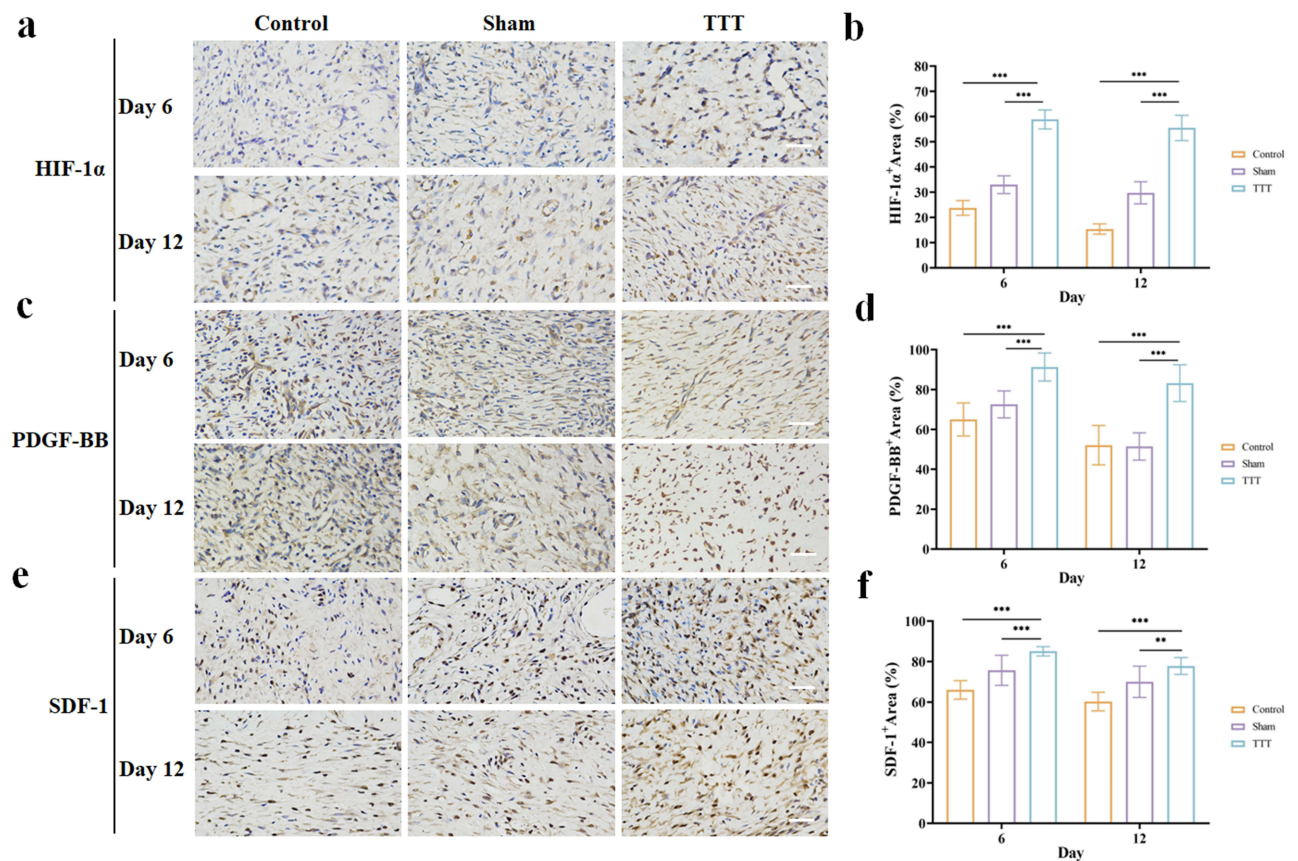


Figure 10 Elevated activity of HIF-1 α , PDGF-BB, SDF-1, and VEGF in diabetic wound after TTT. (a) Representative immunohistochemistry images of HIF-1 α expression in the three groups at day 6 and 12, respectively. (b) Quantitative analysis showed higher expression of HIF-1 α in the TTT group than the other groups. (c) Representative immunohistochemistry images of PDGF-BB expression in the three groups at day 6 and 12, respectively. (d) Quantitative analysis displayed higher expression of PDGF-BB in the TTT group than that of the other groups. (e) Representative immunohistochemistry images of SDF-1 expression in the three groups at day 6 and 12, respectively. (f) Quantitative analysis demonstrated higher expression of SDF-1 expression in the TTT group than the other groups. Scale bar 100 μ m, 100 \times magnification. Data were presented as means (standard deviations), ** $p < 0.01$, *** $p < 0.001$. TTT vs Control or Sham, Tukey's multiple comparison test.

Abbreviations: TTT, tibial cortex transverse transport; DFU, diabetic foot ulcer.

relatively quickly using traditional treatments including debridement and wound care. Using a similar rat model of TTT, another study tried to examine the effect of TTT on DFU and reported positive results.²⁰ However, the skin defect created was relatively small (4 mm \times 5 mm) and hindlimb ischemia was not induced simultaneously.²⁰ Thus, this model mimicked only mild DFU. According to the clinical guideline of TTT treatment, this technique should be applied to severe DFU rather than acute traumatic foot wound or mild DFU considering cost-effectiveness of TTT.⁵⁰ Thus, the findings of previous studies may not be generalizable to severe DFU. In this study, we established a rat model of severe DFU treated using TTT. The severity (area [20 mm long and 10 mm wide] and depth [full-thickness skin loss with tendon exposure]) of the DFU created was higher than that in previous studies,^{19,52} moreover, hindlimb ischemia was induced by ligation of the femoral artery.⁵² Thus, we believe that our findings from this model is more likely to generalize to the clinical settings in which severe DFU is treated using TTT.

One essential condition for distraction osteogenesis is stable fixation of bone fragments with an external apparatus.^{9,10} Other factors affecting stability of the osteotomized tibia include osteotomy site and size. In Ilizarov's canine study, the corticotomy was as large as the middle one-third of the canine tibia and a ring external fixator was used. Similarly, Matsuyama et al adopted a large corticotomy (40 mm long and 10 mm wide) in dogs and used a semicircular external fixator.¹¹ Although the ring distraction assembly provided strong stability to the osteotomized tibia, it was somewhat cumbersome for the animals. In our previous study of DFU patients treated using TTT, we performed a relatively small corticotomy (5 cm long and 1.5 cm wide) in the proximal tibia that comprises only approximately one-fifth of the tibial circumference, minimizing the risk of instability and allowing us to use a unilateral external fixator.⁵² Although Yang

et al also adopted a unilateral external fixator in their study, they still performed a corticotomy (a size of 10 mm × 5 mm) at the middle one-third of the tibia, which may have led to the tibial fracture at the osteotomized site as evidenced on radiographs.¹⁹ To mimic our clinical TTT protocol and avoid potential tibial fracture, we performed a corticotomy with comparable size (10 mm × 5 mm) at the proximal tibia in this study. This site was selected because the circumference of the proximal tibia is larger than the middle and distal tibia and thus reduces the risk of fracture at the surgical site. As confirmed in X-rays, no tibial fracture was found in any animals undergoing corticotomy.

Distraction rate is a vital factor influencing the effect of distraction osteogenesis. Ilizarov proposed a distraction rate of 1 mm/day, which was supported by other animal and clinical studies.^{53,54} This distraction rate was also set in prior canine models of transverse tibial bone distraction and clinical studies of TTT.^{9,17} While studies of longitudinal distraction osteogenesis in the rat tibia also set a distraction speed of 0.25 mm/12 hours,⁵⁵ previous rat studies of TTT adopted a distraction rate of 0.25 mm/12 hours and an outward distraction period of 3 days, leading to a maximum displacement of 1.5 mm for the corticotomized fragment.^{20,56} Furthermore, prior work using rat model of longitudinal distraction osteogenesis showed that a distraction rate of 0.25 mm/day produced excellent quality regenerated bone as those of 0.5 mm/day. Considering that the calf diameter of rats is relatively small and a large transverse displacement of the corticotomized fragment may lead to excessive stress on local soft tissues and skin and eventually skin necrosis, we used a lower speed (0.1 mm/12 hours) but a longer distraction period (6 days of medial transport) in this study, resulting in a maximum transport of 1.2 mm. The positive results of ulcer healing and absence of skin necrosis at the surgical site after surgery indicates that a protocol of TTT in rats with a slower distraction rate while longer distraction phase is feasible.

The purpose of using TTT in the treatment of DFU is to stimulate anagenesis in the foot rather than bone formation in the tibia. Thus, we did not set a latency phase between medial and lateral distraction in the clinical studies.^{6,21} However, previous rat model of TTT set a latency phase of 3 days between the outward and inward transport,¹⁹ which was not analogous to the clinical protocol of TTT and lead to a prolonged period with the attachment of an external fixation. In this study, we did not set a latency phase between the medial and lateral transport or before the medial transport, consistent with the clinical protocol of TTT; rather, we set a longer distraction phase (12 days in total) and attained good angiogenic effect of TTT.

In a previous rat study on the treatment of mild DFU using TTT, quantitative analysis of wound healing and dermis thickness was not performed, thus the effect of TTT on DFU healing was not fully clear.²⁰ In another rat study on the treatment of traumatic foot wound using TTT, it was found that the wound healing rate and blood flow was higher in the TTT group than the control and sham group at day 15 (after 6 days of transport) but not at day 9 (after 3 days of transport).¹⁹ The authors maintained that TTT may mainly affect the late stage of wound healing.¹⁹ However, in our current study, we found higher dermis thickness and collagen content in the TTT group than the sham or control group at both day 6 and 12, respectively, demonstrating that TTT also has an effect on severe DFU healing at an early stage (after 6 days of distraction) which is consistent with the finding of the clinical studies.^{6,21} One possible reason for such a discrepancy was that the length of the distraction phase in the current study (12 days in total) is longer than the previous studies (6 days in total).^{19,20} Another interesting finding is that some hair follicle-like tissue was found in the TTT group at day 6 and 12, respectively, as shown by histology, which was hardly noted in the other groups. This indicate that TTT may mediate skin and appendage regeneration. Nevertheless, this needs to be tested in further study.

In our previous clinical study of recalcitrant DFU treated using TTT, we found obvious neovascularization and increased perfusion in the feet after TTT, suggesting that the effect of this surgery may be attributed to neovascularization and increased perfusion.⁶ However, tibial fractures also reportedly increase the blood flow to the foot skin;⁵⁷ and we did not evaluate a group of patients who underwent only tibial corticotomy because we were concern that tibial corticotomy alone may have no effect, if any. Thus, we cannot exclude the possibility that tibial corticotomy alone could increase foot perfusion facilitate severe DFU healing. In this study, we set up a sham group (corticotomy without following cortex transport) and compared it with the TTT and control group. Although the perfusion in the sham group tended to be higher than the control group, the difference did not achieve significance, consistent with the changes in the levels of angiogenic factors (VEGF, PDGF-BB, and SDF-1) as demonstrated by ELISA and immunohistochemistry. These results indicates that a corticotomy alone may not be sufficient for treatment of severe DFU. Furthermore, our finding of increased angiogenesis and perfusion and better ulcer healing at the feet in the TTT versus the sham group demonstrates that the effect of TTT is attributable to transverse cortex distraction.

Tissue hypoxia, a critical driving force for angiogenesis, is controlled by the HIF-1 α pathway. Activation of HIF-1 α induces the expression of angiogenic factors such as VEGF, PDGF-BB, and SDF-1.^{58,59} Studies of longitudinal distraction osteogenesis detected elevated expression of HIF-1 α in the distracted gap and in serum.^{32,33} Moreover, expression of VEGF, PDGF-BB, and SDF-1 is increased in the distraction site and serum during longitudinal distraction osteogenesis.^{32,34–38} Thus, HIF-1 α is a key molecule that couples angiogenesis to bone formation in distraction osteogenesis. On the other hand, hyperglycemia affects HIF-1 α stability and activation in the circulation and tissue biopsies in patients with DFUs.²³ Correspondingly, the expression of HIF-1 α target genes essential for wound healing, such as VEGF, PDGF-BB, and SDF-1, were downregulated in patients or mice with DFUs.^{24–28} Moreover, HIF-1 α stabilization or supplementation of VEGF, PDGF-BB and SDF-1 is sufficient to promote wound healing in a diabetic environment.^{23,29,30} However, no studies have examined the changes in HIF-1 α expression and its role in DFU after TTT treatment. In this study, we found increased concentration of HIF-1 α , VEGF, PDGF-BB, and SDF-1 in peripheral blood in the TTT group which are consistent with the immunohistology, CTA, and perfusion analysis that illustrated angiogenesis at the diabetic wound. Hence, our results are in line with previous studies of longitudinal distraction osteogenesis^{32,34–38} and may generate a model of “HIF-1 α formation in response to hypoxia during TTT stimulates angiogenesis and promotes DFU healing” for the mechanism of TTT treatment (Figure 11).

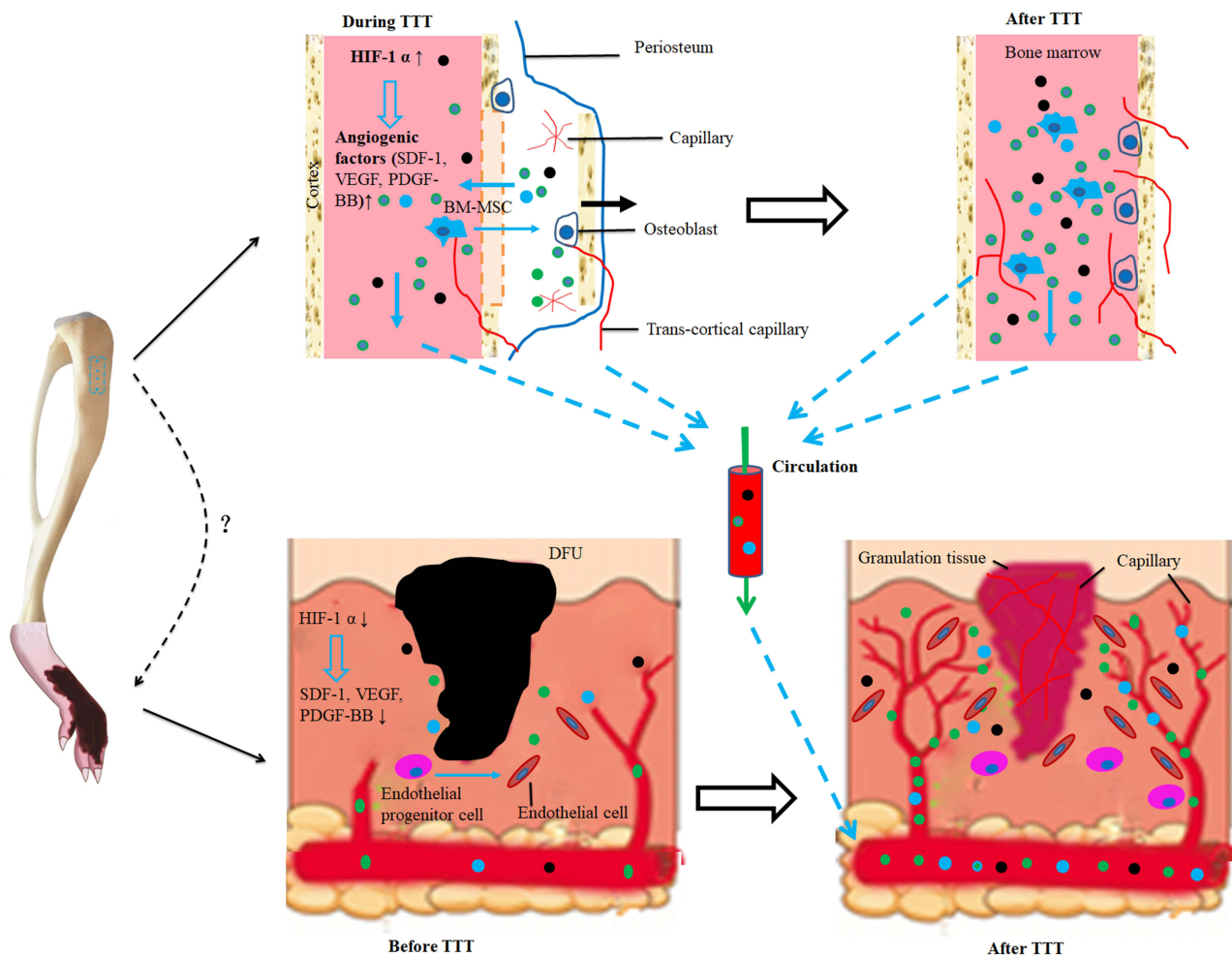


Figure 11 Schematic of the potential mechanism of DFU treatment using TTT. In response to transverse distraction, osteogenic activity (differentiation of bone marrow mesenchymal stem cells into osteoblasts) is elevated, leading to a localized hypoxic microenvironment. This triggers the expression of HIF-1 α which in turn induces formation of multiple angiogenic factors such as VEGF, PDGF-BB, and SDF-1. These downstream factors promote angiogenesis and neovascularization to supply oxygen, nutrients, and critical signals for the newly formed bone and also carry away the metabolic wastes. Simultaneously, HIF-1 α , VEGF, PDGF-BB, and SDF-1 travel through the trans-cortical capillaries into peripheral circulation and eventually reach the site of DFU, which is in hypoxic status and with low levels of HIF-1 α , VEGF, PDGF-BB, and SDF-1. Similar to their effect in the bone transport site, these factors induce angiogenesis (differentiation of endothelial progenitor cells into endothelial cells) and neovascularization at the wound and improves the hypoxic status, ultimately resulting in ulcer healing.

Abbreviations: BM-MSC, bone marrow mesenchymal stem cell; DFU, diabetic foot ulcer; TTT, tibial cortex transverse transport.

This study had several limitations. First, rats, the animal we used, cannot reproduce the complete pathogenesis of DFU in human which is a result of a multifaceted process. Although the current rat model mimics the severity (wound size and depth) and ischemia (ligation of femoral artery) of DFU, it did not simulate other factors of the disease such as prolonged inflammation, poor nutrition, infections, neuropathy, and aging. Nevertheless, this is a common challenge faced by all animal studies on DFU. Second, we did not use mice, the most commonly used animal for DFU model. Using mice has the advantages such as the availability of various mouse-specific reagents and the feasibility of transgenic manipulation. However, the tibial diameter of a mouse is relatively small and it is technically difficult to create a partial tibial corticotomy and implant an external fixator for transverse distraction, as found in our preliminary study (data not shown). Nevertheless, using rats allow us to create larger and deeper DFUs than those in mice, better simulating the clinic setting in which severe DFUs are treated using TTT.

Finally, we did not examine the role of a single downstream signaling pathway of HIF-1 α , such as VEGF/VEGFR or SDF-1/CXCR4, in the treatment of severe DFU using TTT. Numerous previous animal studies have shown that topical application of a single angiogenic factor such as recombinant VEGF (rh-VEGF) or PDGF-BB (Regranex) improves DFU healing.³¹ However, translation of this method to the clinic has met with little success, mainly because of no effect of the drugs and/or adverse side effects.³¹ Thus, we believe that it is multiple, rather than a single angiogenic factor(s) induced by TTT that mediates angiogenesis and neovascularization and promotes DFU healing. Even so, the molecular mechanisms involving HIF-1 α -induced angiogenesis warrant more future investigation.

In conclusion, we established a rat model of severe DFU treated using TTT and found that TTT facilitated ulcer healing. The underlying mechanism is that hypoxic stress in response to mechanical force and abundant bone formation in the distraction gap induces the formation of HIF-1 α , which in turn stimulates the secretion of multiple angiogenic factors. These factors travel through the peripheral circulation to the foot wound, resulting in angiogenesis, neovascularization, and ultimately DFU healing. The results of the study support TTT as an effective treatment for patients with severe DFUs. Nevertheless, this needs to be confirmed in randomized clinical trials and the molecular mechanism requires further future study.

Author Contributions

All authors contributed to data analysis, drafting or revising the article, have agreed on the journal to which the article will be submitted, gave final approval of the version to be published, and agree to be accountable for all aspects of the work.

Funding

This study was supported by grants from National Natural Science Foundation of China (82060406, 82360429, 82260448), Natural Science Foundation of Guangxi (2022JJA141126), Guangxi Key Research and Development Plan (2021AB11027), Advanced Innovation Teams and Xinghu Scholars Program of Guangxi Medical University, China Postdoctoral Science Foundation (2019M650235), Key R&D Project of Qingxiu District, Nanning, Guangxi (2021003), Clinical research climbing plan of the First Affiliated Hospital of Guangxi Medical University (YYZS2020010).

Disclosure

The authors declare that the research was conducted in the absence of any commercial or financial relationships that could be construed as a potential conflict of interest.

References

1. Sun H, Saeedi P, Karuranga S, et al. IDF Diabetes Atlas: global, regional and country-level diabetes prevalence estimates for 2021 and projections for 2045. *Diabet Res Clin Pract.* 2022;183:109119. doi:10.1016/j.diabres.2021.109119
2. Senneville É, Albalawi Z, van Asten SA, et al. IWGDF/IDSA guidelines on the diagnosis and treatment of diabetes-related foot infections (IWGDF/IDSA 2023). *Clin Infect Dis off Publ Infect Dis Soc Am.* 2023;ciad527. doi:10.1093/cid/ciad527
3. Boulton AJ, Vileikyte L, Ragnarson-Tennvall G, Apelqvist J. The global burden of diabetic foot disease. *Lancet Lond Engl.* 2005;366:9498. doi:10.1016/S0140-6736(05)67698-2
4. M K, F M, Ajm B, S E. Etiology, epidemiology, and disparities in the burden of diabetic foot ulcers. *Diabetes Care.* 2023;46(1). doi:10.2337/dci22-0043
5. van Netten JJ, Bus SA, Apelqvist J, et al. Definitions and criteria for diabetes-related foot disease (IWGDF 2023 update). *Diabetes Metab Res Rev.* 2023:e3654. doi:10.1002/dmrr.3654

6. Chen Y, Kuang X, Zhou J, et al. Proximal tibial cortex transverse distraction facilitating healing and limb salvage in severe and recalcitrant diabetic foot ulcers. *Clin Orthop*. 2020;478(4):836–851.
7. Oda T, Niikura T, Fukui T, et al. Transcutaneous CO₂ application accelerates fracture repair in streptozotocin-induced type I diabetic rats. *BMJ Open Diabetes Res Care*. 2020;8(2):e001129. doi:10.1136/bmjdr-2019-001129
8. Edmonds M, Manu C, Vas P. The current burden of diabetic foot disease. *J Clin Orthop Trauma*. 2021;17. doi:10.1016/j.jcot.2021.01.017
9. Ilizarov GA. The tension-stress effect on the genesis and growth of tissues. Part I. The influence of stability of fixation and soft-tissue preservation. *Clin Orthop*. 1989;238:249–281.
10. Ilizarov GA. The tension-stress effect on the genesis and growth of tissues: part II. The influence of the rate and frequency of distraction. *Clin Orthop*. 1989;239:263–285. doi:10.1097/00003086-198902000-00029
11. Ilizarov GA, Ledyayev VI. The replacement of long tubular bone defects by lengthening distraction osteotomy of one of the fragments. *Clin Orthop*. 1992;280:7–10.
12. Ilizarov GA. Clinical application of the tension-stress effect for limb lengthening. *Clin Orthop*. 1990;250:8–26.
13. Minematsu K, Tsuchiya H, Taki J, Tomita K. Blood flow measurement during distraction osteogenesis. *Clin Orthop*. 1998;347:229–235.
14. Gubin AV, Borzunov DY, Marchenkova LO, Malkova TA, Smirnova IL. Contribution of G.A. Ilizarov to bone reconstruction: historical achievements and state of the art. *Strateg Trauma Limb Reconstr*. 2016;11(3):145–152. doi:10.1007/s11751-016-0261-7
15. Kuo KN, Qureshi A, Bush-Joseph CA, Templeton A. Ilizarov distraction histogenesis to reconstruct massive posttraumatic osteoarticular defects: a case report. *J Bone Joint Surg Am*. 2003;85(6):1125–1128. doi:10.2106/00004623-200306000-00025
16. Aston JW, Williams SA, Allard RN, Sawamura S, Carollo JJ. A new canine cruciate ligament formed through distraction histogenesis. Report of a pilot study. *Clin Orthop*. 1992;280:30–36.
17. Matsuyama J, Ohnishi I, Kageyama T, Oshida H, Suwabe T, Nakamura K. Osteogenesis and angiogenesis in regenerating bone during transverse distraction: quantitative evaluation using a canine model. *Clin Orthop*. 2005;433(243–250). doi:10.1097/01.blo.0000150562.24256.a4
18. Ohashi S, Ohnishi I, Kageyama T, Imai K, Nakamura K. Distraction osteogenesis promotes angiogenesis in the surrounding muscles. *Clin Orthop*. 2007;454:223–229. doi:10.1097/01.blo.0000238795.82466.74
19. Yang Y, Li Y, Pan Q, et al. Tibial cortex transverse transport accelerates wound healing via enhanced angiogenesis and immunomodulation. *Bone Jt Res*. 2022;11(4):189–199. doi:10.1302/2046-3758.114.BJR-2021-0364.R1
20. Ou S, Wu X, Yang Y, et al. Tibial cortex transverse transport potentiates diabetic wound healing via activation of SDF-1/CXCR4 signaling. *PeerJ*. 2023;11:e15894. doi:10.7717/peerj.15894
21. Chen Y, Ding X, Zhu Y, et al. Effect of tibial cortex transverse transport in patients with recalcitrant diabetic foot ulcers: a prospective multicenter cohort study. *J Orthop Transl*. 2022;36:194–204.
22. Liu G, Li S, Kuang X, et al. The emerging role of tibial cortex transverse transport in the treatment of chronic limb ischemic diseases. *J Orthop Transl*. 2020;25:17–24.
23. Botusan IR, Sunkari VG, Savu O, et al. Stabilization of HIF-1 α is critical to improve wound healing in diabetic mice. *Proc Natl Acad Sci U S A*. 2008;105(49):19426–19431. doi:10.1073/pnas.0805230105
24. Chen Z, Fu S, Wu Z, et al. Relationship between plasma angiogenic growth factors and diabetic foot ulcers. *Clin Chim Acta Int J Clin Chem*. 2018;482:95–100. doi:10.1016/j.cca.2018.03.035
25. M S, H Q, J Y, et al. Effect of negative-pressure wound therapy on the circulating number of peripheral endothelial progenitor cells in diabetic patients with mild to moderate degrees of ischaemic foot ulcer. *Vascular*. 2019;27(4). doi:10.1177/1708538119836360
26. Wieman TJ, Smiell JM, Su Y. Efficacy and safety of a topical gel formulation of recombinant human platelet-derived growth factor-BB (becaplermin) in patients with chronic neuropathic diabetic ulcers. A Phase III randomized placebo-controlled double-blind study. *Diabetes Care*. 1998;21(5):822–827. doi:10.2337/diacare.21.5.822
27. Li G, Ko CN, Li D, et al. A small molecule HIF-1 α stabilizer that accelerates diabetic wound healing. *Nat Commun*. 2021;12(1):3363. doi:10.1038/s41467-021-23448-7
28. Zubair M, Ahmad J. Role of growth factors and cytokines in diabetic foot ulcer healing: a detailed review. *Rev Endocr Metab Disord*. 2019;20(2):207–217. doi:10.1007/s11154-019-09492-1
29. Saaristo A, Tammela T, Farkkilä A, et al. Vascular endothelial growth factor-C accelerates diabetic wound healing. *Am J Pathol*. 2006;169(3):1080–1087. doi:10.2353/ajpath.2006.051251
30. Patel S, Srivastava S, Singh MR, Singh D. Mechanistic insight into diabetic wounds: pathogenesis, molecular targets and treatment strategies to pace wound healing. *Biomed Pharmacother Biomedecine Pharmacother*. 2019;112:108615. doi:10.1016/j.biopha.2019.108615
31. Okonkwo UA, DiPietro LA. Diabetes and wound angiogenesis. *Int J Mol Sci*. 2017;18(7):1419. doi:10.3390/ijms18071419
32. Mori S, Akagi M, Kikuyama A, Yasuda Y, Hamanishi C. Axial shortening during distraction osteogenesis leads to enhanced bone formation in a rabbit model through the HIF-1 α /vascular endothelial growth factor system. *J Orthop Res off Publ Orthop Res Soc*. 2006;24(4):653–663. doi:10.1002/jor.20076
33. Xu J, Sun Y, Wu T, et al. Enhancement of bone regeneration with the accordion technique via HIF-1 α /VEGF activation in a rat distraction osteogenesis model. *J Tissue Eng Regen Med*. 2018;12(2):e1268–e1276. doi:10.1002/term.2534
34. Cao J, Wang L. A comparison of stromal cell-derived factor-1 expression during distraction osteogenesis and bone fracture in the mandible. *J Craniofac Surg*. 2013;24(3):805–808. doi:10.1097/SCS.0b013e31828f1ca7
35. Fujio M, Yamamoto A, Ando Y, et al. Stromal cell-derived factor-1 enhances distraction osteogenesis-mediated skeletal tissue regeneration through the recruitment of endothelial precursors. *Bone*. 2011;49(4):693–700. doi:10.1016/j.bone.2011.06.024
36. Weiss S, Zimmermann G, Baumgart R, Kasten P, Bidlingmaier M, Henle P. Systemic regulation of angiogenesis and matrix degradation in bone regeneration—distraction osteogenesis compared to rigid fracture healing. *Bone*. 2005;37(6):781–790. doi:10.1016/j.bone.2005.06.014
37. Shen Z, Chen Z, Li Z, et al. Total Flavonoids of rhizoma drynariae enhances angiogenic-osteogenic coupling during distraction osteogenesis by promoting type H vessel formation through PDGF-BB/PDGFR- β Instead of HIF-1 α /VEGF axis. *Front Pharmacol*. 2020;11:503524. doi:10.3389/fphar.2020.503524
38. Xu J, Chen Y, Liu Y, et al. Effect of SDF-1/Cxcr4 signaling antagonist AMD3100 on bone mineralization in distraction osteogenesis. *Calcif Tissue Int*. 2017;100(6):641–652. doi:10.1007/s00223-017-0249-4

39. Sanapalli BKR, Yele V, Singh MK, Thaggikuppe Krishnamurthy P, Karri VVSR. Preclinical models of diabetic wound healing: a critical review. *Biomed Pharmacother Biomed Pharmacother*. 2021;142:111946. doi:10.1016/j.biopha.2021.111946
40. Cheng KY, Lin ZH, Cheng YP, et al. Wound healing in streptozotocin-induced diabetic rats using atmospheric-pressure argon plasma jet. *Sci Rep*. 2018;8(1):12214. doi:10.1038/s41598-018-30597-1
41. Guo SC, Tao SC, Yin WJ, Qi X, Yuan T, Zhang CQ. Exosomes derived from platelet-rich plasma promote the re-epithelization of chronic cutaneous wounds via activation of YAP in a diabetic rat model. *Theranostics*. 2017;7(1):81–96. doi:10.7150/thno.16803
42. Calkosiński I, Gostomska-Pampuch K, Majda J, et al. The influence of α -tocopherol on serum biochemical markers during experimentally induced pleuritis in rats exposed to dioxin. *Inflammation*. 2017;40(3):913–926. doi:10.1007/s10753-017-0536-2
43. Sun F, Lei Y, You J, et al. Adiponectin modulates ventral tegmental area dopamine neuron activity and anxiety-related behavior through AdipoR1. *Mol Psychiatry*. 2019;24(1):126–144. doi:10.1038/s41380-018-0102-9
44. Ricles LM, Hsieh PL, Dana N, et al. Therapeutic assessment of mesenchymal stem cells delivered within a PEGylated fibrin gel following an ischemic injury. *Biomaterials*. 2016;102:9–19. doi:10.1016/j.biomaterials.2016.06.011
45. Monteforte AJ, Lam B, Das S, et al. Glypican-1 nanoliposomes for potentiating growth factor activity in therapeutic angiogenesis. *Biomaterials*. 2016;94:45–56. doi:10.1016/j.biomaterials.2016.03.048
46. Nie X, Kuang X, Liu G, et al. Tibial cortex transverse transport facilitating healing in patients with recalcitrant non-diabetic leg ulcers. *J Orthop Transl*. 2021;27:1–7.
47. Chen Y, Huang YC, Yan CH, et al. Abnormal subchondral bone remodeling and its association with articular cartilage degradation in knees of type 2 diabetes patients. *Bone Res*. 2017;5:17034. doi:10.1038/boneres.2017.34
48. Chen Y, Hu Y, Yu YE, et al. Subchondral trabecular rod loss and plate thickening in the development of osteoarthritis. *J Bone Miner Res off J Am Soc Bone Miner Res*. 2018;33(2):316–327. doi:10.1002/jbmr.3313
49. Yuan Y, Ding X, Jing Z, et al. Modified tibial transverse transport technique for the treatment of ischemic diabetic foot ulcer in patients with type 2 diabetes. *J Orthop Transl*. 2021;29:100–105. doi:10.1016/j.jot.2021.04.006
50. Hua Q, Zhang Y, Wan C, et al. Chinese Association of Orthopaedic Surgeons (CAOS) clinical guideline for the treatment of diabetic foot ulcers using tibial cortex transverse transport technique (version 2020). *J Orthop Transl*. 2020;25:11–16. doi:10.1016/j.jot.2020.05.003
51. Shiha AE, Khalifa ARH, Assaghir YM, Kenawey MO. Medial transport of the fibula using the Ilizarov device for reconstruction of a massive defect of the tibia in two children. *J Bone Joint Surg Br*. 2008;90(12):1627–1630. doi:10.1302/0301-620X.90B12.21378
52. Qu L, Wang A, Tang F. The therapy of transverse tibial bone transport and vessel regeneration operation on thromboangitis obliterans. *Zhonghua Yi Xue Za Zhi*. 2001;81(10):622–624.
53. Li G, Simpson AH, Kenwright J, Triffitt JT. Effect of lengthening rate on angiogenesis during distraction osteogenesis. *J Orthop Res off Publ Orthop Res Soc*. 1999;17(3):362–367. doi:10.1002/jor.1100170310
54. Simpson AHRW, Keenan G, Nayagan S, Atkins RM, Marsh D, Clement ND. Low-intensity pulsed ultrasound does not influence bone healing by distraction osteogenesis: a multicentre double-blind randomised control trial. *Bone Jt J*. 2017;99(4):494–502. doi:10.1302/0301-620X.99B4.BJJ-2016-0559.R1
55. Shen J, Sun Y, Liu X, et al. EGFL6 regulates angiogenesis and osteogenesis in distraction osteogenesis via Wnt/ β -catenin signaling. *Stem Cell Res Ther*. 2021;12(1):415. doi:10.1186/s13287-021-02487-3
56. Yang Y, Andersson P, Hosaka K, et al. The PDGF-BB-SOX7 axis-modulated IL-33 in pericytes and stromal cells promotes metastasis through tumour-associated macrophages. *Nat Commun*. 2016;7:11385. doi:10.1038/ncomms11385
57. Kellerová E, Delius W, Olerud S, Ström G. Changes in the muscle and skin blood flow following lower leg fracture in man. *Acta Orthop Scand*. 1970;41(3):249–260. doi:10.3109/17453677008991512
58. Zimna A, Kurpisz M. Hypoxia-inducible factor-1 in physiological and pathophysiological angiogenesis: applications and therapies. *BioMed Res Int*. 2015;2015:549412. doi:10.1155/2015/549412
59. Fang J, Ji Q, Gao S, et al. PDGF-BB is involved in HIF-1 α /CXCR4/CXCR7 axis promoting capillarization of hepatic sinusoidal endothelial cells. *Heliyon*. 2023;9(1):e12715. doi:10.1016/j.heliyon.2022.e12715