

Blistering distal dactylitis

Li-wen Zhang MD, Wen-ju Wang MD, Tao Chen MD PhD

■ Cite as: *CMAJ* 2022 February 7;194:E167. doi: 10.1503/cmaj.210685

A 4-year-old girl presented to our dermatology clinic with erythema and bullae on the right foot for 4 days. She did not complain of pain or pruritis. She had no history of recent upper respiratory tract infection, trauma or medication use. Physical examination showed that the patient was afebrile and appeared well; she did not have any superficial lymphadenopathy. We observed multiple tense fluid-filled bullae with edematous erythema over the right first metatarsophalangeal joint and sole of the foot (Figure 1). Her white blood cell count and neutrophil percentage were normal. We diagnosed blistering distal dactylitis and treated the patient with puncture of the bullae, topical 5% povidone-iodine solution and oral amoxicillin. Bacterial culture from the bullous fluid later grew group A β -hemolytic *Streptococcus*. The lesions resolved completely in 10 days.

Blistering distal dactylitis is a superficial bacterial infection, typically caused by group A β -hemolytic *Streptococcus* or *Staphylococcus aureus*. It usually affects children aged 2–16 years,¹ but can occur in infants and adults. Blistering distal dactylitis usually presents as tense bullae on an erythematous base over the palmar aspect of the finger or toe, which may extend dorsally to involve lateral nail folds and can also affect the hands and feet.²

Patients are systemically well, afebrile and do not have lymphadenopathy. The lesions usually develop over a few days, and are not painful, pruritic or fragile, unlike bullous impetigo. They are usually unilocular blisters, unlike herpetic whitlow.³ Other differential diagnoses include contact dermatitis, post-traumatic blisters, burns, erythema multiforme, insect bites and stings, and epidermolysis bullosa.⁴ A Gram stain and bacterial culture of the bullae fluid are diagnostic.

Drainage with a sterile needle, leaving the blister wall intact, is suggested for tense bullae. Wet dressings with a topical antibiotic solution can be used. Patients should be treated with systemic antibiotic therapy for both group A β -hemolytic *Streptococcus* and *S. Aureus*. Patients have been treated successfully with amoxicillin, cephalexin or trimethoprim-sulfamethoxazole, but also with amoxicillin-clavulanate in cases of β -lactamase resistance.^{1,2,4,5} Recurrence is not usually reported.

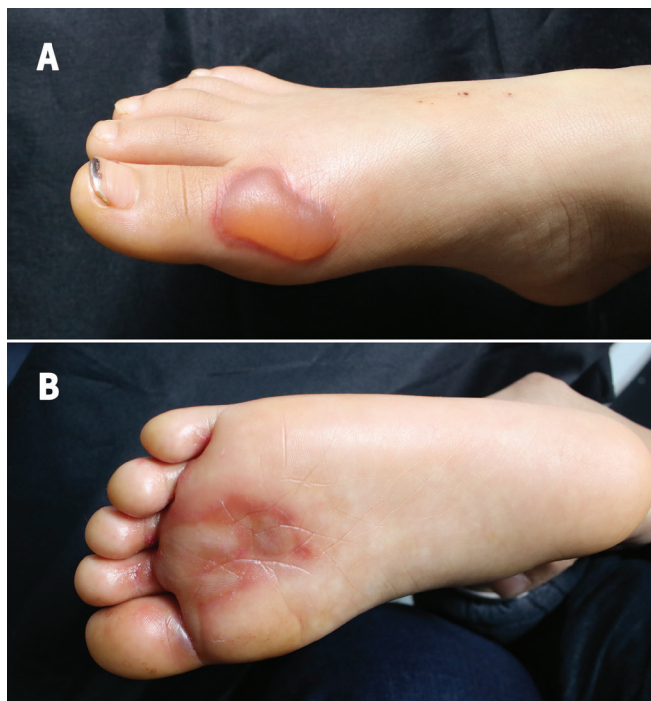


Figure 1: Tense, fluid-filled bullae with edematous erythema (A) overlying the right first metatarsophalangeal joint and (B) on the sole of the foot of a 4-year old girl with blistering distal dactylitis.

References

1. Jung C, Amhis J, Levy C, et al. Group A streptococcal paronychia and blistering distal dactylitis in children: diagnostic accuracy of a rapid diagnostic test and efficacy of antibiotic treatment. *J Pediatric Infect Dis Soc* 2020;9:756-9.
2. Veraldi S, Schianchi R, Nazzaro G, et al. Seven cases of blistering dactylitis. *Acta Derm Venereol* 2020;100:adv00196.
3. Ney AC, English JC III, Greer KE. Coexistent infections on a child's distal phalanx: blistering dactylitis and herpetic whitlow. *Cutis* 2002;69:46-8.
4. Scheinfeld NS. Is blistering distal dactylitis a variant of bullous impetigo? *Clin Exp Dermatol* 2007;32:314-6.
5. Kowtoniuk R, Bednarek R, Maroon M. Blistering distal dactylitis. *JAMA Dermatol* 2018;154:1480.

Competing interests: None declared.

This article has been peer reviewed.

The authors have obtained parental consent.

Affiliation: Department of Dermatovenereology, Chengdu Second People's Hospital, Chengdu, Sichuan, China.

Content licence: This is an Open Access article distributed in accordance with the terms of the Creative Commons Attribution (CC BY-NC-ND 4.0) licence, which permits use, distribution and reproduction in any medium, provided that the original publication is properly cited, the use is noncommercial (i.e., research or educational use), and no modifications or adaptations are made. See: <https://creativecommons.org/licenses/by-nc-nd/4.0/>

Correspondence to: Tao Chen, 13980427003@163.com