

## Cystic Hygroma in an Adult; a Case Report

Veeraraghavan G<sup>1</sup>, Denny C<sup>2</sup> and Lingappa A<sup>3</sup>

<sup>1</sup> Department of Oral Medicine and Radiology, Manipal college of dental sciences, India, <sup>2</sup> Department of Oral Medicine and Radiology, Zliten Dental College, Al-Margeub University, Libya and <sup>3</sup> Department of Oral medicine and Radiology, Bapuji Dental College & Hospital, Davangere, India.

**Abstract;** Lymphangioma is a benign infiltrative malformation of the lymphatic channels. Cystic lymphangioma or cystic hygroma is a subtype of lymphangioma which exhibits large macroscopic cystic space histologically. The cause of cystic hygroma is believed to be developmental defect or primary Multilocular cystic malformation of dilated lymphatic channels. Cystic hygroma is a common and distinct entity that is not manifested in the oral cavity but occurs in the neck as a large, deep diffuse swelling. They are usually found in the posterior triangle of the neck. They often cross the midline, reaching axilla and mediastinum. Such localization verifies the complexity and extent of the lymphatic system in the cervical region when compared to other regions of the body. The five main locations where cystic hygroma can occur are, cervical (75-90%), axillary (20%), inguinal, retroperitoneal and thoracic. They usually appear as solitary lesions. They are usually infiltrative, often separating fascial planes and incorporating nerves, muscles, and blood vessels. They are fluctuant, freely mobile, compressible, painless and transilluminate well. The skin overlying the lesion is normal and usually there is no associated lymphadenopathy. Various treatment modalities have been tried. Surgery has been the main form of treatment, but total removal is not possible in all cases because of the extent of the lesion, which sometimes involves vital structures. We report a case of cystic hygroma in a young male patient.

**Key words:** *Cystic hygroma, lymphangioma, lymphatic tissue.*

### Introduction

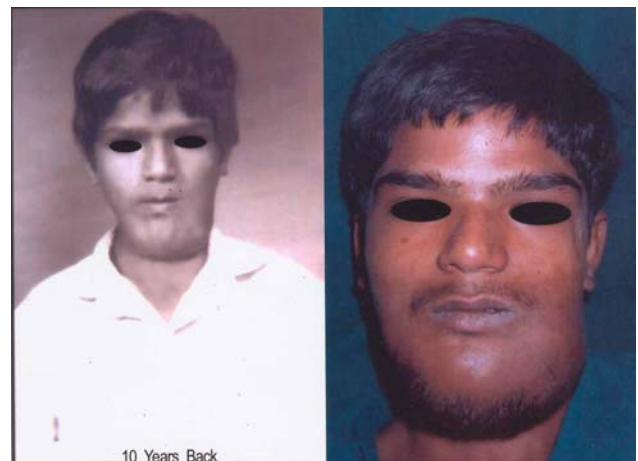Cystic hygroma is an uncommon benign cyst caused by a congenital malformation of the lymphatic vessels. They mainly occur in the head and neck, but may be found anywhere. Sites other than head and neck region include the thoracic wall, the shoulder, intra abdominal region, pharynx and mediastinum [1-5]. These cysts that make up a lymphatic malformation vary in size from a few millimeters to more than several centimeters in diameter [6]. They are often solitary and can accompany chromosomal and Mendelian abnormalities such as Turner syndrome, Down syndrome and trisomy 13 & 18. They occur predominantly in the cervicofacial region in children [1-5].

### Case report

An 18-year-old male came to the department, with a painless swelling in the lower third of face since birth for which the patient got operated when he was one year old. The swelling gradually increased to the present size and it crossed the midline to involve the right side of the face after the surgery. The patient also complained of pus discharge followed by discharge of blood for one month. There were no other associated symptoms.

Extraoral examination showed a solitary swelling in the lower jaw crossing the midline measuring about 12 x 8 cms with multiple sinus openings with blood discharge. Margins were ill-defined and crustations were present on the surface of the lesion. The surface on palpation was lobular, soft to firm in consistency and freely movable. A tender lymph node was palpable in the right submandibular region. Intraorally, a solitary swelling was seen in the left buccal mucosa extending from the left angle of the mouth to the distal of 37, obliterating the vestibule from 41 to 36 and also extending 1cm above occlusal plane. Multiple papular elevations were seen on the buccal mucosa over the fluctuant swelling which was nontender.

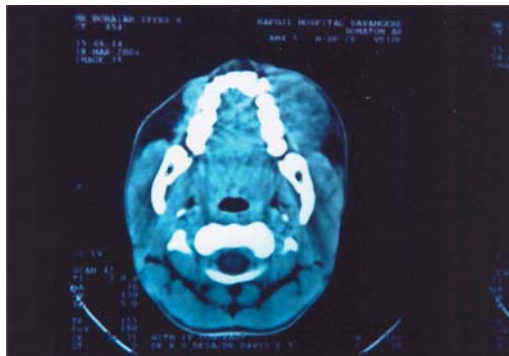
The blood picture was normal except for increased ESR (60/mm 1st hr). Orthopantomograph and lateral cephalogram revealed soft tissue shadow with no bony involvement. Computed tomography showed non homogenous mass of soft tissue density in the buccal aspect with no evidence of bone destruction which gave an impression of benign non-enhancing lesion of soft tissue mass. A provisional diagnosis of haemangioma was made with differential diagnosis of lymphangioma and rhabdomyoma.



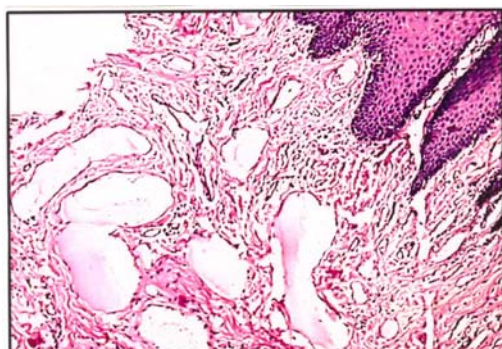
**Figure 1** Extraoral photograph taken 10 years back and at present.

The incisional and excisional biopsy of the swelling intraorally revealed many dilated cavernous lymphatic channels filled with coagulum close to overlying hyperplastic oral epithelium. Extraorally, enumerable dilated vascular lymphatic vessels of varying configuration containing RBC's and pale eosinophilic coagulum were observed. Thin flattened vessels lined by endothelium, scattered inflammatory cells, small lymphoid aggregates and adipose tissue were also evident. Longitudinal and transverse sections of muscle tissue and extravasated RBC's in fibrous stroma were seen throughout the

sections. The lesion was not encapsulated. With the above mentioned features a diagnosis of cystic hygroma was made.



**Figure 2** axial CT section with contrast media showing extension of lesion.



**Figure 3** Photomicrograph revealing many dilated cavernous lymphatic channels filled with eosinophilic coagulum (Haematoxylin and Eosin section Original magnification 40 X)

### Discussion

Cystic hygroma, known as cystic lymphangioma is a benign tumour of the lymphatic tissue [7]. Approximately 65-75% of the tumours are present before the age of 1 and about 90% of the lesions occur prior to the end of the second year of life [8]. Occasionally they may be seen as late as the fourth or sixth decade [9]. The reason these lesions remain dormant for such a period of time is unknown, but it is speculated that local infection may precipitate the growth of a previously unrecognized lesion. Others have implicated specific factors such as infection, tumour or trauma [10]. They are thought to be the result of failure of connection between clusters of blind lymph sacs in the neck and the lymphatic channels normally present during foetal development, so most cases are encountered at birth or in early infancy [11].

Small cystic hygromas usually present with an asymptomatic swelling during development. Enlargement may be rapid secondary to an upper respiratory infection. However, some of those with extensive cervicofacial cystic hygroma may develop symptoms related to compression of airway and pharynx, or more severely, acute respiratory embarrassment and airway obstruction [11]. Adult cystic hygromas are rare, and affect mainly the cervicofacial region. Although patients could be without symptoms, some children develop respiratory, speech and feeding difficulties. Those who had symptoms, had inflammation and infection in neck, exertional dyspnoea, chylothorax, and symptoms related to constrictive pericarditis [4].

Complete surgical excision at an early point in time is the treatment of choice [12-14]. Surgery should be done with care to avoid leaving islands of tissue to act as foci for recurrence [15], indeed a 20% rate of recurrence has been reported [14]. Surgery should be carried out with care to avoid injuring the entangled structures such as hypoglossal, vagus and lingual nerves. The branchial plexus, the sympathetic chain, the carotid sheath contents and lower branches of facial nerves are also important structures to be avoided [12,13]. Facial paralysis, vocal cord paralysis and shoulder weakness are symptoms of neural encroachment but are uncommon [16]. Other complications include sepsis, infection and fistula formation [17]. In very young children, the blood loss associated with a major procedure and the danger of inflammatory complications could cause serious problems [13]. Other treatment modalities have been reported, such as marsupialization, injection of sclerosing agents, an steroids, diathermy and radiotherapy in unresectable or persistent cases [13,17-19]. Injection of sclerosing agents into the lesion such as OK432 (a lyophilized mixture of group A streptococcus pyogenes of human origin), 50% dextrose, triamcinalone, bleomycin, fibrin sealant and hydrocolloid impression material has had some success. For recurrent cystic hygroma, intravenous cyclophosphamide and intracystic injection of OK432 have been advocated [11]. However, when extensive recurrent cystic hygroma becomes symptomatic as in our case, a multidisciplinary surgical approach should be carried out to achieve the optimal functional and cosmetic outcome.

### Acknowledgement

We thank the staff of Department of Oral Pathology and Microbiology of Bapuji Dental College and College of Dental sciences, Davangere, India, for their help in investigative procedures.

### References

- Nanson EM, Lymphangioma (cystic hygroma) of the mediastinum. *J Cardiovasc surg* 1968; 9:447-52
- Feutz EP, Yune HY, Mandelbaum I, Brashear RE. Intrathoracic cystic hygroma. *Radiology* 1973; 108:61-6
- Rasaretnam R, Chanmugam D, Sabanathan K, Paul AT. Cervicomediastinal Lymphangioma. *Aust NZ J Surg* 1976; 46:378-81
- Brown LR, Reiman HM, Rosenow EC, Gloviczki PM, Divertie MB. Intrathoracic lymphangioma. *Mayo Clin Proc* 1986; 61:882-92
- Wright CC, Cohen DM, Vegunta RK, Davis JT, King DR. Intrathoracic cystic hygroma: a report of three cases. *J Pediatr Surg* 1996; 31:1430-2
- Hamoir M, Plouin- Gaudon I, Rombaux P, et al. Lymphatic malformations of the head and neck: a retrospective review and a support for Staging. *Head Neck* 2001; 23:326-37
- Hutchinson. Mandibular enlargement; an unusual complication of a cervical cystic hygroma. *Int J Pediatric Dentistry*. 1996; 6:123-127
- Gleason T, Yuh W, Tali EA, Harris K, Mueller D. *Ann Otol Rhinol Laryngol* 1993; 102:564-7
- Scheffer RP, Oslen K, Gaffey T. Cervical lymphangioma in an adult. *Otolaryngol Head Neck Surg* 1985; 93:65-9
- Antoniades K, Kiziridou A, Psimopoulou M; Traumatic cervical cystic hygroma. *Int J. Oral Maxillofac. Surg.* 2000; 29:47-48
- Cheng LH, Wells F C, A multidisciplinary approach to recurrent cervicothoracic cystic hygroma in an adult. *British Journal of Oral and Maxillofacial Surgery*. 2004; 42:66-68
- Osborne TE, Haller JA, Levin LS, et al: Submandibular cystic hygroma resembling a plunging ranula in a neonate. Review and report of a case. *Oral Surg* 71:16,1991
- Farmand M, Kuttnerberger J: A New therapeutic concept for the treatment of cystic hygroma. *Oral Surg* 81:389,1996
- Chappuis JP: Aspects actuels du lymphangiome kystique cervical. *Arch Padiatr* 1:186,1994
- Batsakis JG: Tumours of the head and neck. Baltimore, MD, Williams & Wilkins, 1979, 301-303
- Thawley SE, Panje WR, Batsakis JG, et al: Comprehensive Management of head and neck Tumours. Philadelphia, PA, Saunders 1987, 1350-1352.
- Kennedy TL: cystic hygroma- lymphangioma: A rare and still unclear entity. *Laryngoscope* 99:1-10,1989.
- Diop EM, Diouf R, Hitimana, et al: Le Lymphangiome Kystique: un probleme pratique de l' oncologic cervicale. A Propos de 4 observations. *Ann Otolaryngol* 101:109,1984
- Osborne TE, Levin LS, Tilghman DM, et al: Surgical correction of mandibulofacial deformities secondary to large cervical cystic hygromas. *J Oral Maxillofac Surg* 45:1015,1987