

# Dehiscence and embolization of CorMatrix tricuspid valve replacement in the setting of infective endocarditis: a case report

Anna N. Tomdio<sup>1\*</sup>, Melissa Y.Y. Moey<sup>1</sup>, Irfan Siddiqui<sup>2</sup>, and Assad Movahed<sup>2</sup>

<sup>1</sup>Department of Internal Medicine, Vidant Medical Center/East Carolina University, Greenville, NC 27834, USA; and <sup>2</sup>Department of Cardiology, Vidant Medical Center/East Carolina University, Greenville, NC 27834, USA

Received 28 January 2018; accepted 5 July 2018; online publish-ahead-of-print 31 July 2018

## Background

Due to increased morbidity and mortality, prosthetic valve infective endocarditis (IE) with dehiscence requires urgent intervention. Early identification and therapy may prevent embolization.

## Case summary

A 27-year-old Caucasian woman with a history of hepatitis C, intravenous drug abuse, and tricuspid valve (TV) replacement was admitted for recurrent IE. She was found to have bacteraemia and fungaemia, and empiric antibiotics were initiated. Transthoracic echocardiogram (TTE) revealed a mobile 'mass' on the TV and dehiscence. The patient developed cardiogenic shock and repeat TTE showed a ruptured TV and absence of the 'mass', suspicious of embolization. She underwent emergent surgery with TV replacement using a Biocor valve and retrieval of the old CorMatrix valve found in the right mid pulmonary artery (PA). The patient was successfully weaned off inotropic agents and completed a prolonged course of antibiotics and anti-fungals.

## Discussion

The multi-disciplinary decision on timing of surgical intervention was challenging, especially due to ongoing mycobacterial infection that increased operative risk. With clinical deterioration, urgent surgery was performed revealing an embolized prosthetic valve in the PA. New surgical options for TV replacement in IE with extracellular-based material have shown promising outcomes with little reported data of long term complications. This case demonstrates a rare occurrence of embolized CorMatrix TV and highlights the challenge in timing of appropriate surgical intervention in a septic patient with thrombocytopenia.

## Keywords

Case report • Infective endocarditis • CorMatrix valve • Tricuspid valve • Bacteraemia • Cardiogenic shock • Sepsis

## Learning points

- Surgical options for tricuspid valve replacement (TVR) with extracellular-based material have shown promising outcomes with little reported data of long-term complications.
- Surveillance blood cultures should be obtained in high-risk patients and rapid surgical intervention, involving a multi-disciplinary team should be considered despite sepsis.

## Introduction

Tricuspid valve replacement (TVR) secondary to infective endocarditis (IE) is challenging with high rates of complications and mortality. Intravenous drug use (IVDU), instrumentation such as peripherally inserted central catheter, and long-term central venous catheter lines are pre-disposing factors for right sided endocarditis. Common sites of embolization include the pulmonary system causing either an infection or a clot. In the setting of an inter-atrial shunt, embolic strokes

\* Corresponding author. Tel: +1 252 744 3229, Email: tomdia16@ecu.edu. This case report was reviewed by Savvas Loizos, Timothy C. Tan, and Mohammed Akhtar.

© The Author(s) 2018. Published by Oxford University Press on behalf of the European Society of Cardiology.

This is an Open Access article distributed under the terms of the Creative Commons Attribution Non-Commercial License (<http://creativecommons.org/licenses/by-nc/4.0/>), which permits non-commercial re-use, distribution, and reproduction in any medium, provided the original work is properly cited. For commercial re-use, please contact [journals.permissions@oup.com](mailto:journals.permissions@oup.com)

are rare. The literature has demonstrated excellent outcomes from the extracellular-based material (ECM) CorMatrix valve,<sup>1</sup> however, long-term data is lacking. To the best of our knowledge, this is the first reported case of an infected CorMatrix TV that embolized to the pulmonary artery (PA).

## Timeline

## Case presentation

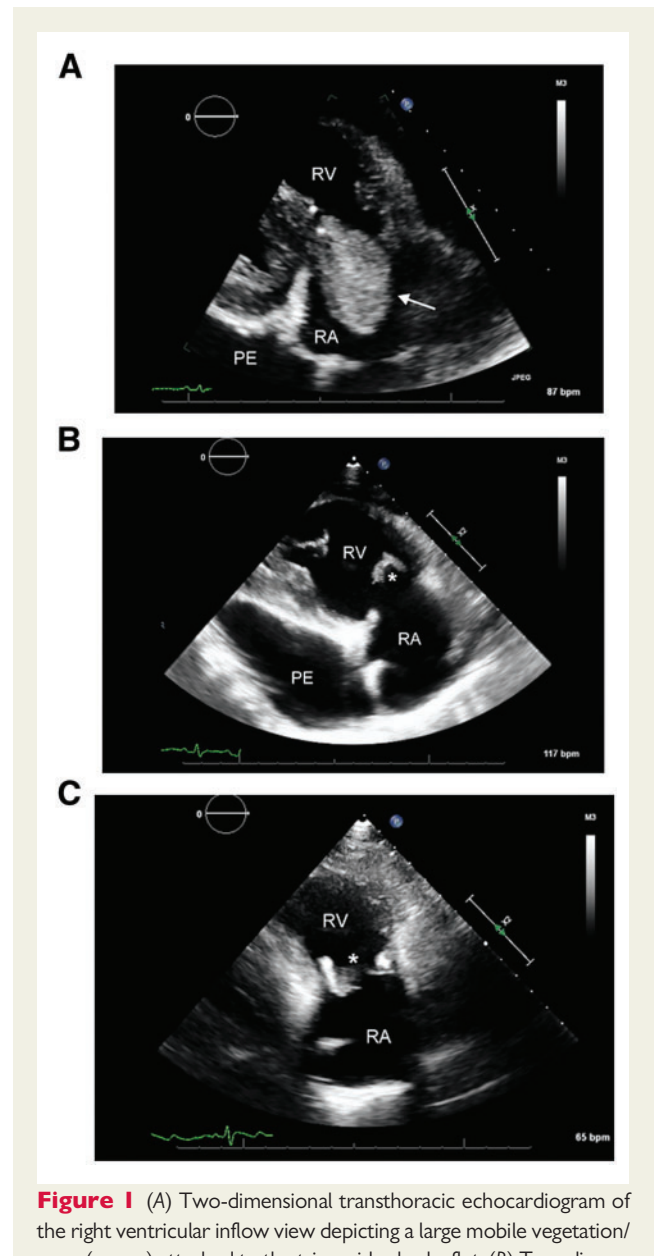
A 27-year-old Caucasian woman with hepatitis C (HCV), current IVDU, and TVR was transferred to our institution for IE due to surveillance blood cultures yielding *Candida parapsilosis* and *Staphylococcus*. Three months prior to this admission, she had completed a 6-week course of antibiotics, followed by TVR with a CorMatrix valve for endocarditis. Post-operative complications

3 months prior to admission	History of intravenous drug use Tricuspid valve (TV) endocarditis and bacteraemia ( <i>Candida</i> and <i>Staphylococcus aureus</i> ) treated with 6 weeks of IV antibiotics and anti-fungals (vancomycin, daptomycin, linezolid, cefepime, and micafungin). TV replaced with CorMatrix extracellular-based material. Post-operative complications of pulmonary embolism, Coumadin was therefore initiated
Admission day	Patient informed about surveillance blood cultures returning positive for methicillin-sensitive <i>S. aureus</i> and <i>Candida parapsilosis</i> Returned to hospital where patient had complaints of gingival haemorrhage, spontaneous bruising, and abdominal swelling Labs showed supratherapeutic international normalized ratio (INR) >10 and thrombocytopenia ( $12 \times 10^9 \mu\text{L}$ ) Computed tomography abdomen and pelvis showed large pericardial effusion and hepatosplenomegaly with mild ascites Infectious disease consulted with recommendations to start nafcillin and amphotericin B. Blood cultures repeated Admitted to the Cardiology Intermediate Unit at our institution
Day 1 of admission	Echocardiogram shows large mobile mass involving the TV that prolapses into the right atrium, causing possibly flail and dehisced TV. Very large pericardial effusion (4.21 cm posteriorly and 3.73 cm anteriorly) with evidence of markedly elevated intrapericardial pressure causing diastolic compression of the right ventricle (RV)
Day 1 of admission	Ultrasound-guided pericardiocentesis with removal of 600 mL of serous fluid Echocardiogram showed residual moderate effusion with no right ventricular diastolic collapse
Day 3 of admission	Nafcillin switched to cefazolin and continued on amphotericin B Blood cultures from 02/13 return positive for <i>Mycobacteria</i> in 2/4 bottles. Repeat blood cultures obtained Amphotericin B discontinued and switched to fluconazole Echocardiogram shows severe TV thickening and large vegetation is pedunculated and mobile. Ruptured TV chordae with a flail septal leaflet. Effusion measures 2.8 cm anteriorly and 3.8cm posteriorly. Some evidence of right ventricular compression without collapse
Day 7 of admission	Blood cultures from 02/18 return positive for <i>C. parapsilosis</i> Clinical deterioration with tachycardia, increased dyspnoea, abdominal distension, lower extremity oedema, persistent fevers, and lactic acid at nine. Transferred to the CICU Echocardiogram shows severe 'torrential' wide open tricuspid regurgitation, flail septal leaflet of TV with echodensity attached to tip suggestive of ruptured chordae and/or vegetation. When compared with prior transthoracic echocardiogram on 02/18, large vegetation attached to tricuspid leaflet is no longer visualized—suspicious for embolization
Day 7 of admission	Cefazolin and fluconazole switched to liposomal amphotericin B, amikacin, imipenem, and azithromycin
Day 8 of admission	Continued clinical deterioration (tachypneic, hypoxic, and hypotensive) requiring intubation and pressors Continued clinical decline with severe metabolic acidosis (lactic acid of 19, pH of 7.27) and signs of multiorgan failure Taken to the OR for emergent TVR by Cardiothoracic Surgery Emergency redo sternotomy, redo TV replacement with 29 Biocor valve, removal of embolized old CorMatrix TV from right pulmonary artery
Day 9 of admission	Blood cultures from 02/19 return positive for <i>Mycobacterium</i> Switched amphotericin B to micafungin and continued on amikacin, imipenem, and azithromycin. Recommendations were to complete micafungin for a total of 6 weeks and antibiotics for a total of 3 months
Day 28 of admission	Patient discharged home

arrival, levofloxacin, piperacillin-tazobactam, vancomycin, nafcillin, and amphotericin B were initiated. A computed tomography (CT) scan of her abdomen and pelvis revealed a pericardial effusion, mild hepatosplenomegaly, and anasarca. She was afebrile, with a blood pressure of 131/70 mmHg and heart rate of 90 b.p.m. Cardiovascular exam was remarkable for grade 2/6 holosystolic murmur at the left lower sternal border and jugular venous distention (JVD) to her ears. She had a distended abdomen and 3+ pitting oedema in bilateral lower extremities extending to her knees. Complete blood count showed normal white count, platelet count of  $12 \times 10^9/L$  (normal range  $150\,000\text{--}450\,000 \times 10^9/L$ ), normocytic anaemia with haemoglobin of 9.7 g/dL (normal range 12–16 g/dL), and an international normalized ratio (INR)  $>10$  (normal range of 1.0–2.0) reversed with IV vitamin K and discontinuation of coumadin. Erythrocyte sedimentation rate (ESR) was 27 mm/h (normal range 0–23 mm/h), fibrinogen was 140 mg/dL (normal range 200–400 mg/dL). Aspartate transaminase (AST) was 55 U/L and ALT - alanine transaminase was 20 U/L (normal range are 10–31 U/L and 10–41 U/L, respectively). Peripheral blood smear revealed numerous schistocytes and rare large platelets. Transthoracic echocardiogram (TTE) showed a mobile mass involving the TV with a large pericardial effusion measuring 4.21 cm by 3.73 cm. There was also evidence of elevated intrapericardial pressure causing diastolic compression of the right ventricle (RV) (Figure 1A, Supplementary material online, Videos S1A, B, S2A, B, S3A, B). Removal of 600 mL of serous pericardial fluid returned negative for bacteria, fungi, and viruses. Analysis was consistent with an exudative effusion. There was no apparent abscess or paravalvular leak. Repeat TTE following pericardiocentesis showed reduced pericardial effusion with relief of RV compression. On Day 8, she developed cardiogenic shock with worsening metabolic acidosis despite vasopressors that were started the day before. TTE showed torrential tricuspid regurgitation (TR) with a filling defect in the right PA (Figure 1B, Supplementary material online, Video S4A, B). Left ventricular function was normal but the RV was dilated and poorly functional. There was an attempt to perform CT chest, however, due to haemodynamic instability, she underwent emergent surgery. Several units of platelets, fresh frozen plasma, and packed red blood cells were required during surgery. The TV was replaced using a Biocor valve (Figure 1C, Supplementary material online, Video S5) following retrieval of the CorMatrix valve from the PA. Pathology of the extracted valve showed acutely inflamed tissue with bacteria, fungal element and acid-fast bacilli. She was discharged home on a prolonged course of antibiotics with Linezolid, Amikacin and Micafungin. All her laboratory values improved. Upon discharge, the patient moved out of state, however, was re-admitted within 2 months for blood cultures positive for AFB. TEE revealed new TV vegetations. Due to recurrent IVDU, she was not a candidate for surgical intervention and was treated with 6 weeks of Linezolid and Imipenem. The patient has since been lost to follow-up.

## Discussion

This case presents several important points including the challenges of TVR, need for additional long-term data on ECM in endocarditis and multi-disciplinary management of recurrent IE in high-risk patients. The patient's presentation raised several differential



**Figure 1** (A) Two-dimensional transthoracic echocardiogram of the right ventricular inflow view depicting a large mobile vegetation/mass (arrow) attached to the tricuspid valve leaflet. (B) Two-dimensional transthoracic echocardiogram of the right ventricular inflow view illustrating an absence of vegetation/mass and dehiscent tricuspid valve (asterisk) with a large pericardial effusion. (C) Two-dimensional transthoracic echocardiogram of the right ventricular inflow view demonstrating a replaced prosthetic tricuspid valve (asterisk). PE, pericardial effusion; RA, right atrium; RV, right ventricle.

diagnoses. Anasarca and JVD was thought to be due to portal hypertension from hepatic disease vs. right sided heart failure (HF). Liver disorder was unlikely as the CT of the abdomen did not reveal any portal vein thrombosis, cirrhosis, or oesophageal varices and HCV load was mildly elevated but not higher than previous levels. Her presentation was likely secondary to decreased RV function with TR seen on TTE. Thrombocytopenia was multifactorial from sepsis-related disseminated intravascular coagulation and myelosuppression from antibiotic use. Due to creatinine levels being at baseline and

**Table 1** Summary of current literature on CorMatrix ECM for valvular repair

Study	Study type	Valve	Indication	Patient population	Follow-up	Results
Gerdisch et al. <sup>1</sup>	Prospective	Tricuspid	TV endocarditis	19	1–18 month echocardiogram	One patient had recurrent disruption of implant at 13 and 22 months One patient had fungal infection Remaining had functioning TV and stable left and right systolic function at 18 months
Gerdisch et al. <sup>16</sup>	Prospective	Mitral	Endocarditis, MR, MS	19	4 days to 48 months (median 10.8 months) echocardiogram	Three deaths were unrelated to MR Two patients had reintervention unrelated to MR Remaining had functioning MV at follow-up
Kelley et al. <sup>14</sup>	Retrospective	Mitral	MR	44	Histology (if re-operated) 3, 6, and 12 month echocardiogram	Eight patients had severe MR (one central perforation, five enlargement with redundancy, and one dehiscence at suture line) Fifteen patients had functioning MV at 1-year follow-up
Wallen et al. <sup>12</sup>	Case report	Tricuspid	TV endocarditis	1	3 month echocardiogram	Mild residual TR Improved RV functioning
Luk et al. <sup>15</sup>	Case series	Mitral	MV endocarditis	2	10–18 months echocardiogram	One patient had severe MR secondary to perforated AML at 10 months follow-up Two patients had bacteraemia and recurrent endocarditis secondary to perforated AML at 18 month follow-up
Sundermann et al. <sup>11</sup>	Case report	Mitral	MV endocarditis	1	34 day echocardiogram	Competent MV with no recurrent endocarditis

Current literature available identified two prospective, one retrospective, two case reports and one case series of the ECM CorMatrix valve for endocarditis, mitral regurgitation (MR), and mitral stenosis (MS).

AML, anterior mitral leaflet; ECM, extracellular-based material; MS, mitral stenosis; MR, mitral regurgitation; MV, mitral valve; RV, right ventricle; TV, tricuspid valve.

normal neurological status, thrombotic thrombocytopenic purpura, and haemolytic uremic syndrome were unlikely. The presentation of acute right sided HF with anasarca, JVD, supratherapeutic INR, and thrombocytopenia was due to recurrent polymicrobial bacteraemia and IE, in the setting of a PE on coumadin.

TV endocarditis is a known complication of IVDU. Morbidity and mortality rates (1% to 6%) are higher in patients with replaced or repaired TV and recurrent endocarditis.<sup>2,3</sup> The causative organism has a major role with *Staphylococci* carrying an increased mortality rate.<sup>3</sup> Management is multidisciplinary often involving cardiology, cardiothoracic surgery, infectious disease and in certain situations, critical care medicine. Early surgical intervention is indicated in haemodynamic instability, septic embolism, uncontrolled infection and IE caused by *Staphylococci*, fungi, *Coxiella*, and *Chlamydia*.<sup>4</sup> Early surgery results in lower rates of recurrence and nearly 90% chance of survival.<sup>5</sup> However, in the setting of active infection, surgery should be delayed due to higher operative complications.<sup>2</sup>

Due to the unique anatomy of the TV and associated risks with bioprosthetic and mechanical valves, there are no ideal prostheses designed for replacement.<sup>6</sup> The fragility of the leaflet tissue and proximity of the right coronary artery to the TV and annulus renders the

procedure particularly challenging.<sup>7</sup> In comparison, the mitral valve (MV) is anatomically closer to the left ventricular outflow tract and the aortic valve, which also causes limitations, but the durability of the MV annulus decreases the risk of complications.<sup>8</sup> Technology in both valvular procedures has advanced with the CorMatrix valve for the TV and the transcatheter approach for the MV. Multimodality imaging tools are often used to measure the annulus size in order to minimize complications.

The successful management of TV endocarditis includes the excision of all infected tissue without valve replacement, but this is often complicated by the development of TR, which cannot be tolerated in up to 25% of patients.<sup>9</sup> In the absence of guidelines, the current best approach is monitoring high risk patients through blood culture surveillance. If there is concern for recurrent IVDU, it is reasonable to obtain blood cultures more frequently.

The CorMatrix ECM derived from porcine small intestines functions as an acellular bioscaffold allowing for native integration of the valve and tissue regeneration. It has garnered increasing interest for use in valve replacement as it eliminates the need for chronic anticoagulation therapy and reduces the risk of valve calcification and recurrent infection.<sup>10</sup> In the adult population, the utility of ECM in valve

replacement is limited to case reports and small prospective studies (Table 1). Favourable results have been seen at 18-month follow up<sup>1</sup> and others have shown resolution of symptoms with CorMatrix ECM intracardiac structural repair in the setting of endocarditis<sup>11,12</sup> however, long-term outcomes are lacking.

CorMatrix ECM naturalization occurs via an inflammatory response leading to fibrin deposition, which is subsequently replaced by smooth muscle and endothelial cells. In our patient, inadequate timing for regeneration vs. intense inflammation in the setting of persistent infection, may have predisposed the valve to damage and dehiscence. Contrary to the manufacturer's claim, there are reports of adverse effects involving inflammation of the CorMatrix valve. Inflammation, fibrosis, neovascularization, and necrosis were observed in 12 explanted CorMatrix specimens with little to no evidence of remodelling<sup>12</sup> and in another study, no resemblance to the native valve at 9 months.<sup>13</sup> Among 44 patients who had MV repair using CorMatrix ECM, 32% had recurrence of severe mitral regurgitation as a result of patch failure.<sup>14</sup> It is therefore possible that inflammation may play a role in failure however, mechanisms still need to be further elucidated.

## Conclusion

Given the risk for dire complications in delayed intervention, close monitoring of patients with IE after TVR is crucial, especially in ongoing IVDU. Despite promising results with CorMatrix valves, recurrent TV IE increases mortality and morbidity. Timing of surgical intervention should involve multidisciplinary evaluation and discussion, however, in the setting of cardiogenic shock, emergent TVR is necessary.

## Supplementary material

Supplementary material is available at *European Heart Journal - Case Reports* online.

**Consent:** The author/s confirm that written consent for submission and publication of this case report including image(s) and associated text has been obtained from the patient in line with COPE guidance.

**Conflict of interest:** none declared.

## References

- Gerdisch MW, Boyd WD, Harlan JL, Richardson JB Jr, Flack JE 3rd, Palafox BA, Johnson WE 3rd, Sun B, Lee R, Guy TS, Gang GI, Cox JL, Rao V. Early experience treating tricuspid valve endocarditis with a novel extracellular matrix cylinder reconstruction. *J Thorac Cardiovasc Surg* 2014;**148**:3042–3048.
- Shetty N, Nagpal D, Koivu S, Mrkobrada M. Surgical and medical management of isolated tricuspid valve infective endocarditis in intravenous drug users. *J Card Surg* 2016;**31**:83–88.
- Baddour LM, Wilson WR, Bayer AS, Fowler VG Jr, Bolger AF, Levison ME, Ferrieri P, Gerber MA, Tani LY, Gewitz MH, Tong DC, Steckelberg JM, Baltimore RS, Shulman ST, Burns JC, Falace DA, Newburger JW, Pallasch TJ, Takahashi M, Taubert MA. Infective endocarditis: diagnosis, antimicrobial therapy, and management of complications: a statement for healthcare professionals from the Committee on Rheumatic Fever, Endocarditis, and Kawasaki Disease, Council on Cardiovascular Disease in the Young, and the Councils on Clinical Cardiology, Stroke, and Cardiovascular Surgery and Anesthesia, American Heart Association: endorsed by the Infectious Diseases Society of America. *Circulation* 2005;**111**:e394–e434.
- Oakley CM, Hall RJ. Endocarditis: problems—patients being treated for endocarditis and not doing well. *Heart* 2001;**85**:470–474.
- Mansur AJ, Dal Bo CM, Fukushima JT, Issa VS, Grinberg M, Pomerantzeff PM. Relapses, recurrences, valve replacements, and mortality during the long-term follow-up after infective endocarditis. *Am Heart J* 2001;**141**:78–86.
- Said SM, Burkhart HM, Schaff HV, Johnson JN, Connolly HM, Dearani JA. When should a mechanical tricuspid valve replacement be considered? *J Thorac Cardiovasc Surg* 2014;**148**:603–608.
- Latib A, Mangieri A. Transcatheter tricuspid valve repair. *J Am Coll Cardiol* 2017;**69**:1807–1810.
- Guerrero ME, Salinger MH, Levisay JP. Transcatheter mitral valve replacement therapies. *Am Coll Cardiol* 2017;**28**. <http://www.acc.org/latest-in-cardiology/articles/2017/04/28/09/32/transcatheter-mitral-valve-replacement-therapies> (2 May 2018).
- Arbulu A, Kafi A, Thoms NW, Wilson RF. Right-sided bacterial endocarditis. New concepts in the treatment of the uncontrollable infection. *Ann Thorac Surg* 1973;**16**:136–140.
- Smith CR, Stamou SC, Boeve TJ, Hooker RC. Repair of a penetrating ascending aortic ulcer with localized resection and extracellular matrix patch aortoplasty. *Ann Thorac Surg* 2012;**94**:988–989.
- Sundermann SH, Rodriguez Cetina BH, Emmert MY, Falk V. Use of extracellular matrix materials in patients with endocarditis. *Thorac Cardiovasc Surg* 2014;**62**:76–79.
- Wallen J, Rao V. Extensive tricuspid valve repair after endocarditis using CorMatrix extracellular matrix. *Ann Thorac Surg* 2014;**97**:1048–1050.
- Zaidi AH, Nathan M, Emani S, Baird C, del Nido PJ, Gauvreau K, Harris M, Sanders SP, Padera RF. Preliminary experience with porcine intestinal submucosa (CorMatrix) for valve reconstruction in congenital heart disease: histologic evaluation of explanted valves. *J Thorac Cardiovasc Surg* 2014;**148**:2216–2224. 2225.e1.
- Kelley TM, Kashem M, Wang H, McCarthy J, Carroll ND, Moser GW, Guy TS. Anterior leaflet augmentation with cormatrix porcine extracellular matrix in twenty-five patients: unexpected patch failures and histologic analysis. *Ann Thorac Surg* 2017;**103**:114–120.
- Luk A, Rao V, Cusimano RJ, David TE, Butany J. CorMatrix extracellular matrix used for valve repair in the adult: is there de novo valvular tissue seen? *Ann Thorac Surg* 2015;**99**:2205–2207.
- Gerdisch MW, Shea RJ, Barron MD. Clinical experience with CorMatrix extracellular matrix in the surgical treatment of mitral valve disease. *J Thoracic Cardiovascular Surgery* 2014;**148**:1370–1378.