

## Oncology

## Primary small cell carcinoma of the upper urinary tract: A case report

Veronica Rupert, Marisa M. Clifton<sup>\*</sup>, Brant R. Fulmer, Ryan L. Mori, Heinric Williams, Alyssa Park

Dept. of Urology, Geisinger, Danville, PA, USA



## ARTICLE INFO

## Keywords:

Small cell carcinoma  
Neuroendocrine tumor  
Renal pelvis and ureter cancer

## BRIEF ABSTRACT

Small cell carcinoma of the urinary tract is an aggressive malignancy that comprises less than 1% of urinary bladder cancers. The renal pelvis and ureter, also lined by urothelium, are rare sites for small cell carcinoma. The diagnosis and staging of upper tract cancer are difficult due to the need for small, atraumatic instrument to access the upper tract. There are fewer than 40 reported cases of upper urinary tract small cell carcinoma. These include both pure and variant histologies. We present the management of a 72 year old male with small cell carcinoma of the upper urinary tract.

## Introduction

Extrapulmonary neuroendocrine (NE) tumors are rare, with >95% of these tumors being found in the gastrointestinal system. The second most common site of extrapulmonary neuroendocrine tumor is the genitourinary system.<sup>1</sup> Most genitourinary primary small cell carcinoma (SCC) occurs in the bladder while the renal pelvis and ureter, despite urothelial lining, are rare sites of primary neuroendocrine tumors.<sup>1,2</sup> The diagnosis and staging of upper urinary tract cancer are challenging due to the need for small, atraumatic instrumentation to access the ureter and renal pelvis. Fewer than 40 cases of ureteral small cell carcinoma or urothelial carcinoma with neuroendocrine differentiation have been reported in the literature since the first case was described in 1986. We present the management of a patient with urothelial carcinoma with neuroendocrine differentiation consistent with small cell carcinoma of the upper urinary tract.

## Case presentation

The patient is a 72 year old male with a 40 pack-year smoking history who presented to primary care with a decline in his estimated glomerular filtration rate (eGFR) to 43.7 mL/min/1.73m<sup>2</sup>. A urinalysis revealed microscopic hematuria. A renal ultrasound was performed and demonstrated severe right hydronephrosis. Further urologic evaluation with cystoscopy and retrograde ureteropyelograms showed a filling defect in

the right renal pelvis (Fig. 1). Right renal pelvis cytology was consistent with high grade urothelial carcinoma. A papillary lesion in the right distal ureter with fibrotic narrowing of the uretero-pelvic junction was visualized on ureteroscopy. Brush biopsy specimens from both areas were non-diagnostic. Due to the visual appearance of the tumor and positive urine cytology, the patient underwent right nephroureterectomy.

Pathology revealed high grade urothelial carcinoma with neuroendocrine differentiation, consistent with small cell carcinoma. On microscopic examination, the tumor cells were a hyperchromatic nuclei, powdery chromatin, small nucleoli, and mitotic index (MIB-1) of 80% (Fig. 2). The tumor was negative for lymphovascular invasion. On immunohistochemistry, the tumor was positive for CD56, stained weakly for synaptophysin, and had focal chromogranin and CK7 staining (Fig. 3). The tumor was negative for p63, GATA-3, and TTF-1. Surgical margins were negative, and final pathologic stage was pT3NxM0.

Postoperatively, PET-CT was performed demonstrating mildly FDG-avid right adrenal nodule which was biopsied and consistent with metastatic small cell carcinoma. He was treated with 15 cycles of paclitaxel (64mg/m<sup>2</sup>, 3 weeks on and 1 week off). Restaging CT was then performed which demonstrated no evidence of active disease. The patient had a treatment break at 19 months of follow-up. At 22 months following nephroureterectomy, he was re-imaged with PET-CT and had an FDG-avid recurrence in the right posterior pararenal space. The patient resumed therapy with paclitaxel.

**Abbreviations:** FDG, Fluorodeoxyglucose; eGFR, Estimated glomerular filtration rate; NE, Neuroendocrine; PET-CT, Positron emission tomography-computed tomography; SCC, Small cell carcinoma.

<sup>\*</sup> Corresponding author. Dept. of Urology, Geisinger, 100 N. Academy Avenue, Mail Code 01-27, Danville, PA, 17822, USA.

E-mail address: [marisameyerclifton@gmail.com](mailto:marisameyerclifton@gmail.com) (M.M. Clifton).

<https://doi.org/10.1016/j.eucr.2019.100995>

Received 5 August 2019; Accepted 13 August 2019

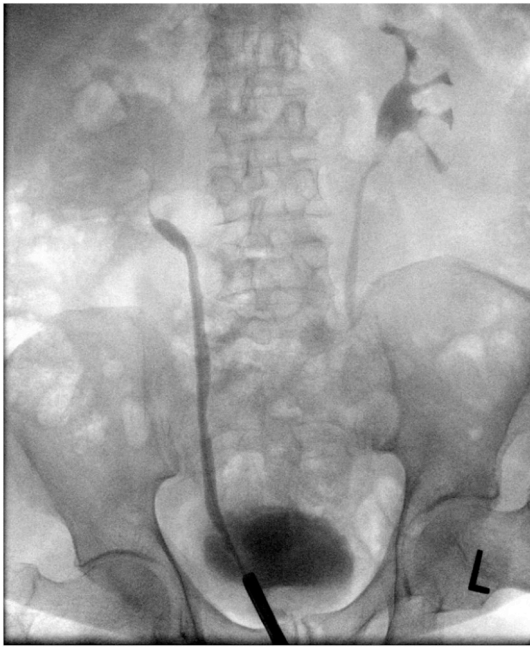
Available online 14 August 2019

2214-4420/© 2019 The Authors.

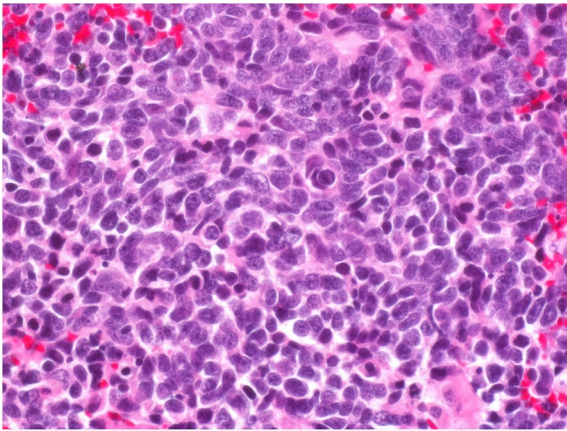
Published by Elsevier Inc.

This is an open access article under the CC BY-NC-ND license

(<http://creativecommons.org/licenses/by-nc-nd/4.0/>).



**Fig. 1.** Right retrograde ureteropyelogram with filling defect and hydronephrosis.

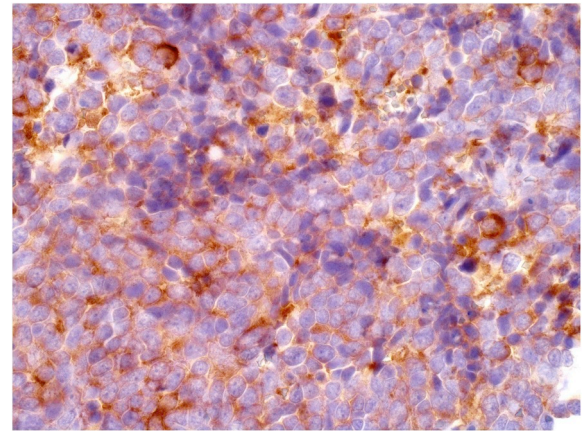


**Fig. 2.** H&E section of the tumor reveals a high grade carcinoma tumor comprised of sheets and nests of tumor cells with hyperchromatic nuclei, nuclear molding and abundant apoptotic cells. Tumor necrosis is seen focally.

## Discussion

Upper tract genitourinary tumors are rare and typically urothelial in origin. The percentage of upper tract urinary tumors with pure non-urothelial origin is accounts for fewer than 2% of all upper tract tumors. Urothelial primary with variant histology accounts for nearly 25% of cases in one study. Small cell was noted in 1.9% of all patients with variant histology. Variant histology is associated with advanced tumor stage, lymphovascular invasion, and lymph node metastasis. The natural history of this disease, these patients should be managed quickly with multimodal therapy.

Patients with pure or variant SCC of the upper urinary tract typically present in the sixth or seventh decade of life.<sup>1,2,3</sup> No definite risk factors have been identified, but smoking may play a role.<sup>1,2</sup> Presenting symptoms include weight loss, flank pain, hematuria, dysuria, or recurrent urinary tract infections.<sup>1,3</sup> Primary NE tumors in the urinary



**Fig. 3.** Immunohistochemistry stain for synaptophysin shows positivity in tumor cells.

tract are not typically associated with paraneoplastic syndromes. Evaluation to exclude an alternate primary should be performed prior to diagnosis of primary ureteral SCC.

The mechanism of NE malignancies in the upper tract is not well elucidated, but there have been four proposed hypotheses including: 1.) Neuroendocrine metaplasia of urothelial carcinoma lesion, 2.) Seeding from normal neuroendocrine cells in the urinary tract, 3.) Entrapped neural crest-derived cells in the ureter during embryogenesis, and 4.) Undifferentiated stem cells that differentiate into neuroendocrine.<sup>1</sup>

Histologic features of upper tract NE tumors are similar to those outside of the urinary tract including scant-moderate cytoplasm, fine speckled chromatin, and high nucleocytoplasmic ratio.<sup>5</sup> These tumors typically stain positive for CAM 5.2, synaptophysin, chromogranin A, pancytokeratin (AE1/AE3), CD56, and/or neuron-specific enolase.<sup>4,5</sup> Thyroid transcription factor- 1 has also been reported in 44% of extrapulmonary SCC and in 40% of bladder SCC.<sup>5</sup> Ureteral small cell carcinoma frequently demonstrates histologic features consistent with aggressive disease course including high mitotic count and proliferation index.<sup>5</sup>

There are no standard recommendations for treatment given disease rarity. The available literature supports neoadjuvant cisplatin-based chemotherapy followed by nephroureterectomy. One case report described a 50% reduction of retroperitoneal lymphadenopathy at 3 months without disease progression on cisplatin-etoposide.<sup>2</sup> Another case managed with irinotecan and cisplatin demonstrated tumor reduction after 2.8 months of therapy.<sup>1</sup>

Median survival ranges from 8.2 months with nephroureterectomy alone to up to 24 months with adjuvant platinum-based chemotherapy, with pathologic stage at diagnosis as the most significant prognostic factor.<sup>1,4,5</sup> Patients with pT1-pT2 had a median survival of 31 months compared to 8 months for pT3-pT4 disease. Aggressive therapy has yielded survival as high as 80 months in one case.<sup>4</sup>

Effective therapies to treat this aggressive variant are needed. Some reports suggest c-kit expression and mutations in platelet derived growth factor alpha (PDGFA) as potential targets. Pharmacologic agents for these targets are an active area of investigation.

## Conclusions

Primary upper urinary tract small cell carcinoma is a rare tumor that requires multimodal management. Treatment should be initiated expeditiously given the aggressive nature of this disease and should include a combination of surgical resection and platinum-based chemotherapy. Prognosis is best predicted by pathologic stage. Continued research is necessary to determine standard treatment recommendations for this

disease. Medications targeting c-kit and/or PDGFA may be promising avenues for future research.

#### Conflicts of interest

None.

#### Funding sources

This research did not receive any specific grant from funding agencies in the public, commercial, or not-for-profit sectors.

#### Acknowledgements

The authors acknowledge Dr. Tullika Garg for review of initial drafts of this manuscript and for writing assistance.

#### Appendix A. Supplementary data

Supplementary data to this article can be found online at <https://doi.org/10.1016/j.eucr.2019.100995>.

#### References

1. Ping JH, Chen ZX, Jiong Q, Han YQ, Nong X. Small cell neuroendocrine carcinoma of the ureter: a case report and literature review. *Oncol Lett.* 2014;7(3):728–730.
2. Sood A, Williamson SR, Leavitt DA. Neuroendocrine tumor of the ureter: a zebra among horses. *J Endourol Case Rep.* 2016;2(1):204–208.
3. Farci F, Manassero F, Baldesi R, et al. Primary small cell carcinoma of the ureter: case report and review of the literature. *Medicine.* 2018;97(24):e11113.
4. Hensley PJ, Bhalodi AA, Gupta S. Primary upper urinary tract small cell carcinoma: a case series and literature review. *J Endourol Case Rep.* 2017;3(1):165–168.
5. Acosta AM, Hamedani FS, Meeks JJ, Wu S. Primary ureteral thyroid transcription factor 1–positive small cell neuroendocrine carcinoma: case report and review of the literature. *Int J Surg Pathol.* 2015;23(6):472–477.