

Dentinogenic Ghost Cell Tumor — A Neoplastic Variety of Calcifying Odontogenic Cyst: Case Presentation and Review

Shalu Rai, Mukul Prabhat, Sumit Goel¹, Kanika Bhalla², Sapna Panjwani, Deepankar Misra, Ankur Agarwal, Gunjan Bhatnagar³

Departments of Oral Medicine and Radiology, Institute of Dental Studies and Technologies, Kadrabad, Modinagar, ¹Subharti Dental College, Meerut, ²Department of Oral Pathology, Inderprastha Dental College, Sahibabad, Ghaziabad, ³Department of Microbiology, Institute of Dental Studies and Technologies, Kadrabad, Modinagar, Uttar Pradesh, India

Abstract

Context: The calcifying odontogenic cyst (COC), also referred to as calcifying ghost cell odontogenic cyst (CGCOC) is a heterogeneous lesion existing either as cystic or solid variant. Due to the fact that all CGCOC lesions are not cystic, and the biological behavior is often not consistent with a cyst, there has always been a controversy as to whether COC is a cyst or a tumor. The dentinogenic ghost-cell tumor (DGCT), a solid variant of the COC, is an uncommon odontogenic neoplasm occurring predominantly in later life. Case report is followed by a concise review and disambiguation of controversial terminologies regarding nomenclature of COC. **Case Report:** We report a case of 33-year-old female patient who presented with an insidious, steadily increasing swelling on the left side of her face since 8 months. Patient reported slight difficulty in eating because of reduced intraoral space and an obvious concern with facial disfigurement. There was no contributory dental or medical history. Intraorally, a hard, well defined, bicortical swelling was noted in left maxillary region with slight mobility of the associated teeth and normal appearing overlying mucosa. A provisional diagnosis of adenomatoid odontogenic tumor was made, and orthopantomogram, paranasal sinus radiograph and computed tomography scan of the face were acquired. A radiographic diagnosis of COC was made, which was subsequently confirmed on histopathology postenucleation of the tumor mass. COC has been seen to be of extensive diversity in its clinical and histopathological features as well as in its biological behavior. **Conclusion:** The present case of 33-year-old female was diagnosed as DGCT, a tumorous form of COC, due to its characteristic histological features; numerous ghost cells and dentinoid material.

Keywords: Calcifying odontogenic cyst, Computed tomography features, Controversial terminologies, Dentinogenic ghost cell tumor, Neoplastic variant of calcifying odontogenic cyst

Address for correspondence: Dr. Shalu Rai, Department of Oral Medicine and Radiology, Institute of Dental Studies and Technologies, Kadrabad, Modinagar - 201 201, Uttar Pradesh, India. E-mail: drshalurai@gmail.com

Introduction

The calcifying odontogenic cyst (COC) was first described in 1962 by Gorlin *et al.* as a separate entity of odontogenic origin.^[1] COC, also referred to as calcifying

ghost cell odontogenic cyst (CGCOC), is a heterogeneous lesion existing either as cystic or solid variant.^[2-6] Majority of CGCOC (85%) are cystic in nature, and clinically may occur as a central (85%) or peripheral (15%) lesion. The peak age of occurrence is second and seventh decade of life with no gender predilection.^[6-9] CGCOC occurs with equal frequency in either of the jaw bones, anterior to the first molar in the incisor-canine region.^[7-9] Central lesions commonly present as asymptomatic bony expansion, while peripheral lesions are seen as sessile or pedunculate smooth surfaced masses.^[6-9] Due to the fact that all CGCOC lesions are not cystic, and the biological behavior is often not consistent with a cyst, there has always been a controversy as to whether COC is a cyst

Access this article online

Quick Response Code:



Website:
www.najms.org

DOI:
10.4103/1947-2714.150084

or a tumor. The dentinogenic ghost cell tumor (DGCT), regarded as a solid variant of the COC, is an uncommon odontogenic neoplasm occurring predominantly in later life. DGCT can exhibit either a benign or a malignant form or can undergo malignant transformation.^[10]

Case Presentation

A 33-year-old female patient reported to the oral medicine and radiology clinic complaining of a swelling on the left side of her face since 8 months. Swelling had started insidiously and steadily increased to the presenting size. Patient reported slight difficulty in eating because of reduced intraoral space and an obvious concern with facial disfigurement. There was no contributory dental or medical history.

Extraorally, gross facial asymmetry could be seen as a diffused swelling in the mid facial region on the left half, approximately 2 cm × 3 cm in overall dimensions. Antero-posteriorly, the swelling extended from the ala of the nose to the malar prominence and superior-inferiorly from the infraorbital ridge to the upper lip region, without crossing the midline. Swelling did not interfere with the eye movements. Skin over the swelling appeared normal. Palpation revealed bony hard consistency of the swelling. No regional lymph nodes were involved.

On intraoral examination, a well-defined, bicortical swelling was noted in left maxillary region, measuring about 3 cm × 4 cm and extending from 22 to 26. Buccally, the inferior border was located at the marginal gingiva and the superior border extended deep into the vestibule. Buccal vestibule was completely obliterated. Palatally, the inferior border was located at the marginal gingiva with the superior border extended along the palatal contour lying approximately 2 cm short of the mid palatine raphe, not crossing the midline. Slight buccal displacement of involved teeth was noticed. Overlying mucosa appeared normal. On palpation, the swelling was hard in consistency, and associated teeth showed grade I mobility.

Based on the history and clinical features, a provisional diagnosis of adenomatoid odontogenic tumor was made. For differential diagnosis, COC, dentigerous cyst, ameloblastoma, and central giant cell granuloma (CGCG) were considered.

Orthopantomograph revealed a well-defined, multilocular, mixed radiolucency, roughly 6 cm × 5 cm in size, extending from 21 to 26 [Figure 1]. Inferiorly it was lined by a sclerotic margin and superiorly extended into the left maxillary antrum. Multiple ill-defined radiopacities were seen within the radiolucency with a diffused opacification of the left maxillary sinus.

Paranasal sinus view revealed a diffused radiopacity obliterating the left maxillary sinus. On close examination, a multilocular pattern was appreciable [Figure 2].

Axial sections on computed tomography (CT) revealed a heterogeneous, soft tissue expansile mass in the left maxillary cuspid region causing destruction of the inner and outer cortical plates. Perforation of the facial wall of the maxillary sinus could be noted. Multiple pebble-like radiopacities were seen dispersed within the tumor mass [Figure 3].

Coronal sections revealed an extension of the lesion into the left maxillary sinus through the antral floor, with a soft tissue mass completely occupying the sinusal cavity causing slight elevation of the orbital floor [Figure 4].

Three-dimensional reconstruction of the cranium showed a perforation of the maxilla in the region of the left canine fossa below the infra-orbital foramen [Figure 5].

Hematological findings were noncontributory.

A radiographic diagnosis of COC (calcifying cystic odontogenic tumor [CCOT] or Gorlin's cyst) was made. Adenomatoid odontogenic tumor, ameloblastoma, Pindborg tumor calcifying epithelial odontogenic tumor, ameloblastic fibro-odontoma, and CGCG were considered under differential diagnosis.

Patient was referred to oral surgery for enucleation of the tumor mass [Figure 6].

Hematoxylin and eosin stained section of the enucleated tissue showed a lesion composed of a fibrous capsule lined by a proliferation of odontogenic epithelial cells. Some of the cells had hyperchromatic nuclei. Numerous pale eosinophilic ghost cells were seen forming masses and filling the lumen. Areas of calcification were seen. Wall adjacent to the epithelium showed homogeneous eosinophilic deposits (dysplastic dentin) [Figure 7a].

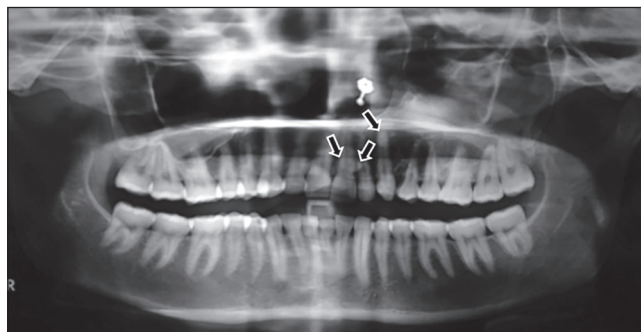


Figure 1: Orthopantomograph showing a well-defined, multilocular, mixed radiolucency, roughly 6 cm × 5 cm in size, extending from 21 to 26 with multiple pebble-like ill-defined radiopacities (black arrows)

Van Gieson's stain later confirmed the histopathological diagnosis of a solid neoplastic variant of COC, also known as DGCT [Figure 7b].

Discussion

In 1962, Gorlin *et al.* were the first to introduce the term and describe COC.^[1] The term COC was commonly used and still prevails in the literature.^[7,11]

Some authors, based on dualistic concept, regard COC as a lesion containing two entities: A cyst and a tumor, which exists either as a cyst or a tumor. Others following the monistic concept regard the lesion as a tumor with a tendency toward cyst formation.^[2-5]

Since its first description as a separate entity, a number of COC cases have been reported, and it is now a well-known clinical and histopathological entity. Controversies over terminology and sub-types of COC still prevail. However, two main types of COC have

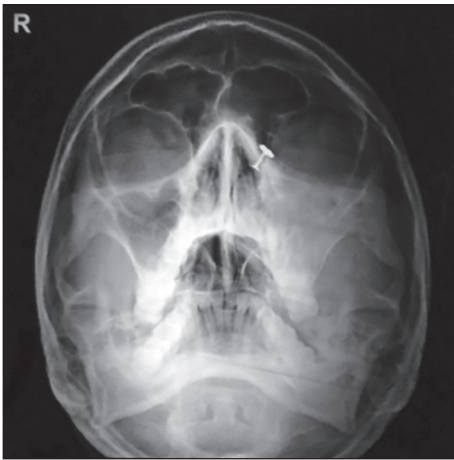

Figure 2: Paranasal sinus view showing a diffused radiopacity obliterating the left maxillary sinus

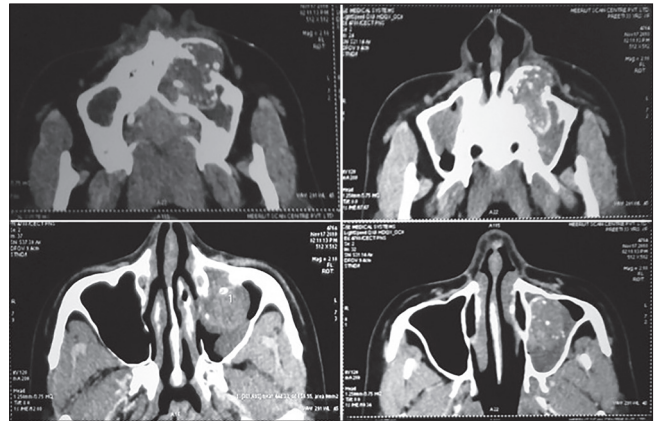


Figure 3: Axial computed tomography showing heterogeneous, soft tissue expansile mass in the left maxillary cuspid region. Destruction of the inner and outer cortical plates and perforation of the facial wall of the maxillary sinus can be noted

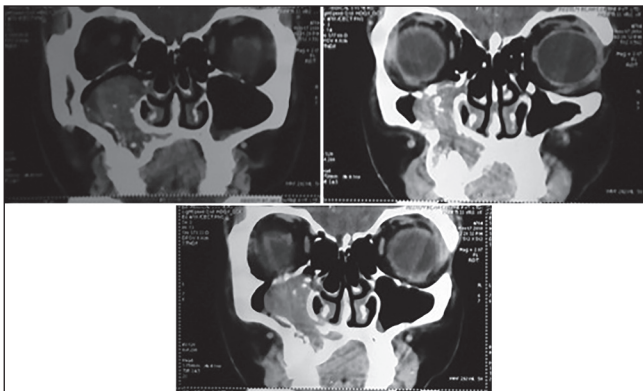


Figure 4: Coronal computed tomography sections showing extension of the lesion into the left maxillary sinus through the antral floor, causing slight elevation of the orbital floor

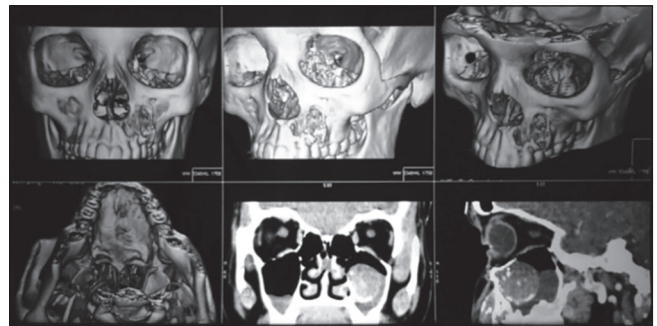


Figure 5: Three-dimensional computed tomography reconstruction of the cranium showing perforation of the maxilla in the region of the left canine fossa below the infra orbital foramen

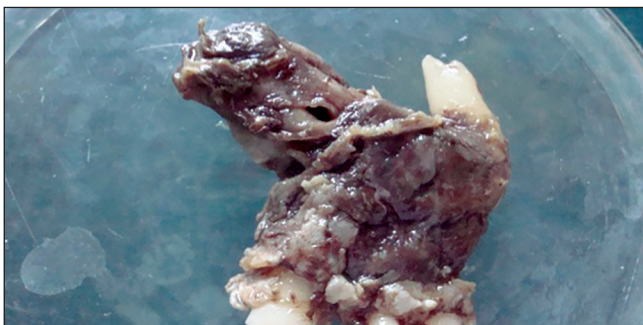

Figure 6: Enucleated tumor mass

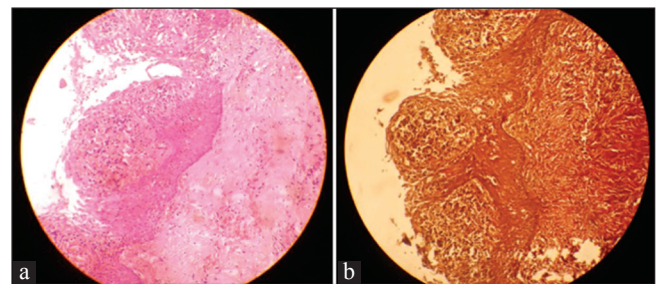


Figure 7: Histopathology. (a) H and E stained section of the enucleated tissue. (b) Van Gieson's staining

chiefly been accepted-the cystic and the solid-tumor type.^[2,3,5]

In 1981, Praetorius, following the dualistic concept, classified COC into two subtypes – a cyst and a neoplasm. He proposed the term DGCT for the 1st time for the neoplastic variant of COC.^[2,12]

In 1991, Buchner clinically classified COC as peripheral COC and central COC. He further sub-classified each of them into cystic or neoplastic variants and also included rare malignant variant of COC in his classification.^[13]

In the same year, Hong followed the dualistic concept and classified COC into cystic and neoplastic types. He further subdivided cystic type into proliferative, nonproliferative, ameloblastomatous and odontoma associated. The term epithelial odontogenic ghost cell tumor was first used by Hong for the solid variant.^[3]

In 1998, Toida suggested that the lesions should not be classified as “cystic” or “neoplastic” because the former term described the morphology while the later defined the biological behavior of the lesion. The term “cystic” is synonymous for “nonneoplastic” and at the same time, there may be lesions with cystic architecture that have extensive proliferative capacity.^[12] Toida proposed a new classification in which the cystic variant was called CGCOC and the neoplastic variant was called calcifying ghost cell odontogenic tumor (CGCOT). He further subdivided the neoplastic group into cystic CGCOT and solid CGCOT, to include neoplasm showing cystic architecture and neoplasm with a solid pattern, respectively. A third category – combined lesions was also introduced which comprised CGCOC and CGCOT associated with odontoma, ameloblastoma and other odontogenic lesions.^[12]

While most authors followed the dualistic concept for classification and nomenclature, the World Health Organization (WHO) followed the monistic concept and in 1971, described the lesion as a nonneoplastic cystic lesion and used the term COC, which was originally introduced by Gorlin *et al.*^[14] In 1992, WHO re-classified this lesion under odontogenic tumors, but continued to use the term COC.^[15] In 2005, as the terminology was misleading and nonexplanatory of the behavior of the lesion, WHO again renamed the lesion as (CCOT).^[9]

The nomenclature of the lesion may affect the treatment planning as “cystic” is usually approached conservatively (enucleation/marsupialization) while a “tumor” calls for a more aggressive intervention (*en bloc* resection) with a pre-cautious and longer follow-up.^[9,10,13] The naming convention should emphasize on biological behavior of the lesion rather than familiar or older

terms and hence that lesion can be approached and treated accordingly.^[16] The authors are of the opinion that the classification proposed by Toida [Table 1] not only avoids confusion, but also helps in planning the treatment accordingly.

Different investigators have given different names to COC. DGCT as a terminology was first proposed by Praetorius *et al.* in 1981 for the neoplastic variety of COC. DGCT has also been termed as odontogenic ghost cell tumor by Colmenero *et al.*^[5]

Dentinogenic ghost cell tumor is an extremely rare variety of COCs that exists both as central and peripheral type. COCs account for only 1-2% of all odontogenic cysts, and only 2-14% of them are DGCTs.^[17] According to the available literature on central DGCTs, only 16 cases have been reported.^[17,18]

Dentinogenic ghost cell tumor commonly occurs in elderly, with an average age for the presentation being 50 years (range: 17-72 years). It shows slight male predilection with a tendency to occur in the anterior segment of the jaws (canine to first molar), with equal frequency in maxilla and mandible. Patients are usually asymptomatic, although pain or discomfort may be a feature in some cases.^[5,19]

Dentinogenic ghost cell tumors on panoramic radiographs show a relatively well-defined radiolucent-radiopaque lesion of considerable size with either unilocular or multilocular presentation. Occlusal radiographs show a bicortical expansion. CT of the lesion reveals a soft tissue density mass with foci of calcifications.^[17,18] Radiographically, radiolucency with scattered radio-opaque calcifications is a common feature. Root resorption or an impacted tooth in relation to the tumor mass is also noted in some cases.^[5]

Microscopically, it consists of ameloblastomatous epithelial islands, with areas of ghost cell formation

Table 1: Classification proposed by Toida (1998)

Category	Type
Cyst	CGCOC
Neoplasm	CGCOT
	Benign CGCOT
	Cystic variant: Cystic CGCOT
	Solid variant: Solid CGCOT
Combined lesion	Malignant CGCOT
	Odontoma
	Ameloblastoma
	Other odontogenic lesions

CGCOC = Calcifying ghost cell odontogenic cyst, CGCOT = Calcifying ghost cell odontogenic tumor

and varying amount of dentinoid material.^[20] Hematoxylin and eosin sections of the solid type of the lesion show a lining consisting of a proliferative epithelium with numerous ghost cells having a tendency to develop foreign body granulomas. The proliferative epithelium and the ghost cells are interspersed with abundant material called dentinoid and hence the lesion is collectively called a DGCT. Under Van-Geison staining, the ghost cells appear yellow, and the dentinoid, red.^[6,7]

Dentinogenic ghost cell tumor can be either benign or malignant, depending on the histopathological features. Malignant DGCTs can show aggressive clinical behavior and can metastasize.^[4,21] Malignant transformation of a benign DGCT has also been reported.

Ramaglia *et al.* Minerva reported a distinguishing case of two central DGCT in the maxilla of a female patient in pediatric age, which was initially detected as complex odontomas associated with bilaterally impacted teeth. After the surgical removal of lesions with the means of piezoelectric, histopathological examination showed the potential of local invasiveness and the authors suggest that an adequate follow-up should be instituted to observe any sign of recurrence.^[22]

Initially enucleation was the primary treatment for central DGCT, but local recurrence was noted. Hence, at present, a more radical approach is employed, which can be a segmental resection or an *en bloc* excision depending on the site and extent.^[21] In this case, the lesion was treated with surgical enucleation of the tumor mass with extensive curettage.

Local recurrences can be present in COCs in general and DGCTs in particular. Central DGCTs have been found to have a high rate of recurrences after resection.^[18] Recurrent cases have occurred over 5-8 years following initial treatment.^[17] The present case is under follow-up, and it has been 2 years after the treatment, and no recurrence has been observed.

References

1. Gorlin RJ, Pindborg JJ, Clausen FP, Vickers RA. The calcifying odontogenic cyst – a possible analogue of the cutaneous calcifying epithelioma of Malherbe. An analysis of fifteen cases. *Oral Med Oral Pathol* 1962; 15:1235-43.
2. Praetorius F, Hjørting-Hansen E, Gorlin RJ, Vickers RA. Calcifying odontogenic cyst. Range, variations and neoplastic potential. *Acta Odontol Scand* 1981;39:227-40.
3. Hong SP, Ellis GL, Hartman KS. Calcifying odontogenic cyst. A review of ninety two cases with reevaluation of their nature as cyst or neoplasm, the nature of the ghost cells, and subclassification.

4. Ellis GL, Shmookler BM. Aggressive (malignant?) epithelial odontogenic ghost cell tumor. *Oral Surg Oral Med Oral Pathol* 1986;61:471-8.
5. Colmenero C, Patron M, Colmenero B. Odontogenic ghost cell tumours. The neoplastic form of calcifying odontogenic cyst. *J Craniomaxillofac Surg* 1990;18:215-8.
6. Shear M. Calcifying odontogenic cyst. In: Shear M, ed. *Cysts of the oral regions*, 3rd edn. Bristol: Wright, 1992;102-10.
7. Rajkumar K, Kamal K, Sathish MR, Leena S. Calcifying odontogenic cyst. *J Oral Maxillofac Pathol* 2004;8:99-103.
8. Gallana-Alvarez S, Mayorga-Jimenez F, Torres-Gómez FJ, Avellá-Vecino FJ, Salazar-Fernandez C. Calcifying odontogenic cyst associated with complex odontoma: Case report and review of the literature. *Med Oral Patol Oral Cir Bucal* 2005;10:243-7.
9. Kler S, Palaskar S, Shetty VP, Bhushan A. Intraosseous calcifying cystic odontogenic tumor. *J Oral Maxillofac Pathol* 2009;13:27-9.
10. Patil K, Mahima VG, Srikanth HS. Dentinogenic ghost cell tumor: A variant of Gorlin's cyst. *J Oral Maxillofac Pathol* 2008;12:38-40.
11. de Fátima Bernardes V, de Lacerda JC, de Aguiar MC, Gomez RS. Calcifying odontogenic cyst associated with an orthokeratinized odontogenic cyst. *Head Neck Pathol* 2008;2:324-7.
12. Toida M. So-called calcifying odontogenic cyst: Review and discussion on the terminology and classification. *J Oral Pathol Med* 1998;27:49-52.
13. Buchner A, Merrell PW, Carpenter WM, Leider AS. Central (intraosseous) calcifying odontogenic cyst. *Int J Oral Maxillofac Surg* 1990;19:260-2.
14. Pindborg JJ, Kramer IRH, Torloni H. Histological typing of odontogenic tumours, jaw cysts, and allied lesions. Geneva: World Health Organization, 1971;28.
15. Kramer IRH, Pindborg JJ, Shear M. Histological typing of odontogenic tumours. WHO, 2nd edn. International histological classification of tumours. Berlin: Springer-Verlag, 1992;7-9.
16. Thinakaran M, Sivakumar P, Ramalingam S, Jeddy N, Balaguan S. Calcifying ghost cell odontogenic cyst: A review on terminologies and classifications. *J Oral Maxillofac Pathol* 2012;16:450-3.
17. Kasahara K, Lixuka T, Kobayashi I, Totsuka Y, Kohgo T. A recurrent case of odontogenic ghost cell tumor of the mandible. *Int J Oral Maxillofac Surg* 2002;31:684-7.
18. Yoon JH, Ahn SG, Kim SG, Kim J. Odontogenic ghost cell tumor with clear cell components: Clear cell odontogenic ghost cell tumor? *J Oral Pathol Med* 2004;33:376-9.
19. Singhaniya SB, Barpande SR, Bhavthankar JD. Dentinogenic ghost cell tumor. *J Oral Maxillofac Pathol* 2009;13:97-100.
20. Tajima Y, Ohno J, Ustumi N. The Dentinogenic ghost cell tumor. *J Oral Pathol* 1986;15:359-62.
21. Tomich CE. Calcifying odontogenic cyst and dentinogenic ghost cell tumor. *Oral Maxillofac Surg Clin N Am* 2004;16:391-7.
22. Ramaglia L, Esposito D, Bruno MP, Siano M. Dentinogenic ghost cell tumor: Histopathology and clinical aspects in pediatric age. *Minerva Stomatol* 2012;61:509-17.

How to cite this article: Rai S, Prabhat M, Goel S, Bhalla K, Panjwani S, Misra D, et al. Dentinogenic ghost cell tumor - A neoplastic variety of calcifying odontogenic cyst: Case presentation and review. *North Am J Med Sci* 2015;7:19-23.

Source of Support: Nil. **Conflict of Interest:** None declared.