

Intraperitoneal and Extraperitoneal Colonic Perforation Following Diagnostic Colonoscopy

Ahmed Dehal, MD, MPH, Deron J. Tessier, MD

ABSTRACT

Both intraperitoneal and extraperitoneal colonic perforations have been reported after colonoscopy; however, cases with combined types of perforation are rare. We present the case of a 55-year-old man with a history of Crohn disease who complained of acute abdominal pain after a diagnostic colonoscopy. Abdominal computed tomography scan showed extensive pneumoperitoneum, pneumoretroperitoneum, pneumomediastinum, and left-sided pneumothorax. Exploratory laparotomy was performed, and the patient underwent subtotal colectomy and end ileostomy with placement of a left-sided chest drain for the left-sided pneumothorax. The patient was discharged home postoperatively in good condition. As the utility of colonoscopy continues to broaden, its complications will also be more common. Whereas intraperitoneal perforation is a known and not uncommon complication, extraperitoneal perforation is an uncommon complication. Combined intraperitoneal and extraperitoneal perforation is extremely rare, with only a few cases reported in the literature. Early diagnosis and operative management resulted in a satisfactory outcome in this particular case.

Key Words: Intraperitoneal, Extraperitoneal, Colon, Perforation, Colonoscopy

INTRODUCTION

Colonoscopy is used worldwide for the diagnosis and treatment of colorectal disease. As colonoscopy use continues to dramatically increase, awareness of its potential complications becomes essential.¹ Colonoscopy has become one of the most common medical procedures performed, in part because of the successful promotion of colorectal cancer (CRC) screening and prevention guidelines, which began in 1980 by the American Cancer Society.² Considering that CRC is the third most common cancer diagnosed and the second leading cause of cancer-related death in the United States and that colonoscopy is an essential screening and diagnostic tool for CRC, the increase in its use becomes apparent.³

Colonoscopy is regarded as a relatively safe procedure and is widely performed. However, it poses risks for serious complications. Perforation of the colon is considered one of the most serious complications of colonoscopy because it can lead to peritonitis, shock, sepsis, and death.⁴ Colon perforation may occur as either intraperitoneal or extraperitoneal perforation or in combination. Generally, intraperitoneal perforation is common.⁵ In contrast, extraperitoneal perforation that can manifest with pneumoretroperitoneum, pneumomediastinum, and subcutaneous emphysema is very rare.⁶ To our knowledge, only 6 cases of combined intraperitoneal and extraperitoneal perforation have been previously reported.^{7–12} We present a case of combined intraperitoneal and extraperitoneal colon perforation that manifested as pneumoperitoneum, pneumoretroperitoneum, pneumomediastinum, and subcutaneous emphysema, as well as pneumothorax. We also present a review of the literature and discussion about the possible etiologies and therapeutic aspect of this complication.

CASE REPORT

A 55-year-old man with a long history of Crohn disease underwent diagnostic colonoscopy to assess disease activity after having worsening abdominal pain. He underwent bowel cleansing, and colonoscopy was performed in the left lateral position with the patient sedated with intravenous propofol. The colonoscope was carefully in-

Department of General Surgery, Kaiser Permanente, Fontana, CA, USA (all authors).

This manuscript has not been submitted for publication elsewhere. All the authors have contributed significantly, and all authors are in agreement with the content of the manuscript.

Conflicts of interest and source of funding: The authors indicate no potential conflict of interest or financial ties.

Address correspondence to: Ahmed Dehal, MD, MPH, Department of General Surgery, Kaiser Permanente, 9961 Sierra Ave, Fontana, CA 92335, USA. Telephone: (912) 541-2526, Fax: (909) 427-4065, E-mail: ahmed.dehal@gmail.com

DOI: 10.4293/108680813X13693422521638

© 2014 by JSLS, *Journal of the Society of Laparoendoscopic Surgeons*. Published by the Society of Laparoendoscopic Surgeons, Inc.

roduced through the anus under direct visualization and advanced to the terminal ileum. The colonoscope was withdrawn, and the mucosa was carefully examined. The quality of preparation was good, and the views were acceptable. Patchy nodular mucosa (**Figure 1A**) was found on the right side of the colon, and erythematous mucosa (**Figure 1B**) and an ulcer (**Figure 1C**) were found in the terminal ileum. Multiple biopsy specimens were taken. The final pathologic diagnosis was consistent with severely active Crohn disease.

After the procedure, the patient was found to have scrotal swelling in the recovery room and a urology consultation was obtained. The urology team diagnosed him with pneumoscrotum, and during that time, the patient began complaining of increasing abdominal pain. The general surgery team was then consulted, at which time the patient was found to be in moderate distress and tachycardic. On examination, he was found to have decreased breath sounds on the left side, and abdominal examination showed a distended tympanic abdomen with subcutaneous air mostly on the right side. There was no evidence of peritonitis, however. His white cell count was 19 900. Computed tomography scan of the abdomen was performed and showed pneumomediastinum and a left-sided pneumothorax (**Figure 2A**), retroperitoneal gas (**Figure 2B**), and intraperitoneal and subcutaneous gas (**Figure 2C**). There was no leakage of contrast from the colon or rectum into the peritoneal cavity or retroperitoneal tissues. In view of the clinical and radiologic findings, colon perforation was strongly suspected, and the patient was taken emergently to the operating room.

In the operating room, it was noted that the patient had creeping fat and significant Crohn disease at the terminal ileum and right side of the colon. On the right side of the abdomen in the retroperitoneal area, there was a large amount of air as well. The descending colon was firm and was also found to be significantly diseased. There was no retroperitoneal air on the left side. The transverse colon seemed to be spared of any significant disease. No overt perforation was seen. The patient underwent subtotal colectomy and end ileostomy, as well as placement of a left-sided chest drain for the left-sided pneumothorax. Postoperatively, the patient did well, the pneumothorax resolved, the chest drain was removed, and the patient was discharged home in good condition.

DISCUSSION

The incidence of colonic perforation after colonoscopy has been variably reported. During diagnostic colonosco-

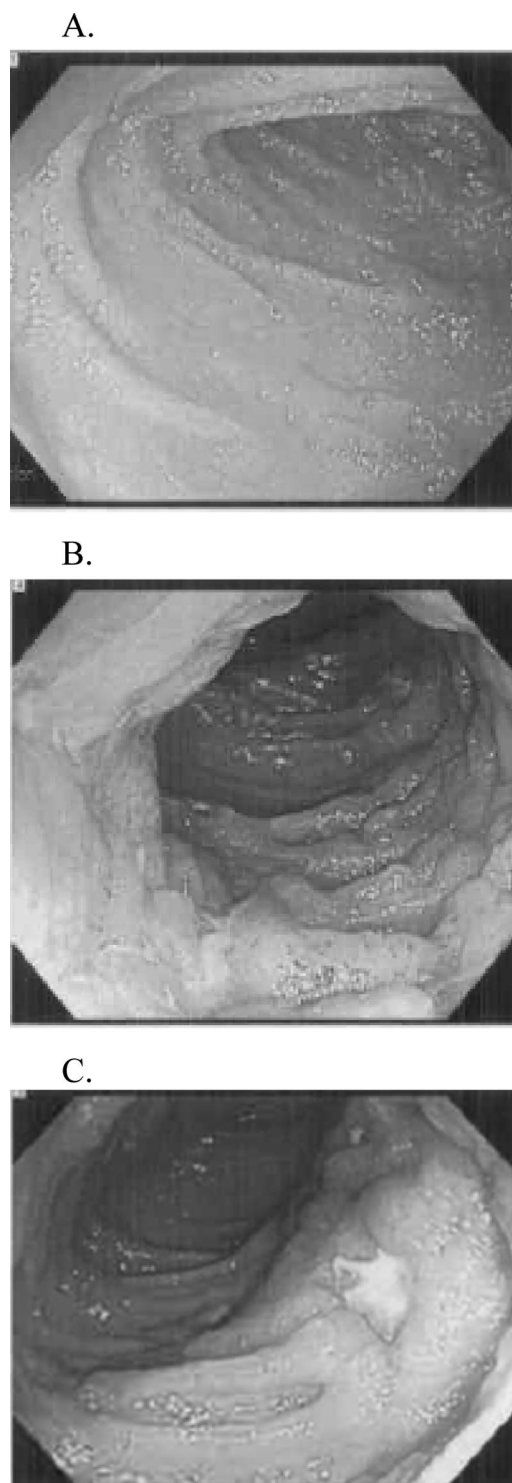


Figure 1. Colonoscopic view showing (A) patchy nodular mucosa on right side of colon, (B) erythematous mucosa in terminal ileum, and (C) ulcer in terminal ileum.

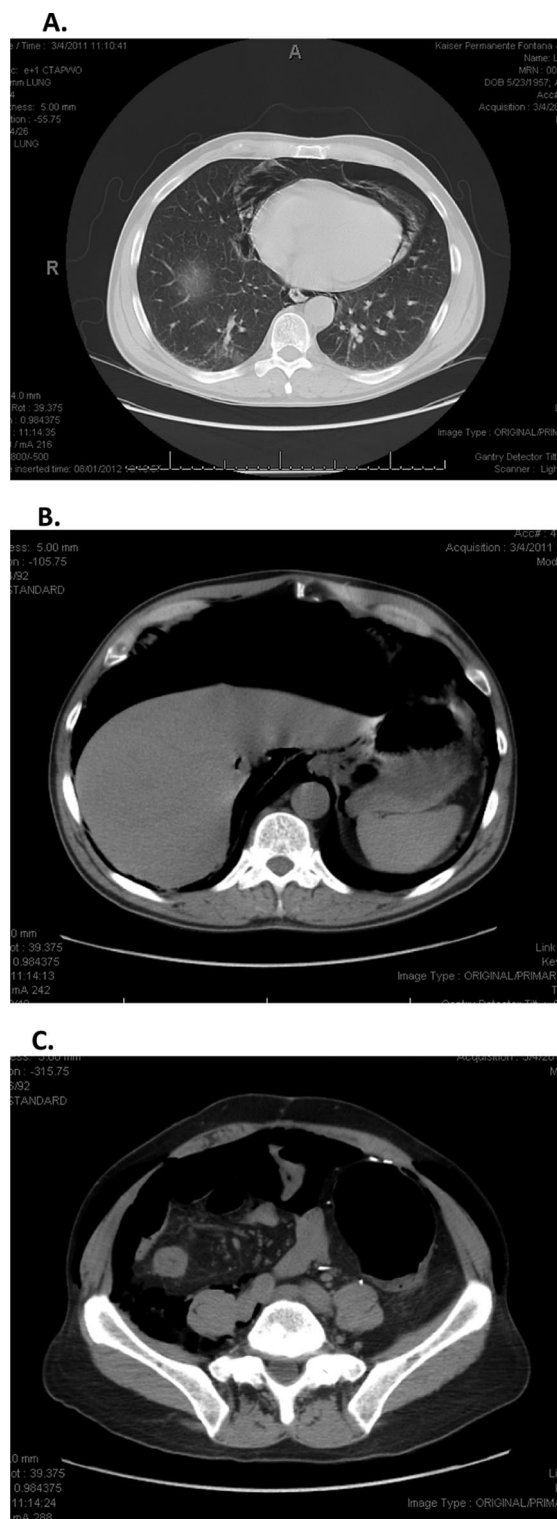


Figure 2. Computed tomography scan of chest and abdomen showing (A) pneumomediastinum and left-sided pneumothorax, (B) retroperitoneal gas, and (C) intraperitoneal and subcutaneous gas.

pies, the rate of perforation is 0.2% to 0.5%, but therapeutic colonoscopies have been reported to have a perforation rate as high as 2%.¹³ Risk factors for perforation include advanced age, female gender, diverticulosis, comorbidities, polypectomy, and the use of biopsy.¹³ The risk of pneumothorax after colonoscopy is extremely rare.¹⁴

Severe abdominal pain after a colonoscopy with pain radiating to the patient's shoulder should be carefully assessed because it could indicate perforation.¹⁵ Dismissing abdominal discomfort or distension as expected symptoms inherent to colonoscopies could delay the diagnosis and treatment of a possible perforation for several days.¹⁶ It is important to note that fewer than 50% of perforations cause symptoms during the colonoscopy procedure. In addition, the presence of nausea and vomiting after a colonoscopy with propofol, which has substantial antiemetic effects, is likely related to insufflation but could also be a sign of perforation.^{15,16} Fever and leukocytosis are other objective findings of perforation.¹⁶ Abdominal, upright radiographs are usually diagnostic of perforations, but computed tomography scan is recommended if findings are not definitive or if the presence of free air in the abdomen cannot be ruled out by radiographs alone.

There are different mechanisms whereby extraluminal air may reach the different body compartments. Maunder et al.¹⁷ described a possible mechanism for the development of subcutaneous emphysema, pneumomediastinum, and pneumothorax after bowel perforation. There are 4 compartments in the neck, thorax, and abdominal soft tissue, and they are separated by fascial planes. The pretracheal layer of the deep cervical fascia encloses the trachea and esophagus and is fused with the pericardium. It follows the esophagus into the retroperitoneal soft tissue. Thus there are potential spaces in the neck, thorax, and abdomen, and air that arises in 1 compartment might follow the potential fascial plane to another.¹⁷ This might explain the occurrence of a pneumoretroperitoneum and the resulting left-sided pneumothorax in this case.

In our case, although no perforation was visible during surgery, a microperforation might have occurred in the terminal ileum or on the right side of the colon presumably at the site at which multiple biopsy specimens were taken. However, an overt perforation is not always necessary for the development of pneumoperitoneum or pneumoretroperitoneum. Forcible herniation of the colonic mucosa may occur, such that the mucosa becomes permeable to air without an actual perforation developing.⁷ Therefore it is reasonable to postulate that the insuf-

flated air traveled extraluminally, traveled into the mesentery and then into the adjacent retroperitoneal space, and continued to travel along the tissue planes to the mediastinum, eventually rupturing the mediastinal pleura, resulting in intrapleural air causing pneumothorax. Another possible explanation is that the gas might have entered the mediastinum from the peritoneum through the small fenestrations in the diaphragm and entered the pleural space along the pressure gradient.¹⁸

Epstein¹⁹ described the etiology of perforation by 3 different mechanisms: (1) pneumatic perforation, (2) mechanical perforation, and (3) perforation associated with therapeutic colonoscopy. Pneumatic perforation results from rupture of the colon wall due to over-distension by excessive air insufflation (barotrauma). Mechanical perforation has been thought to be the cause of 32% to 63% of colonic perforations. It usually results from direct manipulation of the tip or shaft of the endoscope, which excessively pressures the intestinal lumen. For example, perforation of the colon may occur when a colonoscope is forcefully passed through sections of bowel kinked by adhesions or when passed through a diverticulum, from lateral forces of a colonoscope curving against a stretched loop of bowel, or from retroflexion of the colonoscopy. Perforation associated with therapeutic colonoscopy can be induced by any intervention involving dilation or electrocoagulation including treatment of arteriovenous malformation and, most commonly, polypectomy.

In a large literature review of colonic perforation after colonoscopy, Panteris et al.²⁰ reported that the most frequent site of perforation is the sigmoid, followed by the cecum. This predilection may be the result of the shearing forces applied during endoscope insertion and the common location of diverticula and polyps in the sigmoid colon, both of which make mechanical or thermal injury more likely in this particular area. The cecum is also well known to have a thinner muscular layer and a larger diameter of lumen than the rest of the bowel, both of which render it susceptible to either the application of current or barotrauma.²⁰

Management of colonoscopic perforation has been a somewhat controversial subject. The controversy lies in the decision between operative and nonoperative treatment. The decision on whether operative or nonoperative treatment should be used will depend on the type of injury, the quality of bowel preparation, the underlying colonic pathology, the time of diagnosis relative to the time of perforation, and most importantly, the clinical stability of the patient.²¹ Operative intervention has tradi-

tionally been considered by most surgeons as the standard treatment for iatrogenic colonoscopic perforation. Their reasoning is that failed nonoperative management will result in greater intraperitoneal contamination or soilage and inflammation, thus increasing morbidity and mortality rates.²² However, operative management has the drawbacks of a high morbidity rate, substantial mortality rate, and prolonged hospital stay. Conventional operative treatment options for colonic perforation include primary repair of the perforated bowel segment or segmental resection with either primary anastomosis or creation of a colostomy.²³ A retrospective review of 258 248 colonoscopies, performed between 1980 and 2006, found that operative repair can be safely performed in up to 67% of patients if the perforation is diagnosed within 24 hours. In contrast, primary anastomosis is successful in only 17% of patients presenting later than 24 hours, which emphasizes the importance of early recognition and treatment.²⁴ Pneumoperitoneum alone after colonoscopy is not an indication for surgery. Free air could not be shown on abdominal radiographs in 15% of patients with a compatible clinical picture or operatively verified perforation. Similarly, there were patients with intraperitoneal air shown radiographically but no signs of peritoneal irritation who were managed nonoperatively with good results.²⁵

In contrast to operative correction, nonoperative management has been described for selected patients. A retrospective review of 134 383 colonoscopies found that the mortality rate was 3 times higher for patients who underwent surgery for perforation compared with those who received nonoperative treatment.²⁶ Nonoperative management of colonic perforation is usually reserved for perforations after interventions with adequate bowel preparation in stable patients with no signs of peritonitis and symptomatic improvement within 24 hours.^{15,25,26} Generally, it is accepted that patients fulfilling these criteria can be treated nonoperatively with bowel rest, intravenous antibiotics, and close observation, every 3 to 6 hours.²⁷

Our patient underwent bowel preparation and was hemodynamically stable, but the extent of pneumoperitoneum, pneumoretroperitoneum, and subcutaneous emphysema raised the suspicion for a large colonic perforation with potential contamination, thus justifying the need for an operative approach. Furthermore, perforations that occur during therapeutic interventions, such as polypectomy, are more likely to be small and localized, and they are often sealed by the adhesion of pericolic fat, omentum, or adjacent viscera. In contrast, injuries occurring during di-

Table 1.
Cases of Combined Intraperitoneal and Extraperitoneal Colonic Perforation After Colonoscopy

Author, Year	Type of Procedure	Colonic Perforation	Site	Pneumothorax	Treatment
Ho and Burchell, ⁷ 1996	Therapeutic	Yes	Cecum	Yes	Surgical
Cirt et al., ⁸ 2006	Therapeutic	Yes	Rectum	Yes	Surgical
Marwan et al., ⁹ 2007	Diagnostic	Yes	Unknown	Yes	Conservative
Lovisetto et al., ¹¹ 2007	Diagnostic	Yes	Sigmoid	Yes	Surgical
Chan et al., ¹⁰ 2010	Therapeutic	Unknown	Unknown	Yes	Conservative
Kipple, ¹² 2010	Therapeutic	Yes	Sigmoid	Yes	Surgical
Current study, 2013	Diagnostic	Unknown	Unknown	Yes	Surgical

agnostic endoscopic procedures are often caused by the maneuvering of an instrument through a tortuous or tethered bowel, resulting in longitudinal tears of the antimesenteric wall that are unlikely to heal on their own.¹⁸

To date, there have been only 7 cases, including ours, of combined intraperitoneal and extraperitoneal colonic perforation after colonoscopy (**Table 1**). Some trends merit mention. Four of the seven cases occurred after therapeutic colonoscopy. Pneumothorax developed in all case with air dissection through the mediastinum, presumably from the retroperitoneum being the underlying mechanism. The sigmoid colon was the site of the perforation in 2 cases, whereas perforation occurred in the cecum in 1 case and in the rectum in another case. The site of perforation was unknown in 3 cases, including our patient. Treatment was operative in 5 cases and nonoperative in 2.

In summary, we described a case of colonic perforation that presented with both intraperitoneal and extraperitoneal perforation after diagnostic colonoscopy was performed and multiple biopsy specimens were obtained in a patient with Crohn disease. Pneumothorax, pneumomediastinum, and subcutaneous emphysema were also evident on imaging. In this case perforation was not clearly identified during surgery; however, we believe the perforation, if any, most likely occurred in the terminal ileum because this is where a deep ulcer was identified on colonoscopic examination and multiple biopsy specimens were taken. In addition, this was the site at which all of the retroperitoneal air was located. The rates of morbidity and mortality after a perforation are considerable and must prompt endoscopists to take effective measures to avoid them. Knowledge of the risk factors, adoption of preventive actions, early recognition of signs and symptoms, and an adequate management plan are essential tools for defending patient health and medical professional integrity. In this case the patient was well prepared for colonos-

copy, he was operated on quickly after the perforation, and the outcome was satisfactory.

References:

1. Levin BL, McFarland DA, Smith B, et al. Screening and surveillance for the early detection of colorectal cancer and adenomatous polyps: a joint guideline from the American Cancer Society, the US Multi-Society Task Force on Colorectal Cancer, and the American College of Radiology. *CA Cancer J Clin.* 2008;58:130–160.
2. Seeff LC, Richards TB, Shapiro JA, et al. How many endoscopies are performed for colorectal cancer screening? Results from CDC's survey of endoscopic capacity. *Gastroenterology.* 2004;127:1670–1677.
3. Phillips KA, Liang SY, Ladabaum U, et al. Trends in colonoscopy for colorectal cancer screening. *Med Care.* 2007;45:160–167.
4. Brayko CM, Kozarek RA, Sanowski RA, et al. Diverticular rupture during colonoscopy: fact and fancy. *Dig Dis Sci.* 1984; 29:427–431.
5. Ignjatović M, Jović J. Tension pneumothorax, pneumoretroperitoneum, and subcutaneous emphysema after colonoscopic polypectomy: a case report and review of the literature. *Langenbecks Arch Surg.* 2009;394:185–189.
6. Park NS, Choi JH, Lee DH, et al. Pneumoretroperitoneum, pneumomediastinum, pneumopericardium, and subcutaneous emphysema after colonoscopic examination. *Gut Liver.* 2007;1: 79–81.
7. Ho H, Burchell S. Colon perforation, bilateral pneumothoraces, pneumopericardium, pneumomediastinum, and subcutaneous emphysema complicating endoscopic polypectomy: anatomic and management consideration. *Am Surg.* 1996;62: 770–774.
8. Cirt N, de Lajarte-Thirouard AS, Olivié D, et al. Subcutaneous emphysema, pneumomediastinum, pneumoperitoneum and ret-

- ropneumoperitoneum following a colonoscopy with mucosectomy. *Gastroenterol Clin Biol*. 2006;30:779–782.
9. Marwan K, Farmer KC, Varley C, Chapple KS. Pneumothorax, pneumomediastinum, pneumoperitoneum, pneumoretroperitoneum and subcutaneous emphysema following diagnostic colonoscopy. *Ann R Coll Surg Engl*. 2007;89:W20–W21.
10. Chan YC, Tsai YC, Fang SY. Subcutaneous emphysema, pneumothorax, pneumomediastinum, and pnemoperitoneum during colonoscopic balloon dilatation: a case report. *Kaohsiung J Med Sci*. 2010;26:669–671.
11. Lovisetto F, Zonta S, Rota E, et al. Left pneumothorax secondary to colonoscopic perforation of the sigmoid colon: a case report. *Surg Laparosc Endosc Percutan Tech*. 2007;17:62–64.
12. Kipple JC. Bilateral tension pneumothoraces and subcutaneous emphysema following colonoscopic polypectomy: a case report and discussion of anesthesia considerations. *AANA J*. 2010;78:462–467.
13. Wayne JD. Colonoscopy. *CA Cancer J Clin*. 1992;42:350–365.
14. Zeno BR, Sahn SA. Colonoscopy-associated pneumothorax: a case of tension pneumothorax and review of the literature. *Am J Med Sci*. 2006;332:153–155.
15. Weber DJ, Rodney WM, Warren J. Management of suspected perforation following colonoscopy: a case report. *Fam Pract*. 1993;36:567–571.
16. Kavic SM, Basson MD. Complications of endoscopy. *Am J Surg*. 2001;181:319–332.
17. Maunder RJ, Pierson DJ, Hudson LD. Subcutaneous and mediastinal emphysema, pathophysiology diagnosis and management. *Arch Intern Med*. 1984;144:1447–1453.
18. Baumann UA, Nettler M. Diagnosis and hazards of unexpected diaphragmatic hernia during colonoscopy: reports of two cases. *Endoscopy*. 1999;31:274–276.
19. Epstein O. Guidelines on complications of gastrointestinal endoscopy: complications of colonoscopy. November 2006. Available at: www.bsg.org.uk/pdf_word_docs/complications.pdf. Accessed March 22, 2013.
20. Panteris V, Haringsma J, Kuipers EJ. Colonoscopy perforation rate, mechanisms and outcome: from diagnostic to therapeutic colonoscopy. *Endoscopy*. 2009;41:941–951.
21. Vincent M, Smith LE. Management of perforation due to colonoscopy. *Dis Colon Rectum*. 1983;26:61–63.
22. Soon JC, Shang NS, Goh PM, Rauff A. Perforation of the large bowel during colonoscopy in Singapore. *Am Surg*. 1990;56:285–288.
23. Teoh AY, Poon CM, Lee JF, et al. Outcomes and predictors of mortality and stoma formation in operative management of colonoscopic perforations: a multicenter review. *Arch Surg*. 2009;144:9–13.
24. Iqbal CW, Chun YS, Farley DR. Colonoscopic perforations: a retrospective review. *J Gastrointest Surg*. 2005;9:1229–1235.
25. Wayne JD, Kahn O, Auerbach ME. Complications of colonoscopy and flexible sigmoidoscopy. *Gastrointest Endosc Clin N Am*. 1996;6:343–377.
26. Hall C, Dorricott NJ, Donovan IA, Neoptolemos JP. Colon perforation during colonoscopy: operative versus non-operative management. *Br J Surg*. 1991;78:542–544.
27. Lo AY, Beaton HL. Selective management of colonoscopic perforations. *J Am Coll Surg*. 1994;179:333–337.