



Review Article

Corresponding Author

Nobuyuki Shimokawa

<https://orcid.org/0000-0003-3353-6496>

Department of Neurosurgery, Tsukazaki Hospital, 68-1 Waku, Aboshiku, Himeji, Hyogo 671-1227, Japan

E-mail: nobu-shimo0215@snow.odn.ne.jp

Received: July 14, 2020

Revised: August 26, 2020

Accepted: August 28, 2020



This is an Open Access article distributed under the terms of the Creative Commons Attribution Non-Commercial License (<https://creativecommons.org/licenses/by-nc/4.0/>) which permits unrestricted non-commercial use, distribution, and reproduction in any medium, provided the original work is properly cited.

Copyright © 2020 by the Korean Spinal Neurosurgery Society

Complex Revision Surgery for Cervical Deformity or Implant Failure

Nobuyuki Shimokawa¹, Hidetoshi Sato¹, Hiroaki Matsumoto¹, Toshihiro Takami²

¹Department of Neurosurgery, Tsukazaki Hospital, Hyogo, Japan

²Department of Neurosurgery, Osaka City University Graduate School of Medicine, Osaka, Japan

Postoperative cervical deformity sometimes occurs in the short or long term after primary surgery for cervical disorders related to the degenerative aging spine, neoplastic etiologies, hemodialysis, infection, inflammation, trauma, etc. Cervical kyphosis after posterior decompression surgery, such as laminectomy or laminoplasty, is a common problem for spine surgeons. However, revision surgery for cervical deformity is definitely one of the most challenging areas for spine surgeons. There is no doubt that surgery for cervical deformity carries a high risk of surgery-related complications that might result in aggravation of health-related quality of life. Revision surgery is even more challenging. Hence, spine surgeons need to assess carefully the overall severity of the underlying condition before revision surgery, and try to refine the surgical strategy to secure safe surgery. Needless to say, spine surgeons are now facing great challenges in making spine surgery a much more reliable and convincing entity.

Keywords: Cervical deformity, Cervical spine, Destructive spondyloarthropathy, Implant failure, Kyphosis, Revision surgery

INTRODUCTION

Postoperative cervical deformity sometimes occurs in the short or long term after primary surgery for cervical disorders related to the degenerative aging spine, neoplastic etiologies, hemodialysis, infection, inflammation, or trauma, although the prevention of primary surgical failure or the proper correction method is truly important to achieve the successful outcome in the surgery of cervical spine. Cervical kyphosis after posterior decompression surgery, such as laminectomy or laminoplasty, is a common problem for spine surgeons. Loss of the posterior cervical tension band with or without iatrogenic injury to cervical back muscles or facet joints might lead to a progressively increasing compression force on the anterior vertebral body of the cervical spine, ultimately resulting in cervical kyphosis.¹ The needs for corrective revision surgery for cervical deformity are still unclear, although the technical difficulties involved in such procedures should be noted. Surgical strategies include direct decompression of the spinal cord, correction of the deformity, or both, using anterior, posterior, or combined circumferential

approaches.²⁻⁶ In this review article, the rationale behind complex revision surgery for cervical deformity secondary to several etiologies are discussed using illustrative cases (Table 1).

INDICATIONS FOR REVISION SURGERY FOR CERVICAL DEFORMITY AND RADIOLOGICAL SAGITTAL PARAMETERS WITH CERVICAL BIOMECHANICAL IMPLICATION

The surgical indications for revision surgery involving the cervical spine have not been determined. There is little evidence in previously reported literature, and the decision-making process might depend much on the judgment of the individual surgeon. Papavero et al.⁷ retrospectively studied 102 patients who underwent cervical revision surgery at their 2 centers. A total of 107 surgeries was performed. They classified the indications for cervical revision surgery into 5 categories: (1) adjacent segmental disease (ASD), (2) infection, (3) implant failure, (4) noninfectious complications, and (5) deformity. Only 3 patients

(3%) required cervical revision surgery for postoperative cervical deformity, whereas the most frequent indication for cervical revision surgery was postoperative ASD (40%), followed by infection (23%) and implant failure (22%). The primary surgery causing postoperative deformity included cervical laminectomy in 2 patients and circumferential fusion of C3–7 in 1 patient. Patients who develop cervical deformity after the primary procedure might develop severe neck pain related to mechanical malfunction of the cervical spine, cervical myelopathy, and finally, decreasing health-related quality of life (HRQoL).⁸ Progressive cervical kyphosis might lead to gradual compression of the spinal cord against the posterior surface of the vertebral body, resulting in cervical myelopathy. The spinal cord is compressed most intensely at the apex of the cervical kyphosis.

Table 1. Common etiologies of failure after primary cervical surgery requiring the revision surgery

- Insufficient decompression
- Progressive deformity (kyphosis)
- Significant instability after decompression
- Adjacent segmental disease
- Local infection early or late after primary surgery
- Implant-related complication: pseudoarthrosis
- Implant-related complication: hardware trouble
- Miscellaneous

Diagnosis in such cases is based on spinal imaging parameters, including sagittal or coronal parameters of the spine, such as local angle at the index level, C2–7 angle, C2–7 sagittal vertical axis (SVA), cervical tilt angle, and chin-brow vertical angle (Fig. 1). Biomechanical studies have suggested that the anterior vertebral body supports only 36% of cervical load, with the remaining 64% being supported by the posterior column.^{9,10} The center of cranial gravity is situated at the middle of the nasion-inion line, behind the sella turcica, above and slightly in front of the external auditory meatus.¹¹ In cases with lordotic cervical spines, the instantaneous axes of rotation (IAR) of the cervical spine are situated posteriorly in the vertebral body; however, in case of cervical kyphosis, the IAR of the cervical spine might shift significantly anterior to the vertebral body.^{12–14} The center of cranial gravity or IAR of the cervical spine might shift more anteriorly with structural fatigue in the posterior tension band and cervical back muscles. Thoracic inlet angle (TIA), a constant morphological parameter that is not influenced by posture, is defined as the angle formed by intersection of the line perpendicular to the center of the T1 upper endplate and the superior anterior sternum. As a measure of the influence of posture, T1 slope is defined as the angle formed between a horizontal line and the T1 upper endplate. Neck tilt is defined as the angle formed by a vertical line passing through the superior anterior sternum and the line connecting the center of the T1 upper endplate with the superior anterior sternum. T1 slope

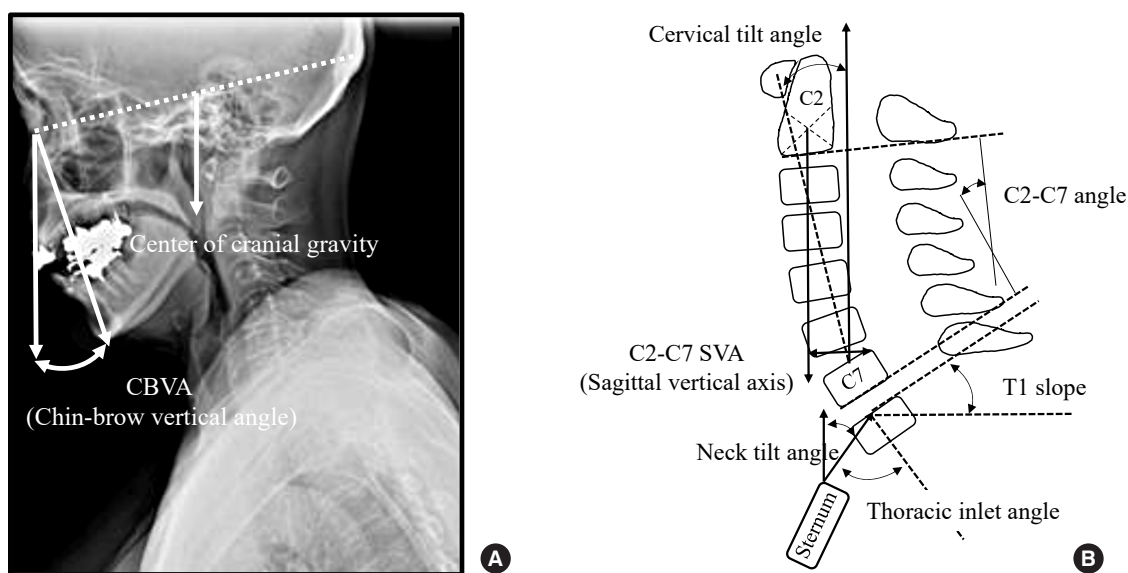


Fig. 1. Radiological assessment of cervical sagittal alignment. (A) Cranial center of gravity and position. (B) Radiological parameters of cervical sagittal alignment. SVA, sagittal vertical axis.

and TIA for cervical sagittal balance may be as important as pelvic incidence about lumbar lordosis. C2–7 SVA has also been suggested to correlate positively with Neck Disability Index scores. As the T1 slope increases, so does C2–7 lordosis to maintain forward gaze, resulting in a greater degree of lordotic curvature. Similarly, C2–7 SVA tends to increase as T1 slope increases. Because T1 slope indicates a compensatory change related to thoracolumbar sagittal imbalance, we should take global sagittal balance into consideration along with cervical sagittal alignment. Compensatory mechanisms of the thoracic spinal curve have been reported to become insufficient when the T1

slope is $>25^\circ$. Harmony between the cervical spine and global sagittal alignment is a critical issue for patient satisfaction and maintenance of the HRQoL.¹⁵⁻¹⁸ Ames et al.¹⁹ developed a novel classification system for cervical deformity based on an extensive review of the literature, using an expert panel to modify the Delphi approach. This classification system included a deformity descriptor and 5 modifiers incorporating sagittal, regional and global spine alignments, and neurological condition. This proposed classification is helpful for spine surgeons to assess cervical deformity within the framework of global spine alignment and clinical parameters (Table 2).

Table 2. Classification of cervical deformity as proposed by Ames et al.¹⁹

Classification	Description
Deformity descriptor	
C	Primary sagittal deformity apex in the cervical spine
CT	Primary sagittal deformity apex at the cervico-thoracic junction
T	Primary sagittal deformity apex in the thoracic spine
S	Primary coronal deformity (C2–7 Cobb angle $\geq 15^\circ$)
CVJ	Primary cranio-vertebral junction deformity
Modifiers	
C2–7 sagittal vertical axis	
0	C2–7 sagittal vertical axis < 4 cm
1	C2–7 sagittal vertical axis = 4–8 cm
2	C2–7 sagittal vertical axis > 8 cm
Horizontal gaze	
0	Chin-brow vertical angle = 1° – 10°
1	Chin-brow vertical angle = -10° – 0° or 11° – 25°
2	Chin-brow vertical angle = $< -10^\circ$ or $> 25^\circ$
T1 slope minus C2–7 lordosis	
0	T1 slope - C2–7 lordosis $< 15^\circ$
1	T1 slope - C2–7 lordosis = 15° – 20°
2	T1 slope - C2–7 lordosis $> 20^\circ$
Myelopathy based on modified JOA score	
0	Normal
1	Mild
2	Moderate
3	Severe
Scoliosis Research Society-Schwab classification	
Coronal curve $> 30^\circ$	Thoracic only, thoracolumbar/lumbar only, double curve or no coronal curve
PI minus LL mismatch	0: $< 10^\circ$; +: 10° – 20° ; ++: $> 20^\circ$
C7–S1 SVA	0: < 4 cm; +: 4–9.5 cm; ++: > 9.5 cm
Pelvic tilt	0: $< 20^\circ$; +: 20° – 30° ; ++: $> 30^\circ$

JOA, Japanese Orthopaedic Association; PI, pelvic incidence; LL, lumbar lordosis; SVA, sagittal vertical axis.

REVISION SURGERY FOR CERVICAL KYPHOSIS AFTER LAMINOPLASTY OR LAMINECTOMY

Posterior cervical surgery might be associated with denervation and atrophic changes in cervical back muscles and malfunction of facet joints of the cervical spine. Destruction of the facet joint capsule of the cervical spine and the extent of laminectomies and laminoplasties might all be significantly related to the occurrence of postoperative kyphosis, especially in pediatric patients (Fig. 2).²⁰⁻²³ The exact incidence of postoperative kyphosis after multilevel cervical laminoplasty or laminectomy is still unclear, although it has been suggested that laminoplasty has a lower risk of postoperative kyphosis compared to laminectomy. Kaptain et al.²² studied 46 patients with cervical spondylotic myelopathy (CSM) who underwent laminectomy. Postoperative cervical alignment was assessed using cervical x-rays. Cervical kyphosis developed in up to 21% of patients during the 4-year follow-up period, although 36 patients (80%) believed that their initial surgery was successful. Machino et al.²⁴ studied a total of 520 patients who underwent cervical laminoplasty for CSM. The average follow-up period was 33.3 months. They demonstrated that sagittal alignment was slightly altered after surgery, with only 1.8° increase in lordosis. Range of motion (ROM) of the cervical spine was well preserved in the majority of patients (87.9%). They suggested the importance of postoperative care in avoiding progression of the cervical de-

formity or mechanical limitation of the cervical ROM. On the other hand, posterior cervical surgery using a muscle preserving technique might be extremely beneficial in avoiding cervical deformity after surgery. Shiraishi et al.²⁵ developed their technique of cervical skip laminectomy that is less invasive to the posterior muscles of the cervical spine. They demonstrated that there was no significant difference between preoperative and postoperative cervical curvature index in patients who underwent cervical skip laminectomy.

Preoperative cervical alignment has been shown to be an important predictor of postoperative kyphotic deformity. Knott et al.²⁶ reported that the T1 slope was the greatest predictor of C2–7 SVA, and they recommended evaluation of full standing radiographs when T1 slope is less than 13° or more than 25°. They also recommended the use of C2 global SVA instead of the standard C7 SVA, because C2 SVA was found to be larger than C7 SVA, and it takes into account the position of the head. Kim et al.²⁷ investigated the relationship between preoperative angle of the T1 slope and postoperative cervical sagittal alignment in patients who underwent cervical laminoplasty for myelopathy (none of the patients had preoperative cervical kyphosis). The patients were divided into 2 groups based on the preoperative angle of the T1 slope: high (26.5° to 43.9°) and low (15.4° to 26.3°), based on the 50th percentile. They reported that postoperative cervical kyphosis occurred twice more often (15.4% vs. 8.0%) in patients with high preoperative T1 slope, although preoperative cervical alignment was more lordotic in patients with a high T1 slope. A T1 slope higher than 25° might be associated with at least 10 cm of positive sagittal imbalance. T1 slope might thus be a compensatory change related to thoracolumbar sagittal imbalance. There is also increasing recognition of the complex interactions between global sagittal curves and the pelvis, and compensatory mechanisms that attempt to maintain global sagittal spinopelvic alignment. Some papers have described reciprocal changes in cervical spine alignment after corrective thoracolumbar deformity.^{28,29}

More careful assessments should be performed in pediatric patients. Since the incompletely ossified vertebral bodies in children offer poor resistance to compressive forces, they are more prone to developing wedge deformity and progressive loss of sagittal balance postoperatively. Yasuoka et al.³⁰ suggested that cervical kyphosis can develop after multilevel laminectomy in pediatric patients without irradiation of the local cervical spine or facet injury. Anakwenze et al.³¹ retrospectively analyzed the clinical data of 255 children with spinal cord tumors. Of these 255 pediatric patients, 52 patients with a biopsy-proven intramedullary

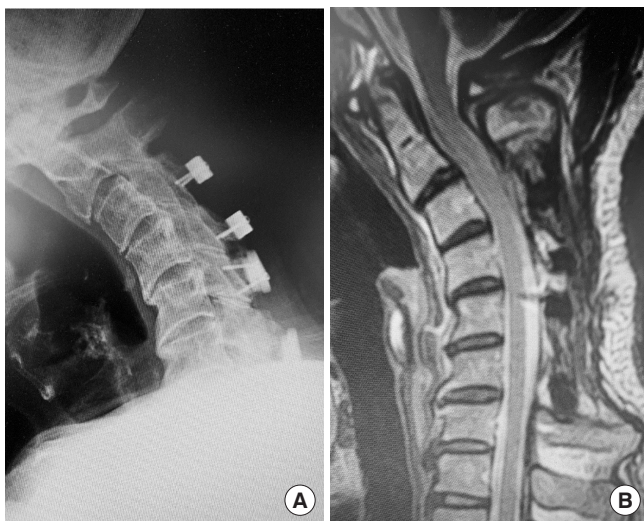


Fig. 2. Illustrative case of cervical kyphosis after cervical laminoplasty. (A) Plain lateral x-ray, (B) T2-weighted sagittal magnetic resonance image.

spinal cord tumor had complete clinical data. These patients included 18 females and 34 males with an average age of 8.1 years. The average time to latest follow-up was 7.6 years. Moderate or severe deformity of the cervical spine (scoliosis $>25^\circ$ and/or sagittal kyphosis angle $>20^\circ$) was noted in 21 of 37 patients (57%) who underwent laminectomy or laminoplasty alone but in 4 of 15 patients (27%) who underwent fusion surgery. Removal of more than 3 laminae was associated with development of postoperative deformity of the cervical spine in these pediatric patients. Thus, prophylactic measures against the development of this complication in pediatric patients need to be investigated in greater detail. Spinal fusion at the time of spinal cord tumor excision might be considered an option to prevent postoperative deformity of the cervical spine in pediatric patients.

REVISION SURGERY FOR POSTOPERATIVE IMPLANT FAILURE

Implant failure after primary surgery of the cervical spine is another big concern for spine surgeons. Implant failure might include conditions such as subsidence, dislocation, migration or breakage of the implant itself, osteolysis, anterior bone loss or vertebral fracture at the local or adjacent segment, local kyphosis, infection, and pseudoarthrosis, sometimes resulting in a serious situation that requires revision surgery.^{7,32-35} Although spine surgeons are trying to avoid the postoperative implant failure in the primary surgery, the possible risk for it cannot be ignored. Revision surgery might be required in cases of pseudoarthrosis, ASD, inadequate decompression of the spinal cord or nerve root, iatrogenic segmental instability, or significant deformity of the cervical spine after primary surgery.³³ However, revision surgery is expected to be technically more demanding

than the primary surgery, and appropriate surgical indications and planning are necessary for safe surgery.

Deen et al.³² performed a prospective study of early complications of posterior rod-screw fixation of the cervical and upper thoracic spine. A total of 888 screws were placed in 100 patients. Perioperative complications included radiculopathy in 4 patients (0.45% per screws), infection and wound complications in 4 patients, screw malposition in 2 patients, loss of alignment in 1 patient, and cerebrospinal fluid leakage in 1 patient. Early complications related to implant failure included pseudoarthrosis ($n=2$: 0.22% per screw placed) and screw breakage ($n=2$: 0.22% per screw placed). Revision surgery was performed in 8 of the 100 patients (8%). Okamoto et al.³⁴ analyzed 142 consecutive patients who underwent posterior cervical fusion using either cannulated Magerl screws or a multiaxial pedicle screw-rod system. Implant failure was recognized in 6 of the 142 patients (4.2%): 5 with rheumatoid arthritis and 1 with athetoid cerebral palsy (CP). Implant failure included occipital plate, cervical pedicle or Magerl screw breakage and disconnection of the screw-rod system, although there was no rod fracture in their study. Implant failure was recognized from 1 month to 42 months after surgery. One study suggested that when surgeons plan to perform revision surgery, they must consider the cause of the underlying problem.³⁵ Although there has been a clear consensus of surgical indication or technical options for revision surgery for the cervical spine, it is absolutely mandatory for surgeons to examine the following points: (1) the patient's clinical history, including details of previous cervical surgeries, (2) general physical condition of the patient, including comorbidities, (3) laboratory data, (4) imaging results, and (5) availability of postoperative support, since the revision surgery is expected to carry a significantly higher risk of perioperative complications

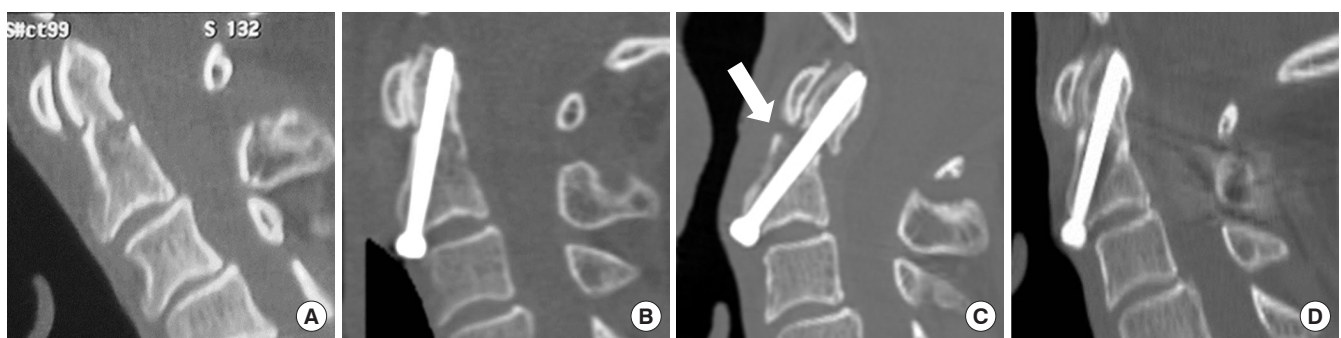


Fig. 3. Illustrative case of revision surgery for postoperative pseudoarthrosis. (A) Cervical computed tomography (CT) before surgery. (B) Cervical CT after the primary surgery of anterior odontoid screw fixation. (C) Cervical CT at 6 months after primary surgery. Arrow indicates the pseudoarthrosis. (D) Cervical CT after revision surgery of posterior C1–2 fixation demonstrating complete osseous fusion.

than the primary surgery.

1. Illustrative Case of Revision Surgery for Postoperative Pseudoarthrosis After Anterior Screw Fixation for Odontoid Fracture

A 67-year-old man suffered from severe neck pain after a fall. Cervical computed tomography (CT) demonstrated an Anderson type 2 odontoid fracture (Fig. 3A), for which anterior screw fixation was performed. The patient had an uneventful postoperative course, and cervical CT performed soon after surgery demonstrated successful osteosynthesis (Fig. 3B). However, the patient complained of severe neck pain about 6 months after the initial surgery. Cervical CT at this time showed clear evidence of pseudoarthrosis (Fig. 3C), for which revision surgery of posterior C1–2 fixation was performed. Cervical CT late after revision surgery demonstrated successful osseous fusion at the odontoid process (Fig. 3D).

REVISION SURGERY FOR DESTRUCTIVE SPONDYLOARTHROPATHY RELATED TO HEMODIALYSIS

Destructive spondyloarthropathy (DSA) related to hemodialysis is generally attributed to deposition of beta-2-microglobulin and amyloid in the synovial structures of the spine.^{36,37} DSA is usually recognized mainly at the C5–7 cervical spine level due to greater mechanical stress at this level.^{38,39} In previous studies, mean age at surgery for DSA was 57 years. The average duration of hemodialysis before surgery was estimated as 13.5–14.9 years. Two-thirds of patients were male and one-third were fe-

male.^{39,40} Patients with DSA usually have numerous comorbidities, such as hypertension, bleeding tendencies, diabetes, and its associated conditions, cardio-pulmonary disorders, cerebrovascular diseases. Patients with DSA are also reported to have a statistically higher incidence of osteoporosis and lower bone mineral density.⁴¹ Maruo et al.^{42,43} proposed a radiological classification of DSA, in which progression of destructive changes is classified into 4 stages: stage 0, no change; stage 1, marginal erosion; stage 2, endplate erosion and disc space narrowing; and stage 3, spontaneous fusion (Fig. 4). The types of destructive changes are classified into 3 types. Type A is defined as destructive kyphosis, type B as spondylolisthesis, and type C as epidural amyloidosis, including extradural amyloid deposits or hypertrophied ligaments (Fig. 5).^{42,43} Types A and B can be evaluated by plain lateral radiographs, whereas type C should be

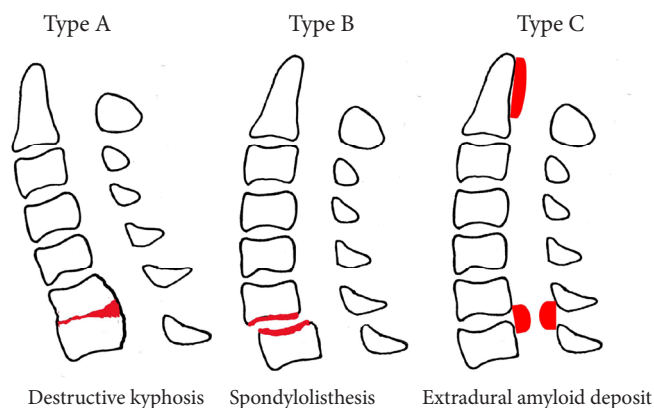


Fig. 5. Schematic drawing of the type of destructive spondyloarthropathy, as proposed by Maruo et al.^{42,43}

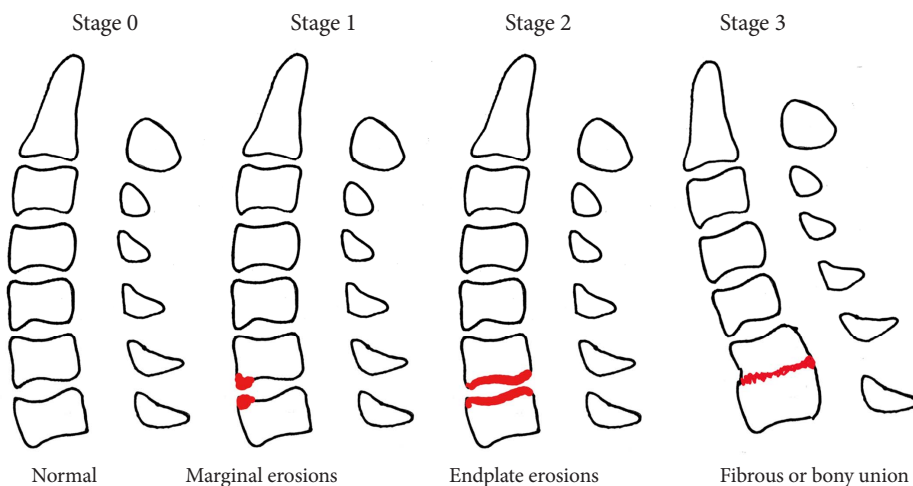


Fig. 4. Schematic drawing of the classification of progression of destructive spondyloarthropathy, as proposed by Maruo et al.^{42,43}

evaluated by magnetic resonance (MR) images.

The optimal surgical management of cervical DSA in patients with long-term hemodialysis is still unclear. Surgical fusion of the cervical spine in patients with DSA is usually challenging because of the high risk of osteoporosis, resulting in hardware failure and instability. Sudo et al.⁴⁴ examined patients on long-term hemodialysis who underwent cervical spine fusion. Their study reported that 40% of patients required subsequent surgery to extend the length of the instrumentation due to adjacent level disease. They noted that the considerable mismatch between construct stiffness and osteoporotic bone resulted in additional stress on adjacent segments. They also suggested that the facet joint components were often severely osteoporotic, and cervical pedicles maintained the integrity of the cervical spine. Surgical treatment options for cervical DSA include anterior decompression and fusion, posterior decompression alone, posterior decompression and fusion, and circumferential decompression and fusion, as with other cervical deformities. There have been many reports of hardware failure and the need for revision surgery after anterior corpectomy or discectomy and fusion due to fragility of the bones in dialysis patients.⁴⁵⁻⁴⁷ In addition, invasive surgical procedures might increase the risk of postoperative complications and mortality in patients on long-term hemodialysis who have multiple comorbidities and poor health condition. Chikuda et al.⁴⁸ reported that dialysis-depend-

ent patients had a 10-fold higher risk of in-hospital mortality. Therefore, cervical deformity surgery, including revision for DSA, requires not only a trained expert spine surgeon, but also a medical team for perioperative management of the patient's comorbidities, including hemodialysis.

1. Illustrative Case of Revision Surgery for Cervical DSA

A 40-year-old man who underwent hemodialysis for more than 15 years presented with gait disturbances due to acute deterioration of cervical myelopathy. Preoperative cervical x-rays demonstrated multilevel stage 0 and type C DSA at C2/3, C4/5, and C5/6 (Fig. 6A). Cervical laminoplasty was performed from C3 to C6 with C2 dome laminectomy (Fig. 6B). Cervical x-ray obtained 4 years after the surgery showed progressive DSA (from stage 0 to stage 2) at C4/5, although his postoperative course was stable. However, the patient complained of severe neck pain about 10 years after the initial surgery. Cervical x-ray showed more advanced changes with cervical kyphosis (stage 3 at C4/5 and type A at C4/5/6) (Fig. 6C). MR images showed progression of a retro-odontoid pseudotumor with destructive changes in the lateral atlantoaxial joint on the right side (Fig. 7A). Posterior cervical fusion was finally performed using an occipital plate, occipital condyle screw and C1 lateral mass, and subaxial pedicle screws (Fig. 6D). The patient's symptoms, including severe neck pain, decreased immediately after the revision sur-

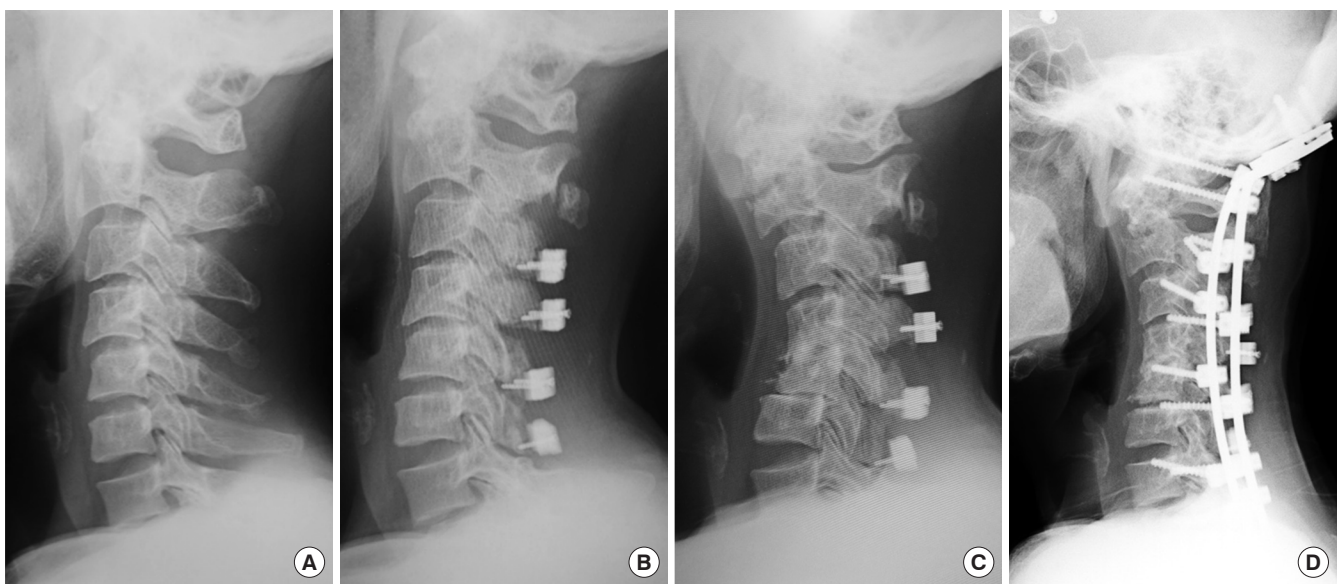


Fig. 6. Illustrative case of revision surgery for cervical destructive spondyloarthropathy. (A) Lateral cervical x-ray before surgery. (B) Lateral cervical x-ray after primary surgery of cervical laminoplasty. (C) Lateral cervical x-ray at 4 years after the primary surgery. (D) Lateral cervical x-ray after the revision surgery of posterior occipital-cervical fixation showing correction of cervical kyphosis.

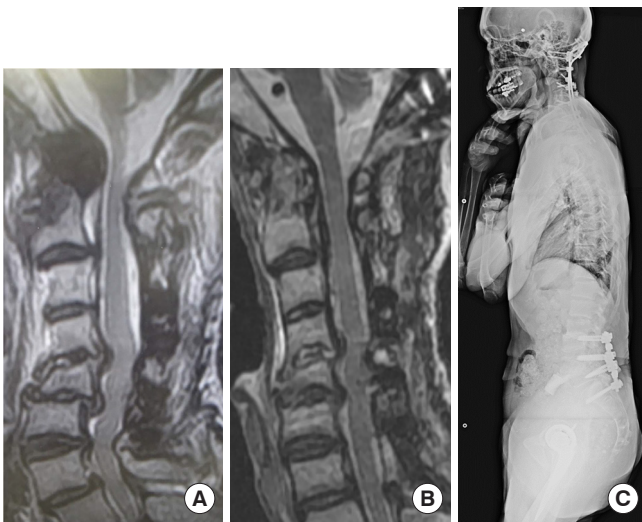


Fig. 7. Illustrative case of revision surgery for cervical destructive spondyloarthropathy (same patient as in Fig. 6). (A) T2-weighted sagittal magnetic resonance (MR) images at 10 years after the primary surgery demonstrating retro-odontoid pseudotumor. (B) T2-weighted sagittal MR images obtained 3 years after the revision surgery demonstrating significant reduction of the retro-odontoid pseudotumor. (C) Whole spine x-ray demonstrating global sagittal harmony.

gery. MR images obtained 3 years after the revision surgery demonstrated significant reduction of the retro-odontoid pseudotumor (Fig. 7B) and radiographs showed no apparent correction loss with no instrumentation failure and maintenance of global sagittal balance (Fig. 7C).

AVOIDANCE OF REVISION SURGERY IN CERVICAL SPONDYLOTIC MYELOPATHY PATIENTS ASSOCIATED WITH ATHETOID CEREBRAL PALSY

Cervical spine surgery in CSM patients with associated athetoid CP is much more complex and difficult, making it a challenging surgery. The involuntary head and neck movements associated with athetoid CP result in progressive multi-intervertebral instabilities, kyphosis, and flexion myelopathy, which can cause severe cervical myelopathy. Additionally, the degree of involuntary neck movement varies from patient to patient, and changes depending on psychogenic stress or emotional changes, such as pain. In patients with mild involuntary neck movements without intervertebral instability and cervical kyphosis, laminoplasty might be indicated. However, in patients with severe involuntary neck movements and cervical kyphosis, corrective cervical fixation with decompression of the spinal cord

and nerve roots needs to be performed. Although postoperative halo-vest orthosis has been recommended to obtain osseous stability at the fixation sites, various complications related to halo-vest orthosis in patients with CP have been reported.^{49,50} Recently, combination use of botulinum toxin^{51,52} and/or muscle release techniques⁵⁰ have been recommended to perioperatively control the involuntary neck movements. Onari et al.⁴⁹ reported a 25% incidence of atlantoaxial subluxation after anterior and posterior combined fusion for subaxial lesions at a minimum of 5-year follow-up. Demura et al.⁵³ reported adjacent segment instability in 17.6% of patients (3 of 17 cases) after posterior decompression and fixation using pedicle screws for CSM associated with athetoid CP. Watanabe et al.⁵⁴ also reported the clinical outcomes after posterior spinal fusion using cervical pedicle screw constructs for CSM associated with athetoid CP. In their study, 6 of 31 patients (19.4%) demonstrated nonunion: at the uppermost instrumented vertebral level in 4 patients and lowermost instrumented vertebral level in 3 patients (1 patient showed nonunion at both locations). This suggests that surgeons must pay critical attention to avoidance of implant failure or pseudoarthrosis in surgeries for CSM associated with athetoid CP, especially in patients with severe involuntary neck movements and cervical kyphosis.

1. Illustrative Case of Revision Surgery for Postoperative Occipital Bone Erosion After Posterior Cervical Fixation

A 56-year-old man with athetoid CP suffered from gradual worsening of tetraparesis. Cervical x-ray and MR images demonstrated multilevel stenosis with cervical kyphosis (Figs. 8A, 9A). The patient underwent combined surgery of anterior discectomy and fusion at C4/5, followed by posterior cervical screw fixation using cervical pedicle screws with iliac bone grafting between C1–2 using the McGraw method (Fig. 8B). His postoperative course was uneventful. However, since screw loosening at the lower level (Th2) was recognized 6 months after the surgery, the fusion level was extended down to Th4 with sublaminar taping. The patient complained of severe local pain around the occipital area 1 year after the second surgery. Cervical CT demonstrated occipital bone erosion caused by the rostral tip of the rod on the right side and minor breakage of the C1 lateral mass screw on the left side (Fig. 8C, D). Revision surgery involving removal of the C1 screws bilaterally and cutting of the rostral side of the rods was performed (Fig. 8E). MR images after revision surgery demonstrated acceptable decompression and correction of the deformity (Fig. 9B).

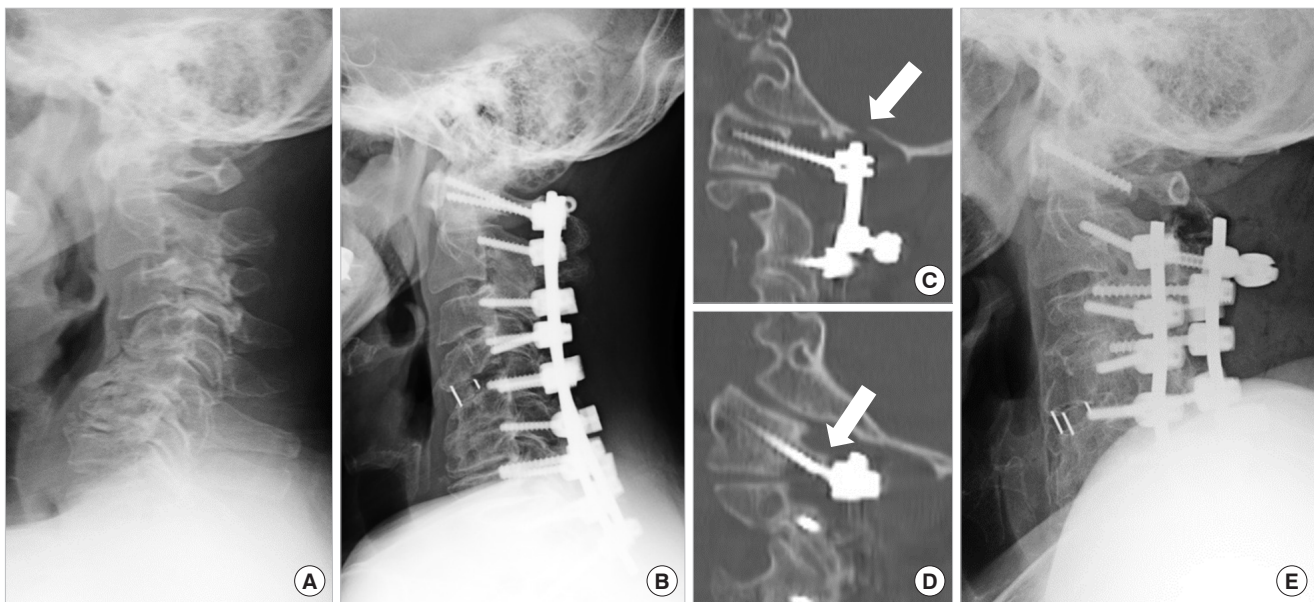


Fig. 8. Illustrative case of revision surgery for postoperative occipital bone erosion. (A) Lateral cervical x-ray before surgery. (B) Lateral cervical x-ray after primary surgery of posterior cervical fixation. Cervical CT 1 year after primary surgery demonstrating occipital bone erosion on the right side (arrow) (C) and minor screw breakage on the left side (arrow) (D). (E) Lateral cervical x-ray after revision surgery demonstrating removal of the C1 screws bilaterally and replacement of the screw-rod system.

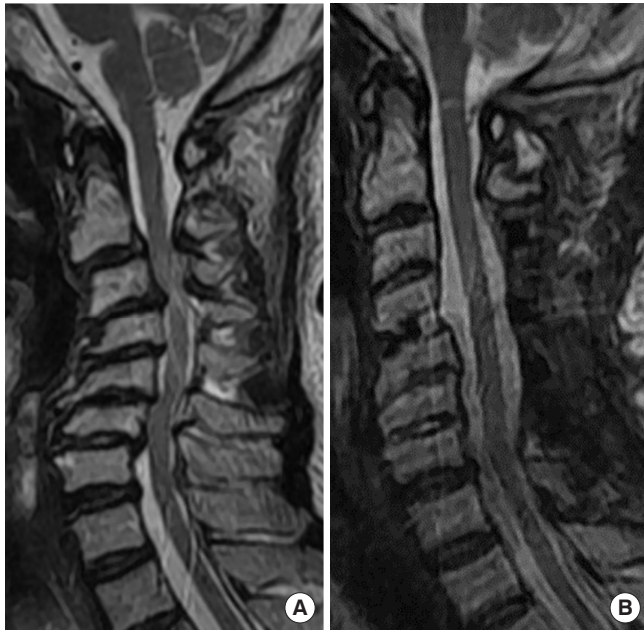


Fig. 9. Illustrative case of revision surgery for postoperative occipital bone erosion (same patient as in Fig. 8). (A) T2-weighted sagittal magnetic resonance (MR) images before surgery. (B) T2-weighted sagittal MR images after revision surgery.

CONCLUDING REMARKS

Revision surgery for cervical deformity is considered one of the most challenging areas for spine surgeons. There is no doubt that surgery for cervical deformity carries a high risk of surgery-related complications, which can potentially worsen HRQoL. Several recent studies have suggested the importance of imaging parameters, such as C2–7 SVA, chin-brow vertical angle, center of gravity of the head–C7 SVA, T1 slope, and C2–7 lordosis, to improve the patient's HRQoL after surgery. Since revision surgery is more challenging than the primary procedure, spine surgeons need to assess carefully the overall severity of the underlying condition before revision surgery and try to refine the surgical strategy to secure safe outcomes. Needless to say, spine surgeons face great challenges in making their surgery a much more reliable and convincing entity.

CONFLICT OF INTEREST

The authors have nothing to disclose.

REFERENCES

1. Deutsch H, Haid RW, Rodts GE, et al. Postlaminectomy cer-

- vical deformity. *Neurosurg Focus* 2003;15:E5.
2. Steinmetz MP, Stewart TJ, Kager CD, et al. Cervical deformity correction. *Neurosurgery* 2007;60(1 Suppl 1):S90-7.
 3. Etame AB, Wang AC, Than KD, et al. Outcomes after surgery for cervical spine deformity: review of the literature. *Neurosurg Focus* 2010;28:E14.
 4. Tan LA, Riew KD, Traynelis VC. Cervical spine deformity-Part 1: biomechanics, radiographic parameters, and classification. *Neurosurgery* 2017;81:197-203.
 5. Tan LA, Riew KD, Traynelis VC. Cervical spine deformity-Part 2: management algorithm and anterior techniques. *Neurosurgery* 2017;81:561-7.
 6. Tan LA, Riew KD, Traynelis VC. Cervical spine deformity-Part 3: posterior techniques, clinical outcome, and complications. *Neurosurgery* 2017;81:893-8.
 7. Papavero L, Lepori P, Schmeiser G. Revision surgery in cervical spine. *Eur Spine J* 2020;29(Suppl 1):47-56.
 8. Scheer JK, Tang JA, Smith JS, et al. Cervical spine alignment, sagittal deformity, and clinical implications: a review. *J Neurosurg Spine* 2013;19:141-59.
 9. Pal GP, Sherk HH. The vertical stability of the cervical spine. *Spine (Phila Pa 1976)* 1988;13:447-9.
 10. Raynor RB, Pugh J, Shapiro I. Cervical facetectomy and its effect on spine strength. *J Neurosurg* 1985;63:278-82.
 11. Vital JM, Senegas J. Anatomical bases of the study of the constraints to which the cervical spine is subject in the sagittal plane. A study of the center of gravity of the head. *Surg Radiol Anat* 1986;8:169-73.
 12. Dimnet J, Pasquet A, Krag MH, et al. Cervical spine motion in the sagittal plane: kinematic and geometric parameters. *J Biomech* 1982;15:959-69.
 13. Amevo B, Aprill C, Bogduk N. Abnormal instantaneous axes of rotation in patients with neck pain. *Spine (Phila Pa 1976)* 1992;17:748-56.
 14. Anderst W, Baillargeon E, Donaldson W, et al. Motion path of the instant center of rotation in the cervical spine during in vivo dynamic flexion-extension: implications for artificial disc design and evaluation of motion quality after arthrodesis. *Spine (Phila Pa 1976)* 2013;38:E594-601.
 15. Glassman SD, Berven S, Bridwell K, et al. Correlation of radiographic parameters and clinical symptoms in adult scoliosis. *Spine (Phila Pa 1976)* 2005;30:682-8.
 16. Mac-Thiong JM, Transfeldt EE, Mehdob AA, et al. Can C7 plumb line and gravity line predict health related quality of life in adult scoliosis? *Spine (Phila Pa 1976)* 2009;34:E519-27.
 17. Tang JA, Scheer JK, Smith JS, et al. The impact of standing regional cervical sagittal alignment on outcomes in posterior cervical fusion surgery. *Neurosurgery* 2012;71:662-9; discussion 9.
 18. Smith JS, Lafage V, Ryan DJ, et al. Association of myelopathy scores with cervical sagittal balance and normalized spinal cord volume: analysis of 56 preoperative cases from the AO-Spine North America Myelopathy study. *Spine (Phila Pa 1976)* 2013;38(22 Suppl 1):S161-70.
 19. Ames CP, Smith JS, Eastlack R, et al. Reliability assessment of a novel cervical deformity classification system. *J Neurosurg Spine* 2015;12:673-83.
 20. Katsumi Y, Honma T, Nakamura T. Analysis of cervical instability resulting from laminectomies for removal of spinal cord tumor. *Spine (Phila Pa 1976)* 1989;14:1171-6.
 21. McLaughlin MR, Wahlig JB, Pollak IF. Incidence of postlaminectomy kyphosis after Chiari decompression. *Spine (Phila Pa 1976)* 1997;22:613-7.
 22. Kaptain GJ, Simmons NE, Replogle RE, et al. Incidence and outcome of kyphotic deformity following laminectomy for cervical spondylotic myelopathy. *J Neurosurg (Spine 2)* 2000;93:199-204.
 23. Yeh JS, Sgouros S, Walsh AR, et al. Spinal sagittal malalignment following surgery for primary intramedullary tumours in children. *Pediatr Neurosurg* 2001;35:318-24.
 24. Machino M, Yukawa Y, Hida T, et al. Cervical alignment and range of motion after laminoplasty: radiographical data from more than 500 cases with cervical spondylotic myelopathy and a review of the literature. *Spine (Phila Pa 1976)* 2012;37:E1243-50.
 25. Shiraishi T, Fukuda K, Yato Y, et al. Results of skip laminectomy-minimum 2-year follow-up study compared with open-door laminoplasty. *Spine (Phila Pa 1976)* 2003;28:2667-72.
 26. Knott PT, Mardjetko SM, Tschy F. The use of the T1 sagittal angle in predicting overall sagittal balance of the spine. *Spine J* 2010;10:994-8.
 27. Kim TH, Lee SY, Kim YC, et al. T1 slope as a predictor of kyphotic alignment change after laminoplasty in cervical myelopathy patients. *Spine (Phila Pa 1976)* 2013;38:E992-7.
 28. Klineberg E, Schwab F, Ames C, et al. Acute reciprocal changes distant from the site of spinal osteotomies affect global postoperative alignment. *Adv Orthop* 2011;2011:415946.
 29. Ha Y, Schwab F, Lafage V, et al. Reciprocal changes in cervical spine alignment after corrective thoracolumbar deformity surgery. *Eur Spine J* 2014;23:552-9.
 30. Yasuoka S, Peterson HA, Laws ER Jr, et al. Pathogenesis and

- prophylaxis of postlaminectomy deformity of the spine after multiple level laminectomy: difference between children and adults. *Neurosurgery* 1981;9:145-52.
31. Anakwenze OA, Auerbach JD, Buck DW, et al. The role of concurrent fusion to prevent spinal deformity after intramedullary spinal cord tumor excision in children. *J Pediatr Orthop* 2011;31:475-9.
 32. Deen HG, Nottmeier EW, Reimer R. Early complications of posterior rod-screw fixation of the cervical and upper thoracic spine. *Neurosurgery* 2006;59:1062-8.
 33. Helgeson MD, Albert TJ. Surgery for failed cervical spine reconstruction. *Spine (Phila Pa 1976)* 2012;37:E323-7.
 34. Okamoto T, Neo M, Fujibayashi S, et al. Mechanical implant failure in posterior cervical spine fusion. *Eur Spine J* 2012; 21:328-34.
 35. Rihn JA, Harrod C, Albert TJ. Revision cervical spine surgery. *Orthop Clin North Am* 2012;43:123-36, ix-x.
 36. Maruyama H, Gejyo F, Arakawa M. Clinical studies of destructive spondyloarthropathy in long-term hemodialysis patients. *Nephron* 1992;61:37-44.
 37. Ohashi K. Pathogenesis of beta2-microglobulin amyloidosis. *Pathol Int* 2001;51:1-10.
 38. Yamamoto T, Matsuyama Y, Tsuji T, et al. Destructive spondyloarthropathy in hemodialysis patients: comparison between patients with and those without destructive spondyloarthropathy. *J Spinal Disord Tech* 2005;18:283-5.
 39. Veeravagu A, Ponnusamy K, Jiang B, et al. Renal osteodystrophy: neurosurgical considerations and challenges. *World Neurosurg* 2012;78:E23-33.
 40. Abumi K, Ito M, Kaneda K. Surgical treatment of cervical destructive spondyloarthropathy (DSA). *Spine (Phila Pa 1976)* 2000;25:2899-905.
 41. Kumar A, Leventhal MR, Freedman EL, et al. Destructive spondyloarthropathy of the cervical spine in patients with chronic renal failure. *Spine (Phila Pa 1976)* 1997;22:573-7.
 42. Maruo K, Moriyama T, Tachibana T, et al. Prognosis and adjacent segment disease after lumbar spinal fusion surgery for destructive spondyloarthropathy in long-term hemodialysis patients. *J Orthop Sci* 2017;22:248-53.
 43. Maruo K, Tachibana T, Arizumi F, et al. Clinical outcome after posterior cervical decompression and fusion surgery for destructive spondyloarthropathy in patients undergoing long-term hemodialysis: a matched case-control study. *J Orthop Sci* 2019;24:404-8.
 44. Sudo H, Ito M, Abumi K, et al. Long-term follow up of surgical outcomes in patients with cervical disorders undergoing hemodialysis. *J Neurosurg Spine* 2006;5:313-9.
 45. Cuffe MJ, Hadley MN, Herrera GA, et al. Dialysis-associated spondylarthropathy. Report of 10 cases. *J Neurosurg* 1994; 80:694-700.
 46. Spinos P, Matzaroglou C, Partheni M, et al. Surgical management of cervical spondyloarthropathy in hemodialysis patients. *Open Orthop J* 2010;19:39-43.
 47. Van Driessche S, Goutallier D, Odent T, et al. Surgical treatment of destructive cervical spondyloarthropathy with neurologic impairment in hemodialysis patients. *Spine (Phila Pa 1976)* 2006;31:705-11.
 48. Chikuda H, Yasunaga H, Horiguchi H, et al. Mortality and morbidity in dialysis-dependent patients undergoing spinal surgery: analysis of a national administrative database in Japan. *J Bone Joint Surg Am* 2012;94:433-8.
 49. Onari K, Kondo S, Mihara H, et al. Combined anterior-posterior fusion for cervical spondylotic myelopathy in patients with athetoid cerebral palsy. *J Neurosurg* 2002;97(1 Suppl): 13-9.
 50. Ueda Y, Yoshikawa T, Koizumi M, et al. Cervical laminoplasty combined with muscle release in patients with athetoid cerebral palsy. *Spine (Phila Pa 1976)* 2005;30:2420-3.
 51. Traynelis VC, Ryken T, Rodnitzky RL, et al. Botulinum toxin enhancement of postoperative immobilization in patients with cervical dystonia. *J Neurosurg* 1992;77:808-9.
 52. Furuya T, Yamazaki M, Okawa A, et al. Cervical myelopathy in patients with athetoid cerebral palsy. *Spine (Phila Pa 1976)* 2013;38:E151-7.
 53. Demura S, Murakami H, Kawahara N, et al. Laminoplasty and pedicle screw fixation for cervical myelopathy associated with athetoid cerebral palsy. *Spine (Phila Pa 1976)* 2013; 38:1764-9.
 54. Watanabe K, Hirano T, Katsumi K, et al. Surgical outcomes of posterior spinal fusion alone using cervical pedicle screw constructs for cervical disorders associated with athetoid cerebral palsy. *Spine (Phila Pa 1976)* 2017;42:1835-43.