

Acute cholecystitis complicated with gallbladder empyema due to *Mycobacterium tuberculosis* in a patient with diabetes mellitus: a case report

Alejandro Ortiz-Hernández¹, Jorge Andrés Castro Flores, Diego-Abelardo Álvarez-Hernández², Fernando Pérez Aldrett, Laura Perfinka Herrera González and Jorge Uriel Méndez Ibarra

Abstract: Acute cholecystitis severity ranges from mild to very severe, and its most dreadful complication is gallbladder empyema. It can be caused by several etiologic agents, but *Mycobacterium tuberculosis* is not common among them. Here we present a 61-year-old female who lives in an area of high tuberculosis endemicity and has type 2 diabetes mellitus. She came to our hospital with a 2-day history of moderate-to-severe colicky right upper quadrant abdominal pain and other clinical manifestations compatible with AC. Imaging studies confirmed the diagnosis. An emergency open cholecystectomy was performed and the gallbladder was sent for histopathologic examination. *M. tuberculosis* was identified by molecular studies and the treatment was adjusted. The patient recovered uneventfully. The clinical history and physical examination are essential for raising the index of suspicion, but complementary evaluation with imaging studies is necessary to confirm the diagnosis and evaluate its complications. Tuberculosis is a major health problem worldwide, and health professionals should be aware of its clinical spectrum to approach and manage common and uncommon presentations within their scope of attention.

Keywords: abdominal tuberculosis, acute cholecystitis, gallbladder disease, gallbladder empyema, *Mycobacterium tuberculosis*, tuberculosis

Received: 4 June 2022; revised manuscript accepted: 9 September 2022.

Introduction

Acute cholecystitis (AC) is one of the most common surgical entities seen in the Emergency Department, it is an acute inflammatory disease caused after cystic duct obstruction due to gallstones or lithogenic bile.^{1,2} The most dreadful complication is gallbladder empyema, which accounts for 6.3–26.6% of complicated AC with mortality of nearly 3%. It occurs when the obstructed gallbladder becomes infected and bacteria-containing bile with purulent material accumulates.^{3–5} The most frequent etiologic agents are Gram-negative enteropathogens: *Escherichia coli*, *Klebsiella* spp., and *Streptococcus faecalis*.^{2,6} However, other pathogens can affect the gallbladder and cause complications.

Gallbladder tuberculosis (TB) is a very rare entity due to the intrinsic role of bile acids that inhibits the growth of the *Mycobacterium* spp.⁷ It can present as acute or chronic cholecystitis,^{8,9} biliary strictures, choledocholithiasis,¹⁰ gallbladder perforation,¹¹ and can also mimic gallbladder carcinoma, one of the most important differential diagnoses of this disease.¹² However, only two cases of gallbladder empyema have been reported in the literature.^{13,14}

Here, we report a case of AC with gallbladder empyema in a patient that lives with diabetes mellitus (DM) due to *Mycobacterium tuberculosis* – a very rare cause of this disease. This case report has been reported in line with the SCARE Criteria.¹⁵

Ther Adv Infect Dis

2022, Vol. 9: 1–6

DOI: 10.1177/
20499361221129161

© The Author(s), 2022.
Article reuse guidelines:
sagepub.com/journals-
permissions

Correspondence to:

Alejandro Ortiz-Hernández
Faculty of Medicine,
Autonomous University of
San Luis Potosí, Centro,
78000 San Luis Potosí,
México.
alexortizh98@gmail.com

Jorge Andrés Castro Flores
Faculty of Medicine,
Autonomous University of
San Luis Potosí, San Luis
Potosí, México

Hospital General ISSSTE,
San Luis Potosí, México

Diego-Abelardo Álvarez-Hernández
Faculty of Health Sciences,
Anáhuac University
México, Huixquilucan,
México

Faculty of Infectious and
Tropical Diseases, London
School of Hygiene &
Tropical Medicine, London,
UK

Fernando Pérez Aldrett
Faculty of Medicine,
Autonomous University of
San Luis Potosí, San Luis
Potosí, México

Laura Perfinka Herrera González

Jorge Uriel Méndez Ibarra
Hospital General ISSSTE,
San Luis Potosí, México

Case report

We present a 61-year-old female from San Luis Potosí, Mexico, with type 2 DM, hypertension, and 2-year history of gallstone disease with no other comorbidities. Her surgical history was not significant. She presented at the Emergency Department of our hospital with a 2-day history of moderate-to-severe colicky RUQ abdominal pain that started an hour after eating a large, fatty meal for breakfast. It radiated to the mid-back and right shoulder and had no alleviating or aggravating factors. Also, she complained of nausea, vomiting, and food intolerance. The patient had previous self-limited episodes of RUQ abdominal pain.

On general examination, she had a poor general status and was diaphoretic and dehydrated with unstable vital signs: a respiratory rate of 20 r/min, a heart rate of 127 bpm, an oxygen saturation of 92%, a blood pressure of 84/52 mmHg, and a body temperature of 38.1°C. The abdominal physical examination revealed tenderness to palpation in the epigastric region with a firm and painful palpable mass in the RUQ abdominal region. Laboratory tests showed an elevated white blood count (WBC) count of 15,670/mcl with 15,400/mcl (98.0%) neutrophils and 235/mcl (1.5%) of lymphocytes, 287,000/mcl platelets, lactate blood levels of 2.3 mmol/l, total bilirubin of 1.09 mg/dl, conjugated bilirubin of 0.45 mg/dl, unconjugated bilirubin of 0.64 mg/dl, creatinine of 0.89 mg/dl, urea of 53.6 mg/dl, prothrombin time of 14.2 seconds, partial thromboplastin time of 35 seconds, and C-reactive protein of 305 mg/L with no other alterations. Blood cultures were obtained prior the start of antibiotics. There was no ultrasound available, but an abdominal computed tomography (CT) scan was performed and showed an enlarged gallbladder with marked wall thickening. Also, a gallstone obstructing the gallbladder neck was shown (Figure 1).

The patient was started with IV antibiotic therapy of ciprofloxacin and metronidazole. Preoperative resuscitation followed by an emergency open cholecystectomy was performed for source control. Surgical exploration revealed omentum and duodenum adhesions to the enlarged gallbladder. The gallbladder was also necrotic without perforation. Retrograde gallbladder dissection with subtotal fenestrating cholecystectomy was performed because of the impossibility to identify the common hepatic bile duct, cystic duct, and

cystic artery. Intraoperative drainage of the gallbladder was performed, obtaining 60 ml of purulent fluid. Cultures were collected from the content of gallbladder. Saratoga sump drainage was collocated on the liver bed for wound drainage. Because of the risk of bile duct injury along with the procedure and risk of biliary fistula, the patient was taken for an endoscopic retrograde cholangiopancreatography (ERCP), where an endoscopic biliary prosthesis was inserted. All blood and fluid cultures and Gram-stain yield negative. The patient recovered uneventfully without pain and fever and was discharged on the fifth postoperative day.

The gallbladder specimen removed during cholecystectomy was sent for histopathologic examination to the Pathology Department of our hospital. The presence of a gallstone of 5.5 × 3 × 3 cm, a wall thickness of 4–10 mm, and a nodular cheesy-looking lesion of 9 mm were noted. The reported histopathologic diagnosis was AC with areas of caseous necrosis. Routine staining was performed and showed intracellular acid-fast bacilli (AFB). (Figure 2) The gallbladder specimen was sent for molecular testing, where *M. tuberculosis* was identified by polymerase chain reaction. A diagnosis of AC complicated with gallbladder empyema due to *M. tuberculosis* was performed and treatment was adjusted. An epidemiological report was sent to our Epidemiology Department and the authorities of the National Secretary of Health for follow-up and starting the antituberculous therapy. They started the shortened primary TB treatment which comprises an intensive therapy with isoniazid, rifampicin, pyrazinamide, and ethambutol for 2 months, followed by 4 months of continuation phase with isoniazid and rifampicin. The patient had completed the intensive phase and currently is in the second month of continuation phase. During follow-up, the patient has not presented any complications due to the disease or the treatment.

Discussion

The case report that we present here belongs to an area with a high prevalence of TB and highlights one of the complications that can develop in the natural course of this disease. It also demonstrates the importance of making a good clinical history in all critically ill patients with AC complicated with gallbladder empyema. Early identification of

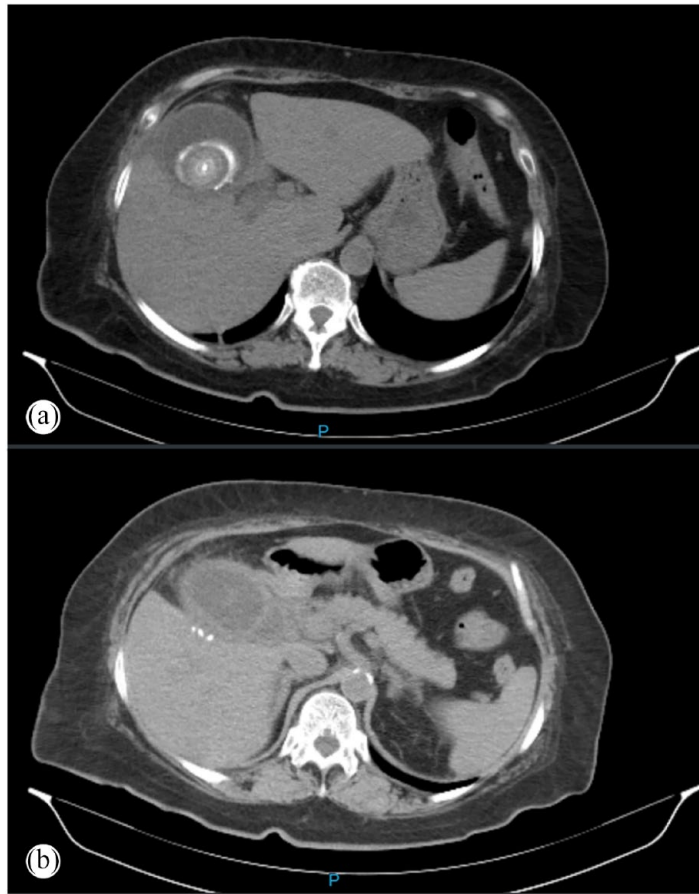

Figure 1. (a) Axial view of the abdominal CT at level of T12 vertebrae, showing an enlarged gallbladder filled with large amounts of fluid, with marked diffuse uniform wall thickening and a hyperdense gallstone partially obstructing the gallbladder neck. (b) Axial view of the abdominal CT at level of L1 vertebrae showing enlarged gallbladder with wall edema and pericholecystic fluid. CT, computed tomography.

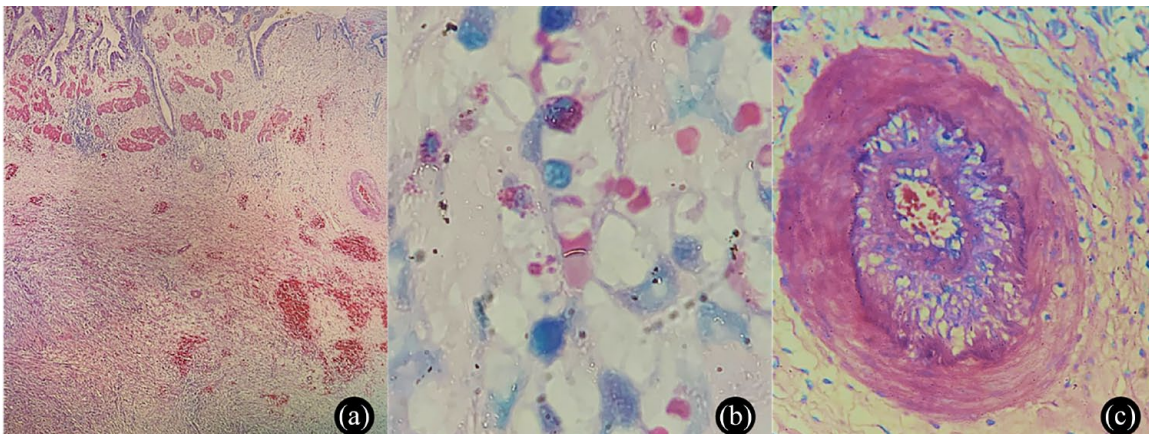


Figure 2. Histopathologic gallbladder tissue examination. (a) Hematoxylin and eosin (HE), gallbladder with marked areas of chronic and acute granulomatous inflammation and caseous-necrosis. (b) Ziehl-Neelsen, gallbladder showing intracellular acid-fast bacilli. (c) HE, marked intimal and a diffuse subendothelial proliferation compatible with tuberculous endarteritis.

potential complications can allow appropriate and prompt medical and surgical management, reducing its morbidity and mortality.

There are well-known risk factors for TB such as low socioeconomic status, TB family history, malnutrition, smoking, and poorly controlled DM.¹⁶ The association of TB with DM has been known for centuries due to the immunosuppression caused by the poor glycemic control.¹⁷ Globally, according to the World Health Organization,¹⁸ DM is associated with a twofold to threefold risk of developing complications due to TB, including death during treatment and risk of developing multidrug-resistant TB (MDR-TB), it is also associated with a fourfold risk of TB relapse after treatment completion. Mexico is among the countries with the highest prevalence of DM, with 15.7% in 2020,¹⁹ where the population attributable risk of DM on TB reaches 25% which is higher than the one from human immunodeficiency virus infection.²⁰ MDR-TB was one of our primary concerns in this patient follow-up because, in San Luis Potosí, the most common risk factor associated with MDR-TB has been DM, which was found in 47.2% of MDR-TB patients.²¹

Abdominal TB prevalence has increased in both immunocompetent and immunocompromised hosts worldwide, mostly in endemic countries. However, the real prevalence and implications are still unknown. Gastrointestinal TB comprises nearly 2% of total TB cases and it is often associated with disseminated disease, with less than 20% associated with pulmonary TB. The most affected organ is the liver, in counterpart to the gallbladder, which is rarely affected.²² People living with DM are less likely to present with extrapulmonary TB,¹⁷ which contrasts with our case because our patients didn't have signs of pulmonary TB. Gallbladder TB can develop by affecting the biliary epithelium causing acute or chronic inflammation or by involving the adjacent periportal and pericholedochal lymph nodes. Typically, patients complain of a slow and insidious clinical presentation with jaundice, fever, anorexia, recurrent abdominal pain, and weight loss. However, the clinical findings are nonspecific and clinical findings are indistinguishable from other gallbladder diseases.²³

Regarding imaging studies, three different CT scan morphology findings of the gallbladder TB

have been described in the literature: micronodular lesions of the gallbladder wall with or without enhancement of the lesion, a thickened gallbladder wall, and a gallbladder mass, being the thickening of the gallbladder wall the most common finding.²⁴ Our patient's CT scan showed an enlarged gallbladder with marked gallbladder wall thickening and small amounts of pericholecystic fluid. However, laboratory tests can be normal or they may demonstrate anemia, elevation of the liver enzymes, such as aspartate aminotransferase and alanine aminotransferase, and elevation of inflammatory biomarkers, such as C-reactive protein and erythrocyte sedimentation rate, and neutrophil-predominant leukocytosis.^{23,24}

Traditionally, all gallbladder specimens are sent for histopathologic examination after cholecystectomy to rule out the presence of malignant diseases when a macroscopic abnormality is present.²⁵ The histopathologic findings can confirm the presence of gallbladder TB. Similar to our case, caseous necrosis, multiple granulomas, and intracellular AFB are the typical histopathologic findings,²⁴ highlighting the importance of doing the AFB routine staining.

Abdominal TB is generally responsive to medical treatment alone, so early diagnosis can prevent unnecessary surgical intervention²⁶ According to our national policy, the diagnosed cases of abdominal TB, including gallbladder TB, should receive the shortened primary treatment of antituberculous therapy, which is strictly supervised and monthly follow-up is recommended.²⁷ However, because the diagnosis of gallbladder TB is mostly done postoperatively, surgery is mandatory²⁶ In our case, we performed a subtotal fenestrating open cholecystectomy as a bail-out procedure in view of our patient's safety due to the impossibility of achieving an optimal view of the hepatobiliary anatomy. It is recommended in cases with a lot of inflammation or loss of the anatomy. Biliary fistula or stenosis is known as postoperative complications of this procedure, making a priority to perform an ERCP.²⁸

Conclusion

This case report describes an AC complicated with gallbladder empyema due to *M. tuberculosis* in a patient that lives with DM in an area of high endemicity for TB. The clinical, imaging, and

laboratory findings are nonspecific for gallbladder TB empyema. The diagnosis can only be made postoperatively after a histopathologic check and confirmation. This highlights the importance of sending all gallbladder specimens for histopathologic routine examination after performing a cholecystectomy due to its implications for treatment and prognosis. TB is a major health problem worldwide, and health professionals should be aware of its clinical spectrum to approach and manage common and uncommon presentations within their scope of attention. Surgeons should have a high index of suspicion for patients with AC and gallbladder empyema that live in endemic countries or that have risk factors for TB as they can change their outcome.

Declarations

Ethics approval and consent to participate

Not applicable.

Consent for publication

Written informed consent was obtained from the patient for the publication of this case report and accompanying images.

Author contributions

Alejandro Ortiz-Hernández: Conceptualization; Investigation; Methodology; Project administration; Resources; Supervision; Visualization; Writing – original draft; Writing – review & editing.

Jorge Andrés Castro Flores: Conceptualization; Investigation; Validation; Writing – original draft.

Diego-Abelardo Álvarez-Hernández: Formal analysis; Methodology; Project administration; Supervision; Validation; Writing – review & editing.

Fernando Pérez Aldrett: Conceptualization; Investigation; Validation; Writing – original draft.

Laura Perfinka Herrera González: Investigation; Methodology; Supervision; Validation; Visualization.

Jorge Uriel Méndez Ibarra: Conceptualization; Investigation; Methodology; Validation; Visualization.

Acknowledgements

None.

Funding

The authors received no financial support for the research, authorship, and/or publication of this article.

Competing interests


The authors declared no potential conflicts of interest with respect to the research, authorship, and/or publication of this article.

Availability of data and materials

Not applicable.

ORCID iDs

Alejandro Ortiz-Hernández  <https://orcid.org/0000-0002-1714-9560>

Diego-Abelardo Álvarez-Hernández  <https://orcid.org/0000-0003-2340-6639>

References

1. Elwood DR. Cholecystitis. *Surg Clin North Am* 2008; 88: 1241–1252.
2. Gallaher JR and Charles A. Acute cholecystitis: a review. *JAMA* 2022; 327: 965–975.
3. Bedirli A, Sakrak O, Sözüer EM, *et al.* Factors effecting the complications in the natural history of acute cholecystitis. *Hepatogastroenterology* 2001; 48: 1275–1278.
4. Cho JY, Han HS, Yoon YS, *et al.* Risk factors for acute cholecystitis and a complicated clinical course in patients with symptomatic cholelithiasis. *Arch Surg* 2010; 145: 329–333; discussion 333.
5. Ambe PC, Jansen S, Macher-Heidrich S, *et al.* Surgical management of empyematous cholecystitis: a register study of over 12,000 cases from a regional quality control database in Germany. *Surg Endosc* 2016; 30: 5319–5324.
6. Mak MHW, Low JK, Junnarkar SP, *et al.* A prospective validation of Sepsis-3 guidelines in acute hepatobiliary sepsis: qSOFA lacks sensitivity and SIRS criteria lacks specificity (cohort study). *Int J Surg* 2019; 72: 71–77.
7. Epstein D, Mistry K, Whitelaw A, *et al.* The effect of physiological concentrations of bile acids on in vitro growth of *Mycobacterium tuberculosis*. *S Afr Med J* 2012; 102: 522–524.
8. Abu-Zidan FM and Zayat I. Gallbladder tuberculosis (case report and review of the literature). *Hepatogastroenterology* 1999; 46: 2804–2806.

9. Chan KS, Shelat VG, Tan CH, *et al.* Isolated gallbladder tuberculosis mimicking acute cholecystitis: a case report. *World J Gastrointest Surg* 2020; 12: 123–128.
10. Renganathan SN and Chakkalakkoombil SV. Uncommon presentation of a common disease. *BMJ Case Reports* 2014; 2014: bcr2014204901.
11. Hahn ST, Park SH, Shin WS, *et al.* Gallbladder tuberculosis with perforation and intrahepatic biloma. *J Clin Gastroenterol* 1995; 20: 84–86.
12. Krishnamurthy G, Singh H, Rajendran J, *et al.* Gallbladder tuberculosis camouflaging as gallbladder cancer – case series and review focussing on treatment. *Ther Adv Infect Dis* 2016; 3: 152–157.
13. Tauro LF, Martis JJ and Shenoy HD. Tuberculosis of gall bladder presenting as empyema. *Saudi J Gastroenterol* 2008; 14: 101.
14. Tse-Hung L and An-Swen T. Gallbladder tuberculosis. *Int J Gerontol* 2019: 264.
15. Agha RA, Franchi T, Sohrabi C, *et al.* The SCARE 2020 guideline: updating consensus Surgical CAse REport (SCARE) guidelines. *Int J Surg* 2020; 84: 226–230.
16. Young BN, Rendón A, Rosas-Taraco A, *et al.* The effects of socioeconomic status, clinical factors, and genetic ancestry on pulmonary tuberculosis disease in northeastern Mexico. *PLoS ONE* 2014; 9: e94303.
17. Restrepo BI and Schlesinger LS. Impact of diabetes on the natural history of tuberculosis. *Diabetes Res Clin Pract* 2014; 106: 191–199.
18. World Health Organization. *Global tuberculosis report 2021: TB and diabetes*. World Health Organization, 2022, <https://www.who.int/publications/digital/global-tuberculosis-report-2021/featured-topics/tb-diabetes>
19. Basto-Abreu AC, López-Olmedo N, Rojas-Martínez R, *et al.* Prevalence of diabetes and glycemic control in Mexico: national results from 2018 and 2020. *Salud Publica Mex* 2021; 63: 725–733.
20. López DE, Melgarejo HMA and Aguilar-Salinas CA. La diabetes tipo 2 y la tuberculosis en México: la confluencia de dos retos para el sistema de salud. *Acta Med* 2012; 10: 189–195.
21. Gómez-Gómez A, Magaña-Aquino M, López-Meza S, *et al.* Diabetes and other risk factors for multi-drug resistant tuberculosis in a Mexican population with pulmonary tuberculosis: case control study. *Arch Med Res* 2015; 46: 142–148.
22. Gil-Rojas N, Cerda-Galomo CA, Carrillo-Muñoz A, *et al.* Autopsy diagnosis of gastrointestinal tuberculosis at the Hospital General de México. *Rev Med Hosp Gen Mex* 2014; 77: 64–69.
23. Saluja SS, Ray S, Pal S, *et al.* Hepatobiliary and pancreatic tuberculosis: a two decade experience. *BMC Surg* 2007; 7: 10.
24. Xu XF, Yu RS, Qiu LL, *et al.* Gallbladder tuberculosis: CT findings with histopathologic correlation. *Korean J Radiol* 2011; 12: 196–202.
25. Agarwal AK, Kalayarasan R, Singh S, *et al.* All cholecystectomy specimens must be sent for histopathology to detect inapparent gallbladder cancer. *HPB* 2012; 14: 269–273.
26. Debi U, Ravisankar V, Prasad KK, *et al.* Abdominal tuberculosis of the gastrointestinal tract: revisited. *World J Gastroenterol* 2014; 20: 14831–14840.
27. Norma Oficial Mexicana. *NOM-006-SSA2-2013 – Para la prevención y control de la tuberculosis*. Diario Oficial de la Federación, 2012, http://dof.gob.mx/nota_detalle_popup.php?codigo=5321934
28. Strasberg SM, Pucci MJ, Brunt LM, *et al.* Subtotal cholecystectomy – ‘fenestrating’ vs ‘reconstituting’ subtypes and the prevention of bile duct injury: definition of the optimal procedure in difficult operative conditions. *J Am Coll Surg* 2016; 222: 89–96.