

Single-stage medial plateau elevation and metaphyseal osteotomies in advanced-stage Blount's disease: a new technique

Mostafa M. Baraka
Hany M. Hefny
Mahmoud A. Mahran
Tamer A. Fayyad
Haytham Abdelazim
Amr Nabil

Abstract

Purpose Surgical treatment in advanced-stage infantile Blount's disease with medial plateau (MP) depression is challenging. Several osteotomies and fixation methods have been described with no established benchmark. We conducted this study to evaluate the efficacy and safety of a new single-stage technique for acute medial condyle elevation and metaphyseal osteotomies with internal fixation.

Methods A prospective case series of 19 consecutive patients (21 knees) with severe infantile Blount's disease underwent a single-stage MP elevation and metaphyseal osteotomies, with internal fixation. The mean age was 10.3 years (8.2 to 13.6) and the mean follow-up was 5.1 years (3.2 to 8.3). The outcome measures included clinical and radiological parameters and patient-reported pediatric outcomes data collection instrument (PODCI) score.

Results The mean PODCI score improved significantly from 50% to 88%. The mean internal tibial torsion improved from -27° to 11° . All cases maintained full knee extension, no limitation in flexion range of movement and no signs of instability or lateral thrust gait. All the radiographic parameters improved significantly; the mean tibiofemoral angle improved from -29° to 7° , the metaphyseal-diaphyseal angle improved from 33.4° to 4.7° and the angle of depressed MP improved from 38.3° to 2.4° ($p < 0.001$). At the latest follow-up, no cases of deformity recurrence were identified, the final limb-length discrepancy was < 1 cm in all patients.

Department of Orthopaedic Surgery, Faculty of Medicine, Ain-Shams University, Cairo, Egypt.

Correspondence should be sent to Mostafa M. Baraka, Division of Paediatric Orthopaedics and Limb Reconstruction Surgery, Department of Orthopaedic Surgery, Faculty of Medicine, Ain-Shams University, Cairo, Egypt.
E-mail: mostafa.baraka@hotmail.com;
mostafa.baraka@med.asu.edu.eg

Conclusion Single-stage MP elevation and metaphyseal osteotomies with internal fixation significantly improved the clinical and radiographic parameters and PODCI score in advanced infantile Blount's disease and precluded the use of external immobilization, with no evidence of deformity recurrence.

Level of evidence: IV

Cite this article: Baraka MM, Hefny HM, Mahran MA, Fayyad TA, Abdelazim H, Nabil A. Single-stage medial plateau elevation and metaphyseal osteotomies in advanced-stage Blount's disease: a new technique. *J Child Orthop* 2021;15:12-23. DOI: 10.1302/1863-2548.15.200157

Keywords: infantile tibia vara; Blount's disease; genu varum; double osteotomy; medial plateau elevation

Introduction

Blount's disease is a developmental condition that results from disordered endochondral ossification of the posteromedial part of the proximal tibial physis. Although the initial description by Blount¹ referred to the condition as "tibia vara", implying a solely coronal malalignment, subsequent studies revealed a complex multiplanar deformity of the lower limb.^{2,4} This comprises proximal tibial varus, procurvatum and internal tibial torsion (ITT). Infantile Blount's disease occurs before four years of age, and when not managed early, the deformity progresses with depression of the medial plateau (MP).^{4,5}

Langenskiold and Riska⁶ classified infantile Blount's disease into six progressive stages based on their radiographic appearance. In late-presenting cases (stages V and VI), an excessive downward sloping of the MP results in increased ligamentous laxity. The knee instability arises from the incongruity of the tibiofemoral articular surfaces with excessive varus thrust during stance phase of gait, and significantly affects lower limb function and gait kinematics.^{3,7} Premature fusion of the medial proximal tibial physis in stage VI leads to rapid deformity progression, limb-length discrepancy (LLD) and inevitable recurrence after simple osteotomies with reported rates up to 60%.^{8,9} Long-term reports have confirmed the progressive nature of the disease, ending up with an awkward gait, excessive varus thrust, knee pain and premature arthritis.^{4,7}

The goal of treatment of Blount's disease is to restore a normal limb alignment, congruence of tibiofemoral articular surfaces, equal limb lengths at skeletal maturity and to prevent recurrence.² Different techniques have been described for angular and rotational correction, including closing wedge, opening wedge, dome, serrated and oblique osteotomies.⁵ Additionally, different fixation methods have been employed, including cast immobilization,¹⁰ Kirschner-wires, screws,¹¹ plates¹² and external fixators.^{8,13-15} A simple metaphyseal osteotomy may correct the metaphyseal source of varus and ITT, but does not restore the normal knee anatomy and joint congruence with persistent varus instability and varus thrust. Attempts to restore the congruency of the tibiofemoral articular surfaces by MP elevation have been described with encouraging clinical results.^{2,8,10,11,13,14,16-19} Nonetheless, consensus on osteotomy details and methods of fixation has not been established. Furthermore, MP elevation osteotomy adds to the complexity of surgical treatment and increases the risk of complications. The previously described techniques for MP elevation are technically demanding and carry potential risks of intra-articular fractures, medial condyle displacement and inadequate MP elevation with persistent lateral laxity.^{15,20} This has also raised difficulty in decision-making about fixation methods, acute *versus* gradual elevation, need for bone grafting and single-stage *versus* two-stage correction.^{8,10,12-14,16,19}

Gradual distraction using Ilizarov/external fixation methods may be adversely associated with pin-site irritation, interference with rehabilitation, pin-tract infection, pin breakage, premature consolidation, undercorrection and deformity recurrence.^{8,14,17,18,21} In addition, many of the reported internal fixation methods did not offer optimum rigidity, stable enough to preclude the use of a postoperative plaster immobilization and start early knee range of movement (ROM), with the risk of medial condyle displacement, loss of correction and revision surgeries.¹⁰⁻¹²

MP elevation combined with a second metaphyseal osteotomy is often termed a double-elevating osteotomy.^{9,12,14,15} This technique is infrequently discussed in the literature and to the best of our knowledge there are no previous reports employing rigid internal fixation methods for both osteotomies. We present a technique for single-stage acute deformity correction in late-presenting infantile Blount's disease through a single medial approach. An 'inside-out' osteotomy technique for acute MP elevation is described that preserves the articular hinge and allows for acute MP elevation with precise joint-levelling, while avoiding the potential risk of intra-articular fractures and medial condyle displacement. This is coupled to a second oblique-plane metaphyseal osteotomy for simultaneous correction of varus and ITT. Both osteotomies are fixed with a proximal tibial locking com-

pression plate (LCP). We hypothesize that this technique would provide a safe and effective single-stage management of the complex deformity in severe infantile Blount's disease; restoring joint congruence, offering rigid internal fixation, avoiding plaster immobilization, as well as avoiding the adverse effects of gradual distraction by external fixation.

Patients and methods

All patients in this series were classified as early-onset or infantile Blount's disease (deformity beginning at less than four years).⁴ Inclusion criteria were advanced-stage infantile Blount's disease (V and VI according to Langenskiöld and Riska⁶), with an angle of MP depression¹¹ > 20°, metaphyseal-diaphyseal angle²² > 16° and age older than eight years to limit the potential LLD since the procedure involves definitive proximal tibial epiphysiodesis. Progressive knee varus deformity secondary to a cause other than Blount's disease, early-stage Blount's disease (stages I to IV), patients younger than eight years and those who had developed arthritic changes were excluded.

This prospective case series from a single institution included 19 consecutive patients (21 limbs), conducted during the period from 1 March 2010 to 1 March 2017. The study included six male and 13 female patients. The mean age was 10.3 years (8.2 to 13.6). The right side was affected in nine limbs and the left side in 12 limbs. Seven patients (eight limbs) had previous surgery, including simple metaphyseal osteotomies in four patients (four limbs) and failed guided growth surgery in three patients (four limbs). The minimum period from their last surgical intervention to the index procedure was one year. Two children were affected bilaterally, surgeries on both limbs were spaced by six months. The mean follow-up was 5.1 years (3.2 to 8.3). No patients in this series were lost in the follow-up. Institutional review board approval was obtained prior to conducting the study.

Clinical evaluation

The spectrum of complaints included medial and lateral knee pain, limp, interference with daily activities, cosmetic concerns due to progressive varus deformity and walking difficulty. Examination included goniometric assessment of knee ROM, flexion and extension. Knee stability was assessed by stress testing of medial and lateral collateral ligaments in full extension and 30° flexion. Varus thrust gait, defined as accentuation of varus malalignment and lateral knee translation during stance which partially corrects during swing, was assessed by observational gait analysis. To avoid interobserver variation, knee instability and varus thrust were coded as positive findings without

grading. ITT was assessed clinically in prone position with 90° knee flexion. The angle of tibial torsion was measured between the thigh axis and the hindfoot axis. ITT was assigned a negative angle and external torsion was assigned a positive angle. A Staheli's rotational profile²³ was completed for evaluation for concomitant increased femoral anteversion.

Functional outcome assessment

A patient/parent-reported assessment questionnaire was used, based on the patient-reported paediatric outcomes data collection instrument (PODCI) developed by the American Academy of Orthopaedic Surgeons.²⁴ The questionnaire has previously proven valid and reliable for patient-reported satisfaction after surgery for Blount's disease.²⁵

Radiographic evaluation

Full-length standing anteroposterior radiographs with patellae facing forwards and LLD corrected by blocks under the short side were obtained, as well as standard anteroposterior and lateral radiographs of the knee and

tibia. CT scans with 3D reconstructions were obtained to help preoperative planning, particularly delineating the posteromedial slope of the MP and ideal graft positioning. Radiographic classification was done according to Langenskiold and Riska.⁶ For validity, radiographic interpretations were performed by the non-operating surgeons. The following radiographic parameters were obtained (Fig. 1): mechanical axis of the lower limb,²⁶ mechanical lateral distal femoral angle (mLDFA),²⁶ medial proximal tibial angle (MPTA),²⁶ tibiofemoral angle (TFA),²⁷ metaphyseal-diaphyseal angle (MDA),²² angle of depression of MP (ADMP),¹¹ posterior proximal tibial angle (PPTA)²⁶ and LLD.²⁸

Surgical technique

Surgery was performed under general anaesthesia with the use of tourniquet. A prophylactic dose of antibiotics was administered at induction of anaesthesia. The patient was positioned supine on a radiolucent table allowing free imaging from the hip to the ankle for intraoperative visualization of mechanical alignment. Surgery was performed by one of the three senior authors (MMB, HMH, MAM).

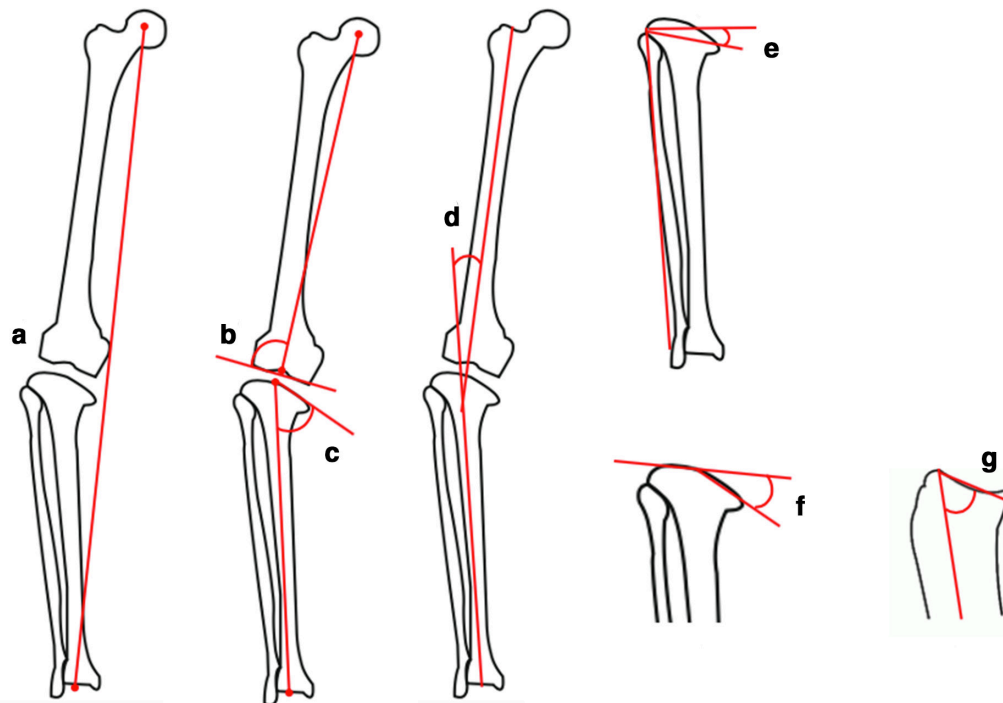


Fig. 1 Radiographic assessment: **a)** mechanical axis of the lower limb, the line joining the centre of the hip to the centre of the ankle; **b)** mechanical lateral distal femoral angle, lateral angle between the mechanical femoral axis and the intercondylar line; **c)** medial proximal tibial angle, the medial angle between the mechanical axis of the tibia and a line parallel to the medial tibial condyle; **d)** tibiofemoral angle, angle created by the intersection of tibial and femoral anatomic axes; **e)** metaphyseal-diaphyseal angle, angle created by the intersection of a line through the transverse plane of the proximal tibial metaphysis with a line perpendicular to the long axis of the tibial diaphysis; **f)** angle of depression of medial plateau, formed by a line drawn parallel to the proximal margin of the medial plateau intersecting a line drawn parallel to the lateral plateau of the tibia; **g)** posterior proximal tibial angle, the angle between the tibial anatomic axis and the medial plateau line in the sagittal view.

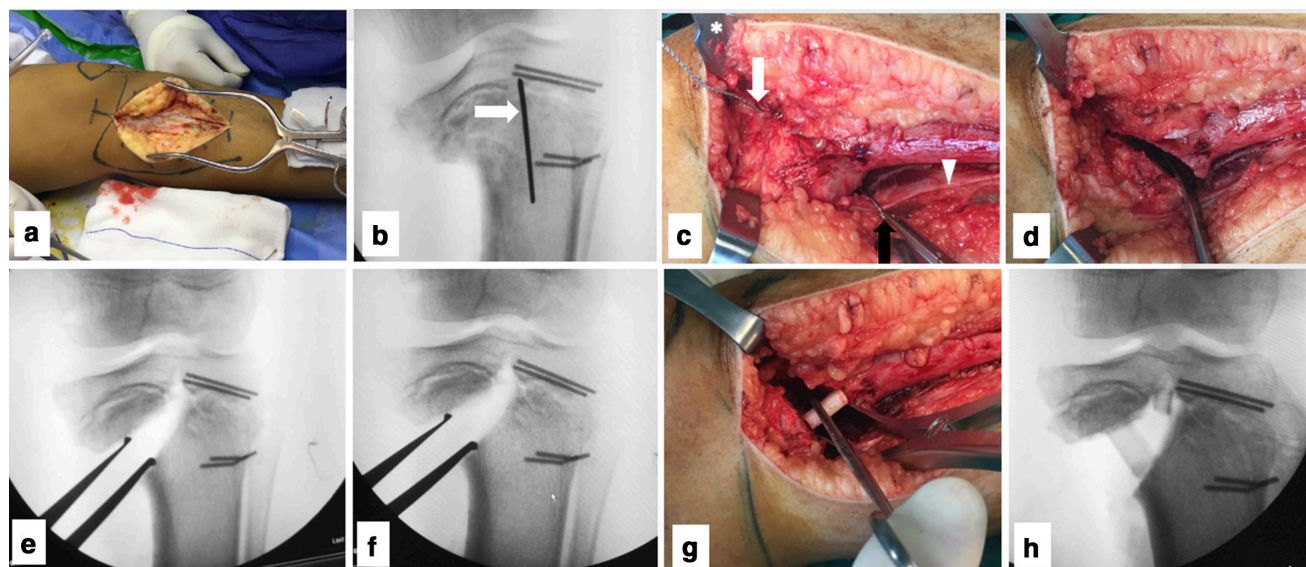


Fig. 2 Inside-out osteotomy technique for medial plateau elevation on the left leg: **a**) anteromedial longitudinal incision with subperiosteal exposure of the tibial surface; **b**) a 2.0-mm guide wire (white arrow) drilled anteroposteriorly 1 cm below the joint line and midway between the tibial eminences. The guide wire is slowly advanced till it engages the posterior Hohman retractor. In the lateral view, this wire was 1 cm below the joint line and parallel to the posterior tibial slope. An anteroposterior hole is created by over drilling the wire by a 5-mm cannulated drill bit. This patient had received previous guided growth surgery. The screws of the guided growth plates were broken and were decided to be left in place during index surgery to act as physal markers for the lateral epiphysiodesis; **c**) a Gigli saw is passed from anterior through the drilled hole (white arrow) and retrieved posteriorly (black arrow), Hohman retractor protecting the patellar tendon (asterisk), the reflected posterior periosteum (white arrow head); **d**) the osteotomy is completed from inside outwards with attention to keep the direction of cutting at first parallel to the tibial axis then curving medially, instead of aiming medially from the start. This preserves bone stock of the medial condyle especially in cases with severe depression; **e**) gradual medial plateau elevation using a laminar spreader; **f**) elevation continues until the medial and lateral plateau surfaces were perfectly parallel. Elevation was made easier with the knee held in valgus by an assistant to increase room for the medial compartment. The articular hinge remains intact despite acute elevation; **g**) the fibular graft inserted anterior to the laminar spreader; **h**) the graft is impacted to support the elevated condyle and the laminar spreader is removed, the plateau remains levelled. Posterior plateau depression can be corrected at this point by placing the graft more posteriorly and confirmed under fluoroscopy.

The procedure is divided into four parts:

(a) Epiphysiodesis of lateral part of the proximal tibial physis and the fibula, performed by percutaneous curettage and drill holes traversing the physis.

(b) Fibular osteotomy at the junction between the middle and distal thirds to ease valgization. A 2-cm segment was resected to be used later as structural support for MP elevation.

(c) Medial plateau elevation. The anteromedial surface of the tibia was approached through a 15-cm longitudinal incision extending from the level of joint line downwards, midway between the anterior tibial crest and the posteromedial tibial border. The pes anserinus insertion was retracted posteriorly to expose the anteromedial tibial surface. The osteotomy exit is planned to be distal to the medial collateral ligament attachment. Subperiosteal dissection was continued posteriorly, elevating the medial gastrocnemius and popliteus in a direction aiming at the centre of the tibial plateau posteriorly. A blunt Hohmann retractor was placed and strict subperiosteal placement was confirmed to protect the neurovascular structures. Dissection continued anteriorly towards the centre of the tibial plateau behind the

patellar tendon, and a second Hohman retractor was put in place. To avoid the risk of intraarticular fracture and medial condyle displacement, an ‘inside-out’ osteotomy technique was utilized to keep the articular hinge intact (Fig. 2).

(d) Metaphyseal osteotomy. The elevated MP restores the articular congruence, but only partially corrects the tibial mechanical axis which remains distorted in varus at the metaphyseal-diaphyseal junction. A single oblique-plane osteotomy was performed for simultaneous correction of varus and internal torsion (Fig. 3). This osteotomy was found to lessen the amount of the inevitable translational deformity induced at the osteotomy level with acute correction (osteotomy rule 2),²⁶ and hence the easier seating of the plate to the anteromedial tibial surface. Upon completion of the osteotomy, the distal fragment was rotated externally resulting in simultaneous valgus and rotational correction. Rotational alignment was checked by realigning the tibial tubercle with the second toe. Frontal-plane alignment was confirmed with an electrocautery cord stretched across the skin from the centres of the hip to the ankle. This should pass midway between the tibial eminences on an AP view of the knee.

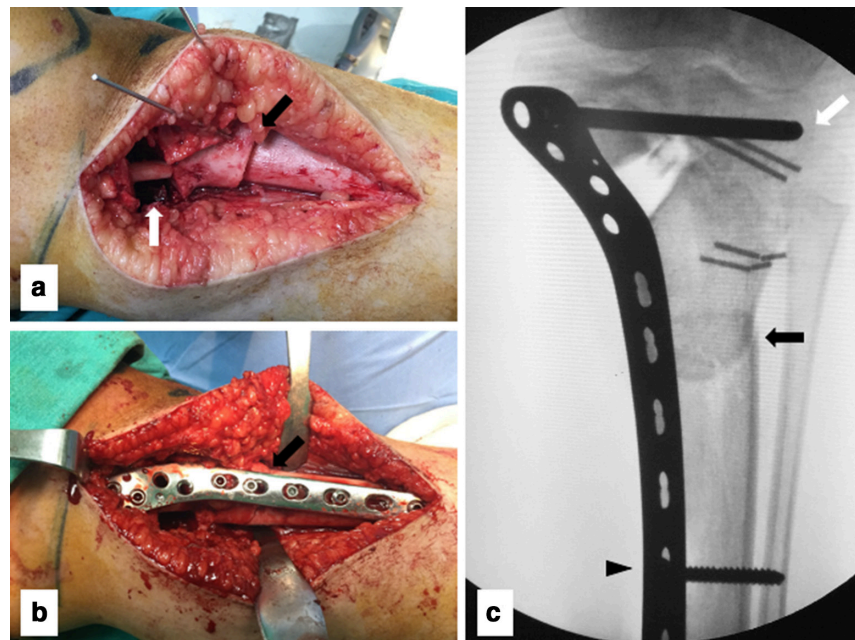


Fig. 3 The second oblique-plane metaphyseal osteotomy for correction of residual varus and internal tibial torsion: **a)** the osteotomy starts 1 cm below the tibial tubercle (black arrow) and directed superiorly at an angle 45° to the tibial shaft. The osteotomy can be temporarily supported by Kirschner-wires while the limb alignment is checked for frontal and rotational alignment. The first osteotomy can be seen elevated by the impacted fibular strut (white arrow); **b)** a proximal tibial locking compression plate applied to the medial tibial surface. The oblique metaphyseal osteotomy can be seen behind the plate (black arrow); **c)** the final alignment with the plate applied. No iatrogenic translational deformity is induced at the metaphyseal osteotomy and the plate is easily seated to the medial surface. The overlapping shadows as the distal fragment rotated externally resulting in simultaneous valgus correction (black arrow). A 4.5-mm compression screw applied first (black arrowhead) to provide buttress effect to the elevated medial condyle. Proximal locking screw (white arrow) placed in the epiphysis to hold the elevated medial condyle, and crossing the midline to ensure effective lateral epiphysiodesis.

Internal fixation. Both osteotomies were then fixed by a single 4.5-mm proximal tibial LCP (Synthes AG, Davos, Switzerland) (Fig. 3c). The plate was placed on the medial tibial side to buttress the elevated medial condyle. Proximal locking screws of the plate were placed in the epiphysis to hold the elevated medial condyle, and crossing the midline to ensure effective lateral epiphysiodesis. Wound closure in layers was done with placement of a suction drain.

Additional procedures

One case in this series had concurrent medial distal femoral hemiepiphysiodesis by 8-plate to address distal femoral valgus secondary to medial femoral condyle hypertrophy. The 8-plate was removed after five months after a neutral mechanical axis was restored on standing long film.

Postoperative management

No plaster or slab immobilization was applied. The patients were allowed to start passive and active knee ROM exercises, as well as quadriceps strengthening exercises. Closed chain kinetic exercises in the form of active and passive heel slides in bed, as well as knee flexion and

extension in the sitting position were instructed early after surgery. Patients were kept toe-touch bearing on the operated side for six weeks. Radiographs were then repeated to start progressive weight-bearing accordingly and then repeated every month till full consolidation of both osteotomies is achieved.

All patients were re-evaluated at six-month intervals till the latest follow-up. Clinical and functional assessment using the PODCI score, goniometric knee ROM measurements and radiographic measurements were assessed at six months after surgery and repeated at the final follow-up. Undercorrection was defined as medial mechanical axis deviation with respect to the centre of the knee on full-length standing radiographs and/or anatomical TFA < 0° and/or ADMP > 10° with persistent lateral laxity or varus thrust gait. Deformity recurrence was defined as a medial mechanical axis deviation with respect to the centre of the knee on standing radiographs²⁶ and/or anatomical TFA < 0°. For validity of results, postoperative assessments were performed by the non-operating surgeons.

Statistical analysis

Pre- and postoperative values were compared for each case. Results were analyzed using the Statistical Package

for Social Science (SPSS 20; IBM Corp., Armonk, New York). Analytical statistics; the paired *t*-test, McNemar test and Wilcoxon signed rank test were used to assess the statistical significance. A *p*-value ≤ 0.05 was considered statistically significant. Correlation analysis (Pearson's method) was used to assess the strength of association between two quantitative variables, correlation coefficient '*r*' = 0.6 to 0.79 were considered as a strong correlation.

Results

Clinical parameters

Since only cases with advanced-stage Blount's disease were included, with significant MP depression and metaphyseal varus, all patients in this series notably had lateral ligamentous laxity in full knee extension. Varus thrust gait was recorded in all except two patients. The

Table 1 Improvements in the clinical parameters and paediatric outcomes data collection instrument (PODCI) score

| Parameters | | Preoperative | Postoperative | p-value | Significance |
|--------------------|-----------|------------------|----------------|-----------|--------------|
| PODCI score, % | Mean (SD) | 50.98 (19.92) | 88.81 (4.95) | < 0.001* | S |
| | Range | 30.5 to 85.5 | 82 to 97 | | |
| | 95% CI | 41.91 to 60.04 | 86.56 to 91.06 | | |
| Tibial torsion, ° | Mean (SD) | -27.43 (8.68) | 11.88 (2.71) | < 0.001* | S |
| | Range | -49 to -13 | 7 to 16 | | |
| | 95% CI | -31.38 to -23.48 | 10.65 to 13.11 | | |
| Lateral laxity (%) | Negative | 0 (0) | 21 (100) | < 0.001** | S |
| | Positive | 21 (100) | 0 (0) | | |
| Varus thrust (%) | Negative | 2 (9.52) | 21 (100%) | < 0.001** | S |
| | Positive | 19 (90.47) | 0 (0) | | |
| Knee flexion (°) | Mean (SD) | 130.67 (12.00) | 132.14 (11.24) | 0.219* | NS |
| | Range | 110 to 155 | 115 to 150 | | |
| Knee extension (°) | Median | 0 | 0 | 0.011*** | S |
| | IQR | -5 to 0 | 0 to 0 | | |
| | Range | -15 to 0 | -5 to 0 | | |

CI, confidence interval; S, significant; NS, non-significant; IQR, interquartile range

*paired t test

**McNemar test

***Wilcoxon signed rank test

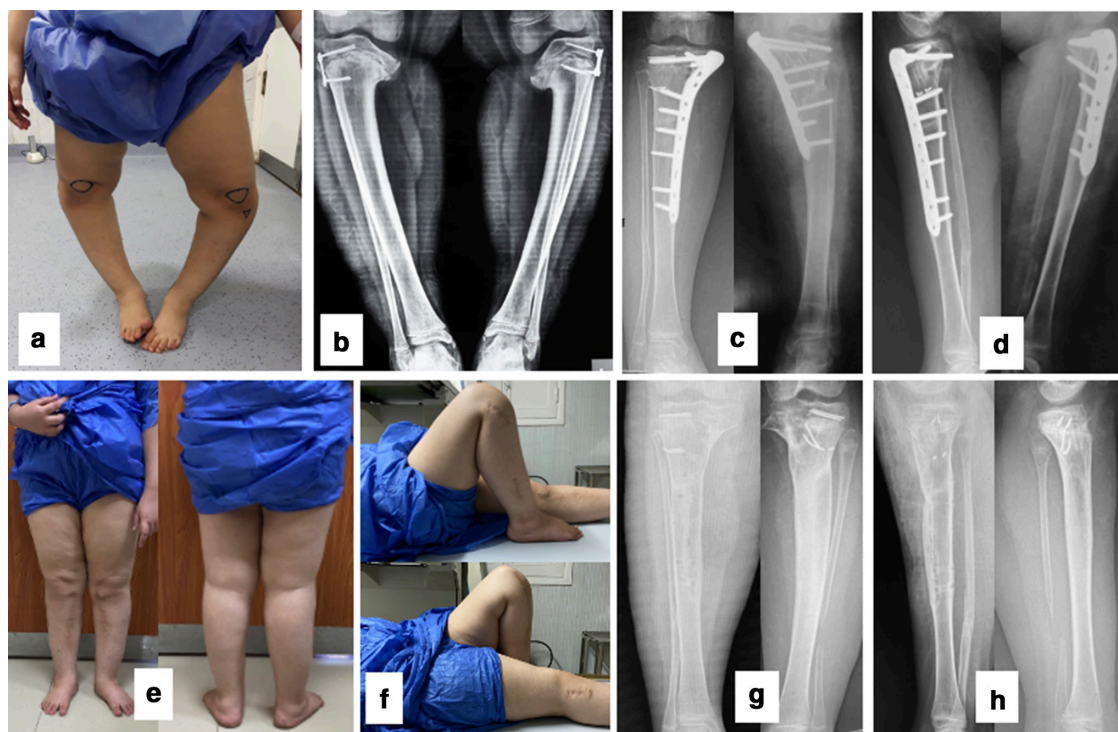


Fig. 4 A 9.3-year-old girl with bilateral late-presenting Blount's disease: **a)** preoperative varus malalignment; **b)** bilateral advanced-stage Blount's disease with significant medial plateau depressions on standing radiographs. The patient had received a previous hemiepiphysiodesis that failed with broken screws. The screws were left in place, acting as physseal markers; **c)** and **d)** six months postoperative radiographs, all osteotomies have consolidated; **e)** front and back coronal and rotational alignment at four-years postoperatively; **f)** maintained knee flexion range of movement; **g)** and **h)** anteroposterior and lateral radiographs upon plate removal.

Table 2 Improvements in the radiographic parameters

| | Preoperative | | | Postoperative | | | Paired t-test | |
|-----------|----------------|--------------|------------------|---------------|------------|----------------|---------------|--------------|
| | Mean (SD) | Range | 95% CI | Mean (SD) | Range | 95% CI | p-value | Significance |
| TFA (°) | -29.66 (10.39) | -51 to -15.5 | -34.39 to -24.93 | 7.05 (1.21) | 5 to 9.5 | 6.5 to 7.6 | < 0.001 | S |
| mLDFA (°) | 84.14 (3.23) | 75.5 to 89.5 | 82.67 to 85.61 | 85.57 (1.91) | 81 to 90 | 84.7 to 86.44 | 0.019 | S |
| MPTA (°) | 47.10 (12.11) | 30 to 69.5 | 41.58 to 52.61 | 86.36 (3.05) | 79 to 90.5 | 84.97 to 87.75 | < 0.001 | S |
| ADMP (°) | 38.31 (10.73) | 21.5 to 53 | 33.42 to 43.2 | 2.46 (1.85) | 0 to 6.6 | 1.62 to 3.3 | < 0.001 | S |
| MDA (°) | 33.45 (6.83) | 22 to 46.5 | 30.35 to 36.56 | 4.76 (1.42) | 2 to 6 | 4.12 to 5.41 | < 0.001 | S |
| PPTA (°) | 70.74 (7.97) | 49.5 to 85.5 | 67.11 to 74.37 | 81.43 (3.12) | 75 to 86 | 80.01 to 82.85 | < 0.001 | S |
| LLD (cm) | 1.64 (0.72) | 0.4 to 2.6 | 1.29 to 1.99 | 0.40 (0.22) | 0.2 to 0.8 | 0.29 to 0.51 | < 0.001 | S |

CI, confidence interval; S, significant; TFA, tibiofemoral angle; mLDFA, mechanical lateral distal femoral angle; MPTA, medial proximal tibial angle; ADMP, angle of depressed medial plateau; MDA, metaphyseal-diaphyseal angle; LLD, limb-length discrepancy

gait pattern improved in all patients; the percentage of patients with a positive lateral laxity and varus thrust declined significantly (Table 1). All patients maintained full knee extension at the final follow-up (Fig. 4). Tibial torsion was corrected significantly from a mean 27.4° (SD 8.68°) of internal torsion to 11.8° (SD 2.71°) external torsion (p < 0.001). The mean PODCI score improved significantly from 50.9% (SD 19.92%) preoperatively to 88.8% (SD 4.95%) at the latest follow-up (p < 0.001).

Radiographic parameters

Nine limbs were classified as stage V, while 12 limbs were classified as stage VI. All the radiographic parameters improved significantly after the procedure and were maintained to the latest follow-up (Table 2, Fig. 4). Osteotomies completely united at an mean of 4.8 months (3.5 to 6). The mean anatomical TFA was significantly corrected from -29.6° (-51° to -15.5°) to 7.0° (5° to 9.5°). The ADMP also significantly corrected from a mean of 38.3° (21.5° to 53°) to 2.4° (0° to 6.6°). The mLDFA showed a less significant correction compared with the other radiographic angles. No cases of deformity recurrence were identified at their latest follow-up. In all cases, LLD at the final follow-up was < 1 cm. No cases required a second-stage tibial lengthening.

Complications

One patient who had three metaphyseal osteotomies prior to the index procedure developed a superficial infection at the proximal end of the surgical wound. This resolved with antibiotics and dressings alone. This patient has union of both osteotomies at 3.5 months and had a final PODCI score of 82% at three years follow-up. Two patients had irritation by prominent hardware at the proximal tibia and had elective plate removal three years after surgery in one patient and four years after surgery in the other. Their corrections were maintained to the latest follow-up with no evidence of recurrence. Two patients developed hypertrophic scar formation. No cases of deformity recurrence, hardware failure, transient or permanent neurologic injury were found till the final follow-up.

Discussion

The current study evaluates the safety and efficacy of a new surgical technique for double-elevating osteotomy that allows acute correction of MP depression, restoring joint congruity, with a second osteotomy for correction of residual metaphyseal varus and ITT. A technique that allows acute MP elevation to be conducted safely is also presented, and the authors believe this is the first study to utilize rigid internal fixation for fixation of both osteotomies, precluding external immobilization and allowing for early postoperative ROM.

The previously described techniques for MP elevation were associated with potential risks of intra-articular fractures, medial condyle displacement and inadequate MP elevation with persistent lateral laxity.^{15,20} Furthermore, studies conducting gradual elevation with Ilizarov have reported various complications, including pin-site irritation, interference with rehabilitation, pin-tract infection, pin breakage, premature consolidation, undercorrection and deformity recurrence.^{8,14,17,18,21} A summary of previous studies with similar procedures, fixation methods and complications is shown (Table 3).

Jones et al⁸ reported a series of seven patients with severe infantile Blount's disease, performed the procedure in two stages, with gradual correction using Ilizarov. Three patients in their series had premature consolidation, two of which required revision surgery. One of these patients was corrected by repeat medial condyle elevation osteotomy with bone grafting, the second patient had premature consolidation with pin breakage that necessitated revision of the osteotomy. Six out of seven patients remained in varus malalignment (mean TFA of -6°), and the mean ADMP was 11° after operation. Similarly, Hefny et al¹⁴ reported a series of five patients (seven knees) with gradual MP elevation and metaphyseal osteotomy using the Ilizarov method. The final mean TFA was -4° of varus, the final ADMP was corrected to a mean of 10° depression. Fitoussi et al¹³ reported a similar technique in six patients (eight knees), but performed acute MP elevation, with Ilizarov fixation. The final mean ADMP was 5.4°. They reported an overall good mechanical alignment with

Table 3 Summary of previous studies with similar procedures

| | Number of patients (limbs) | Mean age at surgery, yrs | Mean follow-up, yrs | Procedures | Fixation method | Mean postoperative TFA (°) | Mean postoperative ADMP (°) | Recurrence rate (%) | Other complications (limbs) |
|------------------------------------|----------------------------|--------------------------|---------------------|--|---|----------------------------|-----------------------------|---------------------|--|
| Schoenecker et al ¹¹ | 7 (7) | 12.6 | 3.1 | Single-stage (3), two-stage (4) | Kirschner-wires, screws, plates | 4 | 10 | 0 (0) | 3 undercorrection, 1 temporary CPN palsy |
| Jones et al ⁸ | 7 (7) | 10.5 | 2.4 | First stage MP elevation, second-stage lengthening/valgus/derotation or lateral epiphysiodesis | Ilizarov | -6 | 11 | 0 (0) | 7 PTI, 3 premature consolidation, 2 undercorrection, 1 pin breakage |
| Hefny et al ¹⁴ | 5 (7) | 11.6 | 6.2 | Single-stage double osteotomy, gradual correction | Ilizarov | -4 | 10 | 0 (0) | 7 PTI |
| Hefny and Shalaby ²⁰ | 8 (12) | 9 | 5 | Single-stage double osteotomy, gradual correction | Ilizarov | -5 | 8 | 0 (0) | 4 PTI |
| Fitoussi et al ¹³ | 6 (8) | 10.5 | 4.0 | Single-stage, acute MP elevation, double osteotomy, lateral epiphysiodesis | Ilizarov | N/A | 5.4 | 1 (12.5) | 1 temporary CPN palsy, 1 premature fibular consolidation, 1 deep infection, 1 necrosis around wire |
| McCarthy et al ¹⁵ | 16 (22) | 8.8 | 4.14 | Acute MP elevation, tibial gradual osteotomy | Ilizarov | 3 | 12 | 5 (31) | 5 undercorrection, 3 PTI, 1 septic knee |
| Gkiokas and Brilakis ¹⁰ | 8 (9) | 12 | 10 | Single-stage | Staples, Kirschner-wires, plates, plaster | -2 | 10 | 0 (0) | 2 slight varus undercorrection |
| Abraham et al ¹² | 23 (29) | | 7.3 | Single-stage, dome metaphyseal osteotomy, lateral epiphysiodesis | Lateral plate, Kirschner-wires, plaster | 1 | N/A | N/A | 8 undercorrection, 1 superficial infection, 1 deep infection, 1 wound dehiscence, 1 transient CPN injury, 1 permanent partial CPN injury |
| Current study | 19 (21) | 10.3 | 5.1 | Single-stage MP elevation, metaphyseal osteotomy | Medial LCP | 7.05 | 2.46 | 0 (0) | 1 superficial infection, 2 hardware prominence, 2 hypertrophic scars |

TFA, tibiofemoral angle, negative values indicate varus, positive values indicate valgus; ADMP, angle of depressed medial plateau; CPN, common peroneal nerve; MP, medial plateau; PTI, pin-tract infection; LCP, locking compression plate

recurrence in one patient due to incomplete lateral epiphysiodesis. McCarthy et al¹⁵ retrospectively reviewed 16 patients (22 limbs) with advanced-stage Blount's disease who had acute MP elevation with concurrent metaphyseal gradual osteotomy. Five patients had undercorrection and deformity recurrence, and this was attributed by the authors to the gradual metaphyseal osteotomy not the acute MP elevation.

Gradual distraction by Ilizarov/external fixator methods may be inconvenient for patients postoperatively; calculation of the rate of distraction and hinge modification during correction may be cumbersome and many cases may need Ilizarov frame adjustments. Undercorrection and deformity recurrence with Ilizarov has been attributed to premature consolidation, undercorrection, pin breakage, frame removal before complete osteotomy consolidation and that an endpoint for gradual correction based on mechanical axis alignment was not defined in these studies.^{8,14,15} Accordingly, gradual correction by Ilizarov may be reserved for cases where there is a poor soft-tissue envelope, when significant LLD needs to be simulta-

neously addressed and for adolescent tibia vara where depression of the MP is less severe.¹²

The current study constitutes evidence that utilizing a single-stage MP elevation and metaphyseal osteotomies with rigid internal fixation has significantly improved the clinical and radiographic parameters in late-presenting infantile Blount's disease; restoring joint congruence, offering rigid internal fixation, avoiding plaster immobilization, as well as avoiding the previously reported adverse effects of gradual distraction. The technique described in the present study has demonstrated several advantages. Acute intraoperative MP elevation permitted precise levelling up with the lateral plateau that can be confirmed intraoperatively under image intensifier, with restoration of knee joint congruence. The described 'inside-out' technique for medial condyle osteotomy preserves an intact cartilaginous hinge. The drilled anteroposterior hole reduces the stress concentration drastically in this area by reducing the notch effect, preventing crack propagation into the articular surface. This has allowed safe elevation of even largely depressed MP, while avoiding the risk of

intra-articular fracture, medial condyle displacement and loss of correction. Acute elevation of ADMP as high as 53° was safely conducted in the current study without intra-articular fractures occurring in any case.

Additionally, the acute elevation has shown consistent healing potential with rapid filling of the acute defect, obviating the need for gradual distraction or massive bone grafting, only a 2-cm fibular strut to maintain elevation while fixation is being carried out. Our results have not shown any union problems or soft-tissue complications, and at the same time avoids the adverse effects and complications reported with gradual distraction.^{8,14,18,21} The presented technique has achieved a greater mean elevation of the MP (mean postoperative ADMP of 2.46° (SD 1.85°)) compared with studies employing gradual distraction (Table 3). It also allowed correction of the posterior slope by placing the graft posteriorly with confirmation under an image intensifier. A similar technique for MP elevation using a Gigli saw has been described before in a single report by Hefny et al,²⁰ but in the setting of gradual elevation by Ilizarov. The authors highlighted its safety regarding avoiding potential risk of intraoperative fractures, which the current study has demonstrated further, permitting a confident acute correction with precise intraoperative joint levelling. Compared with the current study, the previously reported technique with gradual correction has achieved a mean postoperative ADMP of 8° with a mean limb alignment of 4° of varus TFA.

After MP elevation and restoration of articular congruity, the tibial mechanical axis will remain distorted in varus at the metaphyseal-diaphyseal junction. A second metaphyseal osteotomy was conducted for simultaneous correction of residual varus and ITT. This was performed as a single oblique-plane osteotomy, allowing simultaneous valgization and external rotation (Figs 3a and 3b). When compared with conventional osteotomy techniques such as transverse and closing wedge, the oblique-plane osteotomy has been favourably reported to avoid creating iatrogenic translational deformities previously noted with acute correction.^{5,16} We utilized this particular feature to minimize the amount of translation and hence it was easier to adapt the plate to the tibial surface (Fig. 3c). The osteotomy also provides a larger healing surface area and avoids unnecessary limb shortening with closing wedge techniques. Oblique tibial osteotomy has been described before and has proven to be effective in acute correction of both varus and ITT deformities in Blount's disease,^{29,30} but has never been performed with MP elevation or internal fixation. Utilizing this osteotomy, our data has demonstrated significant correction of the mean ITT (from -27.4° to 11.8° external torsion) and the MDA (from 33.4° to 4.7°). Combined with MP elevation, a significant correction of the lower limb alignment has been estab-

lished. The mean TFA and MPTA have been corrected to physiological values of 7.0° and 86.3°, respectively (Table 2), and were maintained to the final follow-up.

Since most cases of Blount's disease have nearly equal degrees of MDA and ITT, a 45° upward-sloping cut from distal-anterior to proximal-posterior has been appropriate for clinical correction in all cases, and variations in inclination angle have not proven to be necessary.²⁹ The original description of oblique osteotomy only relied on limited internal fixation by screws and had to use postoperative cast immobilization. In the current study, a proximal tibial LCP was used and served several functions. It secures both the MP elevation and metaphyseal oblique osteotomies, provides a buttress effect to the elevated medial condyle being applied to the medial surface; the proximal screws traverse the epiphysis from medial to lateral to ensure lateral epiphysiodesis (Fig. 3c). The plate also provides rigid internal fixation that precludes postoperative immobilization, allows early knee ROM and improves patient's postoperative satisfaction. The plate also offered sufficient rigidity of fixation that avoided loss of correction previously reported with screw-only fixation.²⁹

A single-stage double elevating osteotomy with internal is infrequently discussed in the literature. Gkiokas and Brilakis¹⁰ conducted acute MP elevation and metaphyseal osteotomies on a series of eight patients (nine limbs). A closing wedge was resected from the metaphyseal osteotomy that was used to support MP elevation. They relied on staples, Kirschner-wires and plates for fixation of the metaphyseal osteotomy, and Kirschner-wires for the elevated MP with postoperative plaster immobilization in all cases. Mechanical axis alignment was not used to assess their correction and recurrence, instead they relied on the TFA. The technique they reported started with the metaphyseal osteotomy first, achieving correction of the TFA of 10° to 15°, before correcting the MP depression and restoring joint congruence which might affect reliability of assessment of limb alignment. At their latest follow-up, only two limbs had a valgus TFA of only 2°, while the rest remained in varus undercorrection ranging from -8° to -1°. The osteotomy technique they described for MP elevation started from the medial bone surface towards the intercondylar area. Their final mean ADMP was 10°, in two limbs the angles were 18° and 22°, and in the rest of the seven limbs the angles ranged from 2° to 9°. This policy is different from the present technique where joint congruence is restored first followed by correcting mechanical alignment through the metaphyseal osteotomy so that the depressed MP and joint incongruence would not affect measurement of overall limb alignment. This would also eliminate the possible change to corrected limb alignment after MP elevation. Additionally, performing a lateral closing wedge metaphyseal osteotomy would

further increase the limb shortening in unilateral cases. The oblique-plane osteotomy can be regarded as more of a length-preserving technique.

Abraham et al¹² conducted a single-stage double osteotomy with acute correction on a series of 23 cases (29 limbs) with advanced Blount's disease. They described a procedure through a midline anterior incision, a dome osteotomy above the tibial tubercle to correct metaphyseal varus and ITT, with application of a plate on the lateral tibial surface. Limb alignment was adjusted at this stage to neutral or 5° valgus before MP elevation. The epiphyseal screws of the plate were advanced only to the midline, to allow for subsequent MP elevation, but did not offer fixation to the elevated medial condyle. They relied on Kirschner-wires for fixation for the elevated MP, hence long-leg casts were applied for up to four months. A plate applied to the lateral surface can secure the metaphyseal osteotomy, but would not buttress the elevated medial condyle. At their final follow-up, eight out of the 29 limbs (27.5%) had a varus malalignment (negative TFA) and only 11 of 29 (38%) had a normal joint congruence.

The ideal age for a MP elevation has not been set in literature. Sabharwal⁵ recommended an age above six years for a proper size of the medial condyle that can hold fixation. Some authors recommended an age above eight years¹⁰ to avoid excessive limb shortening at maturity while others performed the procedure at age ten years and older.¹¹ Since the procedure involves definitive proximal tibial epiphysiodesis, only cases older than eight years were included in the current study to limit the potential LLD at skeletal maturity. Despite the premature physeal closure, the final LLD at the latest follow-up was not significant (< 1 cm). This was found to be consistent with previous reports.¹⁰

Distal femoral valgus secondary to medial femoral condyle hypertrophy is frequently reported with infantile Blount's disease, probably in response to the facing MTP growth deficit.^{11,13} One of the cases in the current series was an 8.2-year-old girl with unilateral stage VI Blount's disease, TFA of -21.5° and ADMP of 53°. The mL DFA measured 75.5° on preoperative radiographic assessment, denoting compensatory distal femoral valgus. This was managed by concurrent medial distal femoral epiphysiodesis by 8-plate. A corrected mechanical axis was achieved at five months after surgery and the 8-plate was removed. She had a final anatomical TFA of 8°, ADMP of 2.5° and mL DFA of 83.5°.

The current study has several limitations. The mean follow-up in this study was 5.1 years. However, all patients are approaching skeletal maturity at their latest follow-up. Despite satisfactory outcome regarding the joint congruence and limb alignment, longer-term evaluation will be needed for confirmation of LLD at full skeletal maturity to determine if any length-equalizing procedure is required.

Tibiofemoral disproportion secondary to premature tibial epiphysiodesis and the resultant cosmetic concern needs to be addressed in further studies. Instrumented gait analysis to quantify varus thrust and internal torsion was not conducted. The authors relied on preoperative observational gait assessment and clinical examination for knee instability in full extension. This was found to be consistent with previously reported techniques^{10,13,15} and the authors believe it did not negatively impact the decision or the surgical outcome. Mechanical lower limb alignment was determined by intraoperative fluoroscopy using the cautery cord stretched across the knee from the hip to the ankle centres. This method is frequently utilized and has shown a linear correlation with standing full-length radiographs.³¹ However, this method was less reliable in obese patients, and those with ligamentous laxity and incongruent knees. In order to obtain a reliable measurement, the current technique starts with MP elevation first, followed by visualization of mechanical alignment during the second osteotomy in limbs with congruent knees.

In summary, management of late-presenting infantile Blount's disease is technically challenging with potential intraoperative complications. Acute MP elevation and metaphyseal osteotomies through the described technique provide a comprehensive, safe and effective single-stage management of this complex deformity, avoiding the adverse effects of gradual distraction, with no evidence of recurrence. The procedure demonstrated capability of acute correction of even large angles of depressed MP without the need for large bone grafts. The resected fibular segment adequately supported the elevated condyle with good incorporation. In addition, acute elevation with confirmation of joint levelling and congruence with the femoral articular surface has proven to be a precise correction, significantly improving knee instability and varus thrust. The oblique-plane metaphyseal osteotomy simultaneously corrected residual varus and ITT without iatrogenic translational deformity. Rigid internal fixation provided by the LCP obviates the need for external splinting and allows early ROM, provides buttress fixation to the elevated medial condyle, together with an epiphysiodesis effect to the lateral physis. Based on the presented outcomes, we recommend this procedure for late-presenting Blount's disease.

Received 9 July 2020; accepted after revision 25 November 2020.

COMPLIANCE WITH ETHICAL STANDARDS

FUNDING STATEMENT

No benefits in any form have been received or will be received from a commercial party related directly or indirectly to the subject of this article.

OA LICENCE TEXT

This article is distributed under the terms of the Creative Commons Attribution-Non Commercial 4.0 International (CC BY-NC 4.0) licence (<https://creativecommons.org/licenses/by-nc/4.0/>) which permits non-commercial use, reproduction and distribution of the work without further permission provided the original work is attributed.

ETHICAL STATEMENT

Ethical approval: All procedures performed in studies involving human participants were in accordance with the ethical standards of the institutional and/or national research committee and with the 1964 Helsinki declaration and its later amendments or comparable ethical standards. The study was approved by our institution's Ethical Committee of Scientific Research.

Informed consent: Informed consent was obtained from all individual participants included in the study. All parents consented to and were informed that data concerning this study would be submitted for publication.

ICMJE CONFLICT OF INTEREST STATEMENT

None declared.

AUTHOR CONTRIBUTIONS

MMB: Conceived and designed the study, Drafted the manuscript, Particularly involved in literature search, One of the main operating surgeons, Involved in analysis and interpretation of data, Reviewed the final manuscript critically for important intellectual content, Approved the final version.

HMH: One of the main operating surgeons, Reviewed the final manuscript critically for important intellectual content, Approved the final version.

MAM: Contributed to manuscript, One of the main operating surgeons, Reviewed the final manuscript critically for important intellectual content, Approved the final version.

TAF: Patients follow-up, Functional evaluation, acquisition, analysis, and interpretation of data, Reviewed the final manuscript critically for important intellectual content, Approved the final version.

HA: Patients follow-up, Functional evaluation, acquisition, analysis and interpretation of data, Reviewed the final manuscript critically for important intellectual content, Approved the final version.

AN: Patients follow-up, functional evaluation, acquisition, analysis, and interpretation of data, reviewed the final manuscript critically for important intellectual content, approved the final version.

SUPPLEMENTAL MATERIAL

Supplemental material is available for this paper at <https://online.boneandjoint.org.uk/doi/suppl/10.1302/1863-2548.15.200157>

REFERENCES

1. **Blount WP.** Tibia vara: osteochondrosis deformans tibiae. *JBJS* 1937;19:1-29.
2. **Sabharwal S, Lee J Jr, Zhao C.** Multiplanar deformity analysis of untreated Blount disease. *J Pediatr Orthop* 2007;27:260-265.
3. **Siffert RS, Katz JF.** The intra-articular deformity in osteochondrosis deformans tibiae. *J Bone Joint Surg [Am]* 1970;52-A:800-804.
4. **Langenskiöld A.** Tibia vara: osteochondrosis deformans tibiae. Blount's disease. *Clin Orthop Relat Res* 1981;158:77-82.
5. **Sabharwal S.** Blount disease. *J Bone Joint Surg [Am]* 2009;91-A:1758-1776.
6. **Langenskiöld A, Riska EB.** Tibia vara (osteochondrosis deformans tibiae): a survey of seventy-one cases. *J Bone Joint Surg [Am]* 1964;46-A:1405-1420.
7. **Zayer M.** Osteoarthritis following Blount's disease. *Int Orthop* 1980;4:63-66.
8. **Jones S, Hosalkar HS, Hill RA, Hartley J.** Relapsed infantile Blount's disease treated by hemiplateau elevation using the Ilizarov frame. *J Bone Jt Surg - Ser B* 2003;85:565-571.
9. **van Huyssteen AL, Hastings CJ, Olesak M, Hoffman EB.** Double-elevating osteotomy for late-presenting infantile Blount's disease. The importance of concomitant lateral epiphysiodesis. *J Bone Jt Surg - Ser B* 2005;87:710-715.
10. **Gkiokas A, Brilakis E.** Management of neglected Blount disease using double corrective tibia osteotomy and medial plateau elevation. *J Child Orthop* 2012;6:411-418.
11. **Schoenecker PL, Johnston R, Rich MM, Capelli AM.** Elevation of the medial plateau of the tibia in the treatment of Blount disease. *J Bone Jt Surg - Ser A* 1992;74:351-358.
12. **Abraham E, Toby D, Welborn MC, Helder CW, Murphy A.** new single-stage double osteotomy for late-presenting infantile tibia vara: a comprehensive approach. *J Pediatr Orthop* 2019;39:247-256.
13. **Fitoussi F, Ilharreborde B, Lefevre Y, et al.** Fixator-assisted medial tibial plateau elevation to treat severe Blount's disease: outcomes at maturity. *Orthop Traumatol Surg Res* 2011;97:172-178.
14. **Hefny H, Shalaby H, El-Kawy S, Thakeb M, Elmoatasem E.** A new double elevating osteotomy in management of severe neglected infantile tibia vara using the Ilizarov technique. *J Pediatr Orthop* 2006;26:233-237.
15. **McCarthy JJ, MacIntyre NR III, Hooks B, Davidson RS.** Double osteotomy for the treatment of severe Blount disease. *J Pediatr Orthop* 2009;29:115-119.
16. **Feldman DS, Madan SS, Ruchelsman DE, Sala DA, Lehman WB.** Accuracy of correction of tibia vara: acute versus gradual correction. *J Pediatr Orthop* 2006;26:794-798.
17. **Coogan PG, Fox JA, Fitch RD.** Treatment of adolescent Blount disease with the circular external fixation device and distraction osteogenesis. *J Pediatr Orthop* 1996;16:450-454.
18. **Alekberov C, Shevtsov VI, Karatosun V, Günal I, Alici E.** Treatment of tibia vara by the Ilizarov method. *Clin Orthop Relat Res* 2003;409:199-208.
19. **Wright J, Calder P.** Severe infantile Blount's disease: hemiplateau elevation and metaphyseal correction with use of the taylor spatial frame. *J Limb Lengthening Reconstr* 2018;4:76.
20. **Hefny H, Shalaby H.** A safer technique for the double elevation osteotomy in severe infantile tibia vara. *Strategies Trauma Limb Reconstr* 2010;5:79-85.
21. **De Pablos J, Azcarate J, Barrios C.** Progressive opening-wedge osteotomy for angular long-bone deformities in adolescents. *J Bone Jt Surg - Ser B* 1995;77:387-391.
22. **Levine AM, Drennan JC.** Physiological bowing and tibia vara. The metaphyseal-diaphyseal angle in the measurement of bowleg deformities. *J Bone Jt Surg - Ser A* 1982;64:1158-1163.
23. **Staheli LT, Corbett M, Wyss C, King H.** Lower-extremity rotational problems in children. Normal values to guide management. *J Bone Joint Surg [Am]* 1985; 67-A:39-47.
24. **Haynes RJ, Sullivan E.** The Pediatric Orthopaedic Society of North America pediatric orthopaedic functional health questionnaire: an analysis of normals. *J Pediatr Orthop* 2001;21:619-621.
25. **Jones JK, Gill L, John M, Goddard M, Hambleton IR.** Outcome analysis of surgery for Blount disease. *J Pediatr Orthop* 2009;29:730-735.

26. **Paley D.** *Principles of Deformity Correction*. Herzenberg J, ed. Berlin, Heidelberg: Springer Berlin Heidelberg, 2002.
27. **Salenius P, Vankka E.** The development of the tibiofemoral angle in children. *JBS* 1975;57:259-261.
28. **Sabharwal S, Zhao C, McKeon J, et al.** Reliability analysis for radiographic measurement of limb length discrepancy: full-length standing anteroposterior radiograph versus scanogram. *J Pediatr Orthop* 2007;27:46-50.
29. **Rab GT.** Oblique tibial osteotomy revisited. *J Child Orthop* 2010;4:169-172.
30. **Rab GT.** Oblique tibial osteotomy for Blount's disease (tibia vara). *J Pediatr Orthop* 1988;8:715-720.
31. **Sabharwal S, Zhao C.** Assessment of lower limb alignment: Supine fluoroscopy compared with a standing full-length radiograph. *J Bone Jt Surg - Ser A* 2008;90:43-51.