



Contents lists available at ScienceDirect

## International Journal of Surgery Case Reports

journal homepage: [www.casereports.com](http://www.casereports.com)

# Single incision laparoscopic surgery approach for obscure small intestine bleeding localized by CT guided percutaneous injection of methylene blue



Juan Carlos Martinez<sup>a,\*</sup>, Jamie L. Thomas<sup>b</sup>, John J. Lukaszczyk<sup>a,1</sup>

<sup>a</sup> Department of Surgery, St Luke's University Hospital, Bethlehem, PA 18015, USA

<sup>b</sup> Department of Radiology, St Luke's University Hospital, Bethlehem, PA, USA

## ARTICLE INFO

## Article history:

Received 25 February 2014

Received in revised form 18 May 2014

Accepted 21 June 2014

Available online 16 October 2014

## Keywords:

Single incision laparoscopy

Obscure small intestine bleeding

CT guided percutaneous localization

Methylene blue

## ABSTRACT

**INTRODUCTION:** Traditionally, localization of small intestine sources of obscure gastrointestinal bleeding has been a challenge. Advances in the field of endoscopy with the introduction of capsule endoscopy and radiographic imaging with computed tomography angiography and visceral angiography have facilitated more accurate visualization of the small intestine. If a bleeding lesion is identified on angiography and surgery is indicated, the use of methylene blue for enteric mapping is very effective to aid intraoperative localization of the culprit. However, when this is not an option, more invasive surgical techniques are required.

**PRESENTATION OF CASE:** We present a new technique used in a patient with angiodysplasia of the small intestine, in where preoperative localization was done using percutaneous computed tomography (CT) guided injection of methylene blue dye. This allowed us to perform a single incision laparoscopic small intestine resection of the culprit.

© 2014 The Authors. Published by Elsevier Ltd. on behalf of Surgical Associates Ltd. This is an open access article under the CC BY-NC-ND license (<http://creativecommons.org/licenses/by-nc-nd/3.0/>).

## 1. Introduction

The diagnosis and management of patients with obscure gastrointestinal bleeding (OGIB) traditionally has been very challenging due to the small intestine's length, tortuosity and anatomic location. Overall, lesions in the small intestine account for approximately 5% of cases with OGIB.<sup>1</sup> These subsets of patients are frequently subjected to extensive diagnostic work up, with inherent costly hospital expenses and potential procedure related complications. Moreover, the diagnostic yield is notoriously low. Patients with OGIB typically present with occult blood loss or recurrent episodes of melena or maroon stool without a specific diagnosis. Recent innovations in endoscopic technology have resulted in more effective small intestine imaging such as capsule endoscopy (CE) and deep enteroscopy. The diagnostic yield and therapeutic capabilities of these technologies have been compared with conventional approaches of push endoscopy, intraoperative enteroscopy and radiographic methods.

We report a case of a patient with a jejunal arteriovenous malformation (AVM) identified by computed tomography angiography

(CTA) that was successfully marked by preoperative percutaneous computed tomography (CT)-guided injection of methylene blue. This innovative preoperative localization technique was followed by single incision laparoscopic surgery (SILS) with selective segmental jejunum resection.

## 2. Case

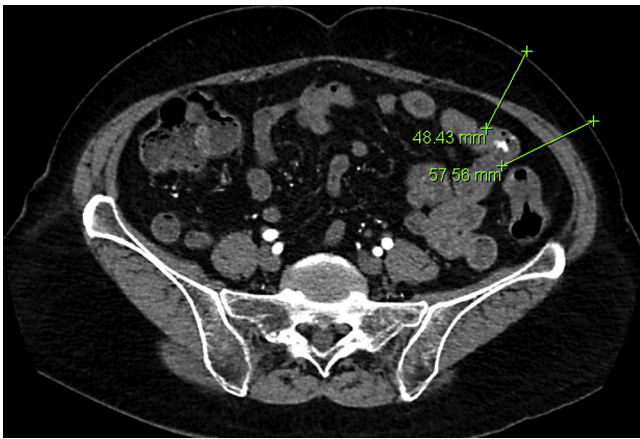
The patient is an 82-year-old white female who had a two-year history of gastrointestinal bleeding of unknown source. Previous studies included multiple upper and lower gastrointestinal (GI) endoscopies, as well as a capsule endoscopy without successful localization of a source of bleeding. She received approximately 104 units of packed red blood cells (PRBCs) over the previous 3 years due to chronic anemia refractory to iron supplements. Her most recent hemoglobin and hematocrit upon presentation were 7.8 g/dl and 25.1%. She was referred after an attempted arteriogram at an outside hospital, performed to localize and embolize the source of bleeding resulted in a partial dissection of the superior mesenteric artery (SMA). A multidisciplinary team decided to perform a computed tomography angiography (CTA) of the abdomen and pelvis to localize the source of bleeding and to assess the SMA dissection. This CTA demonstrated contrast extravasation from the mid jejunum on the left side of the abdomen with evidence of an early draining vein (Fig. 1). The lesion was compatible with an angiodysplasia of the small intestine. Repeating a mesenteric arteriogram

\* Corresponding author. Tel.: +1 484 526 2255; fax: +1 484 526 2220.

E-mail addresses: [drjcmg@yahoo.com](mailto:drjcmg@yahoo.com) (J.C. Martinez),

[John.Lukaszczyk@sluhn.org](mailto:John.Lukaszczyk@sluhn.org) (J.J. Lukaszczyk).

<sup>1</sup> Tel.: +1 484 526 2200; fax: +1 484 526 2220.



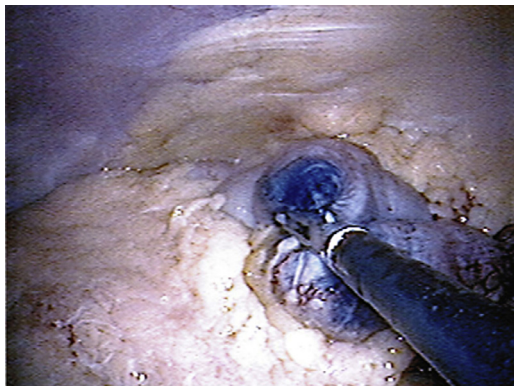
**Fig. 1.** Computed tomography angiography showing angiodysplasia of small intestine.

was felt to be unsafe; therefore an alternative method of localizing the lesion was necessary.

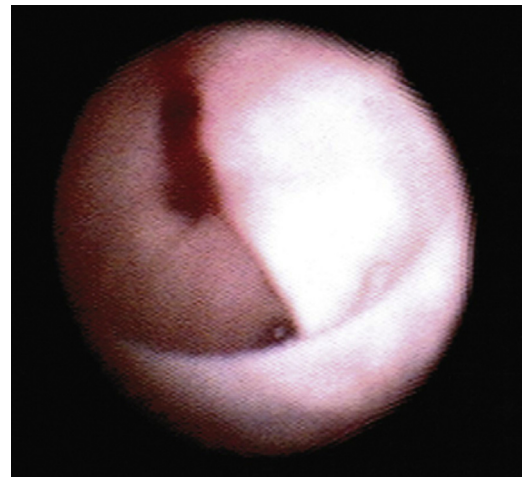
### 3. Procedure

After obtaining informed consent and counseling the patient about the planned procedure, a CT arteriogram of the mesenteric arteries was repeated, which confirmed the vascular malformation in the left lower quadrant. A 22-gauge needle was placed percutaneously using CT guidance into a left lower quadrant small intestine loop near the area of the aforementioned malformation. Then methylene blue (0.3 ml) was injected and the needle was removed. This was performed to tattoo the involved loop of small intestine to facilitate intraoperative localization of the lesion.

The patient was then taken directly to the operating room (OR). In the OR, an Olympus Quad port device (Olympus Corp. Tokyo, Japan) was used. This is a SILS access device. Carbon dioxide gas was insufflated in the usual fashion for standard laparoscopy. A laparoscopic exploration was then carried out. Having had prior surgery, the patient's omentum was adherent to the anterior abdominal wall making visualization of the entire abdomen difficult. The omentum was reflected to the right and the methylene blue tattooing was seen. The tattooed loop of intestine was grasped with a laparoscopic intestinal instrument and brought up to the single port device and delivered through the abdominal incision easily (Fig. 2). The small intestinal loop was exteriorized and an enterotomy was performed. A sterile choledochoscope was passed through the enterotomy to confirm the lesion. An area of denuded epithelium with bleeding was identified in close proximity to the tattooing (Fig. 3). A



**Fig. 2.** Small intestine segment tattooed with methylene blue via CT-guided percutaneous injection.



**Fig. 3.** Small intestine lumen seen intraoperatively with choledochoscope showing the angiodysplasia with slight bleeding.

20-centimeter (cm) segment of this loop of intestine was resected and primarily anastomosed in a standard stapled side-to-side technique. The patient was discharged on post-operative day two.

The patient was reviewed as outpatient at two and six weeks post-operatively. At the first follow-up visit she described a two-day episode of black stools, but had still been taking oral iron. The iron supplementation was discontinued; and on a follow up visit 4 weeks later, there was no further evidence of bleeding and stool color was normal. Outpatient laboratory work demonstrated hemoglobin and hematocrit of 11.5 g/dl and 37%, respectively. At a routine visit with primary care physician at 20 months since the surgery, the patient denied any signs or symptoms of GI bleeding; and had no procedures or any hospitalization since the surgery.

### 4. Discussion

Obscure GI bleeding (OGIB) is defined as bleeding of unknown origin that persists or recurs after an initial negative endoscopic evaluation including colonoscopy and esophagogastroduodenoscopy (EGD). It can be further classified as overt OGIB when there is clinical evidence of visible GI bleeding (e.g. melena or hematochezia) or occult OGIB, when there is no clinical evidence of gross bleeding (e.g., unexplained iron deficiency anemia).<sup>2</sup> Only 5% of GI bleeding occurs between the ligament of Treitz and the ileocecal valve.<sup>3</sup> Approximately 30–40% of OGIB is caused by small intestine angiodysplasia, which is the most common cause in older patients.<sup>4</sup> Angiectasias are ectatic, thin walled, blood vessels with or without endothelial lining. Small arteriovenous communications are often present due to incompetence of the precapillary sphincter. In patients less than 50 years old, the most common sources are tumors such as leiomyomas, carcinoid tumors, lymphomas and adenocarcinoma.<sup>5</sup> Other causes include nonsteroidal anti-inflammatory drug enteropathy,<sup>6,7</sup> inflammatory bowel disease, Meckel's diverticulum,<sup>8,9</sup> Dieulafoy's lesions,<sup>10</sup> radiation enteropathy,<sup>11</sup> hemosuccus pancreaticus,<sup>12</sup> small intestine varices<sup>13–15</sup> and aortoenteric fistula in patients with prior abdominal aortic aneurysm repair.

A thorough history and physical examination is extremely important in the evaluation of a patient with OGIB. There are a number of diagnostics studies available to determine the etiology of OGIB. The diagnostic approach depends upon clinical factors, such as the age of the patient, quality of the prior endoscopic evaluation, and the overt or occult status of the bleeding.<sup>2</sup> The small intestine can be examined using a number of radiologic and endoscopic modalities. Radiologic methods

include barium studies, nuclear studies (tagged red blood cell scans and Meckel's scan), computed tomography and magnetic resonance imaging with enteroclysis; and mesenteric arteriography. Endoscopic methods include esophagoduodenoscopy (EGD), colonoscopy, push enteroscopy, double balloon endoscopy (DBE), and capsule endoscopy.

In 2005, Pennazio et al. proposed an algorithm for the diagnosis and management of obscure GI bleeding.<sup>16</sup> In patients presenting with OGIB, upper endoscopy and colonoscopy should be performed. A second look endoscopy evaluation should also be considered before proceeding with capsule endoscopy, since 20–30% of patients undergoing evaluation for obscure bleeding have lesion present in the upper and lower GI tracts that may be missed on initial endoscopic evaluation.<sup>17,18</sup> Video capsule endoscopy (VCE) should be the next test in the evaluation of patients with GI bleeding, once findings on upper endoscopy and colonoscopy are negative.

Mesenteric angiography is typically reserved to evaluate patients with overt OGIB. Diagnostic yield ranges from 27% to 77% for lower GI bleeding.<sup>19</sup> A randomized controlled trial by Leung et al. demonstrated a superior diagnostic yield of video capsule endoscopy compared with angiography (53.3% vs 20.0%,  $n = 60$ ).<sup>20</sup> Although VCE enables visualization of the entire small intestine it lacks the potential for therapeutic intervention. Recent advances in angiographic techniques such as superselective embolization (SSMA) are becoming increasingly popular.<sup>21</sup> The data on the clinical utility of angiography and embolization in the specific setting of obscure GI bleeding is very limited.

Once a diagnosis is made, the therapeutic options are nonsurgical and surgical. Of these methods, surgery traditionally offers the best chance of cure. However, the small intestine lacks posterior fixation in the abdominal cavity as oppose to some areas of the colon and also vascular lesions are not readily visible externally upon surgical exploration. For this reason, intraoperative techniques for localization of a source of bleeding are vital to successful surgical management. One half of small intestine bleeding lesions can be missed with older methods described such as visual inspection, palpation, transillumination, enterotomy for direct mucosal inspection and blind resections.<sup>22</sup>

The use of methylene blue dye to aid the localization of these obscure sources of GI hemorrhage has been well described in the literature. The goal is to help the surgeon find the specific small intestine culprit in order to perform a selective bowel resection and preserve small intestine length. Folger et al. reported the first case in 1978, in which 10 ml of methylene blue were injected in the superior mesenteric artery by preoperative angiography.<sup>23</sup> Over the years, numerous case reports using similar techniques have described successful preoperative enteric mapping of the small intestine lesion using methylene blue followed by surgical exploration and selective resection.<sup>24–32</sup>

Superselective angiographic catheters have enabled Interventional Radiologists to localize more accurately a lesion or bleeding site by cannulating distal visceral vessels. Jiao et al. described a case series of 4 patients with active OGIB, in which preoperatively superselective angiography aid localization of small intestine bleeding site and subsequently the patients were transported to the operating room and 0.5 ml of methylene blue was injected intraoperative, delineating the segment of bowel to be resected. Their success rate was 100%.<sup>33</sup> These methods have the potential risk of catheter dislodgement or malposition during transfer to the operating room. Lundy et al. described another approach by performing the first combined intraoperative SSMA with methylene blue dye enteric mapping followed by immediate small bowel resection.<sup>34</sup> Larger prospective studies are needed to assess the use of superselective mesenteric angiography for embolization and to assist the intraoperative localization of bleeding site in the setting of OGIB.

In the case presented, an iatrogenic SMA dissection limited options for endovascular management. She was not symptomatic from this injury and a multidisciplinary discussion, including a vascular surgeon and an interventional radiologist, recommended against attempting an SSMA. The use percutaneous CT-guided biopsy of small intestine wall lesions have been described in the literature and are found to be safe and accurate. This is considered an option in selected cases with negative endoscopic biopsy.<sup>35</sup> As a result, the CT-guided percutaneous injection with laparoscopic resection was devised.

To the best of our knowledge, this is the first reported description of this technique. One challenging aspect of the technique was the rapid clearance of contrast. A second issue was the peristalsis of the small intestinal loops. The percutaneous needle was placed in the loop of small intestine that looked very similar in appearance and location to the loop seen on CTA. The primary concern was that to ensure that the small intestine to be resected contained the source of obscure bleeding. Prior to segmental resection of the stained segment, a small enterotomy was made and a choledoscope was used to perform an intraoperative enteroscopy, which demonstrated a small mucosal area with signs of recent bleeding. This area was in close proximity to the tattooing area.

## 5. Conclusion

Localization of OGIB lesions of the small intestine continues to be a challenge. Of those patients requiring surgical management, current imaging modalities are imperative for successful treatment. We describe another viable option that may be implemented in patients where preoperative imaging indicates a vascular abnormality and are not candidates for endovascular procedures. As demonstrated in our case, CT guided percutaneous techniques may potentially be useful for enteric mapping prior to definitive surgical resection.

## Conflict of interest

None declared.

## Funding

None.

## Ethical approval

Written informed consent was obtained from the patient for publication of this case report and accompanying images. A copy of the written consent is available for review by the Editor-in-Chief of this journal on request.

## Author contribution

Case report writing and literature review: Juan Carlos Martinez; Collection of information: Juan Carlos Martinez, John Lukaszczyk; Manuscript submission: Juan Carlos Martinez; Case report editing and review: Jamie Thomas, John Lukaszczyk; Attending interventional radiologist involved in this case: Jamie Thomas; Attending surgeon involved in this case: John Lukaszczyk.

## References

1. Szold A, Katz LB, Lewis BS. Surgical approach to occult gastrointestinal bleeding. *Am J Surg* 1992;163(1):82–90, discussion 92–93.
2. ASGE Standards of Practice Committee. The role of endoscopy in the management of obscure GI bleeding. *Gastrointest Endosc* 2010;72(3):471–9.
3. Katz LB. The role of surgery in occult gastrointestinal bleeding. *Semin Gastrointest Dis* 1999;2(10):78–81.



4. Foutch PG. Angiodysplasia of the gastrointestinal tract. *Am J Gastroenterol* 1993;**88**:807–18.
5. Lewis BS, Kornbluth A, Wayne JD. Small bowel tumours: yield of enteroscopy. *Gut* 1991;**7**(32):63–5.
6. Kwo PY, Tremaine WJ. Nonsteroidal anti-inflammatory drug-induced enteropathy: case discussion and review of the literature. *Mayo Clin Proc* 1995;**1**(70):55–61.
7. Lang J, Price AB, Levi AJ, Burke M, Gumpel JM, Bjarnason I. Diaphragm disease: pathology of disease of the small intestine induced by non-steroidal anti-inflammatory drugs. *J Clin Pathol* 1988;**5**(41):516–26.
8. Bartram CI, Amess JA. The diagnosis of Meckel's diverticulum by small bowel enema in the investigation of obscure intestinal bleeding. *Br J Surg* 1980;**6**(7):417–8.
9. Kiratli P, Aksoy T, Bozkurt MF, Orhan D. Detection of ectopic gastric mucosa using 99mTc pertechnetate: review of the literature. *Ann Nucl Med* 2009;**2**(23):97–105.
10. Blecker D, Bansal M, Zimmerman RL, Fogt F, Lewis J, Stein R, et al. Dieulafoy's lesion of the small bowel causing massive gastrointestinal bleeding: two case reports and literature review. *Am J Gastroenterol* 2001;**3**(96):902–5.
11. Taverner D, Talbot IC, Carr-Locke DL, Wicks AC. Massive bleeding from the ileum: a late complication of pelvic radiotherapy. *Am J Gastroenterol* 1982;**1**(77):29–31.
12. Risti B, Marincek B, Jost R, Decurtins M, Ammann R. Hemosuccus pancreaticus as a source of obscure upper gastrointestinal bleeding: three cases and literature review. *Am J Gastroenterol* 1995;**10**(90):1878–80.
13. Yuki N, Kubo M, Noro Y, Kasahara A, Hayashi N, Fusamoto H, et al. Jejunal varices as a cause of massive gastrointestinal bleeding. *Am J Gastroenterol* 1992;**4**(87):514–7.
14. Traina M, Tarantino I, Barresi L, Mocciaro F. Variceal bleeding from ileum identified and treated by single balloon enteroscopy. *World J Gastroenterol* 2009;**5**(15):1904–5.
15. Kodama M, Uto H, Numata M, Hori T, Murayama T, Sasaki F, et al. Endoscopic characterization of the small bowel in patients with portal hypertension evaluated by double balloon enteroscopy. *J Gastroenterol* 2008;**8**(43):589–96.
16. Pennazio M, Eisen G, Goldfarb N. ICCE consensus for obscure gastrointestinal bleeding. *Endoscopy* 2005;**10**(37):1046–50.
17. Fry LC, Belluci M, Neumann H, Marfertheiner P, Mönkemüller K. Incidence of bleeding lesions within reach of conventional upper and lower endoscopes in patients undergoing double balloon enteroscopy for obscure GI bleeding. *Aliment Pharmacol Ther* 2009;**29**:342–9.
18. Robinson CA, Jackson C, Condon D, Gerson LB. Impact of inpatient status and gender on small-bowel capsule endoscopy findings. *Gastrointest Endosc* 2011;**74**:1061–6.
19. Zuckerman GR, Prakash C. Acute lower intestinal bleeding: Part I: Clinical presentation and diagnosis. *Gastrointest Endosc* 1998;**48**:606–17.
20. Leung WK, Ho SS, Suen BY, Lai LH, Yu S, Ng EK, et al. Capsule endoscopy or angiography in patients with acute overt gastrointestinal bleeding: a prospective randomized study with long term follow up. *Am J Gastroenterol* 2012;**107**:1370–6.
21. d'Othee BJ, Surapaneni P, Rabkin D, Nasser I, Clouse M. Microcoil embolization for acute lower gastrointestinal bleeding. *Cardiovasc Intervent Radiol* 2006;**29**(1):49–58.
22. Lewis BS, Wayne J. Chronic gastrointestinal bleeding of obscure origin: role of small bowel enteroscopy. *Gastroenterology* 1988;**94**:1117–20.
23. Folger R, Golembe E. Methylene blue injection. An intraoperative guide in small bowel resection for arteriovenous malformation. *Arch Surg* 1978;**113**:194–5.
24. Rubio PA, Farrell EM. A new technique for indentifying bleeding diverticula of the small bowel utilizing methylene blue infusion. *Surgery* 1980;**86**:764.
25. Athanasoulis CA, Moncure AC, Greenfield AJ, Ryan JA, Dodson TF. Intraoperative localization of small bowel bleeding sites with combined use of angiographic methods and methylene blue injection. *Surgery* 1980;**87**:77–84.
26. McDonald ML, Farnell MB, Stanson AW, Ress AM. Preoperative highly selective catheter localization of occult small-intestinal hemorrhage with methylene blue. *Arch Surg* 1995;**130**:106–8.
27. Schrodt JF, Bradford WR. Presurgical angiographic localization of small bowel bleeding site using methylene blue injection. *J Ky Med Assoc* 1996;**94**:192–5.
28. Mazziotti MV, Muldowney S, Darcy M, Hackett BP, Skinner MA. Intraoperative localization of small intestinal bleeding in an infant by methylene blue injection: a case report. *J Pediatr Surg* 1998;**33**:754–5.
29. Schechter S, Deorchis D, Bass J, Marcoux DA. Angiographic selective methylene blue staining of small-bowel arteriovenous malformation. *Ann Surg* 2002;**68**:15–7.
30. Remzi FH, Dietz DW, Unal E, Levitin A, Sands MJ, Fazio VW. Combined use of preoperative provocative angiography and highly selective methylene blue injection to localize an occult small-bowel bleeding site in a patient with Crohn's disease. Report of a case. *Dis Colon Rectum* 2003;**46**:260–3.
31. Pasupathy S, Lau TN, Chia KH. Methylene blue injection to localize the site of small intestinal hemorrhage. *ANZ J Surg* 2004;**74**:1133–4.
32. Stauffer JA, Shaddix KK, Achem SR, Stark M, Adelson A, Metzger PP, et al. Intra-operative use of super-selective or highly selective angiography with methylene blue injection to localize arterial-venous malformation. *Colorectal Dis* 2011;**13**:e65–6.
33. Pai M, Frampton AE, Virk JS, Nehru N, Kyriakides C, Limongelli P, et al. Preoperative superselective mesenteric angiography and methylene blue injection for localization of obscure gastrointestinal bleeding. *JAMA Surg* 2013;**148**:665–8.
34. Gifford SM, Peck MA, Reyes AM, Lundy JB. Methylene blue enteric mapping for intraoperative localization in obscure small bowel hemorrhage: report of a new technique and literature review. *J Gastrointest Surg* 2012;**16**:2177–81.
35. Felds S, Libson E. CT-guided aspiration core needle biopsy of gastrointestinal wall lesions. *J Comput Assist Tomogr* 2000;**24**(2):224–8.

#### Open Access

This article is published Open Access at [sciedirect.com](http://sciedirect.com). It is distributed under the [IJSCR Supplemental terms and conditions](#), which permits unrestricted non commercial use, distribution, and reproduction in any medium, provided the original authors and source are credited.