

# Bilateral paranasal sinus fungal balls

## A retrospective cohort study in 28 patients over a 21-year period

Jong Seung Kim, MD<sup>a,b</sup>, Sam Hyun Kwon, MD, PhD<sup>a,b</sup>, Jung Soo Kim, MD, PhD<sup>c</sup>, Sung Jae Heo, MD<sup>c,\*</sup>

### Abstract

Paranasal fungal balls are rare entities for which a recent increase in reported cases has been observed. Fungal balls are most commonly unilateral, and there are few bilateral cases in the literature. Here we report the clinical features of bilateral fungal balls in 24 patients treated in our institution over the past 20 years.

In this retrospective study, we reviewed the medical records of 5279 patients who underwent endoscopic sinus surgery performed by a single surgeon from January 1996 to December 2016 at a tertiary care center in order to identify patients diagnosed with fungal balls confirmed histopathologically. Demographic data and radiologic findings of patients with bilateral fungal balls were compared with those who had unilateral fungal balls. Multiple logistic regression test was used to compare demographic information between patients with unilateral and bilateral fungal balls.

The most commonly involved sinus in bilateral cases was maxillary (87.5%), followed by ethmoid (37.5%) and sphenoid (33.3%). Of the 24 patients, 19 were female, and patient age ranged from 45 to 83 years, with an average of 65.1 years. Common existing comorbidities were hypertension (45.8%), diabetes (29.2%), cardiac problem (16.7%), cerebral infarction (8.3%), pulmonary tuberculosis (8.3%), and lung cancer (4.2%).

The clinically relevant features of patients diagnosed with bilateral fungal balls from our review include advanced age and immunocompromised status compared to those with unilateral fungal balls. These features contribute to the clinical distinction of bilateral fungal ball disease from unilateral fungal balls and invasive fungal sinusitis.

**Abbreviation:** CT = computed tomography.

**Keywords:** epidemiology, mycoses, sinusitis

### 1. Introduction

Paranasal fungal balls are the most common type of noninvasive fungal rhinosinusitis.<sup>[1]</sup> The most common causative organisms, *Aspergillus* can be inhaled through the respiratory tract, leading to colonization of the lung and paranasal sinus as part of our normal flora. Fungal balls from this organism usually occur unilaterally and can be differentiated from a malignant tumor on noncontrast computed tomography (CT) imaging by characteristic calcification findings.<sup>[2,3]</sup>

Although *Aspergillus* fungal balls are typically solitary and affect a single sinus, there have been case reports of bilateral involvement or multiple distinct fungal balls.<sup>[4]</sup> Patients with paranasal fungal ball are usually immunocompetent despite not fully meeting diagnostic criteria.<sup>[2]</sup> Further investigation of bilateral fungal balls is warranted to help characterize this disease.

In this study, we report 28 cases of bilateral fungal balls through our 21-year experience. We compare patient demographics,

medical history, and radiographic findings in cases of bilateral fungus balls versus those of unilateral fungus balls.

### 2. Patients and Methods

#### 2.1. Ethical considerations

The study was reviewed and approved by the institutional ethical review board of Chonbuk National University Hospital, Korea (Institutional review Board no. CUH 2021-09-048), and conducted in compliance with the Declaration of Helsinki.

#### 2.2. Subjects

All patients treated for bilateral fungal balls in the Department of Otorhinolaryngology, Chonbuk National University Hospital, between 1996 and 2016 were enrolled in this study. After Institutional review Board approval, retrospective chart

*This study was supported by the fund of the Biomedical Research Institute, Jeonbuk National University Hospital. This work was supported by the NRF grant funded by the Korean Government (MSIT) (No. 2021R1G1A1094681) and by project for Industry Academic Cooperation Based Platform R&D funded by the Korea Ministry of Small and Medium Enterprises (SMEs) and Startups in 2021 (No. S3017921).*

*The authors have no conflicts of interest to disclose.*

*The datasets generated during and/or analyzed during the current study are not publicly available, but are available from the corresponding author on reasonable request.*

<sup>a</sup> Department of Otorhinolaryngology-Head and Neck Surgery, College of Medicine, Chonbuk National University, Jeonju, Republic of Korea, <sup>b</sup> Research Institute of Clinical Medicine of Chonbuk National University, Biomedical Research Institute of Chonbuk National University Hospital, Jeonju, Republic of Korea, <sup>c</sup> Department of Otorhinolaryngology-Head and Neck Surgery, School of Medicine, Kyungpook National University, Daegu, Republic of Korea.

*\*Correspondence: Sung Jae Heo, Department of Otorhinolaryngology-Head and Neck Surgery, Kyungpook National University Chilgok Hospital, 807, Hoguk-ro, Buk-gu, Daegu 41404, Korea (e-mail: blueskyhsj@hanmail.net).*

*Copyright © 2022 the Author(s). Published by Wolters Kluwer Health, Inc. This is an open-access article distributed under the terms of the Creative Commons Attribution-Non Commercial License 4.0 (CCBY-NC), where it is permissible to download, share, remix, transform, and buildup the work provided it is properly cited. The work cannot be used commercially without permission from the journal.*

*How to cite this article: Kim JS, Kwon SH, Kim JS, Heo SJ. Bilateral paranasal sinus fungal balls: A retrospective cohort study in 28 patients over a 21-year period. Medicine 2022;101:33(e30174).*

*Received: 15 March 2022 / Received in final form: 6 July 2022 / Accepted: 7 July 2022*

*<http://dx.doi.org/10.1097/MD.00000000000030174>*

analysis was performed to obtain patient age, sex, clinical symptoms, laboratory data, and radiographic findings on CT scan. Abnormalities on CT imaging were then compared with specimens obtained following surgical intervention, as described below.

### 2.3. Surgical technique

All patients were treated by functional endoscopic sinus surgery under general or local anesthesia. An external approach was not performed. After finding the dark greenish grumous material in the sinuses, we suspected fungal ball intraoperatively, which was sent for fungal culture, permanent staining. We removed the remaining debris with suction, large curette, and saline irrigation. To avoid saline aspiration and the dissemination of debris in the airway, the nasopharyngeal opening was obstructed with saline-soaked gauze. After surgery, we documented the affected sinus, demographic data, medical history, and CT findings.

### 2.4. Histologic criteria

The diagnosis of fungal ball was confirmed microscopically. Although hematoxylin–eosin staining was sufficient to detect fungal hyphae, either periodic acid-schiff or Gomory silver stain was also used to increase the sensitivity to detect fungi.

### 2.5. Statistical analysis

Multivariate analysis was performed on age, sex, and past history to determine the causative factors affecting bilateral fungal ball. A chi square test were used to compare the involved sinus between patients with unilateral and bilateral fungal balls. SPSS software (version 20.0) for Windows was used for all descriptive analyses. *P* values of <0.05 were considered statistically significant.

## 3. Results

### 3.1. Incidence

In a total of 5279 patients who underwent endoscopic surgery between 1996 and 2016 at our center, the incidence of unilateral fungal ball was 6.9% (363/5279) and the incidence of bilateral fungal balls was 0.53% (28/5279; Table 1).

### 3.2. Demographics

The average patient age in bilateral cases was  $65.1 \pm 15.6$  years and was higher than the average age in unilateral cases, which was  $57.8 \pm 12.8$  years, however, statistically insignificant (Table 1; *P* = .742, independent *t* test). Although female predominance was noted in both groups (3:1 in bilateral cases, 1.7:1 in unilateral cases), the difference between the 2 groups was not statistically significant (*P* = .969, multiple logistic regression test; Table 1)

### 3.3. Underlying diseases

The proportion of patients with existing comorbidities was significantly higher in bilateral cases (25/28) than in unilateral cases (207/363, *P* = .001, chi square test). Hypertension was the most common and significant comorbidity in bilateral fungal balls (18/28), compared to unilateral cases (*P* = .002, multiple logistic regression test). Patients who received chemotherapy for solid tumors were significantly higher in the bilateral group. (*P* = .037, multiple logistic regression test; Table 1). History of cardiac problem and diabetes mellitus

were also more prevalent in bilateral cases than in unilateral cases, however, statistically insignificant. The history of cerebral infarction, pulmonary tuberculosis, liver cirrhosis, kidney transplantation, and nasal trauma had no correlation with unilateral or bilateral cases.

### 3.4. Radiologic finding

Of the 28 bilateral cases, 26 patients underwent CT imaging (Figs. 1 and 2). Marked calcification was seen in 21 patients (Fig. 1A). Of the remaining 5 patients, 4 had uneven, pop-out boundaries in the involved sinus, which we found to be radiologically predictive (Fig. 2). The maxillary sinus was the most commonly involved sinus (bilateral: 89.3%, unilateral: 84.3%), followed by the sphenoid sinus (bilateral: 21.4%, unilateral: 10.7%) and ethmoid sinus (bilateral: 14.3%, unilateral: 10.2%; Table 1). We found a significant difference in the involved sinus between the 2 groups (*P* = .001, chi square test). We performed magnetic resonance imaging in 6 patients, and all cases demonstrated a signal void within the involved sinuses in T2-weighted imaging (Fig. 1B).

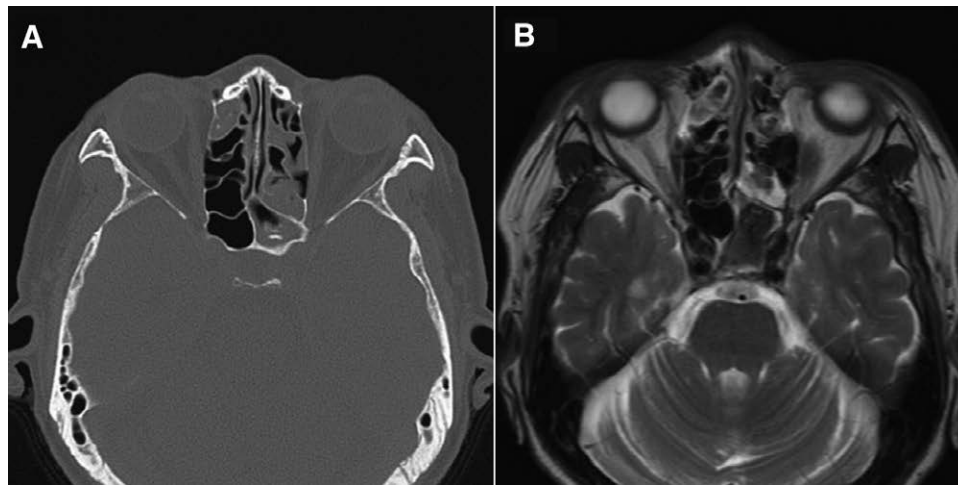
## 4. Discussion

A unilateral sinus lesion evokes the differential diagnosis of malignancy, fungal ball, nasal polyp, and inverted papilloma.<sup>[5]</sup> In some cases, sinus debris can be biopsied during preoperative endoscopy.<sup>[6]</sup> However, most cases of fungal ball are usually not detected by preoperative endoscopy.<sup>[2,7]</sup> Likewise, this can be applied in bilateral fungal balls, which has no expected clue preoperatively. We found the bilateral fungal balls by nasal endoscopy intraoperatively (Fig. 3). The first clue of paranasal bilateral fungal balls is the detection of brownish or greenish aggregate in the affected sinus, which has variable friability. Our

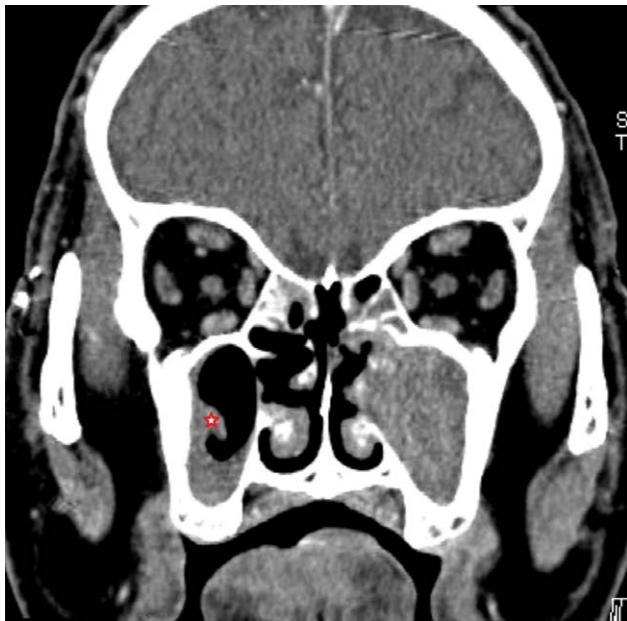
**Table 1**  
Comparison of demography between bilateral and unilateral fungal balls.

				<i>P</i> value
1. Age distribution of fungal ball patients				
Bilateral fungal balls		Unilateral fungal ball		
	65.1 ± 12.7 yr		57.8 ± 11.8 yr	.727
2. Sex distribution of fungal ball patients				
Bilateral fungal balls		Unilateral fungal ball		
	Male:female = 7:21		Male:female = 137:226	.969
3. Underlying disease				
Bilateral fungal balls (25/28)		Unilateral fungal ball (207/363)		
Hypertension	18	Hypertension	91	.002
Diabetes mellitus	8	Diabetes mellitus	42	.229
Solid cancer	4	Solid cancer	26	.037
Cerebral infarction	0	Cerebral infarction	14	.999
Cardiac problem	4	Cardiac problem	17	.144
Pulmonary tuberculosis	2	Pulmonary tuberculosis	11	.279
Liver cirrhosis	0	Liver cirrhosis	1	.999
Kidney transplantation	0	Kidney transplantation	2	.999
Nasal trauma	0	Nasal trauma	20	.998
4. Involved sinuses				
Bilateral fungal balls (n = 28)		Unilateral fungal ball (n = 363)		.001
Maxillary sinus	35	Maxillary sinus	306	
Sphenoid sinus	11	Sphenoid sinus	30	
Ethmoid sinus	10	Ethmoid sinus	27	
Maxillary–maxillary*	15			
Maxillary–ethmoid*	4			
Maxillary–sphenoid*	6			
Sphenoid–sphenoid*	3			

\*Bilateral sinuses.



**Figure 1.** (A) The calcification of the right ethmoid sinus and left sphenoid sinus was shown in CT image. (B) Signal voids in T2-weighted imaging were shown in the same sinuses. CT = computed tomography.



**Figure 2.** Uneven, pop-out boundaries within the right maxillary sinus (red star) exhibits retrogressive movement due to gravity, which is another diagnostic clue for fungal balls.

purpose is to get more preoperative information throughout our 21-year experience.

CT is the most common diagnostic tool to detect the presence of fungal balls.<sup>[3,8]</sup> The radiologic characteristics of paranasal fungal ball on CT are calcifications or a hyperattenuating area in the center of the sinus with enhanced inflamed mucosa.<sup>[1,3]</sup> In this study, the calcification of the involved sinus in bilateral fungal balls was detected in 21 of 26 (80.8%) patients (Fig. 1A). Of the remaining 5 cases, we were able to make an informal diagnosis by correlating uneven pop-out boundaries within the sinus (Fig. 2). These features likely reflect the slow saprophytic growth of the fungal aggregate. In this study, magnetic resonance imaging was performed in 6 bilateral cases. All cases showed a signal void in T2-weighted imaging (Fig. 1B).<sup>[3]</sup> This might be another important radiologic characteristic of fungal balls.

The maxillary sinus was the most commonly involved sinus in both in the bilateral and unilateral cases. However, sphenoid and ethmoid involvement was significantly more common in the bilateral group than in the unilateral group ( $P = .001$ ).

To find the causative factor of the past history, we performed the multivariate logistic regression test. Medical history data from our study reveals that hypertension and chemotherapy for solid cancer are more prevalent in patients with bilateral fungal disease than in those with unilateral disease. Of these, history of chemotherapy for solid cancer is associated with immunocompromised status. Not as many as the invasive fungal sinusitis, the presence of immunocompromise in the bilateral fungal balls is so meaningful that careful history taking may be a diagnostic clue for bilateral fungal balls.<sup>[9]</sup>

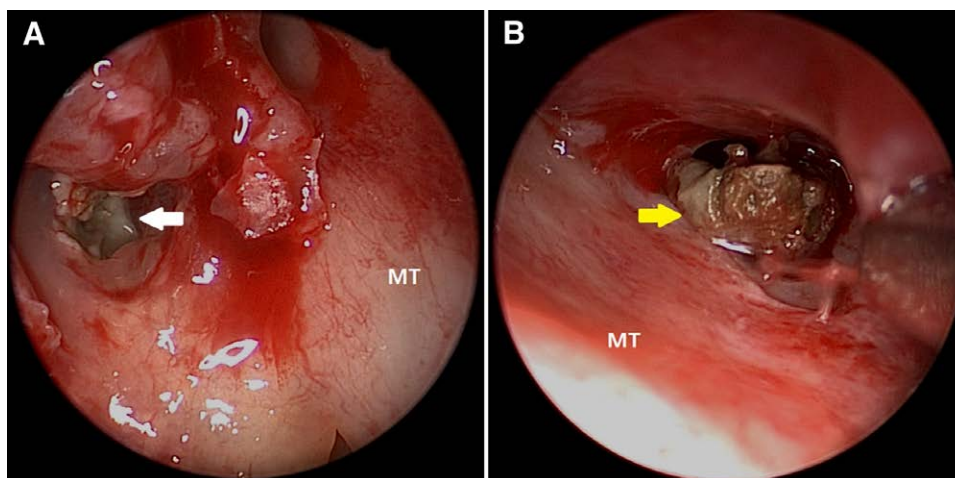
Hypertension was the single most commonly observed comorbidity in the bilateral fungal ball disease. Although the mechanism by which hypertension causes fungal ball has not been elucidated yet, we have previously discussed the epidemiological relationship between fungal ball and hypertension.<sup>[11]</sup> Peripheral resistance of the vessels in hypertension can affect paranasal sinuses, which results in hypoperfusion and decreased drainage of multiple sinus mucosa. Therefore, careful history taking is important for anticipating bilateral fungal balls.

The female predominance (2:1) seen in our study was similar to that in previous studies. However, the sex difference between bilateral and unilateral groups was not significant.

A limitation of this study is the retrospective methodology. However, the rareness of bilateral fungal balls makes prospective cohort studies difficult. Despite this weakness, this is the first clinical characterization of bilateral fungal balls in a single patient population.

## 5. Conclusion

The rareness of bilateral fungal balls complicates the diagnosis of this disease. Here we present several radiological, demographic, and comorbid characteristics of bilateral fungal balls that will contribute to our clinical knowledge of this disease. The clinically relevant features of patients with bilateral fungal balls in this study include advanced age and immunocompromised status compared to those with unilateral fungal balls. These features contribute to the clinical distinction of bilateral fungal ball disease from unilateral fungal balls and invasive fungal sinusitis. Future large-scale studies will hopefully corroborate and strengthen our conclusions.



**Figure 3.** Representative endoscopic image of bilateral fungal balls in the ethmoid sinus. (A) Whitish fungal debris was noted in the right ethmoid sinus (white arrow). (B) Dark brownish fungal ball was noted in the left ethmoid sinus (yellow arrow). MT = middle turbinate.

### Author contributions

Jong Seung Kim- Conceptualization, Funding acquisition, Data curation, Investigation, Formal analysis, Writing – original draft.  
 Sam Hyun Kwon- Data curation, Methodology, Formal analysis.  
 Jung Soo Kim- Data curation, Methodology, Formal analysis.  
 Sung Jae Heo- Project administration, Conceptualization, Formal analysis, Supervision, Writing – review & editing.

### References

- [1] Kim JS, So SS, Kwon SH. The increasing incidence of paranasal sinus fungus ball: a retrospective cohort study in two hundred forty-five patients for fifteen years. *Clin Otolaryngol*. 2017;42:175–9.
- [2] Grosjean P, Weber R. Fungus balls of the paranasal sinuses: a review. *Eur Arch Otorhinolaryngol*. 2007;264:461–70.
- [3] Seo YJ, Kim J, Kim K, et al. Radiologic characteristics of sinonasal fungus ball: an analysis of 119 cases. *Acta radiologica*. 2011;52:790–5.
- [4] Mitsimponas KT, Walsh S, Collyer J. Bilateral maxillary sinus fungus ball: report of a case. *Br J Oral Maxillofac Surg*. 2009;47:242.
- [5] Nair S, James E, Awasthi S, et al. A review of the clinicopathological and radiological features of unilateral nasal mass. *Indian J. Otolaryngol Head Neck Surg*. 2013;65:199–204.
- [6] Lee JH, Jeong HM. Fungal sinusitis with a nasal septal perforation. *Ear Nose Throat J*. 2013;92:E24–5.
- [7] Klossek JM, Serrano E, Peloquin L, et al. Functional endoscopic sinus surgery and 109 mycetomas of paranasal sinuses. *Laryngoscope*. 1997;107:112–7.
- [8] Adil A, el Amraoui F, Kadiri R. Role of computed tomography in pulmonary aspergillosis. 20 cases. *Presse Med*. 2001;30:621–5.
- [9] Klingspor L, Saadi B, Ljungman P, et al. Epidemiology and outcomes of patients with invasive mould infections: a retrospective observational study from a single centre (2005-2009). *Mycoses*. 2015;58:470–7.