

Contents lists available at [ScienceDirect](https://www.sciencedirect.com)

Respiratory Medicine Case Reports

journal homepage: <http://www.elsevier.com/locate/rmcr>

Case report

Extracorporeal carbon dioxide removal in heart-beating donor with acute severe asthma: A case report

Silvia De Rosa ^{a,b,*}, Gianlorenzo Golino ^{a,b,c}, Claudio Ronco ^{a,d,e}^a International Renal Research Institute of Vicenza, Vicenza, Italy^b Department of Anesthesiology and Intensive Care, San Bortolo Hospital, Vicenza, Italy^c Department of Medicine – DIMED, Section of Anesthesiology and Intensive Care Medicine, University of Padova, Padova, Italy^d Department of Nephrology, Dialysis and Transplantation and International Renal Research Institute of Vicenza, San Bortolo Hospital, Vicenza, Italy^e Department of Medicine, University of Padova, Padova, Italy

ARTICLE INFO

Keywords:

Acute hypercapnic respiratory failure
 Extracorporeal carbon dioxide removal
 Hypercapnia
 Near-fatal asthma
 Respiratory dialysis
 Status asthmaticus

ABSTRACT

Status asthmaticus is a life-threatening disorder that can manifest in dangerous levels of hypercapnia and acidosis. The use of extracorporeal carbon dioxide removal (ECCO₂R) has been used successfully to control pH and PaCO₂ in patients with acute severe asthma. The present report describes the use of this technology in near-fatal asthma with brain death, and awaiting organ harvest.

The ProLUNG® system consists of a veno-venous hemoperfusion circuit with an artificial lung poly-methylpentene membrane coated with phosphorylcholine with a surface of 1.81 m². The system can reach a blood flow of 450 ml/min through a double-lumen central venous catheter (13.0 Fr) placed in femoral, subclavian or jugular vein. The platform is provided with automated management of airflow and VCO₂ monitoring during treatment.

The patient was maintained on extracorporeal treatment ensuring stable arterial pH control and PaCO₂ control.

In acute status asthmaticus, complicated with cardiac arrest, mini-invasive ECCO₂R was an effective method of controlling pH and PaCO₂, for optimizing hemodynamic and aerobic metabolism and for performing protective ventilation for an optimal organ donor preservation until the organ harvest occurs.

1. Introduction

Status asthmaticus is a life-threatening disorder that can manifest in dangerous levels of hypercapnia and acidosis, with a significant mortality and morbidity [1]. Peripheral tissue perfusion and oxygenation depend on various factors, including inspired oxygen concentration, arterial oxygen tension [2], hemoglobin concentration [3], cardiac output [4], local perfusion [5] and the autonomous response to stress in pain [6]. Different concentrations of carbon dioxide can alter some of these parameters. Mechanical ventilation (MV) can cause increased air trapping and hyperinflation, predisposing the lungs to barotraumas [7, 8]. Although with well-defined indications, extracorporeal membrane oxygenation (ECMO) is generally recommended in the setting of potentially reversible cardiopulmonary failure poorly responsive to maximal conventional medical [8]. Since hypercarbia rather than

hypoxemia is the primary abnormality in asthmaticus status, the use of extracorporeal carbon dioxide removal (ECCO₂R) must also be given consideration. ECCO₂R is a partial respiratory support technique that, based on the use of an extracorporeal circuit with a gas-exchanging membrane, achieves a relevant CO₂ clearance directly from the blood, at a blood flow in the range of 0.4–1 L/min [9–11]. Interestingly, the concept of mini-invasive ECCO₂R, where a proper design of the artificial lung can ensure a clinically relevant CO₂ removal amount at a blood flow around 400 ml/min using a double lumen venous-venous vascular access between 12 and 14 Fr, like the ones commonly used for continuous renal replacement therapies.

Nowadays, ECCO₂R systems are proposed as respiratory support for recovery, or to facilitate protective ventilation [9]. The present case report describes the use of mini-invasive ECCO₂R in a near-fatal asthma patient with brain death awaiting organ harvest.

* Corresponding author. Department of Anesthesiology and Intensive Care Medicine, AULSS 8 Berica, San Bortolo Hospital, Viale Rodolfi 37, 36100, Vicenza, Veneto, Italy.

E-mail address: derosa.silvia@gmail.com (S. De Rosa).

<https://doi.org/10.1016/j.rmcr.2020.101010>

Received 5 December 2019; Received in revised form 25 January 2020; Accepted 25 January 2020

Available online 28 January 2020

2213-0071/© 2020 Published by Elsevier Ltd. This is an open access article under the CC BY-NC-ND license (<http://creativecommons.org/licenses/by-nc-nd/4.0/>).

2. Case report

A 51 year-old male was admitted to the hospital after collapse and respiratory arrest. He had a medical history of bronchial asthma for 3 years duration and was currently taking inhaled corticosteroids with a long acting beta-2 agonist (budesonide/formoterol) and short acting beta-2 agonist (Salbutamol), as needed. His past medical history was significant for allergic reactions to levofloxacin and ceftriaxone. His parents reported that, during the last 10 days, he had more frequent dyspnea episodes, and a poor medication adherence. During the course of his work in the tannery, he fell unconscious as a result of cardiac arrest. The cardiac arrest was witnessed firstly by volunteers, then by an advanced cardiac life support team that immediately started advanced cardiopulmonary resuscitation (first return of spontaneous circulation achieved in 40'). After successful resuscitation with standard cardiopulmonary resuscitation with chest compressions and epinephrine, he was transferred to the Shock Room. On admission, SaO₂ 96%, heart rate 105 b.p.m., blood pressure 60/40 mmHg, normal heart sounds with no additional murmurs, and his chest was positive on auscultation for end-expiratory wheezing. There was no elevation of cardiac enzymes. His electrocardiography was unremarkable. Echocardiography was performed, which also showed no abnormalities. In the absence of any cardiac abnormalities, his case was managed as exacerbation of bronchial asthma. At admission, the patient was unresponsive with a Glasgow Coma Scale of 3 (E1VtM1) weakly preserved brainstem reflexes. Initial arterial blood gas showed pH 6.76, PaCO₂ 132.4 mmHg, PaO₂ 89.4 mmHg, Bicarbonate 18.5 mmol/L, Base Excess -18.3.

He failed to respond to nebulized salbutamol and therapeutic doses of intravenous aminophylline, magnesium sulfate, and steroids. MV was attempted in accordance with general principles of ventilation for severe acute asthma: sedation and analgesia, neuromuscular blocking drugs, low respiratory rate, prolonged expiratory time, and low extrinsic positive end-expiratory pressure. Intrinsic positive end-expiratory pressure (PEEPi) was 14 cmH₂O. Fig. 1 shows the pressure-time waveform on the volume preset ventilation mode. However, the patient remained hypercapnic and acidotic. We started a target controlled inhalative sedation with Sevoflurane through Mirus™ system (Pall Medical, Dreieich, Germany) with etSEVO of 2%. After 2 hrs of ventilation and Sevoflurane, PaCO₂ had reached 71.7 mm Hg with pH of 7.08.

Because of the failure of this trial of MV to control the PaCO₂ and arterial pH, it was decided to reduce PaCO₂ with the ProLUNG® (Estor SpA, Pero, Italy). The ProLUNG® system consists of a veno-venous hemoperfusion circuit with a gas exchanger device (surface of 1.81 m² of polymethylpentene membrane coated with phosphorylcholine). Anticoagulation was performed with continuous administration of low dosage of Heparin (7.5 IU/kg/h). The veno-venous CO₂ removal (VVCO₂R) relies on a peristaltic pump to drive blood flow through the system.

Under ultrasound guidance, a 13.0 Fr double lumen catheter was inserted into the right femoral vein using the Seldinger technique. The system was primed with saline and Heparin and attached to the vascular catheter. Blood was then gently released into the ProLUNG circuit, with an initial flow of 400 mL/min through the catheter. The patient was maintained on this system with adequate control of the PaCO₂ and arterial pH. After two hours, this produced a corresponding fall in PaCO₂ to 42.7 mm Hg and pH 7.24. Fig. 2 shows changes in pH, PaCO₂, vasoactive inotropic score and lactate before and after ProLUNG. Unresponsive mydriasis was also noted (Right Eye 4.7 mm with 1% of reactivity to the light stimulus, Left Eye 5.2 mm with 0% of reactivity to the light stimulus). A first electroencephalogram (EEG) showed no status epilepticus and slow activity. Twenty-four hours later, brainstem reflexes disappeared. Second EEG was flat. VVCO₂R was stopped after 30 hours to determine the absence of brain-stem reflexes (included hypercapnia testing). The patient was pronounced brain dead, and the family agreed to organ donation. Both kidneys, the liver and pancreas were recovered and subsequently transplanted into 4 recipients.

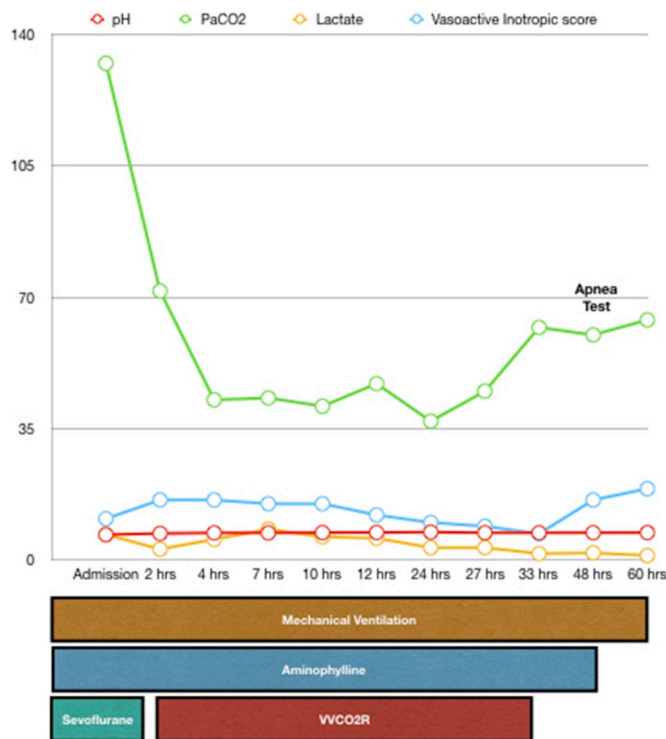


Fig. 1. The pressure-time waveform on the volume preset ventilation mode. Changes in the pressure-time waveform secondary to the presence of bronchospasm with associated gas trapping or similar degree of increase in both PIP and Pplat.

PIP indicates peak inspiratory pressure; Pplat, plateau pressure, PEEP, positive end-expiratory pressure.

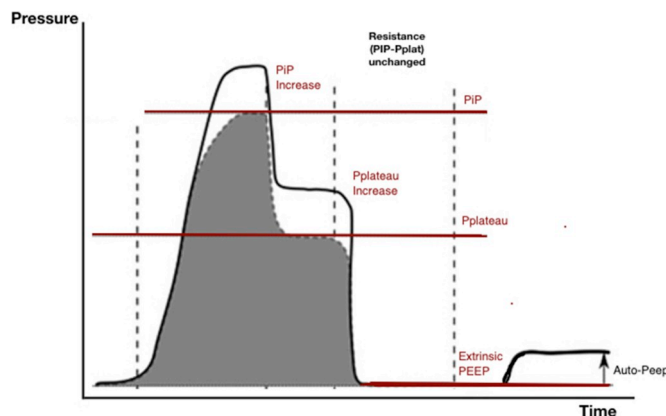


Fig. 2. Arterial pH, paCO₂, Vasoactive Inotropic Score and Lactate before and after VVCO₂R.

3. Discussion

A substantial percentage of 4% of acute asthma exacerbation requires admission to intensive care and one third of these patients require endotracheal intubation and MV [12,13]. Risk factors for NFA requiring MV include a younger age at presentation, poor compliance with prescribed therapy, poor outpatient follow-up, more than three emergency department visits in the preceding year, recent hospital admission, a prior episode of NFA and prior MV [14]. In the present case report, the patient had poor compliance with prescribed therapy and poor follow-up. The significant heart-lung interaction present in patients with asthma causes hemodynamic instability. An increase in intrathoracic

pressure secondary to gas trapping (dynamic hyperinflation) can lead to an acute increase in pulmonary vascular resistance and right heart pressure, with impaired venous return, right ventricular preload of the right ventricular afterload and then left ventricular diastolic volume and cardiac output [15]. In our patient, when we selected the mode of ventilation, we considered the degree of underlying airway resistance and the presence of gas trapping, alveolar hyperinflation and permissive hypercapnia. On ventilator waveform, the airflow resistance was indicated by elevated peak inspiratory pressure together with an increase in peak inspiratory pressure to plateau pressure gradient. Plateau pressure (P_{plat}) was high. Although plateau pressure is a reflection of lung compliance or alveolar pressure and pathophysiology of asthma does not directly involve the alveoli, an increase in P_{plat} would suggest the presence of either worsening bronchospasm with associated gas trapping or an expanding pneumothorax [16–18]. Gas trapping, also described as PEEPi, auto-PEEP, dynamic hyperinflation, or expiratory airflow obstruction, should be quantified by measuring the total volume of exhaled gas during a 20- to 40-s period of apnea (end-inspiratory lung volume) [19]. We determined the presence of PEEPi by real time analysis of ventilator waveform graphics. We observed increase in pressure above the set PEEP after initiating an end-expiratory hold maneuver with the patient paralyzed. The difference between this and the set PEEP was the PEEPi, that in our case was 14 cmH₂O. In presence of a further worsening of hypercapnia, despite the MV, nebulized salbutamol, therapeutic doses of intravenous aminophylline, magnesium sulfate, and steroids, the use of modified extracorporeal membrane oxygenation (ECMO) techniques such as extracorporeal carbon dioxide removal (ECCO₂R) was taken in consideration. In literature, ECMO is generally recommended in the setting of potentially reversible cardiopulmonary failure that is poorly responsive to maximal conventional medical treatment. However, although literature is confined to a few case reports [20,21], a recent review of the multicenter International Extracorporeal Life Support Organization registry by Mikkelsen and colleagues [22] documented that status asthmaticus was the primary indication for ECMO in 24 of 1257 adult patients included in the registry. A total of 20 (83.3%) patients with asthma survived to hospital discharge, whereas only 50.8% of patients with other causes of respiratory failure (odds ratio 4.86) survived therapy. Extracorporeal carbon dioxide removal, when compared to ECMO, is less invasive, requires a single venous catheter and a lower blood flow rate. MacDonnell et al. reported the first use of ECCO₂R as an adjunct to IMV for refractory asthma [23]. Subsequently, Brenner et al. reported two patients with refractory status asthmaticus managed with ECCO₂R, emphasizing the challenges in managing patients with distinct asthma exacerbation phenotypes, the use of modern extracorporeal technology and a new perspective of the role of ECCO₂R for status asthmaticus [24]. Sakai et al. [25], Elliot et al. [26], Jung et al. [27] reported cases of successful treatment with ECCO₂R for status asthmaticus. Despite our interventions aimed at improving the patient's ventilation, unfortunately our patient suffered a brain death, so our objective shifted towards preserving the organs of the potential donor, limiting the harmful effects of hypercapnia. Brain death diagnosis and donor care are becoming important for patients awaiting organ transplants due to organ failure. However, in patients with brain death with cardiorespiratory insufficiency, such as acute myocardial infarction and acute respiratory distress syndrome, it is difficult to protect donor organs not only from ischemic damage but also from damage related to high CO₂ levels. Particularly, hypercarbia leads to cerebral ischemia, brain edema, and increased ICP mutually resulting in a vicious cycle. The vasodilatation effect of increased PaCO₂ also affects systemic vasculature, thus causing hypotension. Several studies have shown that the most frequent complication of apnea testing, as high as 39%, is hypotension [26,27], as a result of peripheral vasodilatation, acidosis, and the cardio-depressant effects of CO₂. The harmful apnea test consists in the disconnection of the patient from the ventilator to let the PaCO₂ rise at least 20 mmHg above the baseline, while oxygenation is preserved via a catheter down the endotracheal tube

delivering 100% O₂ [28]. This apnea test is harmful because the hypercarbia that results can bring the cerebral blood flow below the critical level of 10–15 ml/100 g/min, below which the irreversible damage of the brain tissue occurs [29]. Extracorporeal carbon dioxide removal could be an useful therapeutic tool. In our case brain death occurred, and we continued with ECCO₂R for its organ-preserving role. The treatment was discontinued for procedure for Clinical Assessment of Brain Death and in order to perform apnea test.

4. Conclusion

In status asthmaticus complicated with cardiac arrest, veno-venous extracorporeal carbon dioxide removal was an effective method of controlling pH and PaCO₂, to optimize hemodynamic and aerobic metabolism and to perform a protective ventilation for an optimal preservation in organ donor until organ harvest.

Statement of ethics

The research was conducted ethically in accordance with the World Medical Association Declaration of Helsinki. The patient gave his consent for publication of the report.

Funding

This research did not receive any specific grant from funding agencies in the public, commercial, or not-for-profit sectors.

Authors' contributions

SDR and GG wrote the first draft of the manuscript and provided revisions; CR critically revised the manuscript. All the authors read and approved the final version of the manuscript.

Declaration of competing interest

The authors do not have any conflicts of interest to disclose.

Acknowledgement

None.

Appendix A. Supplementary data

Supplementary data to this article can be found online at <https://doi.org/10.1016/j.rmcr.2020.101010>.

References

- [1] E.R. McFadden Jr., Acute severe asthma, *Am. J. Respir. Crit. Care Med.* 168 (2003) 740–759.
- [2] R. Greif, O. Akça, E.P. Horn, A. Kurz, D.I. Sessler, Outcomes Research Group, Supplemental perioperative oxygen to reduce the incidence of surgical-wound infection, *N. Engl. J. Med.* 342 (3) (2000 Jan 20) 161–167.
- [3] A. Gosain, J. Rabkin, J.P. Reymond, J.A. Jensen, T.K. Hunt, R.A. Upton, Tissue oxygen tension and other indicators of blood loss or organ perfusion during graded hemorrhage, *Surgery* 109 (4) (1991 Apr) 523–532.
- [4] W. Shoemaker, P. Appel, H. Kram, Oxygen transport measurements to evaluate tissue perfusion and titrate therapy: dobutamine and dopamine effects, *Crit. Care Med.* 19 (1991) 672–688.
- [5] T. Ikeda, F. Tayefeh, D.I. Sessler, A. Kurz, O. Plattner, B. Petschnigg, et al., Local radiant heating increases subcutaneous oxygen tension, *Am. J. Surg.* 175 (1998) 33–37.
- [6] O. Akça, M. Melischek, T. Scheck, K. Hellwagner, C.F. Arkilic, A. Kurz, et al., Postoperative pain and subcutaneous oxygen tension, *Lancet* 354 (1999) 41–42.
- [7] M. Oddo, F. Feihl, M.D. Schaller, C. Perret, Management of mechanical ventilation in acute severe asthma: practical aspects, *Intensive Care Med.* 32 (4) (2006 Apr) 501–510.
- [8] A.E. Laher, S.K. Buchanan, Mechanically ventilating the severe asthmatic, *J. Intensive Care Med.* 33 (9) (2018 Sep) 491–501.

- [9] N.A. Barrett, L. Camporota, The evolving role and practical application of extracorporeal carbon dioxide removal in critical care, *Crit. Care Resusc.* 19 (Suppl 1) (2017) 62–67, 31.
- [10] L. Camporota, N. Barrett, Current applications for the use of extracorporeal carbon dioxide removal in critically ill patients, *BioMed Res. Int.* 2016 (2016) 9781695.
- [11] A. Baker, D. Richardson, G. Craig, Extracorporeal carbon dioxide removal (ECCO2R) in respiratory failure: an overview, and where next? *J. Intensive Care Soc.* 13 (2012) 232–237.
- [12] T.B. Pendergraft, R.H. Stanford, R. Beasley, D.A. Stempel, C. Roberts, T. McLaughlin, Rates and characteristics of intensive care unit admissions and intubations among asthma-related hospitalizations, *Ann. Allergy Asthma Immunol.* 93 (1) (2004) 29–35.
- [13] E.R. McFadden, Acute severe asthma, *Am. J. Respir. Crit. Care Med.* 168 (7) (2003) 740–759.
- [14] T.G.V. Cherpanath, W.K. Lagrand, M.J. Schultz, A.B.J. Groeneveld, Cardiopulmonary interactions during mechanical ventilation in critically ill patients, *Neth. Heart J.* 21 (4) (2013) 166–172.
- [15] A. Rafanan, Ventilator waveforms: interpretation [published online August 12, 2014], <http://www.apsresp.org/pdf/esap/esap-201408-lectures/gp-2-1.pdf>. (Accessed 2 September 2016).
- [16] M. Nagarjuna, Ventilator waveform analysis [published online July 19, 2016], <http://www.indiachest.org/wp-content/uploads/2016/07/Ventilator-waveform-analysis-nagarjuna-2012.pdf>. (Accessed 2 September 2016).
- [17] T.J. Williams, D.V. Tuxen, C.D. Scheinkestel, D. Czarny, G. Bowes, Risk factors for morbidity in mechanically ventilated patients with acute severe asthma, *Am. Rev. Respir. Dis.* 146 (3) (1992) 607–615, <https://doi.org/10.1164/ajrccm/146.3.607>.
- [18] C. Chang, D. Yates, Use of early extra-corporeal membrane oxygenation (ECMO) for severe refractory status asthmaticus, *J. Med. Cases* 2 (3) (2011) 124–126.
- [19] A.H. Alzeer, H.A. Al Otair, S.M. Khurshid, S.E.I. Badrawy, B.M. Bakir, A case of near fatal asthma: the role of ECMO as rescue therapy, *Ann. Thorac. Med.* 10 (2) (2015) 143–145.
- [20] M.E. Mikkelsen, Y.J. Woo, J.S. Sager, B.D. Fuchs, J.D. Christie, Outcomes using extracorporeal life support for adult respiratory failure due to status asthmaticus, *Am. Soc. Artif. Intern. Organs J.* 55 (1) (2009) 47–52.
- [21] K.F. MacDonnell, H.S. Moon, T.S. Sekar, M.P. Ahluwalia, Extracorporeal membrane oxygenator support in a case of severe status asthmaticus, *Ann. Thorac. Surg.* 31 (2) (1981 Feb) 171–175.
- [22] K. Brenner, D.C. Abrams, C.L. Agerstrand, D. Brodie, Extracorporeal carbon dioxide removal for refractory status asthmaticus: experience in distinct exacerbation phenotypes, *Perfusion* 29 (1) (2014 Jan) 26–28.
- [23] M. Sakai, H. Ohteki, K. Doi, Y. Narita, Clinical use of extracorporeal lung assist for a patient in status asthmaticus, *Ann. Thorac. Surg.* 62 (3) (1996 Sep) 885–887.
- [24] S.C. Elliot, K. Paramasivam, J. Oram, A.R. Bodenham, S.J. Howell, A. Mallick, Pumpless extracorporeal carbon dioxide removal for life-threatening asthma, *Crit. Care Med.* 35 (3) (2007 Mar) 945–948.
- [25] C. Jung, A. Lauten, R. Pfeifer, et al., Pumpless extracorporeal lung assist for the treatment of severe refractory status asthmaticus, *J. Asthma* 48 (2011) 111–113.
- [26] J.L. Goudreau, E.F. Wijdicks, S.F. Emery, Complications during apnea testing in the determination of brain death: predisposing factors, *Neurology* 55 (7) (2000 Oct 10) 1045–1048.
- [27] G. Saposnik, G. Rizzo, A. Vega, R. Sabbatiello, J.L. Deluca, Problems associated with the apnea test in the diagnosis of brain death, *Neurol. India* 52 (3) (2004 Sep) 342–345.
- [28] A.R. Joffe, N.R. Anton, J.P. Duff, The apnea test: rationale, confounders, and criticism, *J. Child Neurol.* 25 (11) (2010 Nov) 1435–1443.
- [29] Coimbra Cicero Galli, Are “brain dead” (or “brain-stem dead”) patients neurologically recoverable? in: De Mattei Roberto, Paul A. Byrne (Eds.), *Finis Vitae: “Brain Death” Is Not True Death* Life Guardian Foundation, Oregon, Ohio, 2009, 313–78.