

Eosinophilic dermatosis after AstraZeneca COVID-19 vaccination

Editor

Local site reactions, urticaria and morbilliform eruptions have been recently reported as possible cutaneous adverse reactions after Moderna and Pfizer COVID-19 vaccination.¹ We would like to highlight that, in addition to the described skin manifestations related to COVID-19 vaccines, AstraZeneca COVID-19 vaccination could trigger a unique skin rash.

We observed a 70-year-old man with itchy urticarial plaques centred by tiny vesicles (Fig. 1) developed 5 days after the first dose of AstraZeneca vaccination. Cutaneous lesions started on the face and then progressively spread to the neck and trunk and, to a lesser extent, to the limbs over 1 week.

The lesions could have been consistent with a COVID-19-associated cutaneous manifestation, but the infection was excluded by a history of COVID-19 6 months before our observation and a negative molecular test. The patient was hospitalized and received 0.5 mg/kg/day methylprednisolone for one week tapered in the following 3 weeks, with complete resolution of the skin lesions.

During the hospitalization, we observed increased blood leukocyte and eosinophil counts, and C reactive protein up to a peak of $14.13 \times 10^3/\mu\text{l}$, $4.76 \times 10^3/\mu\text{l}$ and 11 mg/dl, respectively. These blood tests reverted to normal after 3 days. Fever (38.5°C)

was observed the day before the eosinophilia peak. Skin histology revealed spongiosis, intraepidermal vesicles and a superficial and deep dermal interstitial and perivascular CD4^+ and CD8^+ T lymphocyte and histiocyte infiltrate with numerous eosinophils consistent with an initial phase of eosinophilic cellulitis (Wells syndrome). Direct immunofluorescence was negative. We could not find any cause for the skin rash and acute eosinophilia other than the vaccination. The patient had been receiving lercanidipine chlorhydrate for arterial hypertension for many years and it was not discontinued. Chest radiography and abdomen ultrasound were negative. Viral serology did not show any reactivation of previous Herpes Simplex 1 and 2 virus and Varicella-Zoster virus infections, and HIV test was negative. Tzanck smear from a fresh vesicle and reflectance confocal microscopy examination of the affected skin did not show any sign of herpetic infection. Parasitological stool examination was also negative. Drug rash with eosinophilia and systemic symptoms (DRESS) syndrome diagnostic criteria were not fulfilled and cutaneous parasitoses were excluded due to negative skin scrapings and dermoscopy examinations.

Interestingly, the skin lesions of our patient had similarities with the COVID-19-related papulovesicular varicella-like exanthema.² Eosinophils were reported in some of the few available histological examinations of COVID-19-associated skin manifestations³ and blood eosinophilia is possibly associated with urticarial manifestations of COVID-19. Histological features of our case were consistent with those of eosinophilic cellulitis, an eosinophilic dermatitis that may show urticarial and vesicular features and has been reported as a rare adverse event following vaccines.^{4,5} We suggest including eosinophilic cellulitis among the huge spectrum of skin reactions to COVID-19 vaccines.

With large-scale vaccination programmes, even rare adverse effects of vaccines may be encountered more often. Thus, it is paramount that dermatologists worldwide are acquainted with the possible skin reaction patterns to the coming vaccines.

Acknowledgement

The patient in this manuscript has given written informed consent to publication of his case details.

Conflicts of interest

None.

Data availability statement

The data that support the findings of this study are available on request from the corresponding author. The data are not publicly available due to privacy or ethical restrictions.

Funding source

None.

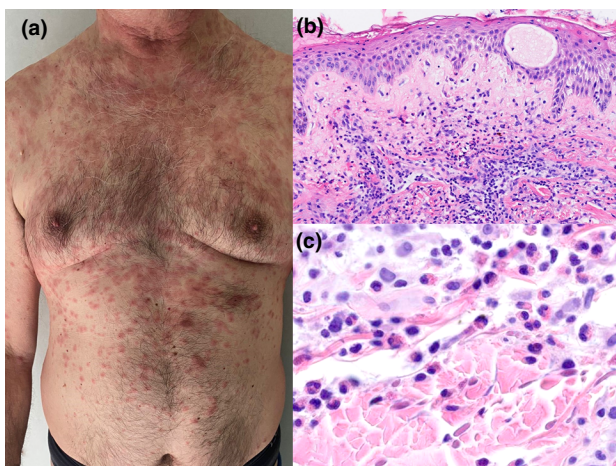


Figure 1 Clinical (a) and histological (b, c) aspect of the eosinophilic dermatosis developed after AstraZeneca COVID-19 vaccination. Histopathological examination (hematoxylin and eosin stain, b $20\times$ and c $80\times$) shows spongiosis with intraepidermal vesicles and dermal inflammatory infiltrate of lymphocytes and numerous eosinophils.

E. Cinotti,^{1,*} J.-L. Perrot,² F. Bruzziches,¹ L. Tognetti,¹ A. Batsikosta,³ E. Sorrentino,³ A.V. Marzano,^{4,5} P. Rubegni¹

¹Dermatology Unit, Department of Medical, Surgical and Neurological Sciences, University of Siena, Siena, Italy, ²Department of Dermatology, University Hospital of St-Etienne, Saint-Etienne, France, ³Department of Human Pathology and Oncology, Pathological Anatomy Section, University of Siena, Siena, Italy, ⁴Dermatology Unit, Fondazione IRCCS Ca' Granda Ospedale Maggiore Policlinico, Milan, Italy, ⁵Department of Pathophysiology and Transplantation, Università degli Studi di Milano, Milan, Italy

*Correspondence: E. Cinotti. E-mail: elisacinotti@gmail.com

References

- McMahon DE, Amerson E, Rosenbach M *et al*. Cutaneous reactions reported after moderna and pfizer COVID-19 vaccination: a registry-based study of 414 cases. *J Am Acad Dermatol*. 2021; **85**: 46–55. Published online April 7, 2021.
- Marzano AV, Genovese G, Fabbrocini G *et al*. Varicella-like exanthem as a specific COVID-19-associated skin manifestation: Multicenter case series of 22 patients. *J Am Acad Dermatol* 2020; **83**: 280–285.
- Gianotti R, Recalcati S, Fantini F *et al*. Histopathological study of a broad spectrum of skin dermatoses in patients affected or highly suspected of infection by COVID-19 in the northern part of Italy: analysis of the many faces of the viral-induced skin diseases in previous and new reported cases. *Am J Dermatopathol* 2020; **42**: 564–570.
- Cinotti E, Rongioletti F. New emerging diseases or syndromes in dermatopathology with impact on clinical management. *Expert Rev Dermatol* 2012; **7**: 69–80.
- Safran T, Masckauchan M, Maj J, Green L. Wells syndrome secondary to influenza vaccination: A case report and review of the literature. *Hum Vaccines Immunother* 2018; **14**: 958–960.

DOI: 10.1111/jdv.17806

Lymphomatoid drug reaction developed after BNT162b2 (Comirnaty) COVID-19 vaccine manifesting as pityriasis lichenoides et varioliformis acuta-like eruption

Editor

The current global healthcare response to the COVID-19 pandemic is focused on a widespread vaccination campaign, which started with the authorization of Pfizer/BioNTech and Moderna mRNA COVID-19 vaccines in December 2020. Local injection site reactions have been described during the clinical trials of both the abovementioned mRNA vaccines; skin rashes were additionally reported in the trial of Moderna. Despite this,

cutaneous adverse reactions to the vaccines and their timing remain to date poorly characterized.^{1,2}

A 31-year-old Caucasian woman presented with an acute generalized rash arising 10 days after the first dose of BNT162b2 (Comirnaty, Pfizer/BioNTech), which was mildly itchy and associated with fatigue. No reactions at the site of injection and no systemic symptoms, such as fever, were reported. The patient denied taking any medication prior to the eruption. Past and recent medical history was uneventful. Skin examination showed erythematous-pinkish papular lesions partially covered by sero-hematic crusts, involving the trunk, the arms, legs and the face (Fig. 1). The mucous membranes were apparently spared. Bilateral inguinal lymphadenopathy was appreciated at physical examination. The evaluation of serum inflammatory markers, liver and renal function tests, vasculitis-specific antibodies and other markers of autoimmunity was unremarkable. Blood tests for viral and bacterial infections were also negative. The diagnostic workup was completed by skin histologic and immunohistochemical studies: the histopathologic findings were hyperkeratosis producing scaling and crusting. There was reactive epidermal hyperplasia, diffuse spongiosis with foci of mixed, lympho-monocytic infiltrates, as well as the presence of Langerhans cells and granulocytes. The superficial and medium dermis were also involved with a dense, polymorphic inflammatory

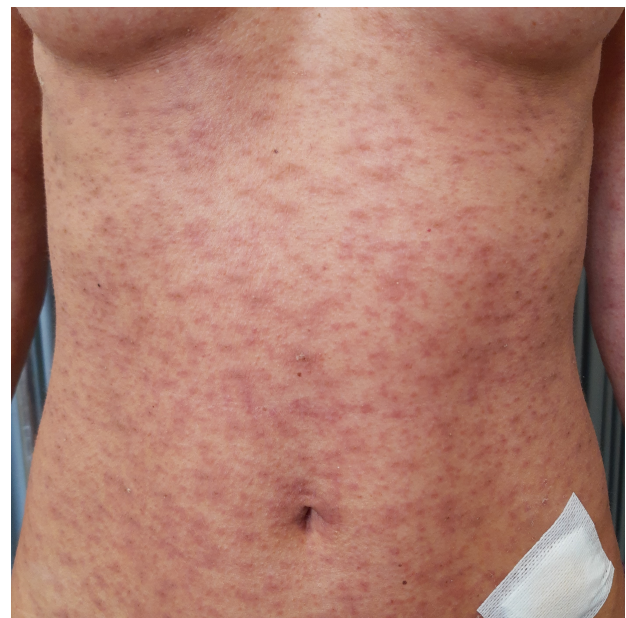

Figure 1 Lymphomatoid drug reaction. Erythematous papular lesions partially covered by sero-hematic crusts, clinically resembling pityriasis lichenoides et varioliformis acuta, are appreciated on the trunk of a 31-year-old female subject.