

# Papillary mucinous cystadenoma of the kidney: Case report and review of literature

JINGSHENG LIU<sup>1\*</sup>, QIAN ZHAO<sup>2\*</sup>, YUANYUAN ZHANG<sup>3</sup> and LIANG XIE<sup>4</sup>

<sup>1</sup>Department of Urology, Cangzhou Hospital of Integrated TCM-WM•HEBEI, Cangzhou, Hebei 061000; Departments of <sup>2</sup>Pharmacy and <sup>3</sup>Geriatrics, North China Petroleum Administration Bureau General Hospital, Renqiu, Hebei 062552; <sup>4</sup>Department of Urology, Cangzhou People's Hospital, Cangzhou, Hebei 061000, P.R. China

Received March 22, 2022; Accepted April 28, 2022

DOI: 10.3892/etm.2022.11378

**Abstract.** Epithelial tumors that originate from the kidney are uncommon. The majority of cases reported in the literature are malignant, with <1% of adenocarcinomas. Adenomas are even rarer. A case of mucinous cystadenoma of the kidney was diagnosed and treated in Cangzhou Hospital of Integrated TCM-WM•HEBEI. The clinical feature of this disease was atypical. The principal symptom of mucinous cystadenoma of the kidney was a lump in the upper abdomen with intermittent pain in the abdomen. The tumor size ranged from 5-12 cm. The patient was clinically diagnosed with multiple renal cysts with thickened walls and hemorrhage. The patient was admitted to the hospital five days later, and a left nephrectomy was performed. The tumor capsule was integrated and did not adhere to the adjacent tissue. One or multiple smooth-walled dilated cystic areas were found on the cut section, some of which were filled with grey opaque gelatinous clots. Under light microscopy, the epithelial lining was characterized by a single layer of columnar with papillary proliferation and almost had no mitosis. Immunohistochemistry showed that the cyst was positive for carcinoembryonic antigen (CEA) and proliferating cell nuclear antigen (PCNA). Following nephrectomy, the patient was followed up for 8 years and no recurrence and metastasis were found. A total of five articles were retrieved, including six cases with mucinous cystadenoma of the kidney. The clinical feature of this disease was atypical, making clinical diagnosis difficult. Histopathological examination revealed that the cyst consisted of mucinous epithelium with supporting fibrous tissue and immunohistochemistry showed that the cyst was positive for CEA and PCNA. Patients with all resection of the affected kidney had an improved prognosis.

## Introduction

Mucinous epithelial tumors originating from the kidney are uncommon. Most reported cases are malignant. Only isolated cases have been reported where the epithelial lining of the tumor was benign (1). In the present study, clinical data of a patient with mucinous cystadenoma of the kidney, who was treated at hospital in December 2011, were analyzed. A literature review was also performed to investigate clinicopathologic features and treatment of mucinous cystadenoma of the kidney.

## Case report

A 52-year-old Chinese woman complained of angina capitis, dizziness, and intermittent pain in the abdomen for 6 days with a 3-year history of hypertension. Physical examination on admission showed nothing remarkable. The laboratory data revealed normal values. From abdominal computed tomography, an ovoid cyst with a diameter of 12 cm and partial calcifications in the cystic wall was found in the inferior pole of the left kidney. Additionally, two cystic masses measuring 2 cm in diameter were found in the left kidney. The patient was clinically diagnosed with multiple renal cysts with thickened walls and hemorrhage. An intravenous pyelogram revealed that a large, round, high-density mass had developed in the left kidney and part of the pelvic area, and the calyx was absent. A diagnosis of a large cyst in the left kidney and left hydronephrosis was made. No relevant past interventions were implemented.

The diameter of the renal cysts of the present case reached 12 cm. The patient was clinically diagnosed with multiple renal cysts with thickened walls and bleeding. As the disease has malignant potential, a left nephrectomy was performed. Only a few ml of cyst material were obtained during the surgery via renal cyst aspiration to determine cyst fluid characteristics. Due to the mucinous and characteristic thickness of the cyst content, it was impossible to empty the cyst.

From sections, the specimen showed grossly distorted kidney and pelvic tissue. The well-defined monolocular cyst was 10 cm in diameter, filled with gray-red jelly mucin, and located in the upper half of the kidney (Fig. 1). The inner surface was gray-white, turbid, and rather smooth and showed no apparent tumorous protrusion. The cyst wall was 0.2-0.4 cm thick and accompanied by focal calcifications, which led to pressure

---

*Correspondence to:* Dr Qian Zhao, Department of Pharmacy, North China Petroleum Administration Bureau General Hospital, South Huizhan Road, Renqiu, Hebei 062552, P.R. China  
E-mail: 524110335@qq.com

\*Contributed equally

**Key words:** mucinous cystadenoma, kidney, nephrectomy, case report, literature review

atrophy of the renal parenchyma. The border between the cyst and residual renal pelvis formed a firm septum without any communication through the lumen. In addition, two cysts of 2 cm in diameter were located around the large cyst and contained dark red liquid. The two cysts were 0.2 cm thick. No calculi had formed in the urinary tracts or cyst. No tumorous lesion was found in the renal parenchyma.

Histopathological examination of the renal cyst wall revealed that it consisted of mucinous epithelium with supporting fibrous tissue. The epithelial lining was characterized by a single layer of columnar cells with sporadic papillary proliferation (Fig. 2A and B). Atrophy in the renal glomerulus and tubules were found in some sections of the cyst wall. Therefore, the cyst was believed to arise from the renal parenchyma, not from the collecting system. Histopathology was consistent with mucinous cystadenoma. Immunohistochemistry showed that the cyst was positive for carcinoembryonic antigen (CEA) and proliferating cell nuclear antigen (PCNA; Fig. 2C and D). No adverse and unanticipated events occurred following surgery. Furthermore, an 8-year follow-up was conducted. The patient was well, and there was no evidence of recurrence or metastasis. The patient was highly satisfied with the treatment methods and outcomes.

### Literature review

To further elucidate the clinical manifestations, treatment, and prognosis of mucinous cystadenoma of the kidney, a literature review was conducted. The search was performed using PubMed and the following search terms were used in all databases: ((kidney[Title/Abstract]) OR (renal[Title/Abstract])) AND (cystadenoma[Title/Abstract]). A total of five articles were retrieved, including six cases with mucinous cystadenoma of the kidney. A total of six cases (1-5) were reported between 1985 and 2015 (Table I). of these, two cases arose from the left kidney, three cases from the horseshoe kidney, and one case from the right kidney. The onset age was between 27 and 69 years. Three cysts occurred in female patients and three in male patients. Of these six patients, three patients with capillary mucinous cystadenomas had horseshoe kidney deformities, suggesting that renal tumor may be associated with congenital kidney malformation.

### Discussion

Benign primary mucinous cystadenomas arising from the kidney are extremely rare. Some reports have shown that mucinous cystadenomas originate from the renal pelvis (2,4,5), while others have shown that they originate from the renal parenchyma (1). In the present case, the cyst originated from the renal parenchyma. The cause of this disease remains elusive. Mardi *et al* (6) suggest the possibility that an adenoma-carcinoma sequence might exist among glandular neoplasms arising from the renal pelvis. According to this theory, the normal transitional epithelium may undergo squamous, columnar, or cuboidal metaplasia. Gangane *et al* (2) hypothesize that mucinous metaplasia may progress into an adenoma, which may then progress into a malignancy. Kobayashi *et al* (7) hypothesize that kidney calculi and long-standing chronic infection are possible etiologic factors for mucinous adenocarcinoma of the pelvis. However, not all patients with mucinous cystadenoma arising from the kidney had such preceding lesions. It is unclear

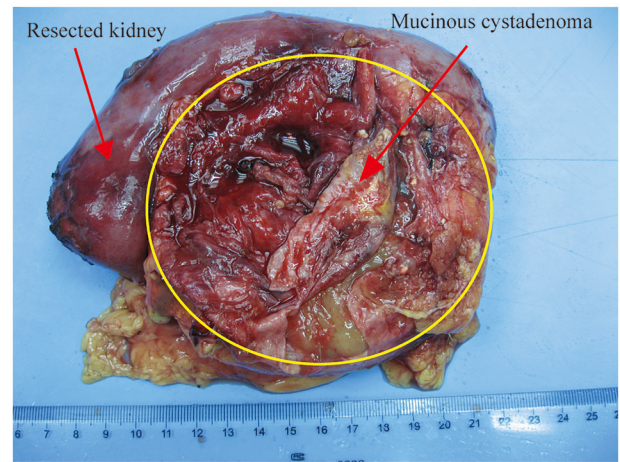


Figure 1. Gross appearance of the resected kidney and mucinous cystadenoma.

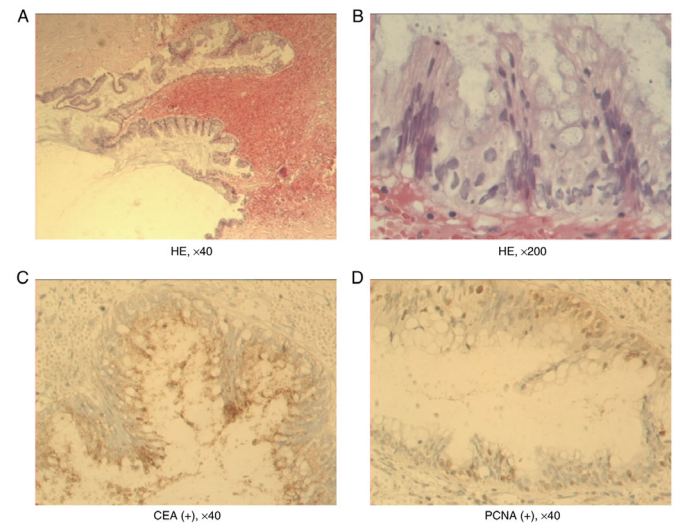


Figure 2. Pathologic examination. (A) Tumor tissue squeezed the kidney around it, and the boundary between renal tissue with glomeruli and tubular atrophy and tumor tissue with fibrosis and chronic inflammatory cell infiltration is clear (HE; magnification, x40). (B) Monolayer mucinous columnar epithelium lining the cyst wall with papillary proliferation (HE; magnification, x200). (C and D) Immunohistochemical analysis indicated positive staining for (C) CEA and (D) PCNA (magnification, x40). HE, hematoxylin and eosin stain; CEA, carcinoembryonic antigen; PCNA, proliferating cell nuclear antigen.

whether the same hypothesis also holds for adenomas. A total of six cases (1-5) were reported, of which three patients with capillary mucinous cystadenomas had horseshoe kidney deformities, which suggests that the renal tumor may be associated with congenital kidney malformation. Patients suffering from mucinous epithelial tumors originating from the kidney have no specific symptoms, and most of these tumors are found from physical examination or based on nonspecific symptoms, such as abdominal pain, abdominal lumps, and other symptoms. Generally, the tumor is 5-12 cm across. In the present case, the patient presented with headache and dizziness, and a tumor of 10 cm across was found.

Renal mucinous cystadenoma is a tumor with a single capsule or polycystic tumor containing jelly-like mucus. During microscopic examinations, a single-layered tall columnar mucinous epithelium, and occasionally papillary hyperplasia, can be found

Table I. Review of reported mucinous cystadenoma of the kidney.

Author, year	Sex	Age, years	Chief complaint	Tumor size, cm	Treatment	Pathology	Follow-up time	Recurrence	(Refs.)
Gangane <i>et al</i> , 2008	Female	35	Intermittent pain in the abdomen	NA	Left nephrectomy	Mucinous cystadenoma	2 years	None	(2)
Gangane <i>et al</i> , 2008	Male	65	Pain in the abdomen, weakness and loss of appetite	NA	Left nephrectomy	Mucinous cystadenoma arising from the renal pelvis with changes of pyonephrosis	8 months	None	(2)
Toyoda <i>et al</i> , 1997	Male	69	Dysuria	5	Right nephrectomy	Mucinous cystadenoma with malignant transformation	2 years	None	(5)
Ross and D'Amato, 1985	Female	59	Experiencing abdominal pain	7	Partial nephrectomy	Horseshoe kidney, mucous papillary cystadenoma of renal pelvis	4 years	None	(4)
Akan <i>et al</i> , 2005	Female	27	A mass was incidentally discovered in the right upper quadrant of the abdomen	12	Cyst excision	Horseshoe kidney, mucinous cystadenoma	22 months	None	(1)
Mitome <i>et al</i> , 2015	Male	45	A palpable mass in the left abdomen	15	Cyst excision	Horseshoe kidney, mucinous cystadenoma	6 months	None	(3)

NA, information not available.

inside the wall. Thus, it is not difficult to make a pathological diagnosis. Toyoda *et al* (5) hypothesize that the diagnosis of malignant/benign tumors can be safely made only if the following criteria are met: i) Macroscopic or microscopic evidence of invasion, metastasis, or recurrence; and ii) histological evidence of structural or cellular atypia. However, despite the first criterion, the second criterion alone is the basis for judgments. This case does not meet the above criteria for histology; thus, the diagnosis was a benign tumor. The patient was symptom-free during the 8-year follow-up period. Ross and D'Amato (4) hypothesize that renal mucinous cystadenoma and ovarian mucinous cystadenoma tissues are very similar, suggesting that the criteria used to evaluate mucinous ovarian tumors might also be appropriate for mucinous tumors of the kidney.

As for renal mucinous cystadenoma treatment, Akan *et al* (1) suggest that as there are no definite diagnostic radiological criteria, the treatment should be individualized. If a malignancy is suspected, partial nephrectomy or cyst excision can be performed. Benign cysts found from imaging can be followed. Fine-needle aspiration biopsy should be performed first if the cyst compresses the collecting system. If needle aspiration fails due to viscous cyst content or if the malignant material is extracted, surgical specimens can be obtained through the operation. Thus, a diagnosis can be made and confirmed. Kawahara *et al* (8) present a case of primary renal carcinoid coexistent with a mucinous cystadenomatous element. Takashi *et al* (9) report the first documented composite tumor of mucinous cystadenoma and somatostatinoma of the kidney. They consider that excision is the first choice for treatment due to the unspecific clinical manifestations of this case, difficult preoperative qualitative diagnosis, and probable malignant tumor. Moreover, the cyst wall is thin and may rupture during surgery. Total nephrectomy is advocated to prevent metastasis. Of the six cases reported, three cases were treated with nephrectomy, one case with partial renal nephrectomy, and two cases with cyst excision. Complete laparoscopic resection is not advocated as it may be difficult to separate the tumor, or the tumor may rupture due to adhesions between renal mucinous papillary cystadenoma and the surrounding tissue. Therefore, manual laparoscopic nephrectomy or open nephrectomy is recommended. Although the cyst is possibly malignant in this case, the patient was in good condition 8 years after surgery, and there was no evidence of recurrence or metastasis. The patient was highly satisfied with the treatment methods and outcomes. The limitation of the present study is that there is no corresponding pre-operative imaging data.

In the present study, a case of mucinous cystadenoma of the kidney was reported. The left nephrectomy was performed and no tumor recurrence was found during the 8-year follow-up. The clinical feature of this disease was atypical, making clinical diagnosis difficult. Histopathological examination revealed that the cyst consisted of mucinous epithelium with supporting fibrous tissue and immunohistochemistry showed that the cyst was positive for CEA and PCNA. The main treatment is partial nephrectomy or nephrectomy, and postoperative follow-up is required. Patients with this disease had an improved prognosis.

## Acknowledgements

Not applicable.

## Funding

No funding was received.

## Availability of data and materials

The datasets used and/or analyzed during the current study are available from the corresponding author on reasonable request.

## Authors' contributions

LX and YZ designed the study and revised the manuscript. JL and QZ collected and analyzed the patient data. YZ contributed to data extraction, quality assessment and drafted the paper. QZ and JL checked and confirm the authenticity of the raw data. All authors contributed to the manuscript and all authors read and approved the final manuscript.

## Ethics approval and consent to participate

Not applicable.

## Patient consent for publication

The patient gave written informed consent for the publication of this case report and all accompanying images.

## Competing interests

The authors declare that they have no competing interests.

## References

1. Akan H, Dalva I, Yildiz O, Kutluay L, Gündoğdu S and Güngen Y: Mucinous cystadenoma mimicking simple renal parenchymal cyst in a horseshoe kidney. *Int J Urol* 12: 493-496, 2005.
2. Gangane N, Anshu, Shende N and Sharma SM: Mucinous cystadenoma arising from renal pelvis: A report of 2 cases. *Urol J* 5: 197-199, 2008.
3. Mitome T, Yao M, Udaka N, Fusayasu S, Izumi K, Osaka K, Hayashi N, Nakaigawa N, Nagashima Y and Kubota Y: Mucinous cystadenoma of a horseshoe kidney: A case report and literature review. *Can Urol Assoc J* 9: E30-E32, 2015.
4. Ross DG and D'Amato NA: Papillary mucinous cystadenoma of probable renal pelvic origin in a horseshoe kidney. *Arch Pathol Lab Med* 109: 954-955, 1985.
5. Toyoda H, Mabuchi T and Fukuda K: Mucinous cystadenoma with malignant transformation arising in the renal pelvis. *Pathol Int* 47: 174-178, 1997.
6. Mardi K, Sharma J and Mahajan P: Mucinous cystadenoma of the renal pelvis with malignant transformation: A case report. *Indian J Pathol Microbiol* 49: 595-596, 2006.
7. Kobayashi S, Ohmori M, Akaeda T, Ohmori H and Miyaji Y: Primary adenocarcinoma of the renal pelvis. Report of two cases and brief review of literature. *Acta Pathol Jpn* 33: 589-597, 1983.
8. Kawahara T, Nagashima Y and Misaki H: Primary renal carcinoid tumor with a mucinous cystadenoma element. *Int J Urol* 16: 920-921, 2009.
9. Takashi M, Matsuyama M, Furuhashi K, Kodama Y, Shinzato M, Shamoto M and Nakashima N: Composite tumor of mucinous cystadenoma and somatostatinoma of the kidney. *Int J Urol* 10: 603-606, 2003.



This work is licensed under a Creative Commons Attribution-NonCommercial-NoDerivatives 4.0 International (CC BY-NC-ND 4.0) License.