

# Multifocal Humeral Fractures: Clinical Results, Functional Outcomes and Flowchart of Surgical Treatment

Michelangelo Scaglione<sup>1</sup>, Francesco Casella<sup>2</sup>, Edoardo Ipponi<sup>3</sup>, Federico Agretti<sup>4</sup>, Simone Polloni<sup>5</sup>, Michele Giuntoli<sup>6</sup>, Stefano Marchetti<sup>7</sup>

## ABSTRACT

**Aim and objective:** Multifocal fractures of the humerus are rare. The aim of our study is to evaluate the effectiveness of surgical treatment and propose a modification to the Maresca–Pascarella classification. A flowchart for surgical treatment is provided.

**Materials and methods:** Thirty-one patients with multifocal humeral fractures were treated and evaluated. The Maresca–Pascarella classification was used. All were treated using with either plates and screws, external fixation or intramedullary nailing. Functional outcomes were evaluated using the QuickDASH test, the University of California – Los Angeles (UCLA) shoulder score and the Mayo elbow performance score (MEPS).

**Results:** There were 12 Type A, 17 Type B, 1 Type C and 1 of combined fractures of the proximal and distal epiphysis. Of the 31 patients, 5 were lost to the follow-up (FU), 1 died of pulmonary embolism (PE) and the remaining 25 had a mean FU of 19.8 (7–35) months. Three patients had radial nerve damage and 1 went to a non-union that required further surgical intervention. The mean QuickDASH score was 15.7, the average UCLA shoulder score was 26.3 and the mean MEPS elbow score resulted to be 83.0.

**Conclusion:** Although multifocal fractures are severe injuries, patients are able to recover good functionality if treated judiciously.

**Clinical significance:** We proposed a standardised surgical approach based on the fracture characteristics, site and a modified Maresca–Pascarella classification.

**Keywords:** Bone screws, Elbow, External fixators, Fracture fixation, Humeral fractures, Intramedullary, Segmental, Shoulder.

*Strategies in Trauma and Limb Reconstruction* (2022): 10.5005/jp-journals-10080-1559

## INTRODUCTION

Humeral fractures are common and account for 7–8% of all fractures in general population.<sup>1</sup> Data from the United States of America show the proximal humerus is most affected with an annual incidence of 60 in 100,000 persons per year. A significant correlation is present with advancing age; after the age of 45 years, the risk rises until a peak around the age of 85 years. Distal humeral fractures have a lower incidence at 40 in 100,000 persons per year, involving children under 15 years of age mainly. The humeral shaft is the least frequently involved, with an incidence of about 20 persons in 100,000 per year and has no age peak.<sup>2</sup>

Nearly 90% of all humeral fractures occur after a fall; less common mechanisms of injury are motor vehicle accidents. These fractures have significant impact on patients' autonomy and quality of life, even becoming life-threatening injuries in the elderly.<sup>3–5</sup> Accurate diagnosis and appropriate treatment are mandatory to restore local anatomy and upper limb functionality. While the available classifications and treatments remain controversial and debated,<sup>6,7</sup> the literature provides some evidence for the management of fractures involving single segments of the humerus.<sup>8–15</sup> However, there is a paucity of studies on multifocal or segmental humeral fractures. These uncommon injuries, less than 1% of all humeral fractures, still lack a comprehensive classification and treatment consensus. The AO classification does not subclassify multifocal fractures involving different sites of the same bone since the system is limited to a single segment subcategorization.

In 2014, Maresca et al.<sup>15</sup> proposed a classification for multifocal fractures with subdivisions within to guide surgeons in choosing

<sup>1–7</sup>Department of Orthopedics and Trauma Surgery, University of Pisa, Pisa, Italy

**Corresponding Author:** Edoardo Ipponi, Department of Orthopedics and Trauma Surgery, University of Pisa, Pisa, Italy, Phone: +39 050993415, e-mail: edward.ippo@gmail.com

**How to cite this article:** Scaglione M, Casella F, Ipponi E, et al. Multifocal Humeral Fractures: Clinical Results, Functional Outcomes and Flowchart of Surgical Treatment. *Strategies Trauma Limb Reconstr* 2022;17(2):81–87.

**Source of support:** Nil

**Conflict of interest:** None

the most suitable treatment for each patient. The classification of these multifocal fractures includes the following: Type A if they affect proximal humerus and humeral shaft; Type B if the injury is limited to the shaft; and Type C if the involved segments are humeral diaphysis and distal epiphysis. Type A fractures can be further divided into three subgroups: A1 with humeral shaft displacement but an undisplaced proximal humerus; A2 with proximal humerus and shaft displacement and A3 for multifragmentary fractures that extend from proximal humerus to the shaft (Fig. 1).

Suitable approaches for surgical treatment of multifocal humeral fractures are external fixation, intramedullary nailing and plate fixation with each one having advantages and disadvantages. The optimal choice, with due consideration for the patient's anatomical and global clinical picture, prompts the need for a treatment algorithm which is not available to this date.

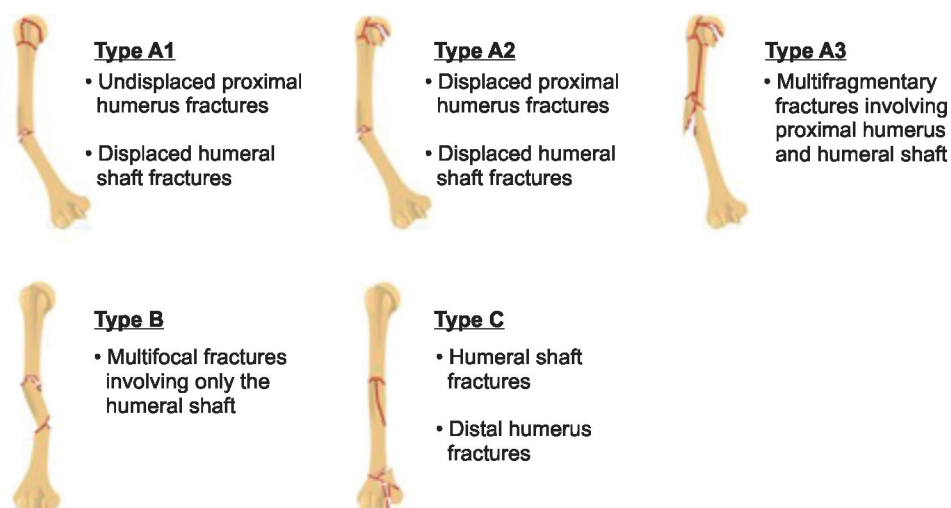


Fig. 1: Maresca–Pascarella classification of multifocal humeral fractures

The aim of our study is to review the results from our own work on these fractures and to propose slight changes to the classification made by Maresca et al. to befit an algorithm for surgical treatment.

## MATERIALS AND METHODS

This single-centre retrospective study was ethical committee approved and has been performed in accordance with the ethical standards laid down in the 1964 Declaration of Helsinki and its later amendments. All patients gave written consent.

Between March 2016 and March 2020, a total of 425 patients were treated surgically for humeral fractures, 31 (7.3%) of which were multifocal. Of these 31 patients, 9 patients were males and 22 were females, and the sample had an average age at surgery of 64 (21–90) years. The fractures were caused by an accidental fall in 22 patients as follows: in 13 patients, the fall was from a height lower than 2 m whereas in the remaining 9 patients, the patient fell from more or 2 m. Six patients were from a motor vehicle collision, two patients suffered a sport injury and one patient was hit by a wild animal. All patients had pre-operative X-rays to diagnose and evaluate the fracture morphology, whereas postoperative X-rays were used to verify the surgical reduction of bone fragments and placement of fixation devices.

The medical records indicated that three patients had overt osteoporosis, three patients with diabetes, one patient had a grade II chronic kidney disease and one patient had cirrhosis of the liver.

The 31 patients were categorised according to the Maresca classification before surgery as follows: 7 patients (22.6%) were of Type A1 fracture, 3 patients (9.7%) were of Type A2 fracture, 2 patients (6.4%) were of Type A3 fracture, 17 (54.8%) were of Type B fracture and only 1 (3.2%) was classified as Type C fracture. One fracture did not fit the classification by Maresca et al. due to the combination of fractures involving proximal and distal humerus. One patient (of Type A1 fracture) had an open fracture and another patient was diagnosed to have a radial nerve lesion from the injury.

Of the seven patients of Type A1 fracture, five patients were treated with intramedullary nails (Fig. 2). The other two patients were treated with external fixators because one was an open fracture and the other owing to the presence of a haematoma close to the radial nerve which was first discovered by ultrasound and then confirmed using a CT angiography. This diagnosis of

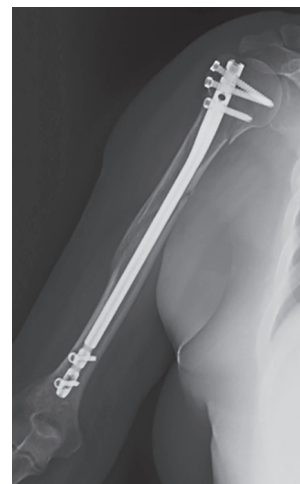

Fig. 2: A patient of A1 fracture, according to the Maresca–Pascarella classification, treated with an endomedullary nail

the haematoma prompted a less invasive intervention with the plan to drain the collection at a second stage. Five days after humeral external fixation, an open drainage of the haematoma was carried out to decompress the nerve; at surgery, we noted the organised hematoma was compressing the radial nerve which was intact despite the pressure. This intervention was successful and no permanent neurological damage remained. The three patients of Type A2 fracture were treated with different fixation devices: one angle-stable plate and screw implant, one with an intramedullary nail and the third with external fixation. Both two patients of Type A3 fracture were treated with plate and screw fixation. The 17 patients with Type B fracture had the following surgeries: 10 intramedullary nailing, 4 external fixation and 3 fixations with plates and screws. The Type C fracture was treated with two plates to achieve better structural stability. The fracture that was not classified, due to the combination of proximal and distal humeral fractures, had external fixation applied to heal the proximal fracture component and fixation with plates and crews to stabilise the distal epiphysis. Summarising, 16 (51.6%) patients were treated with intramedullary nails, 7 (22.6%) patients with plates and screws, 7 (22.6%) patients with external fixation and 1

(3.2%) with a combination of external fixation and plate fixation. Open fractures of degree III A, B or C according to the Gustilo Anderson classification<sup>16</sup> were treated with external fixation in accordance with the current principles of surgical management for open fractures, regardless of the fracture pattern.

After surgery, the shoulder and elbow were immobilised for 2 weeks. Passive mobilization of the shoulder and elbow was encouraged for the next 2 weeks. One month after surgery, patients were allowed to start active mobilization gradually with a functional restoration schedule adapted to the individual.

Postoperative FU consisted of periodic outpatient visits with X-rays and clinical evaluations to assess bone and soft tissue healing alongside restoration of upper limb mobility and function. Each patient underwent clinical and radiographical evaluation at 30, 60 and 120 days from surgery, regardless the surgical approach undertaken. After 4 months, the frequency of outpatient visits was further reduced to every 4–6 months for the next 3 years; thereafter, on a yearly basis. Eventual additional visits were scheduled depending on the needs of the patient. External fixators were removed around 2–3 months after the first intervention when the radiographic images suggested a good amount of bone healing had been achieved; before removal, stressing the fracture site under X-ray control was performed to confirm union stability.

The functional outcomes were recorded at the latest FU using the Quick DASH test, the UCLA shoulder score and the MEPS elbow score.

## RESULTS

The results are reported for 26 patients. Five patients were lost at last FU. The remaining 26 patients had a mean FU of 19.8 (7–35) months. Postoperative results for all 31 patients are presented in Table 1. One patient died of PE in less than 1 month after the surgery. Among the remaining 25 patients, 24 patients had successful bone healing without further surgical intervention with a mean union time of 3.3 (2–6) months. One patient, a 46-year-old male with a Type C fracture treated with plates and screws, developed a non-union. Infection was excluded with normal values from serological tests and the absence of clinical signs of inflammation. Revision surgery was performed 6 months after the index procedure and this consisted of removal of the prior fixation devices and the implantation of two new plates. This patient sustained persistent radial nerve damage that limited the final functional outcome. Radial nerve palsy was reported in the following two other patients: A 48-year-old female patient with a Type B fracture that was treated with plates and screws and a 64-year-old female with a Type A1 fracture who had external fixation. This latter patient developed a large hematoma that surrounded and compressed the radial nerve over the middle third of the arm and required surgical drainage 5 days after the first orthopaedic intervention. None of the patients developed deep or superficial infections of the involved anatomical site nor wound dehiscence.

The functional results were: the mean QuickDASH score was 15.7 (0–40.9); the average UCLA shoulder score was 27.0 (15–35); and the mean MEPS elbow score was 83.0 (40–100). These functional results are tabulated in Table 1. Patients with Type A fractures had mean QuickDASH, UCLA shoulder and MEPS elbow scores, 10.3, 29.0 and 91.4, respectively. Patients with Type B fractures had slightly worse outcomes (Quick DASH score 16.4,

UCLA shoulder score 25.7, MEPS elbow score 81.7). In particular, patients with Type A fractures were more likely to have good or excellent elbow functionality (MEPS scores 75 or higher) in comparison to the rest of the sample (91% against 64%), although this did not reach statistical significance ( $p = 0.180$ ).

The patient with Type C fracture had poor QuickDASH (40.9), UCLA (15) and MEPS scores (50), confirming the influence of the associated radial nerve palsy and non-union with need for revision surgery. The 67-year-old man who had a combination of proximal and distal humerus fractures had similar functional outcomes, despite the absence of major local complications or reinterventions.

Using the Fisher exact test, we could demonstrate that the patients with local complications and chronic radial nerve damage had a significantly higher risk of poor UCLA shoulder scores (20 or lower in 2 of 3 patients) as compared to the others ( $p = 0.029$ ). Similarly, these same patients were less likely to have good or excellent postoperative elbow functionality (MEPS-ES >75) as compared to the remaining patients ( $p = 0.009$ ).

There was no correlation between patients' age at surgery and functional outcomes (QuickDASH, UCLA-SS and MEPS-ES). In this sample, the UCLA shoulder scores and the MEPS scores, which are meant to evaluate the functional outcome of a single articulation, had a strong negative correlation with the QuickDASH values, which is used to evaluate the upper limb as a whole (Pearson's  $R$  values:  $-0.77$ ,  $-0.94$ ;  $p < 0.001$ ). Statistical analysis also showed a significant positive correlation between UCLA-SS and MEPS-ES (Pearson's  $R$  value:  $0.90$ ;  $p < 0.001$ ), confirming a strong association between postoperative shoulder and elbow function in patients with multifocal fractures of the humerus.

The functional results and complication rates of patients with osteoporosis or diabetes did not significantly differ from the rest of the sample although the small size would not allow meaningful analysis.

## DISCUSSION

Multifocal (segmental) humeral fractures are uncommon injuries and the number of studies reporting the incidence is limited. According to McQueen and Broadbent,<sup>17</sup> these represent only 0.1% of all fractures involving the upper limb. In 2014, Pascarella and Maresca<sup>15</sup> reported multifocal fractures in 4.8% of 717 patients of humeral fractures that required surgery. In the same year, Zambrosky et al.<sup>18</sup> reported on 278 humeral fractures of which 11 (3.9%) were multifocal. Our sample showed that 7.3% of the 425 humeral fractures that required surgical treatment were bifocal or multifocal, this incidence is higher than the ones previously published. There was a higher incidence of multifocal fractures in female patients (22 of 31) with an average age at surgery of 63 years, this being comparable to that in the literature. With a growing ageing population, it is reasonable to think that the incidence of multifocal humeral fractures will increase.

The AO and OTA fracture classifications do not separate multifocal humeral fractures from others. Complex humeral shaft fractures are described as 12C while variations in this group are not determined. To overcome this limitation, Pascarella and Maresca proposed a classification that divides multifocal fractures in Types A1, A2, A3, B and C.<sup>15</sup> This designation had been established and was used to catalogue the patients in this study although one fracture could not be accounted for using the criteria proposed in this 2014. Another limitation from the Maresca and Pascarella study

**Table 1:** Detailed patients' data. Surgical delay is the time gap between the traumatic event and the beginning of surgical procedure. Healing time was considered as the time between surgery and radiographic signs showing complete bridging of the fracture gap

N	Age (years)	Gender	Surgical delay (hours)	Fracture type (Maresca-Pascarella)	Surgical approach	Healing time (months)	Complications	Quick dash	UCLA shoulder	MEPS elbow	F-U
1	43	F	15	A1	Intramedullary nailing	2	None	0	34	100	24
2	75	F	18	A1	Intramedullary nailing	6	None	11.4	27	85	25
3	67	M	16	A1	Intramedullary nailing	2	None	13.6	26	95	26
4	57	F	50	A1	Intramedullary nailing	5	None	4.5	32	100	24
5	76	F	16	A1	Intramedullary nailing	3	None	31.9	24	80	7
6	71	M	9	A1	External fixation	-	-	-	-	-	L
7	64	F	4	A1	External fixation	5	Hematoma with transitory radial deficits (before hematoma drainage)	27.3	20	70	16
8	73	F	35	A2	Intramedullary nailing	3	None	0	35	100	14
9	71	F	9	A2	External fixation	2	None	2.3	34	100	26
10	78	M	13	A2	Plate and screws	3	None	15.3	26	80	15
11	50	M	24	A3	Plate and screws	3	None	4.5	29	95	11
12	77	F	37	A3	Plate and screws	3	None	2.3	32	100	24
13	84	F	9	B	Intramedullary nailing	3	None	20.5	22	85	24
14	47	F	11	B	Intramedullary nailing	-	-	-	-	-	L
15	90	F	41	B	Intramedullary nailing	-	-	-	-	-	L
16	69	F	34	B	Intramedullary nailing	5	None	33.0	22	60	23
17	93	F	45	B	Intramedullary nailing	-	-	-	-	-	L
18	57	F	14	B	Intramedullary nailing	3	None	20.5	21	85	22
19	56	F	30	B	Intramedullary nailing	-	-	-	-	-	L
20	64	F	21	B	Intramedullary nailing	2	None	0	35	100	25
21	75	M	12	B	Intramedullary nailing	3	None	13.6	26	85	16
22	75	M	38	B	Intramedullary nailing	4	None	11.4	26	90	11
23	82	F	23	B	External fixation	3	None	13.6	24	80	28
24	67	F	19	B	External fixation	-	PE	-	-	-	1
25	84	F	8	B	External fixation	4	None	21.0	24	75	24
26	29	M	15	B	External fixation	4	None	27.3	21	60	33
27	48	F	17	B	Plate and screws	4	None	4.5	31	100	17
28	30	M	32	B	Plate and screws	2	None	0	35	100	14
29	21	M	19	B	Plate and screws	2	Radial palsy (pre- and postoperative)	31.9	22	60	16
30	46	M	20	C	Plate and screws	X	Radial palsy (pre- and postoperative) pseudoarthrosis	40.9	15	50	17
31	67	M	26	Proximal Hum + Distal Hum	External fixation + Plate and screws	3	None	40.9	16	40	14

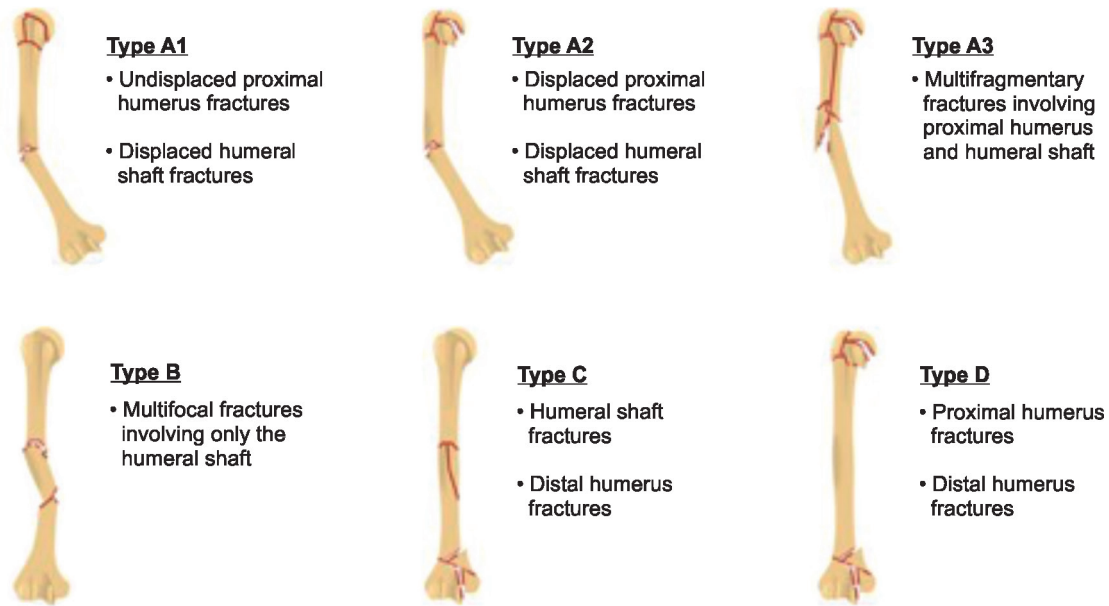


Fig. 3: Our modified Maresca–Pascarella classification for multifocal humeral fractures, with the addition of a Type D

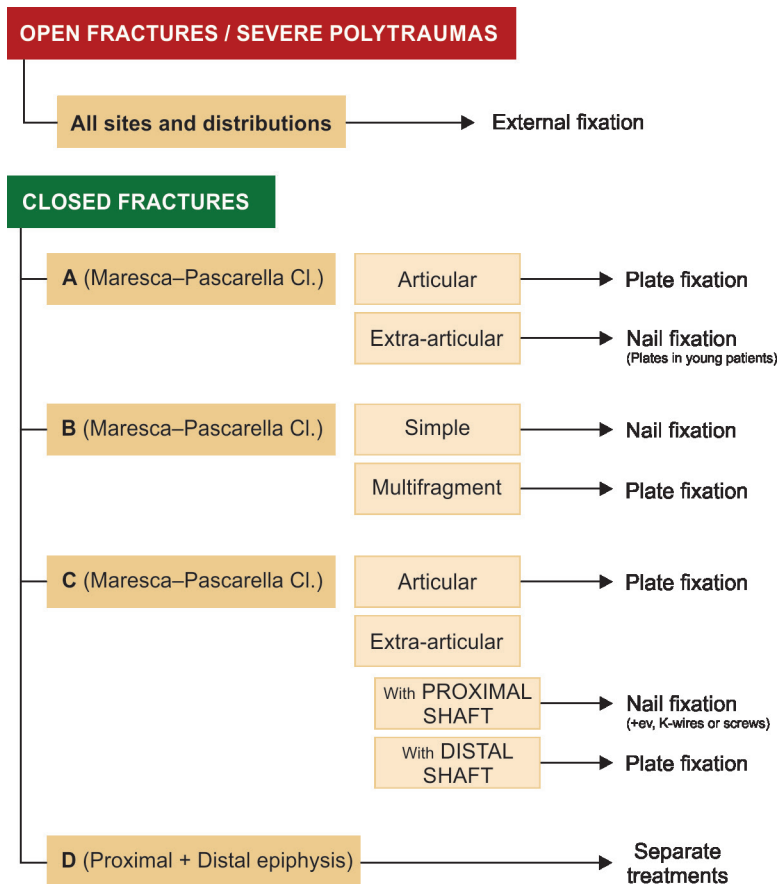


Fig. 4: Our flowchart for surgical treatment of multifocal humeral fractures

is that suggested surgical approaches to each fracture type was not made. This study has identified that the classification proposed can be usefully expanded (Fig. 3) and we introduce a flowchart of suggested treatment to the various types (Fig. 4).

Type A multifocal fractures include the proximal and the humeral shaft. In both Maresca’s and Zambrosky’s reports, these are the most common fracture type although in this series were less common than Type B (38.7%). Maresca and Pascarella used plate



internal fixation for all closed Type A multifocal fractures. Plate internal fixation provides good fracture stabilization and allows preservation of the rotator cuff. Conversely, a wide exposure of the fracture area may increase adding to the soft tissue damage, risk of infection and wound problems. Fixation with an intramedullary nail is an attractive alternative due to minimal access incisions required for the implantation. Yin et al.<sup>19</sup> and Dai et al.<sup>20</sup> described both nail and plate fixation as reliable for humeral fractures but showed a higher incidence of radial nerve palsy in patients treated with plates and greater subacromial impingement for those who underwent nail fixation. In our sample, none of our patients developed impingement syndrome there was no correlation between surgical fixation and nerve damage. In light of these considerations, we suggest selecting different surgical approaches depending on the fracture location and the patients' functional demands. Internal fixation with plates and screws are preferred in articular Type A fractures and non-articular Type A fractures in patients with high functional demands whereas intramedullary nailing may be chosen for low demand elderly individuals with extra-articular Type A fractures. The study sample had with good functional outcomes from QuickDASH, UCLA and MEPS mean scores with either the use of plates or nails. In case of comminuted fractures of the humeral head, which would deter both internal and external fixation, prosthetic replacement of the proximal humerus with endoprosthetic implants or reverse shoulder arthroplasty should be taken into consideration.

Type B multifocal fractures involve humeral shaft alone. Resulting from high energy trauma, these fractures were the most frequent subclass in this study. Fixation with intramedullary nails provide good surgical and functional outcomes in patients with transversal, oblique or spiral fractures and we suggest this as first line treatment. Multifragmentary fractures of the humeral shaft may get better fixation from plates and screws as evidenced by several reports in the literature.<sup>21–24</sup>

Type C multifocal fractures involve both humeral diaphysis and distal epiphysis. We recommend different surgical approaches based on fracture location. As with Type A fractures, fixation with plates and screws should be used to treat articular fractures, extending the same technique to those extra-articular fractures that involve metaphysis and the distal segment of humeral shaft. Following the same criteria used for Types B and C extra-articular fractures located in the proximal segment of the humeral shaft could benefit more from treatment with intramedullary nail and (if necessary) K-wires or screws to supplement the distal fixation.

One patient presented a combination of proximal and distal humeral fractures that did not fit into the categories proposed by Maresca and Pascarella. For this reason, we suggest the introduction of a new Type D multifocal humeral fracture to the classification (Fig. 3). In view of the distance between the two fracture sites, surgery was performed of the proximal and distal fractures with different fixation strategies. The patient was a 67-year-old man with polytrauma and was treated with external fixation for the proximal fracture and plate fixation for the distal. Union was accomplished at both sites at 3 months.

The most frequently documented complication in our study was radial nerve damage which affected 11.5% of all our patients. This percentage is similar to that previously described by Shao et al.<sup>25</sup> for humeral shaft fractures, although higher than reported by Maresca and Pascarella, who had only 1 patient (2.8%) or by Zambrosky et al. who had none.

This study provides a heterogeneous overview of surgical treatments and functional outcomes for multifocal humeral fractures. It has a major limitation in the small number of patients treated, attributable to the low incidence of multifocal humeral fractures. Another limitation is represented by the retrospective nature of the study which led to the loss of five patients during the FU.

## CONCLUSION

Multifocal (segmental) humeral fractures represent uncommon and serious injuries. Only a few studies are available in literature. The AO fracture classification system does not subdivide these fractures. The Maresca and Pascarella classification overcomes this limitation. This study shows that expansion of the Maresca and Pascarella classification is appropriate owing to a previously unrecognised fracture pattern. There is a lack of consensus to treatment currently. A flowchart has been proposed to guide surgeons in the treatment of multifocal humeral fractures with the aim to standardise surgical treatment with due consideration to the fracture location and characteristics as well as the anticipated functional demands of the patient.

## ORCID

Edoardo Ipponi  <https://orcid.org/0000-0003-2107-6357>

Michele Giuntoli  <https://orcid.org/0000-0001-7752-7706>

## REFERENCES

- Bergdahl C, Ekholm C, Wennergren D, et al. Epidemiology and patho-anatomical pattern of 2,011 humeral fractures: data from the Swedish Fracture Register. *BMC Musculoskelet Disord* 2016;17:159. DOI: 10.1186/s12891-016-1009-8.
- Kim SH, Szabo RM, Marder RA. Epidemiology of humerus fractures in the United States: nationwide emergency department sample, 2008. *Arthritis Care Res (Hoboken)* 2012;64(3):407–414. DOI: 10.1002/acr.21563.
- Piirtola M, Vahlberg T, Lopponen M, et al. Fractures as predictors of excess mortality in the aged: a population-based study with a 12-year follow-up. *Eur J Epidemiol* 2008;23(11):747–755. DOI: 10.1007/s10654-008-9289-4.
- Johnell O, Kanis JA, Oden A, et al. Mortality after osteoporotic fractures. *Osteoporos Int* 2004;15(1):38–42. DOI: 10.1007/s00198-003-1490-4.
- Olsson C, Nordquist A, Petersson CJ. Long-term outcome of a proximal humerus fracture predicted after 1 year: a 13-year prospective population-based follow-up study of 47 patients. *Acta Orthop* 2005;76(3):397–402. PMID: 16156469.
- Murray IR, Amin AK, White TO, et al. Proximal humeral fractures: current concepts in classification, treatment and outcomes. *J Bone Joint Surg Br* 2011;93(1):1–11. DOI: 10.1302/0301-620X.93B1.25702.
- Robinson CM, Hill RM, Jacobs N, et al. Adult distal humeral metaphyseal fractures: epidemiology and results of treatment. *J Orthop Trauma* 2003;17(1):38–47. DOI: 10.1097/00005131-200301000-00006.
- Bhandari M, Devereaux PJ, McKee MD, et al. Compression plating versus intramedullary nailing of humeral shaft fractures: a meta-analysis. *Acta Orthop* 2006;77(2):279–284. DOI: 10.1080/17453670610046037.
- Brorson S, Rasmussen JV, Frich LH, et al. Benefits and harms of locking plate osteosynthesis in intraarticular (OTA Type C) fractures of the proximal humerus: a systematic review. *Injury* 2012;43(7):999–1005. DOI: 10.1016/j.injury.2011.08.025.
- Chapman JR, Henley MB, Agel J, et al. Randomized prospective study of humeral shaft fracture fixation: intramedullary nails versus

- plates. *J Orthop Trauma* 2000;14:162–166. DOI: 10.1097/00005131-200003000-00002.
11. Hardeman F, Bollars P, Donnelly M, et al. Predictive factors for functional outcome and failure in angular stable osteosynthesis of the proximal humerus. *Injury* 2012;43(2):153–158. DOI: 10.1016/j.injury.2011.04.003.
  12. Jupiter JB. Managing fractures of the humeral shaft and distal humerus. *J Musculoskelet Med* 1994;11:35–44. DOI: 10.3928/0147-7447-19920701-07.
  13. Mast JW, Spiegel PG, Harvey JP, et al. Fractures of the humeral shaft: a retrospective study of 240 adult fractures. *Clin Orthop Relat Res* 1975;112(1):254–262. DOI: 10.1097/00003086-197510000-00033.
  14. Neer 2nd CS. Four-segment classification of proximal humeral fractures: purpose and reliable use. *J Shoulder Elbow Surg* 2002;11(4):389–400. DOI: 10.1067/mse.2002.124346.
  15. Maresca A, Pascarella R, Bettuzzi C, et al. Multifocal humeral fractures. *Injury* 2014;45(2):444–447. DOI: 10.1016/j.injury.2013.10.010.
  16. Yim GH, Hardwicke JT. The Evolution and interpretation of the Gustilo and Anderson classification. *J Bone Joint Surg Am* 2018;100(24):e152. DOI: 10.2106/JBJS.18.00342.
  17. Broadbent MR, Quaba O, Hadjucka C, et al. The epidemiology of multifocal upper limb fractures. *Scand J Surg* 2003;92(3):220–223. DOI: 10.1177/145749690309200310.
  18. Zamborsky R, Chandoga I, Barinka J, et al. Viacetážové Zlomeniny Humeru (Multifocal humeral fractures.). *Zborník Vedeckých Prác Lfuk-Od Anatómie Po Kliniku - Od Vesalia Po Súčasnosc'. Vydavateľstvo PROPRINT. Bratislava. 2014. ISBN: 978-80-89747-04-7.*
  19. Yin P, Mao Z, Zhang L, et al. Effectiveness comparison between locking compression plate fixation and locked intramedullary nail fixation for humeral shaft fracture of types B and C. *Zhongguo Xiu Fu Chong Jian Wai Ke Za Zhi* 2013;27(12):1457–1461. PMID: 24640365.
  20. Dai J, Chai Y, Wang C, et al. Dynamic compression plating *versus* locked intramedullary nailing for humeral shaft fractures: a meta-analysis of RCTs and nonrandomized studies. *J Orthop Sci* 2014;19(2):282–291. DOI: 10.1007/s00776-013-0497-8.
  21. Carroll EA, Schweppe M, Langfitt M, et al. Management of humeral shaft fractures. *J Am Acad Orthop Surg* 2012;20(7):423–433. DOI: 10.5435/JAAOS-20-07-423.
  22. Changulani M, Jain UK, Keswani T. Comparison of the use of the humerus intramedullary nail and dynamic compression plate for the management of diaphyseal fractures of the humerus: a randomised controlled study. *Int Orthop* 2007;31(3):391–395. DOI: 10.1007/s00264-006-0200-1.
  23. Singiseti K, Ambedkar M. Nailing *versus* plating in humerus shaft fractures: a prospective comparative study. *Int Orthop* 2010;34(4):571–576. DOI: 10.1007/s00264-009-0813-2.
  24. Marsh JL, Mahoney CR, Steinbronn D. External fixation of open humerus fractures. *Iowa Orthop J* 1999;19:35–42. PMID: 11888611.
  25. Shao YC, Harwood P, Grotz MR, et al. Radial nerve palsy associated with fractures of the shaft of the humerus: a systematic review. *J Bone Joint Surg Br* 2005;87(12):1647–1652. DOI: 10.1302/0301-620X.87B12.16132.