

# A new technique for lipid core plaque detection by optical coherence tomography for prevention of peri-procedural myocardial infarction

## A case report

Yongcheol Kim, MD<sup>a,\*</sup>, Muthukaruppan Gnanadesigan, PhD<sup>b</sup>, Gijs van Soest, PhD<sup>b</sup>, Thomas W. Johnson, BSc, MBBS, MD<sup>a</sup>

### Abstract

**Rationale:** Percutaneous coronary intervention (PCI) provides effective revascularization of atherosclerotic coronary arteries but the invasive nature of treatment can result in complications.

**Patient concerns:** A 53-year old man underwent coronary angiography due to chest pain with minimal ST-segment elevation in the inferior leads of the electrocardiogram.

**Diagnosis:** We proceeded directly to coronary angiography and delineated a moderate stenosis with haziness in the mid right coronary artery (RCA).

**Interventions:** Expert analysis of the pre-intervention OCT imaging demonstrated a large lipid core plaque (LCP), upstream of the culprit site, with minimal thrombus burden. Subsequent implantation of a bioresorbable vascular scaffold, protected with distal deployment of a filter protection device provided an excellent result with retrieval of plaque material. Post-hoc attenuation analysis confirmed the presence of large LCP.

**Outcomes:** A post-procedural transthoracic echocardiogram confirmed good left ventricular function with no regional wall motion abnormality. An excellent clinical outcome was achieved.

**Lessons:** Optical coherence tomography (OCT) derived attenuation analysis can provide with qualitative and quantitative detailed evaluation of the underlying plaque substrate. Our case shows OCT can provide the interventionist with qualitative and quantitative assessment of large LCP for prevention of periprocedural complications, which may improve outcome for PCI.

**Abbreviations:** BVS = bioresorbable vascular scaffold, LCBI = lipid core burden index, LCP = lipid core plaque, MI = myocardial infarction, NIRS = near-infrared spectroscopy, OCT = optical coherence tomography, PCI = percutaneous coronary intervention, RCA = right coronary artery.

**Keywords:** Attenuation analysis, Lipid core plaque, Optical coherence tomography, Peri-procedural myocardial infarction

## 1. Introduction

Intravascular imaging offers potential in the planning and optimization of percutaneous coronary intervention (PCI); however, image interpretation is challenging.<sup>[1,2]</sup> We report a

new technique that simplifies interpretation and provides the interventionist with a detailed evaluation of the underlying plaque substrate. Although anecdotal, our case promotes consideration of a concept of “personalized” intervention to avoid periprocedural complication and improve outcomes for PCI.

Editor: Jacek Bil.

Conflicts of interest: Erasmus MC has a patent licensing agreement with Terumo Corporation in the area of OCT imaging. Dr Van Soest has the right to receive royalties as part of this agreement. Dr Johnson has received speaker and consultancy fees from St Jude Medical and Terumo Corporation. The other authors report no relationships that could be construed as a conflict of interest. Supplemental Digital Content is available for this article.

<sup>a</sup> Bristol Heart Institute, Bristol, UK, <sup>b</sup> Department of Biomedical Engineering, Thoraxcenter, Erasmus University Medical Center, Rotterdam, the Netherlands.

\* Correspondence: Yongcheol Kim, Bristol Heart Institute, Upper Maudlin Street, Bristol BS2 8HW, UK (e-mail: Dr.YongcheolKim@gmail.com).

Copyright © 2017 the Author(s). Published by Wolters Kluwer Health, Inc. This is an open access article distributed under the terms of the Creative Commons Attribution-Non Commercial License 4.0 (CCBY-NC), where it is permissible to download, share, remix, transform, and buildup the work provided it is properly cited. The work cannot be used commercially without permission from the journal.

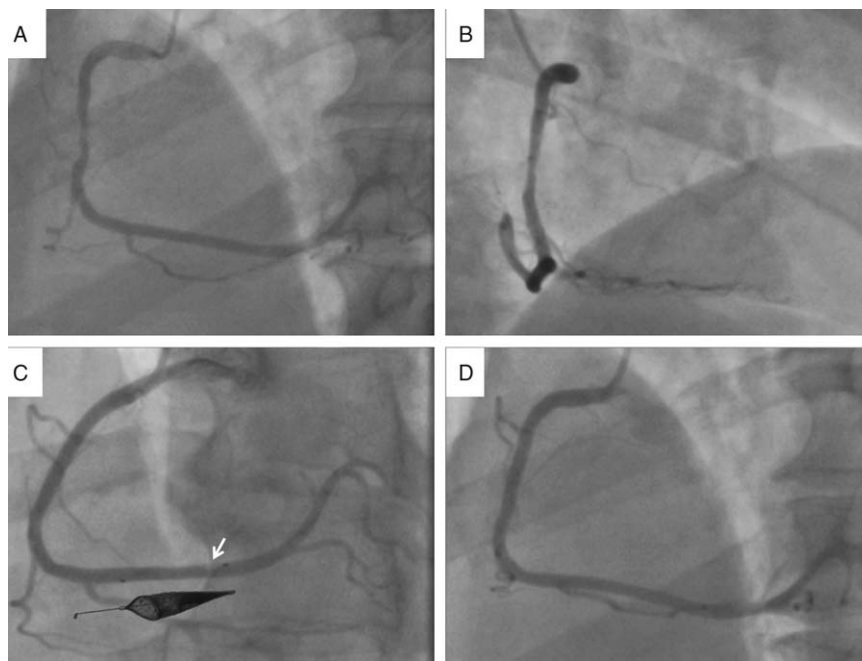
Medicine (2017) 96:23(e7125)

Received: 10 April 2017 / Received in final form: 11 May 2017 / Accepted: 15 May 2017

<http://dx.doi.org/10.1097/MD.0000000000007125>

## 2. Case presentation

A 53-year-old man presented to our department with a 12-hour history of intermittent angina. His admission electrocardiogram demonstrated minimal ST-segment elevation in the inferior leads and a high sensitivity troponin measurement was elevated. We proceeded directly to coronary angiography and delineated a moderate stenosis with haziness in the mid right coronary artery (RCA) (Fig. 1A and B). The nonflow-limiting nature of the lesion and the consideration of using a bioresorbable vascular scaffold (BVS) led to assessment with optical coherence tomography (OCT). The OCT was very instructive, demonstrating a minimal lumen area of 2.5 mm<sup>2</sup>, plaque rupture with associated luminal thrombus and a highly attenuating plaque, representing lipid core plaque (LCP), upstream of the culprit site (Fig. 2, A, B1, and C1). Detection of the large lipid core plaque at the site of planned intervention led to use of a filter-based distal protection device (SpiderFX, Ev3, Plymouth, MN) to minimize risk of distal embolization. Predilation was undertaken with a 2.5 × 20 mm



**Figure 1.** (A and B) Angiographic assessment demonstrating a moderate stenosis, nonflow-limiting nature of the lesion, with haziness in the mid right coronary artery. (C) Poststent angiogram demonstrating filling defect within the distal protection device (arrow) (inset: macroscopic evidence of material in filter device). (D) Final angiogram demonstrating good distal flow without residual stenosis.

compliant balloon (Emerge, Boston Scientific, Natick, MA) at 14 atmosphere, and a  $3.5 \times 28$  mm BVS (ABSORB, Abbott Vascular, Santa Clara, CA) was implanted in the mid-RCA. Postdilation was achieved with a  $3.5 \times 20$  mm noncompliant balloon, and repeated OCT assessment demonstrated excellent stent expansion and good strut apposition with no edge disruption. Angiographic assessment of the filter device suggested capture of material, confirmed by evidence of macroscopic plaque on retrieval of the distal protection device (Fig. 1C) and final angiogram demonstrated good distal flow without residual stenosis (Fig. 1D). A postprocedural transthoracic echocardiogram confirmed good left ventricular function with no regional wall motion abnormality. An excellent clinical outcome was achieved.

The patient written informed consent was waived due to the retrospective nature of the presented case. Patient information was anonymized and deidentified.

### 3. Discussion

Percutaneous coronary intervention provides effective revascularization of atherosclerotic coronary arteries, but the invasive nature of treatment can result in complications. Periprocedural myocardial infarction (MI), associated with short and long-term adverse outcomes, has been reported in as many as 30%.<sup>[3,4]</sup> This complication presumably related to distal embolization of the thrombotic and large lipid core burdens of acute plaque lesion.<sup>[5,6]</sup> Consequently, methods of predicting distal embolization and strategies to minimize periprocedural MI would be advantageous.

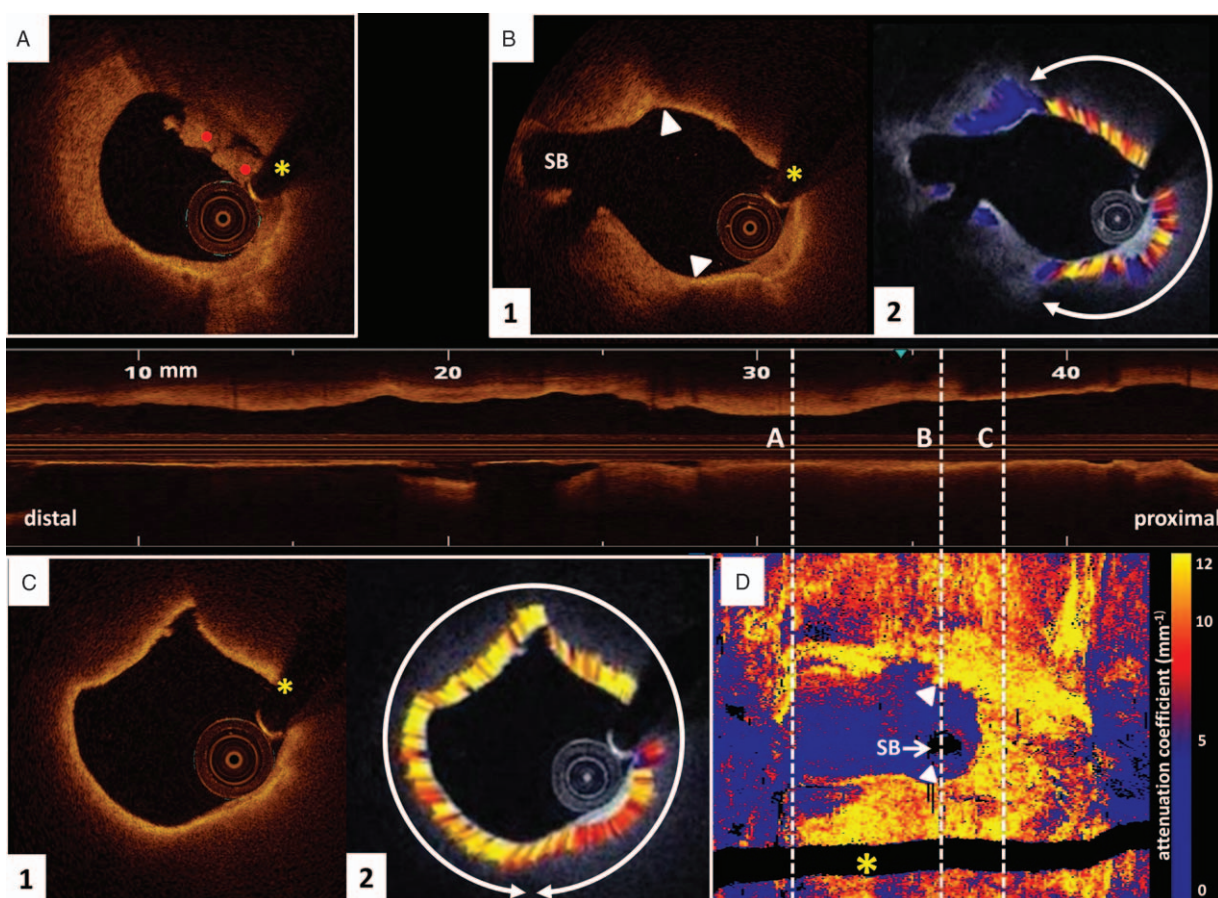
Optical coherence tomography provides high-resolution ( $10 \mu\text{m}$ ) assessment of the coronary vasculature and allows characterization of tissue components of atherosclerotic plaques by qualitative interpretation.<sup>[7]</sup> However, OCT interpretation can be challenging,<sup>[1,2]</sup> and consequently methods to automate and quantify plaque characteristics are being developed. Different tissue types generate specific OCT signals through variations in their scatter and

attenuation of light, especially OCT-derived attenuation can be quantified and thereby assist in differentiating tissue components.<sup>[8]</sup> Ex vivo validation experiments have confirmed OCT-derived attenuation analysis as a potentially useful method for quantitative tissue characterization, in which highly attenuating regions (attenuation coefficient  $\mu_t \geq 11/\text{mm}$ ) relate to necrotic core or macrophage infiltration.<sup>[9]</sup> The attenuation calculation and the OCT image analysis were done in MATLAB R2012b (The Mathworks, Inc., Natick, MA), which generates an attenuation image for every OCT frame (see supplement video 1, <http://links.lww.com/MD/B733>). OCT-derived attenuation can be also visualized using a “carpet-view” vessel map, analogous to the near-infrared spectroscopy (NIRS) chemogram (Fig. 1D). Similar to lipid core burden index (LCBI), an index of plaque attenuation can be derived to facilitate quantification of necrotic core/lipid burden 4 mm sections of the plaque, and this measure has been confirmed as an accurate in vivo method of detecting thin-cap fibroatheroma with higher discriminating ability than NIRS-derived LCBI.<sup>[10]</sup>

Post hoc analysis of our preintervention OCT confirmed the large lipid rich nature of the plaque burden upstream of the culprit rupture site and minimal associated thrombus (Fig. 1, B2 and C2; see supplement video 1, <http://links.lww.com/MD/B733>). Image interpretation extended the length of scaffold deployed and led to the use of a distal protection device to minimize embolization of plaque material. Despite the high resolution of OCT images, clinical interpretation of tissue characteristics remains challenging and mechanisms of automatic detection would maximize the use of the technology.

### 4. Conclusions

Periprocedural complications and late stent failure continue to thwart interventional cardiologists and their patients. This case highlights the potential that intravascular imaging offers in providing personalized care, with interventional strategies



**Figure 2.** (A) Optical coherence tomography (OCT) assessment demonstrating minimal luminal area of 2.5 mm<sup>2</sup> with intraluminal thrombus (red points). (B1) OCT cross-section at the level of a small side branch demonstrating noncircumferential LCP (arrow heads delineate margins of the lipid core); (B2) post hoc analysis confirming the lipid rich nature of the plaque (between arrow both ways). (C1) Signal-poor and poorly delineated region, representing circumferential LCP; (C2) post hoc attenuation analysis demonstrating circumferential LCP (between arrow both ways). (D) A "carpet-view" attenuation vessel map demonstrating the large burden of LCP. Asterisk indicates wire artefact. LCP=lipid core plaque, OCT=optical coherence tomography, SB=side branch.

dictated by the interpretation of pretreated vessel characteristics and optimization of the freshly deployed stent. However, evidence of effect is needed and trials to demonstrate the superiority of image-guided intervention continue.

## References

- [1] van Soest G, Regar E, Goderie TP, et al. Pitfalls in plaque characterization by OCT: image artifacts in native coronary arteries. *JACC Cardiovasc Imaging* 2011;4:810–3.
- [2] Manfrini O, Mont E, Leone O, et al. Sources of error and interpretation of plaque morphology by optical coherence tomography. *Am J Cardiol* 2006;98:156–9.
- [3] Herrmann J. Peri-procedural myocardial injury: 2005 update. *Eur Heart J* 2005;26:2493–519.
- [4] Porto I, Selvanayagam JB, Van Gaal WJ, et al. Plaque volume and occurrence and location of periprocedural myocardial necrosis after percutaneous coronary intervention: Insights from delayed-enhancement magnetic resonance imaging, thrombolysis in myocardial infarction myocardial perfusion grade analysis, and intravascular ultrasound. *Circulation* 2006;114:662–9.
- [5] Prasad A, Herrmann J. Myocardial infarction due to percutaneous coronary intervention. *N Engl J Med* 2011;364:453–64.
- [6] Rezkalla SH, Kloner RA. Coronary no-reflow phenomenon: from the experimental laboratory to the cardiac catheterization laboratory. *Catheter Cardiovasc Interv* 2008;72:950–7.
- [7] Tearney GJ, Regar E, Akasaka T, et al. Consensus standards for acquisition, measurement, and reporting of intravascular optical coherence tomography studies: a report from the international working group for intravascular optical coherence tomography standardization and validation. *J Am Coll Cardiol* 2012;59:1058–72.
- [8] Xu C, Schmitt JM, Carlier SG, et al. Characterization of atherosclerosis plaques by measuring both backscattering and attenuation coefficients in optical coherence tomography. *J Biomed Opt* 2008;13:034003.
- [9] van Soest G, Goderie T, Regar E, et al. Atherosclerotic tissue characterization in vivo by optical coherence tomography attenuation imaging. *J Biomed Opt* 2010;15:011105.
- [10] Gnanadesigan M, Kameyama T, Karanasos A, et al. Automated characterisation of lipid core plaques in vivo by quantitative optical coherence tomography tissue type imaging. *EuroIntervention* 2016;12:1490–7.