

Zygomatic complex fracture: A comparative evaluation of stability using titanium and bio-resorbable plates as one point fixation

Department of Dentistry, Hind Institute of Medical Sciences, Barabanki, Lucknow, *Department of Oral and Maxillofacial Surgery, Santosh Dental College, Ghaziabad, ²Departments of Plastic Surgery and ³Anesthesiology, King Georges Medical University, Lucknow, Uttar Pradesh, India

Nalini Tripathi, Manoj Goyal¹, Brijesh Mishra², Satish Dhasmana³

ABSTRACT

Background: The malar bone represents a strong bone on fragile support and its processes - frontal, orbital, maxillary and zygomatic are frequently the site of fracture. Current study was done to compare the stability of zygomatic complex fracture using Biodegradable plates and titanium miniplates with one point fixation. **Materials and Methods:** Twenty patients of zygomatic complex fracture were randomly selected and divided in two groups which were further divided into two subgroups (A, B). Group I patients were treated with titanium miniplate at zygomatic buttress and Group II was treated by bio-resorbable plates. One point fixation was done either at zygomatic buttress or at frontozygomatic suture and it was observed that both the site have been the most favored site of rigid internal fixation in terms of stability, aesthetics and prevention of rotation of the fracture segment in either vertical or horizontal axis. **Conclusion:** There is no significant difference in post operative outcomes between two groups, but still bioresorbable system has some advantage over titanium system as these plates resorbs over a period of time and does not cause any interference with growth and post operative radiotherapy. However application of biodegradable system demands highly précised technique.

Address for correspondence:
Dr. Brijesh Mishra,
MM 4/88, Vinay Khand,
Gomti Nagar, Lucknow - 226 010,
Uttar Pradesh, India.
E-mail: drbrijeshmishra@gmail.com

Key words: Bioresorbabale plates, titanium plates, zygomatic complex fracture

INTRODUCTION

Facial bones are one of the most important and complex portion of skeletal anatomy. Injuries to them result in devastating emotional as well as functional disturbances. The malar bone represents a strong bone on fragile support, and it is for this reason that though the body of the bone is rarely broken, the four processes-Frontal,

orbital, maxillary, and zygomatic are frequently the site of fracture.

The zygomaticotemporal articulation is very thin and delicate connection that fracture frequently with minimal forces. For unstable, displaced fractures of the zygoma, miniplates were found to efficiently stabilize the bones with minimal complications. Titanium miniplates may have disadvantages as the possibility of bone atrophy due to stress-shielding and the obligation to remove these devices in the second operation.

An area of ongoing research is the use of biodegradable plate system for fixation of facial fractures. The main advantage of the biodegradable plates and screws is that they lose their mechanical properties due to

Access this article online	
Quick Response Code: 	Website: www.njms.in
	DOI: 10.4103/0975-5950.127648

degradation, so that masticatory loads are gradually retransferred to the bone preventing stress-shielding of the healed bone. These plates cause less interference with craniofacial growth in children and with postoperative radiotherapy.

Current study was done to compare the stability of zygomatic complex fracture using biodegradable plates and titanium miniplates with one point fixation in the management of zygomatic complex fractures.

MATERIALS AND METHODS

Twenty patient shaving fracture of zygomatic complex involving either frontozygomatic suture or zygomatic buttress region were included in this study and were selected among the patients who reported to the casualty/ outpatient Department of Oral and Maxillofacial Surgery, Santosh Medical Dental College and Hospitals, Ghaziabad. Age of all patients ranged from 17 to 50 years.

Diagnosis of the zygomatic complex fracture was made on the basis of detailed history, clinical examination [Figure 1], and radiological examination [Figure 2] [Digital PNS View, Digital SMV view and computed tomography scan].

Patients with gross comminuted fracture of the face, blood dyscrasia, immunocompromised patients, psychologic or psychiatric conditions that could influence a subject's reaction to treatment were excluded from the study.

These patients were divided in two groups of 10 each, In Group I, 1.7 mm Titanium Miniplates were used for fixation. In Group II, 1.5 mm Inion Biodegradable plates were used for fixation. Both groups were divided into two subgroups of five patients each, in subgroup I/II

A fixation was done at the zygomatic buttress and in subgroup I/II B fixation was done at the frontozygomatic suture.

Results were evaluated for clinical and radiographic findings on the 1st day postoperative, 3 months postoperative, and 6 months postoperative. Parameters evaluated were as follows:

1. Enophthalmos.
2. Diplopia.
3. Swelling.
4. Vision, pupillary reaction.
5. Malocclusion.
6. Paresthesia.
7. Infection at surgical site.
8. Need for removal of plate.
9. Biting efficiency.
10. Facial asymmetry.

Radiographic assessment using digital paranasal sinus view/CT scan/three-dimensional CT scan after surgery to evaluate reduction or any malunion.

OPERATIVE PROCEDURE

Procedure was explained and Informed consent was taken for every patient included in the study.

All the patients were operated under general anesthesia (nasotracheal intubation) along with 2% lignocaine hydrochloride with 1:2,00,000 concentration of epinephrine for local infiltration at surgical site to achieve blood less field.

The fracture sites were exposed in both the groups by giving upper buccal incision and the mucoperiosteal flap was raised for the exposure of zygomatic buttress in subgroups IA and IIA.

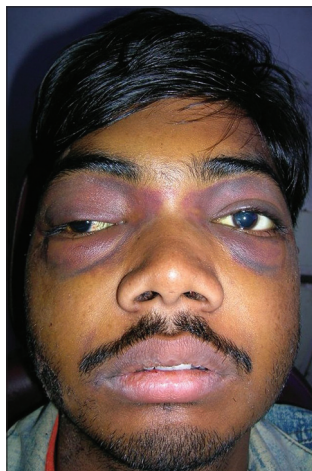

Figure 1: Pre operative photograph of bilateral fracture of zygomatic complex

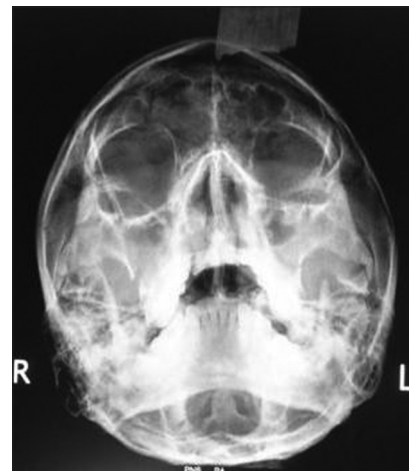

Figure 2: Bilateral zygomatic complex fracture pre operative PNS view

For subgroups IB and IIB, lateral eyebrow incision was given and the mucoperiosteal flap was raised to expose the frontozygomatic suture.

Reduction was done using Taylor Monk Elevator through the upper buccal sulcus approach in 18 cases. In two cases, reduction was done through the Gillies temporal approach using Bristows elevator. The occlusion was achieved and temporary intermaxillary fixation was done [Figure 3].

In group I

In group IA, five patients were treated with four hole L shape 1.7 mm titanium plates at the zygomatic buttress.

In group IB, five patients were treated with four hole with or without gap 1.7 mm plates at the frontozygomatic sutures.

In group II

Group II patients were treated by 1.5 mm biodegradable plates. After reduction of the fracture site, the biodegradable plates were dipped in the hot water bath of 55°C for 1-2 min [Figure 4]. The plates became soft so now they could be easily adapted to the contour of the bone. The holes were drilled with 1.5 mm drill bit followed by flushing of the hole, then the hole were tapped with the bone tap again followed by flushing and then the monocortical screws were placed with the help of screw driver. Copious flushing was done to avoid screw breakage.

In group IIA, the plates were placed on the zygomatic buttress and in group II B, the plates were placed on the frontozygomatic suture. Finally, the temporary intermaxillary fixation was opened.

In all the cases, closure of wound was done by 3-0 vicryl sutures intraorally and 3-0 ethicon suture extraorally to close lateral eyebrow incision after proper irrigation with normal saline and 5% betadine (povidone-iodine).

All the patients were kept under antibiotic cover, that is, third generation cephalosporins preoperatively and continued postoperatively for 5 days, with only four doses of metronidazole postoperatively.

All the patients were advised to apply ice pack extra orally to reduce swelling. No postoperative maxillomandibular fixation was used and the patients were immediately placed on a liquid diet for the first 2 days postoperatively; semisolid diet was started on 3rd day and normal diet thereafter. The skin sutures were removed on the 7th postoperative day. In all patients, follow-up was done at immediate postoperative, at interval of 3 months postoperative and 6 months postoperative [Figures 5 and 6].

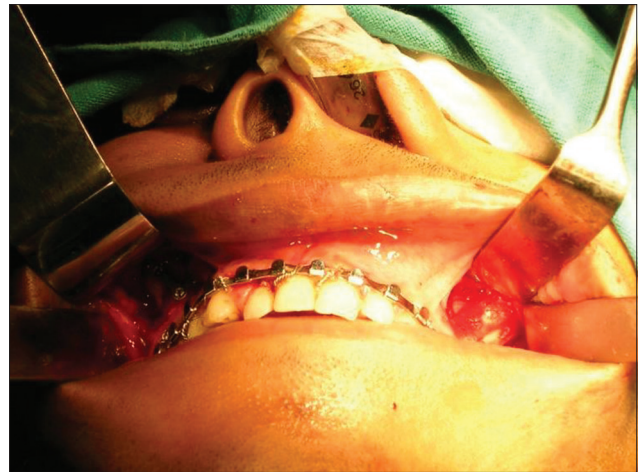

Figure 3: Fixation of fractures by titanium plate on right side and bioresorbable on left side

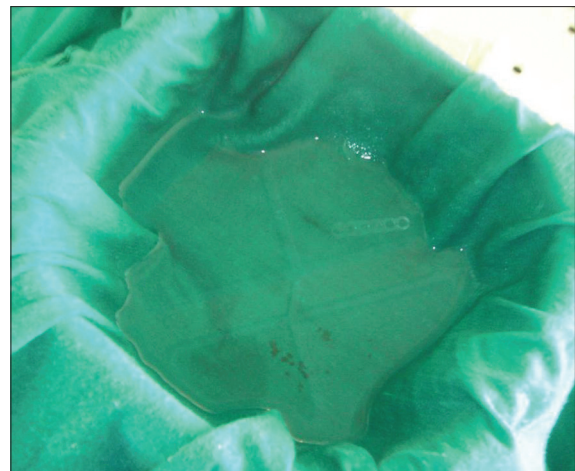


Figure 4: Hot water bath with 1.5 mm bioresorbable plate

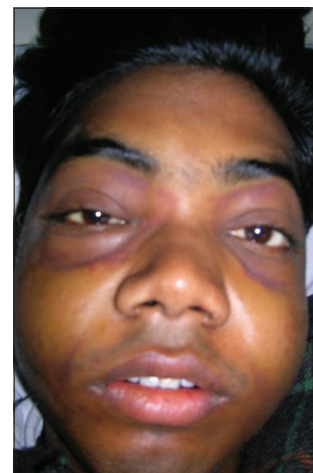

Figure 5: Immediate post operative photographs

OBSERVATION AND RESULTS

All the patients in this study were in age group of 17-50 years. About 35% of the patients belonged to third

decade of life followed by 30% in the fourth decade, 20% in the fifth decade and 15% in the second decade.

The maximum patients in this study were male 85%, while females were 15%. Male:female ratio was 5.67:1.

Road traffic accident was the leading cause of the injury, it was 55% followed by assault which was 35% and fall from the height was seen in only 10% of the cases. A total of 60% of the patient had injury on the left side and 40% had injury on the right side.

Table 1 shows the diagnostic clinical features like pain, swelling, epistaxis, circumorbital ecchymosis, subconjunctival hemorrhage, facial asymmetry like flattening of the cheeks were seen in all the patients. Also, deranged occlusion was seen in 30% of the patients, diplopia and enophthalmos was seen in 20% of the patients.

Table 2 shows the time lag between the injury and the surgery. The maximum time between trauma and surgery was of 11 days which was only in 5% of the cases and the minimum time lag was of 2 days which was seen in 10% of the cases. About 45% of the cases had a time interval of 4 days in our study.

Table 3 shows the postoperative complication encountered in group I - Swelling was seen in all the patients on the first postoperative day. Diplopia was seen in 5% of the patients for 3 months in subgroup A. Palpability was also seen in 5% of the case in subgroup B for 6 months. On the contrary, enophthalmos, paresthesia, screw breakage, plate exposure, infection at the site, malocclusion, and thermal sensitivity were not seen postoperatively and the biting efficiency of all the patients were normal postoperatively.

Table 4 show the postoperative complication encountered in group II - Swelling was seen in all the patients on the

first postoperative day. Diplopia was seen in 10% of the patients, screw breakage was seen in 10% of the patient at the time of surgery, plate exposure and infection at the site was seen in 10% of the cases at 6-month review. On the contrary, enophthalmos, paresthesia, palpability, thermal sensitivity, and malocclusion were not seen in any patients postoperatively. Biting efficiency was found to be normal in all the patients.

DISCUSSION

Our study showed that RTA (55%) outnumbered the other mode of injury followed by assault (35%) and fall from height (10%). These results were very much similar with the results of Ahluwalia *et al.*,^[1] Mehrotra *et al.*,^[2] Chowdhary *et al.*,^[3] and Menon *et al.*^[4]

Most of our patients belonged to third (35%) and fourth (30%) decades of life. This shows that individuals in this decades of life are more active physically. A similar observation was found in the other studies Ahluwalia *et al.*,^[1] Mehrotra *et al.*,^[2] Chowdhary *et al.*,^[3] and Menon *et al.*^[4]

The male:female ratio in our study was 5.67:1 which is very much similar to the observation of above studies.

The injury to the left side of the face showed more predominance in our study, this could be due to

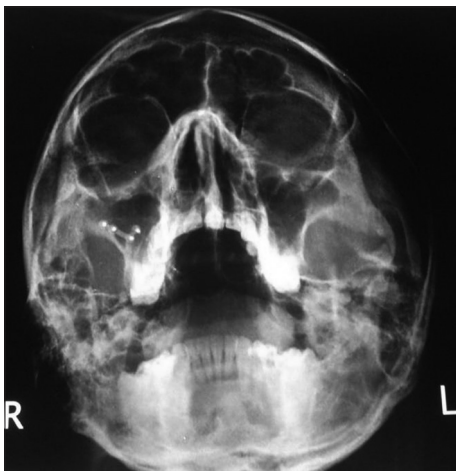

Figure 6: PNS view postoperative

Table 1: Clinical features in patients with zygomatic complex fracture

Features	Group I		Group II		Total	Percentage
	A	B	A	B		
Pain	5	5	5	5	20	100
Swelling	5	5	5	5	20	100
Epistaxis	5	5	5	5	20	100
Circumorbital ecchymosis	5	5	5	5	20	100
Subconjunctival hemorrhage	5	5	5	5	20	100
Deranged occlusion	3	0	2	1	6	30
Facial asymmetry	5	5	5	5	20	100
Diplopia	1	-	2	1	4	20
Enophthalmos	1	1	2	-	4	20
Paresthesia	-	1	1	-	2	10

Table 2: Time interval between trauma and surgery

No. of days	Group I		Group II		Total	Percentage
	A	B	A	B		
1 st	-	-	-	-	-	0
2 nd	-	1	-	1	2	10
3 rd	2	1	-	-	3	15
4 th	1	3	3	2	9	45
5 th	-	-	-	1	1	5
6 th	-	-	-	-	-	0
7 th	-	-	-	-	-	0
8 th	-	-	-	-	-	0
9 th	1	-	1	1	3	15
10 th	-	-	-	-	-	0
11 th	-	-	1	-	1	5
12 th	-	-	-	-	-	0

Table 3: Postoperative complications in group I

Complications	Group I						Total	Percentage
	A			B				
	1 st day	3 rd month	6 th month	1 st day	3 rd month	6 th month		
Swelling (N= 10)	5	-	-	5	-	-	10	100
Diplopia (N=1)	-	1	-	-	-	-	1	10
Enophthalmos (N=0)	-	-	-	-	-	-	0	0
Paresthesia (N=0)	-	-	-	-	-	-	0	0
Screw breakage (N=0)	-	-	-	-	-	-	0	0
Plate exposure (N=0)	-	-	-	-	-	-	0	0
Infection at the site (N=0)	-	-	-	-	-	-	0	0
Palpability (N= 1)	Present	Present	Present	-	-	-	1	10
Malocclusion (N=0)	-	-	-	-	-	-	0	0
Thermal sensitivity (N=0)	-	-	-	-	-	-	0	0
Biting efficiency (N= 10)	0	5	5	0	5	5		

N: Number of patients, Biting efficiency score-5: Not able to chew, 0: On soft diet, 3: On normal diet but can chew only on one side, 5: On normal diet

Table 4: Postoperative complications in group II

Complications	Group II						Total	Percentage
	A			B				
	1 st day	3 rd month	6 th month	1 st day	3 rd month	6 th month		
Swelling (N= 10)	5	-	-	5	-	-	10	100
Diplopia (N=1)	-	1	-	-	-	-	1	10
Enophthalmos (N=0)	-	-	-	-	-	-	0	0
Paresthesia (N=0)	-	-	-	-	-	-	0	0
Screw breakage (N= 1)	1	-	-	-	-	-	1	10
Plate exposure (N=1)	-	-	1	-	-	-	1	10
Infection at the site (N= 1)	-	-	1	-	-	-	1	10
Palpability (N=0)	-	-	-	-	-	-	0	0
Malocclusion (N=0)	-	-	-	-	-	-	0	0
Thermal sensitivity (N=0)	-	-	-	-	-	-	0	0
Biting efficiency (N=0)	0	5	5	0	5	5		

N: Number of patients, Biting efficiency score-5: Not able to chew, 0: On soft diet, 3: On normal diet but can chew only on one side, 5: On normal diet

interpersonal violence as this may be due to the fact that majority of the population is right-handed. Similar results were seen in the studies of Mehrotra *et al.*, Dziadek, *et al.*^[5] but in the studies of Chowdhary *et al.*,^[3] right side was more involved than the left side. Bilateral involvement was seen in two cases in our study.

Diplopia was seen in 10% of the cases, that is one patient in both groups Zachary *et al.*,^[6] Evans and Evans^[7] observed in their study diplopia in 60% of the which were transitory and enophthalmos in 3-4% of patients.

Reduction was done using upper buccal sulcus approach in 80% of the cases and Gillies temporal approach in 20% of the cases. The reason being that the upper buccal sulcus approach has a number of advantages over Gillies approach like no skin scar and more precise application of the force by the operator, placement of bone plate at buttress through the same incision, minimal bleeding, and simple mucosal closure. Similar observation was observed with the study of Courtney^[8] and Ho.^[9]

In our study, only one point fixation was done either at zygomatic buttress or at frontozygomatic suture. We observed that zygomatic buttress was one of the best sites of fixation as it is the direct antagonist to the pull of masseter muscle and the site of fixation was deep and

the plates were rarely felt in this area so the fixation was longer and stronger. Frontozygomatic suture was also a good site for fixation of zygomatic complex fracture as the bone in this area was thick which was ideal for rigid fixation.

Similar observations were noted by Ellis^[10] that in isolated zygomatic complex fracture zygomatic buttress provides great mechanical advantage for stabilization to the fracture segment by application of bone plates and one plate can prevent medial rotation of the zygomatic complex into maxillary sinus.

Praveen and Parmar^[11] observed that the fixation at zygomatic buttress can provide acceptable stability of the zygomatic complex but in highly unstable fracture two or three point of fixation was additionally achieved to fix the fracture at infraorbital and frontozygomaticline.

Davidson *et al.*,^[12] observed that single point fixation of frontozygomatic suture or infraorbital rim using miniplate would appear to be a method of internal fixation that provide acceptable post reduction stability and concluded that stable fixation is achieved by methods that involve the use of at least one miniplate and incorporate the frontozygomatic suture line as one of the point of fixation.

Champy^[13] and Mitchell *et al.*,^[14] concluded that single bone plate in the frontozygomatic suture provides adequate three-dimensional stability of an unstable zygoma.

Oyen *et al.*,^[15] observed that the tensile strains predominates in the frontozygomatic region thus it supports the use of compression plates in osteosynthesis for improved stabilization in this region.

Maski *et al.*,^[16] concluded in their study that one plate fixation of zygomatic complex fracture was significantly rigid when the fracture was not comminuted and three point alignment can be achieved.

Kelly *et al.*,^[17] observed in their study that the best site for fixation is zygomatic buttress as it is the direct antagonist to the pull of masseter muscle and frontozygomatic suture is also ideal for rigid fixation, but the plate in this area is palpable so one should use thin plate.

Wittwer *et al.*,^[18] observed in their study that the optimum location for the placement of biodegradable plate is frontozygomatic suture, as most appropriate anchorage of screws and most suitable fixation is achieved at this site. On the contrary, Parashar *et al.*,^[19] Ho,^[9] Hanemann *et al.*,^[20] observed in their study that three-point fixation group maintained better stability at the fracture site resulting in decreased incidence of dystopia and enophthalmos, they had better malar projection and malar height as measured radiographically, when compared with two-point or one-point fixation group.

The complications that were observed in our study were intraoperative complications and postoperative complications. Intraoperative complication included screw breakage. This was seen in only one case in which the fixation was done at zygomatic buttress with biodegradable plates. This happened during the screw tightening and was seen in the first case which was done with the biodegradable plate which suggested that there is a learning curve with this material. This complication was also seen in the study of Menon *et al.*,^[4] Wittwer *et al.*,^[18] and Bessho *et al.*^[21] On the contrary, there were no intraoperative complication seen with titanium plates.

In our study, postoperative complication included plate exposure and infection at the site after 6 months in one patient in which fixation was done with biodegradable plate at zygomatic buttress [Figure 7]. The plate was not removed rather they were treated conservatively with the antibiotic and the healing occurred. This finding was also seen in the study done by Enislidis *et al.*,^[2] Menon *et al.*,^[11] Wittwer *et al.*,^[8] Bessho *et al.*,^[21] Bergsma *et al.*^[23] They also observed that the plate was exposed and infection at the site of fixation was there in those

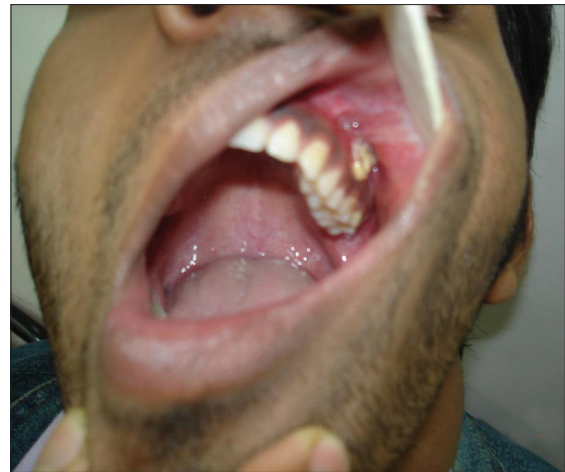

Figure 7: Biodegradable plate exposure after 6 months

patients who were chronic smokers and were treated with biodegradable plate.

In our study, the operating time was longer with the patients who were treated with biodegradable plates which show that there is a learning curve with biodegradable material which is there with any new material. Bergsma *et al.*,^[23] Laine *et al.*,^[24] Bessho *et al.*,^[21] also observed this in their studies.

Plate palpability was seen in one patient who was treated with titanium plate at frontozygomatic suture for 6 months; the reason for this could be that the soft tissue cover in this area was very thin. Matthew *et al.*,^[25] Wittwer *et al.*,^[18] observed in their study that in addition to being palpable and/or visible, metal fixation systems are sensitive to temperature and poses difficulties for imaging techniques.

Diplopia was seen in 5% of the cases for 3 months postoperatively, but 6 months postoperatively there were no signs of diplopia seen in these patients.

Swelling was seen in all the cases on first day postoperatively after which it subsided. Paresthesia was seen in two patients, that is, one patient in each group preoperatively, but no patient reported back with paresthesia postoperatively. Flattening of cheek was seen in all the patients preoperatively, but no patient complaints of facial asymmetry postoperatively.

Malocclusion was seen in six patients (three in each group) preoperatively, but no patient had postoperative malocclusion. Pupillary reflex was reduced for the first postoperative day in two patients but on 3 months review no patient was suffering from decreased pupillary reflex. All the patients were on soft diet on the first postoperative day, but thereafter all the patients were on normal diet and no patient reported

with decreased biting efficiency for the next 6 months follow-up.

The postoperative radiograph showed adequate reduction in all the cases and only holes were seen where the biodegradable plate were placed.

Thus, in our study, we observed that there was uneventful healing of the zygomatic complex fracture in almost all patients and both the systems provided adequate stability.

CONCLUSIONS

Reviewing results from all the aspects and keeping in mind the limitation and variables in this study, it can be concluded that though two-point and three-point fixations provides more stable fixation, but acceptable stability can also be achieved with one-point fixation either at frontozygomatic suture or at zygomatic buttress as was the case in our study.

Also, there is no significant difference in postoperative outcomes between two groups, but still bioresorbable system has some advantage over titanium system as these plates resorb over a period of time and does not cause any interference with growth and postoperative radiotherapy. However, application of biodegradable system demanded a highly precise technique as compared with titanium system.

REFERENCES

- Ahluwalia TP, Jatin K. Changing picture of facial fractures: A retrospective study with special reference to incidence and etiology. *Indian J Oral Maxillofac Surg* 2002;17:2.
- Divya M, Pradhan H. Fractures of zygomatic complex: An evaluation of surgical management. *J Oral Maxillofac Surg* 2003;2:2.
- Roy CS, Menon S. Etiology and management of zygomaticomaxillary complex fractures in armed forces. *MJAFI* 2005;61:3.
- Menon S, Chowdhary SK. Evaluation of bioresorbable vis-à-vis titanium plates and screws for craniofacial fractures and osteotomies. *MJAFI* 2007;6:331-3.
- Dziadek H, Ciešlik T. Causes and effects of zygomatico orbital and zygomatico-maxillo-orbital fractures managed by open reduction and rigid internal fixation. *Ann Univ Mariae Curie Skłodowska Med* 2004;59:44-51.
- Zachary S. Facial trauma, zygomatic complex fractures; emedicine – facial trauma, zygomatic complex fracture. Available from: <http://www.emedicine.com/Plastic/topic531.htm>. [Last accessed on 11 Mar 2009].
- Evans BG, Evans GR. MOC-PS CME Article: Zygomatic fractures. *Plast Reconstr Surg* 2008;121 (1S):1-11.
- Courtney DJ. Upper buccal sulcus approach to management of fracture of the zygomatic complex: A retrospective study of 50 cases. *Br J Oral Maxillofac Surg* 1999;37:464-6.
- Tang Ho. Zygomaticomaxillary Complex Fracture. (Online). Available from <http://www.bcm.edu/oto/grand/10072004.htm>. [Cited on 2007 Aug 5].
- Ellis E, Kittidumkerngl W. Analysis of treatment for isolated zygomaticomaxillary complex fractures. *J Oral Maxillofac Surg* 1996;54:386-400.
- Praveen P, Parmar S. Treatment of zygomatic fractures through upper buccal sulcus incision. Review of 200 cases. *Int J Oral Maxillofac Surg* 2007;36:76-7.
- Davidson J, Nickerson D, Nickerson B. Zygomatic fractures: Comparison of methods of internal fixation. *Plast Reconstr Surg* 1990;86:25-32.
- Champy. Treatment of zygomatic bone fracture. In: Hjorting-Hansen E, editor. *Oral and Maxillofacial Surgery: Proceedings from the 8th Int Conference on Oral and Maxillofacial Surgery*, Chicago; 1991.
- Mitchell DA, Macleod SP, Bainton R. Multipoint fixation at the frontozygomatic suture with microplate: A technical note. *Int J Oral Maxillofac Surg* 1995;24:151-2.
- Oyen OJ, Melugin MB, Indresano AT. Strain gauge analysis of the frontozygomatic region of the zygomatic complex. *J Oral Maxillofac Surg* 1996;54:1092-5; discussion 1095-6.
- Fujioka M, Yamanoto T, Miyazato O, Nishimura G. Stability of one-plate fixation for zygomatic bone fracture. *Plast Reconstr Surg* 2002;109:817-8.
- Kelley P, Hopper R, Gruss J. Evaluation and treatment of zygomatic fractures. *Plast Reconstr Surg* 2007;120:5S-15.
- Wittwer G, Adeyemo WL, Yerit K, Voracek M, Turhani D, Watzinger F, *et al.* Complications after zygoma fracture fixation: Is there a difference between biodegradable materials and how do they compare with titanium osteosynthesis? *Oral Surg Oral Med Oral Pathol Oral Radiol Endod* 2006;101:419-25.
- Atul P, Sharma RK, Surinder M. Rigid internal fixation of zygoma fractures: A comparison of two-point and three-point fixation. *Indian J Plast Surg* 2007;40:18-24.
- Hanemann M Jr, Simmons O, Jain S, Baratta R, Guerra AB, Metzinger SE. A comparison of combination of titanium and resorbable plating systems for repair of isolated zygomatic fracture in adult: A quantitative biomechanical study. *Ann Plast Surg* 2005;54:402-8.
- Bessho K, Iizuka T, Murakami K. A bioabsorbable poly-L-lactide miniplate and screw system for osteosynthesis in oral and maxillofacial surgery. *J Oral Maxillofac Surg* 1997;55:941-5.
- Enislidis G, Pichorner S, Lambert F, Wagner A, Kainberger F, Kautzky M, *et al.* Fixation of zygomatic fractures with a new biodegradable copolymer osteosynthesis system. *Int J Oral Maxillofac Surg* 1998;27:352-5.
- Bergsma JE, de Bruijn WC, Rozema FR, Bos RR, Boering G. Late degradation tissue response to poly (L-lactide) bone plates and screws. *Biomaterial* 1995;16:25-31.
- Laine P, Kontio R, Lindqvist C, Suuronen R. Are there any complications with bioabsorbable fixation devices? A ten year review in orthognathic surgery. *Int J Oral Maxillofac Surg* 2004;33:240-4.
- Matthew IR, Frame JW. Policy of consultant oral and maxillofacial surgeons towards removal of miniplate components after jaw fracture fixation: Pilot study. *Br J Oral Maxillofac Surg* 1999;37:110-2.

How to cite this article: Tripathi N, Goyal M, Mishra B, Dhasmana S. Zygomatic complex fracture: A comparative evaluation of stability using titanium and bio-resorbable plates as one point fixation. *Natl J Maxillofac Surg* 2013;4:181-7.

Source of Support: Nil. **Conflict of Interest:** None declared.