

[Orthopaedics]

Shoulder Pain in the Overhead Throwing Athlete

Shane T. Seroyer, MD,* Shane J. Nho, MD, Bernard R. Bach Jr, MD, Charles A. Bush-Joseph, MD, Gregory P. Nicholson, MD, and Anthony A. Romeo, MD

Treatment of the overhead throwing athlete is among the more challenging aspects of orthopaedic sports medicine. Awareness and understanding of the throwing motion and the supraphysiologic forces to which the structures of the shoulder are subjected are essential to diagnosis and treatment. Pain and dysfunction in the throwing shoulder may be attributed to numerous etiologies, including scapular dysfunction, intrinsic glenohumeral pathology (capsulolabral structures), extrinsic musculature (rotator cuff), or neurovascular structures. Attention to throwing mechanics and appropriate stretching, strength, and conditioning programs may reduce the risk of injury in this highly demanding activity. Early discovery of symptoms, followed by conservative management with rest and rehabilitation with special attention to retraining mechanics may mitigate the need for surgical intervention. Prevention of injury is always more beneficial to the long-term health of the thrower than is surgical repair. An anatomic approach is used in this report, focusing on common etiologies of pain in the overhead thrower and emphasizing the clinical presentation and treatment.

Keywords: shoulder pain; overhead throwing; throwing athlete

The act of throwing a baseball is one of the fastest and most violent maneuvers to which any joint in the body is subjected. For each pitch, the thrower must generate high levels of energy in the lower extremities and trunk to accelerate the ball to top velocity. The muscles and capsular structures of the shoulder must then dissipate this force after ball release and during arm deceleration. In elite pitchers, internal rotation of the humerus can reach velocities as great as 7000 deg/s.²⁹ To maximize the force that can be generated and transferred to the ball, the structures of the shoulder must strike a delicate balance between adequate laxity to achieve extreme range of motion and sufficient stability to inhibit subluxation and instability. This delicate equilibrium has been referred to as the “throwers paradox.”⁸⁴ At the extremes of motion, the forces generated, and the speed with which this motion occurs, place the stabilizing structures of the glenohumeral joint and scapula at risk.⁶⁰

The speed of pitching, coupled with the complex coordination of many constituent muscles, makes pinpointing the point of breakdown in throwing mechanics (source of pain) difficult to ascertain. Inherent to the successful treatment of the throwing athlete is a thorough understanding of the biomechanical stresses on the at-risk structures, as they relate to the specific phases of the throwing motion (Figure 1).^{29,30,43,60}

The legs and trunk serve as the force generators, allowing adequate production and efficient transfer of energy to propel the ball upon release.^{11,44} The coordinated function of this “kinetic chain” is essential to alleviate the need for the shoulder to generate large forces. The throwing motion facilitates the synchronization of the kinetic chain. The scapula plays a key role in the positioning of the glenoid, allowing for the necessary extremes of motion to occur without impingement.^{19,21,55,63} Breakdown of the kinetic chain at any level requires increased force generation by the

From Rush University Medical Center, Chicago, Illinois

*Address correspondence to Shane T. Seroyer, MD, Midwest Orthopedics at Rush University, 1725 W. Harrison St., Suite 1063, Chicago, IL 60612 (e-mail: sseroyer@gmail.com).

No potential conflict of interest declared.

DOI: 10.1177/1941738108331199

© 2009 American Orthopaedic Society for Sports Medicine

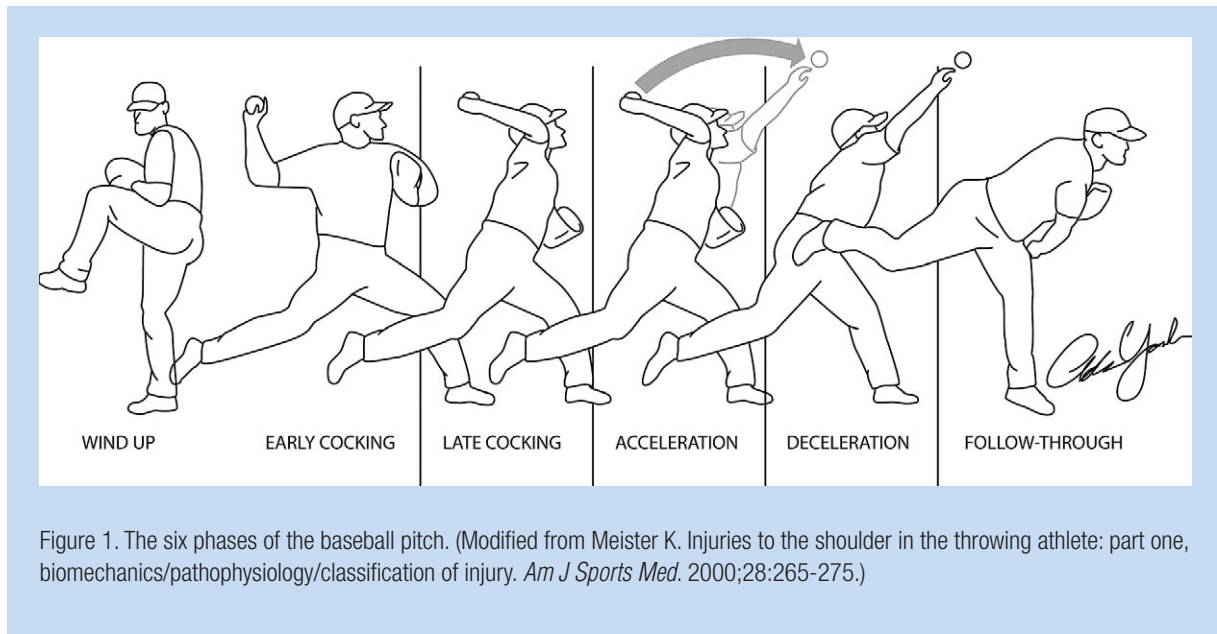


Figure 1. The six phases of the baseball pitch. (Modified from Meister K. Injuries to the shoulder in the throwing athlete: part one, biomechanics/pathophysiology/classification of injury. *Am J Sports Med.* 2000;28:265-275.)

shoulder in order to maintain normal pitching velocity, control, and performance.²⁷ Although it is beyond the scope of this article, a detailed understanding of the components of the kinetic chain and the normal throwing mechanics is essential to the proper treatment of the throwing athlete.

DIAGNOSTIC APPROACH

A systematic approach to the potential causes of shoulder pain must be developed by the examiner to avoid misdiagnosis. Scapular dysfunction, neurovascular compression, and inherent structural pathology in the glenohumeral joint, including the rotator cuff, labrum, and capsule, must all be considered (Table 1). Early recognition of the etiology of shoulder pain is essential, as conservative intervention in the at-risk throwing shoulder is often enough to prevent development of capsular, tendinous, or labral conditions that can rapidly deteriorate.

Maintaining conditioning and efficient throwing mechanics can alleviate potential sources of injury and pain. Core conditioning, periscapular and rotator cuff muscle strengthening, and flexibility programs are essential off-season components to injury-free throwing. Evaluation of the injured thrower requires a very detailed pitching history (Table 2) and physical examination. The examiner must be comfortable with and consider normal changes that occur in the competitive throwing athlete and assimilate as much information as possible from the history and comparative examination of the contralateral upper extremity. The throwing shoulder acquires increased external rotation compared to

Table 1. Differential diagnosis of pain in the throwing shoulder.^a

Extrinsic	Intrinsic	Neurovascular
Rotator cuff	Bone	Thoracic outlet syndrome
Tendinitis	Bony Bankart	Neurogenic, arterial, venous
Tear	OCD	Axillary artery
Subacromial impingement	Posttraumatic/osteoarthritis	Thrombosis, aneurysm
Scapular dysfunction	Bennett's lesion	Effort thrombosis
Scapular dyskinesis	Biceps tendon	Quadrilateral space syndrome
SICK scapula	Tendinitis/tendinopathy	Long thoracic nerve palsy
Snapping scapula	Soft tissue	Suprascapular nerve palsy
Scapulothoracic bursitis	SLAP	Brachial neuritis
Scapular winging	Bankart/anterior instability	
	Posterior labral tear/posterior instability	
	HAGL	
	MDI	
	GIRD	

^aOCD, osteochondritis dissecans; SICK, Scapular malposition, Inferior medial border prominence, Coracoid pain and malposition, and dyskinesis of scapular movement; SLAP, superior labrum anterior and posterior; HAGL, humeral avulsion of the glenohumeral ligament; MDI, multidirectional instability; GIRD, glenohumeral internal rotation deficit.

Table 2. Thorough pitching history and shoulder pain history.

Pitching History	Pain History
Age patient first began pitching	Description of pain: location, character, duration, radiation
Total years throwing	Phase of throwing cycle in which pain occurs
Number of outings per year	Point of season when pain began (is thrower exceeding number of innings he or she is accustomed to throwing)
Approximate number of pitches/outing	Point in outing pain begins (early innings vs late innings)
Were pitch-count limits enforced	Changes in velocity
Amount of rest between outings	Changes in ability to locate ball
Amount of complete rest from throwing/year	Changes in endurance (ability to go into late innings)
Types of pitches thrown	Changes in ability to "get loose" prior to outing
Age at which different pitches were first thrown	
Ratio of fastballs to breaking balls thrown	
History of injury/treatment to throwing shoulder	
History of missed outings due to pain or injury	

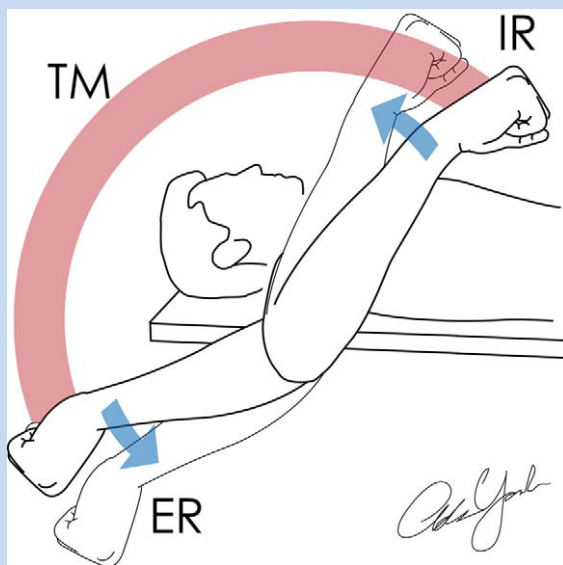


Figure 2. Total motion concept: Total Motion (TM) = IR + ER. The normal adaptation in the throwing athlete consists of increased external rotation (ER), with a symmetrical compensatory decrease in internal rotation (IR). The total arc of motion should be preserved. (Illustration modified from Wilk KE, Meister K, Andrews JR. Current concepts in the rehabilitation of the overhead throwing athlete. *Am J Sports Med.* 2002;30:136-151.)

preserved.⁶¹ Any gain in external rotation should be offset by a comparable decrease in internal rotation, resulting in equal total rotation in the dominant and nondominant shoulders (Figure 2). Symptomatic throwers often demonstrate a significant loss in internal rotation greater than the compensatory gain in external rotation.¹⁰

Active and passive range of motion and stability testing should be performed and compared to the nonthrowing extremity. Scapular function should be assessed for tracking, positioning, winging, and muscle wasting. Overhead throwers may demonstrate asymmetries in the resting scapular position on the dominant side, with more scapular internal rotation and antetilting.⁶⁶ This asymmetry may be present in asymptomatic throwers. Radiographs, advanced imaging (MRI, angiography/ultrasonography), and electromyographic studies may assist in the diagnosis of pathology in the overhead throwing athlete.

SOURCES OF SHOULDER PAIN

Rotator Cuff

A properly functioning and well-conditioned rotator cuff is essential to withstand the extraordinary forces experienced with the normal throwing motion. Lesions of the rotator cuff tendons are a significant source of shoulder pain.⁸⁶ The repetitive nature of these supraphysiologic loads imparted to the rotator cuff commonly lead to rotator cuff impingement, tendinitis, and tearing. Rotator cuff tears may be partial thickness, intratendinous, or full thickness in nature.⁵⁶ The thrower will often complain of diffuse shoulder pain aggravated by overhead activity and will often notice

the contralateral shoulder^{33,41,42,48} and demonstrates altered strength profiles with increased strength of the humeral internal rotators compared to the external rotators.^{20,24,37,64,81} The throwing athlete's total arc of motion in the dominant arm should be

weakness and decreased velocity. Night pain radiating down the arm to the elbow is common.⁸⁶ Although these tears may be the result of an acute event, they are more commonly the result of fatigue failure and degenerative changes in the rotator cuff.⁸⁶ Prevention of rotator cuff injury through conditioning and proper mechanics is critical as the results of rotator cuff repair have been very disappointing in elite throwers.⁵⁶ Only 8% of professional baseball pitchers (1 of 12) with repaired full-thickness tears have returned to the same level of competition at a mean 66-month follow-up.⁵⁶ After repair, many pitchers are able to pitch pain-free and regain their velocity and control, but complain of fatigue that limits their effectiveness. They also require a prolonged recovery time between pitching performances.⁵⁶ The most common location of rotator cuff pathology in overhead throwers is at the undersurface of the posterior half of the supraspinatus and the superior half of the infraspinatus.⁵ Early recognition and conservative intervention with rotator cuff tendinitis may avert the need for surgical intervention. A subacromial corticosteroid injection, followed by a brief period of rest (2-4 days), will often rectify the symptoms. The only contraindication to steroid injections is in a patient on whom operating for rotator cuff pathology in the ensuing 6 to 12 weeks will take place, as it may negatively affect rotator cuff healing. Rotator cuff strengthening and rehabilitation, as well as an interval throwing program, can then be used to condition the thrower for return to play. Repair of partial-thickness rotator cuff tears in professional and college throwers allowed 89% to return to the same level of play, with follow-up of only 12 months.¹⁴

Glenohumeral Internal Rotation Deficit

The large distraction forces during the follow-through phase of pitching have been implicated as a cause of contractures in the posteroinferior capsule.²⁹ The loss of internal rotation in throwers is likely a result of this posteroinferior capsular contracture. A shortened, contracted posteroinferior capsule creates a posterosuperior shift in the humeral head.³⁵ This allows hyperexternal rotation as the posterior capsule reaches maximum length while the anterior capsule still allows for additional external rotation.¹⁰ This pathologic loss of motion has been associated with type 2 superior labrum anterior and posterior (SLAP) lesions in throwing athletes.¹⁰ Verna (unpublished data, 1991) prospectively followed a group of professional baseball pitchers with glenohumeral internal rotation deficit (GIRD) of at least 35°. Sixty percent of these subjects developed shoulder problems requiring them to stop pitching between spring training and the end of the season.

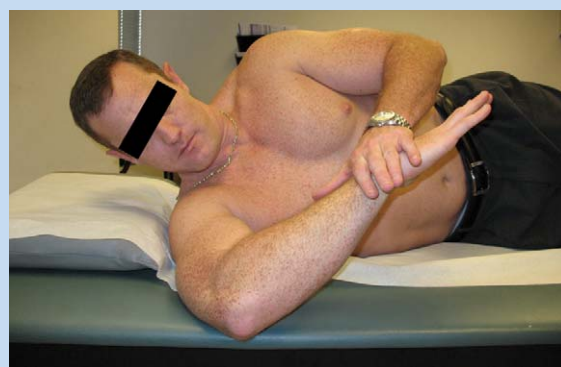
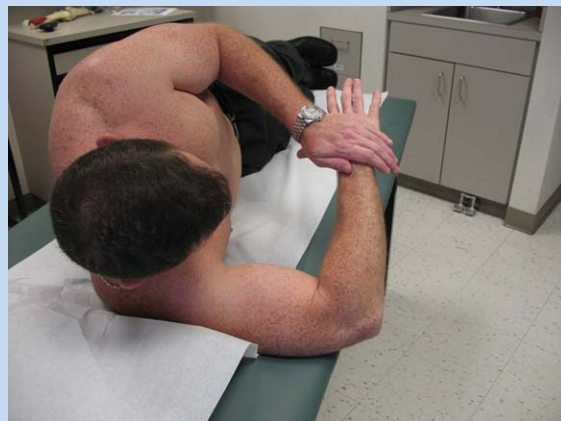
Figure 3. Sleeper stretch performed by the patient to stretch the posterior capsule of the glenohumeral joint.

Burkhart et al¹⁰ suggested that approximately 90% of throwers with symptomatic GIRD will respond to a posteroinferior capsular stretching program. Acceptable limits of internal rotation deficit are less than a 20° loss of internal rotation compared to the contralateral arm or 10% of the total rotation of the contralateral arm.¹⁰ Early conservative treatment with “sleeper stretches” of the posteroinferior capsule can be very successful in returning the symptomatic thrower to competition (Figure 3). Off-season strength, conditioning, and stretching programs may prevent or mitigate this pathologic motion from developing and decrease the likelihood of labral and rotator cuff pathology developing throughout the season. Symptomatic throwers who do not respond to conservative management may require a selective posteroinferior capsular release followed by an immediate postoperative internal rotation stretching program.¹² Rotational profiles of each thrower should be accurately monitored.

Capsulolabral Pathology

The glenoid capsulolabral complex provides a stabilizing force to prevent glenohumeral instability.⁶⁵ As the arm moves through the extremes of the throwing motion, the rapid glenohumeral motion, coupled with the large compressive and distractive forces imparted to the joint, place the labrum at risk for injury. The superior and posterior portions of the labrum are particularly susceptible to injury.^{4,9,67} The superior labrum/biceps anchor complex is placed under a distractive force when the arm is abducted and externally rotated in the cocking/acceleration phases of throwing,^{10,62} resulting in physiologic impingement of the posterosuperior labrum between the humeral head and glenoid.³⁶ Abnormalities in the translational or rotational limits of glenohumeral motion due to capsular contracture or patholaxity increase the risk of injury. Posterior labral lesions and subsequent instability are likely due to the large distraction forces at the posterior shoulder. Successful return to play after repair of posterior labral pathology appears to be much less favorable than with superior labral lesions.⁶⁷ The most common labral lesion in the overhead thrower is a tear of the posterosuperior labrum and avulsion of the biceps anchor.¹⁰ Eighty-seven percent of overhead throwers who undergo repair of type 2 SLAP lesions successfully return to their preinjury level of performance and velocity.^{9,62} Sparse data exist in the literature relating to recovery from this injury isolated specifically to throwers. Return to the same level of competition may not be as successful as once thought.

Impingement

In patients with impingement symptoms, the scapula should also be assessed using the scapular muscle assistance test because deficient acromial elevation can cause impingement. Figure 4 demonstrates this test as Kibler⁴⁴ described: an upward and lateral force is exerted on the inferior medial scapula as the arm is brought to the provocative position of impingement. If impingement symptoms are reduced, inhibition of the scapular elevators (scapular dyskinesia) may be the cause of the impingement. In patients with subacromial impingement, kinematic studies have demonstrated decreased upward scapular rotation.^{52,53} Many cases of impingement syndrome may improve with scapular physical therapy and conditioning.⁴⁴

Posterior-superior impingement often presents as posterior shoulder pain in the position of late cocking and early acceleration.⁶⁰ As with rotator cuff tendinitis, a conservative approach to impingement with a subacromial corticosteroid injection, brief

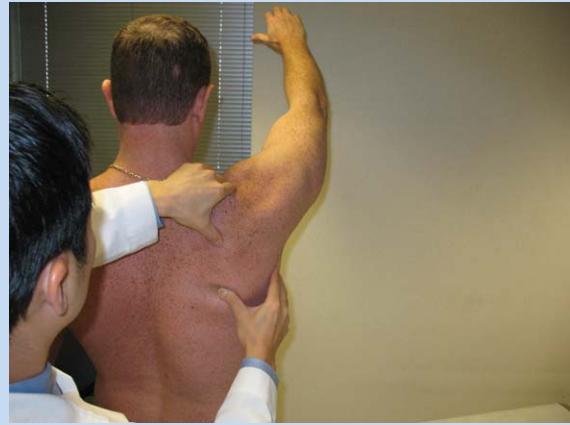

Figure 4. Scapular muscle assistance test. The examiner assists in upward rotation of the scapula by providing stabilization at the superomedial border of the scapula and lateral rotation at the inferomedial border as the patient actively elevates the arm into the zone of impingement. If impingement symptoms are reduced, scapular dyskinesia is a likely cause of the subacromial impingement.

rest until symptoms resolve, and a rotator cuff and periscapular muscle strengthening and conditioning program should be the initial treatment approach. Arthroscopic subacromial decompression may be needed for recalcitrant cases, but acromioplasty should be avoided if possible, as return to play in throwing athletes has been very unsatisfactory.⁷⁸

Scapular Etiologies of Shoulder Pain

The scapula provides a stable base for the muscles of the rotator cuff to exert forces on the glenohumeral joint and allow upper extremity motion. Without this stable base, there will be a breakdown of energy transfer in the kinetic chain, requiring the muscles to compensate. Scapular dyskinesia, SICK (Scapular malposition, Inferior medial border prominence, Coracoid pain and malposition, and dysKinesia of scapular movement) scapula, and snapping scapula can all cause pain and dysfunction in the overhead thrower.

A tight posterior capsule may lead to increased protraction (failure of proper retraction) and inferior positioning of the scapula during throwing.^{44,60} This can cause antetilting and insufficient elevation of the scapula, narrowing the subacromial arch and decreasing the rotator cuff clearance under the acromion. This may manifest as clinical impingement during late cocking through the acceleration and follow-through phases.²⁸

Scapular dyskinesia is the abnormal positioning and motion of the scapula. This abnormal positioning disrupts the efficient transfer of energy along the kinetic chain. This loss of coordinated protraction/retraction and resulting glenoid antetilting subjects the anterior labrum and capsule to greater shear forces as the arm is brought to provocative positions.⁴⁴ Fatigue of the lower trapezius and serratus anterior after throwing a few innings can also cause closure of the subacromial arch by decreasing upward scapula rotation, leading to impingement symptoms.^{7,60} The SICK scapula syndrome is the extreme of scapular dyskinesia, caused by overuse muscle fatigue. Prophylactic periscapular muscle strengthening and conditioning should prevent this problem.

Burkhart et al¹¹ described “dead arm” syndrome in throwing athletes. The etiology of this syndrome is uncoordinated or deficient periscapular muscle activation, leading to altered dynamic scapular kinematics that disrupts the kinetic chain and places the shoulder in an at-risk position.¹¹ In the throwing athlete, SICK scapula may lead to other pathologies, including impingement, or labral or rotator cuff abnormalities.¹¹ A drooping throwing shoulder at rest may be caused by excessive protraction of the scapula with downward scapular rotation. Tenderness at the medial edge of the coracoid tip may be caused by tension from the pectoralis minor tendon. Downward rotation and protraction (antetilting) may insidiously shift the coracoid into a more inferior and lateral position, causing anterior coracoid pain with or without associated posterosuperior scapular pain.¹¹ The anterior pain necessitates a thorough and accurate examination similar to that for anterior instability or SLAP lesions. Pain at the coracoid process with resisted forward flexion is common with a lack of active terminal forward flexion. Abatement of coracoid symptoms and increased forward flexion with the scapular retraction test is considered diagnostic of SICK scapular syndrome. In the scapular retraction test, the scapula is repositioned and tilted posteriorly by the examiner, as the patient actively forward flexes (Figure 5).¹¹ The SICK scapular syndrome can be confused with other pathologies that require operative intervention. The correct diagnosis, followed by rotator cuff and periscapular muscle rehabilitation and reeducation, can allow a rapid return to sport, but will require a maintenance strengthening program to prevent recurrence.¹¹

Scapulothoracic crepitus, pain, or bursitis can be debilitating to the overhead thrower.⁴⁷ There are 6 scapulothoracic bursae. The 2 major bursae, which are most frequently symptomatic, are located between the serratus anterior and the chest wall, and

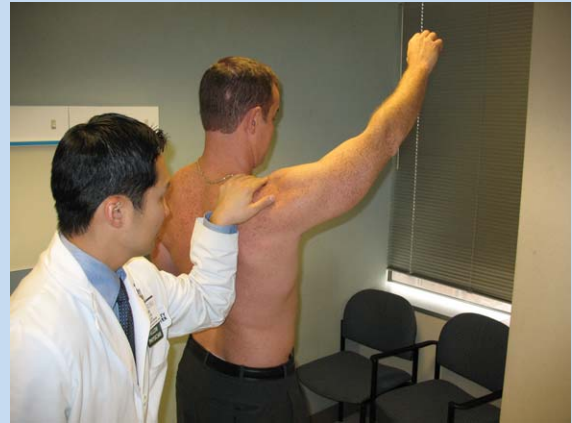

Figure 5. Scapular retraction test. The examiner manually repositions the scapula into retraction and posterior tilting. The patient then actively attempts forward flexion. Additional terminal forward flexion without impingement symptoms and added muscle strength suggests that periscapular muscle inactivation or dysfunction is contributing to the patient's symptoms.

between the subscapularis and the serratus anterior muscle.¹³ The rapid and repetitive movement of the scapula on the posterior thorax during throwing can lead to soft tissue irritation and chronic bursitis.⁷⁵ Clinically, the pain is usually localized to the superomedial or inferior angle during the late cocking and acceleration phases of throwing.^{47,75} There may be tenderness and a fullness over the bursa. The thrower may reproduce audible crepitus with active circumduction. Initial treatment is nonoperative: rest, analgesia, and nonsteroidal anti-inflammatory drugs (NSAIDs). Corticosteroid injections may also provide acute relief.^{47,75} Placing the patient prone with the affected arm in internal rotation so the dorsum of the hand rests on the lumbar spine will elevate the medial border of the scapula. This produces a direct approach (superomedial or inferomedial angle) to the bursa for injection. A rehabilitation program should also be implemented to reduce thoracic kyphosis and strengthen the serratus anterior and subscapularis. This training should increase the separation between the scapula and the chest wall.^{47,58} In recalcitrant cases, the bursa and possibly a portion of the superior or inferior medial angle of the scapula may be resected.⁷⁵

Neurovascular

When examining an overhead thrower for shoulder pain, neurovascular etiologies (Figure 6), including thoracic outlet syndrome, axillary artery

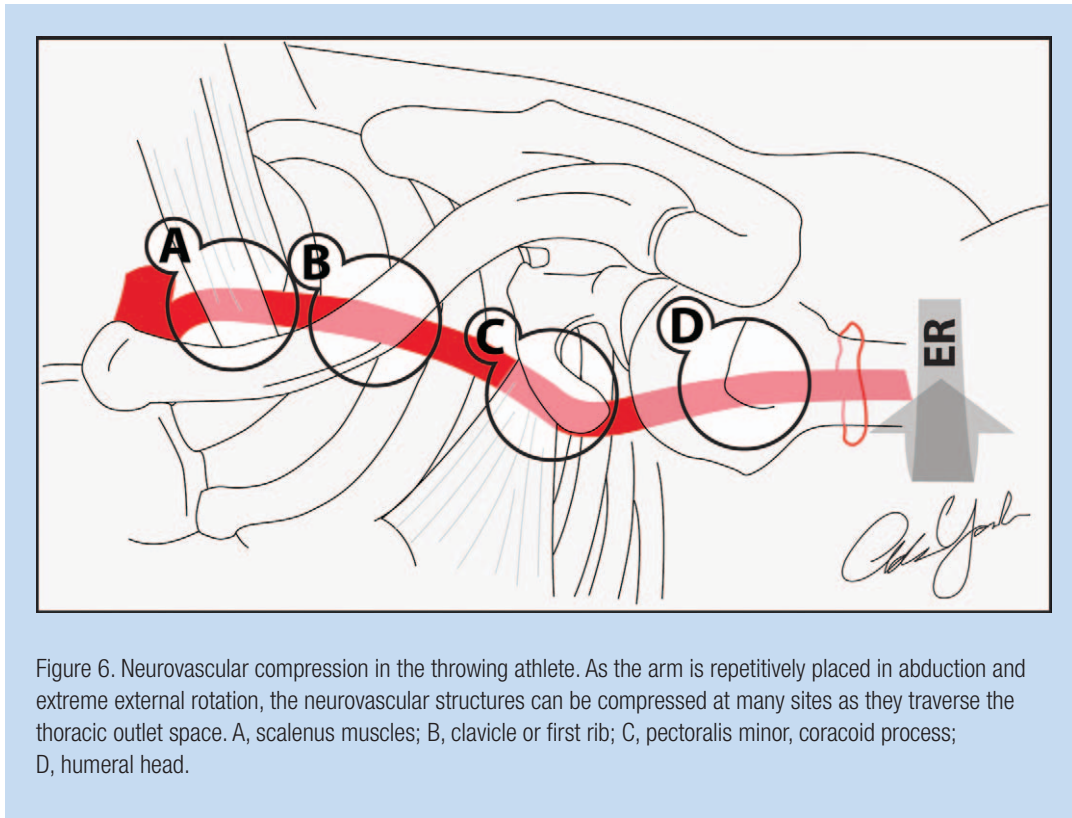


Figure 6. Neurovascular compression in the throwing athlete. As the arm is repetitively placed in abduction and extreme external rotation, the neurovascular structures can be compressed at many sites as they traverse the thoracic outlet space. A, scalenus muscles; B, clavicle or first rib; C, pectoralis minor, coracoid process; D, humeral head.

thrombosis, and quadrilateral space syndrome must be considered. Although rare, these entities may cause profound morbidity. They often have similar clinical presentations: fatigue, loss of velocity, vague shoulder pain, sense of heaviness, aching, or cramping in the upper extremity. Patients will often experience nerve dysfunction (commonly ulnar) after the onset of throwing, with numbness and tingling that may present as weakness of grip and loss of manual dexterity secondary to intrinsic muscle weakness.^{59,70} Athletes with arterial pathology may present with cold, pale extremities, while the venous compressive syndromes may produce swelling and a mottled discoloration.⁷⁰

Examinations in all throwers should include a thorough assessment for bruits, thrills, diminution in pulses, and capillary refill in comparison to the nonthrowing extremity. Wrist, hand, and digit swelling, cyanosis, or digital petechiae should be noted. Plain radiographs should be taken to detect cervical ribs, long transverse processes of C7, or bony abnormality from a previous clavicular fracture.^{71,72} Ancillary examinations including ultrasound, MRI, or magnetic resonance arthrography may also be indicated.

Thoracic outlet syndrome involves compression of the neurovascular contents of the thoracic outlet space (Figure 6). The subclavian artery and brachial

plexus travel between the anterior and middle scalene muscles, over the first rib and beneath the clavicle, the pectoralis minor tendon, and coracoid process as they descend to the extremity (Figure 7).^{25,50,59,70} With the arm in excessive abduction, the neurovascular structures may be compressed under the pectoralis tendon and the coracoid (Figures 6 and 7).⁷¹ Thoracic outlet syndrome in pitchers may be the consequence of several factors, including excessive muscle development or scapular depression from inadequate scapular muscle stabilization.²⁵

Thoracic outlet syndrome can be either neurologic or vascular in nature, with compression of the brachial plexus or axillary/subclavian vessels.^{71,79} The neurologic form involves the lower trunk of the brachial plexus affecting the ulnar nerve and presenting with numbness of the fifth digit.⁵⁰ Several provocative tests have been described to evaluate for thoracic outlet syndrome, including the Adson, Roos, and Wright tests.^{2,69,85} Initial treatment is nonoperative and includes rest, NSAIDs, strengthening of the scapular stabilizers, and postural exercises. Conservative management has been successful in up to 90% of cases.^{49,69,72}

Axillary artery thrombosis and aneurysm have been reported in Major League Baseball pitchers.^{80,82} The axillary artery is a continuation of the subclavian, taking its origin at the lateral margin of the first rib. It

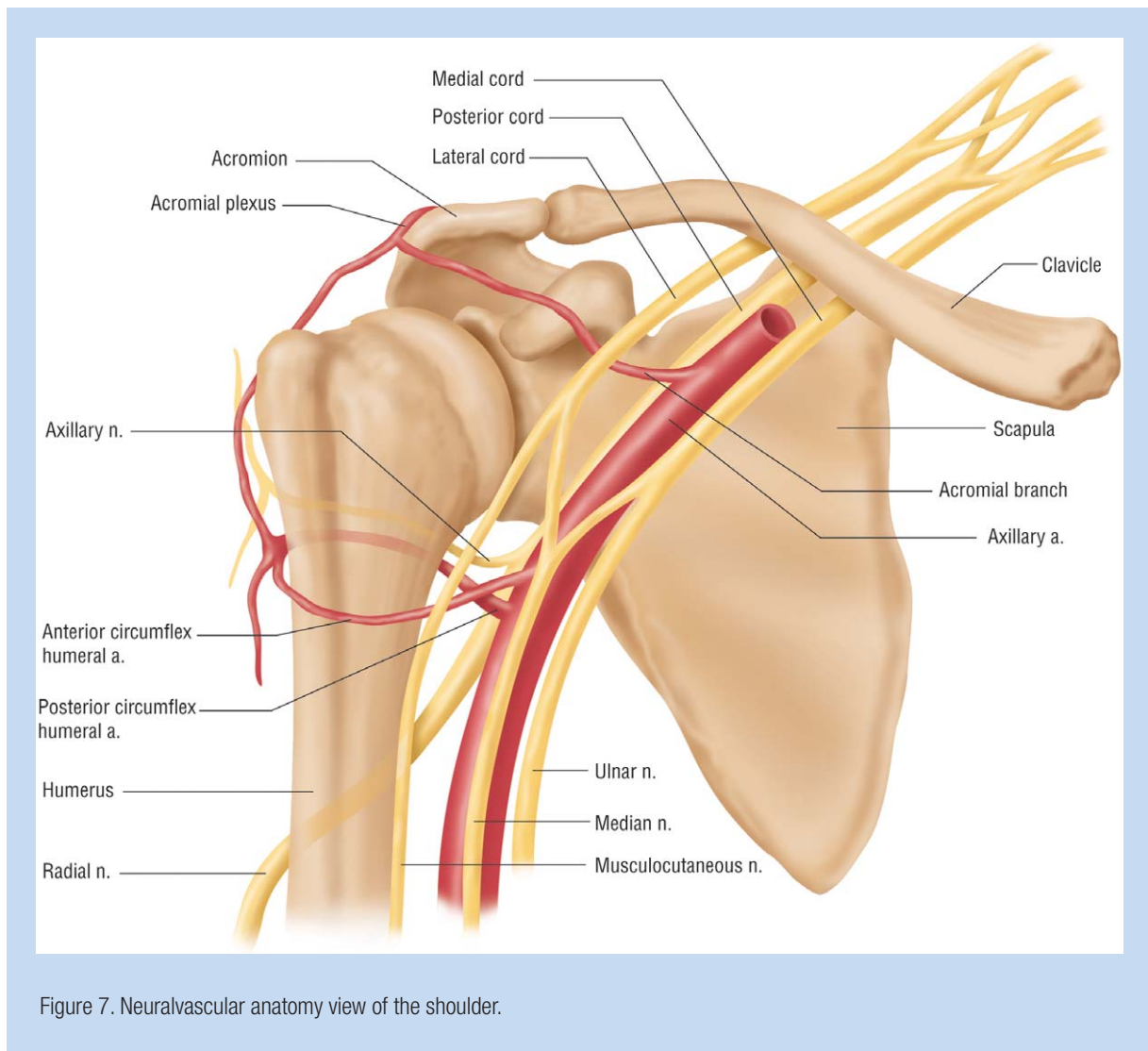


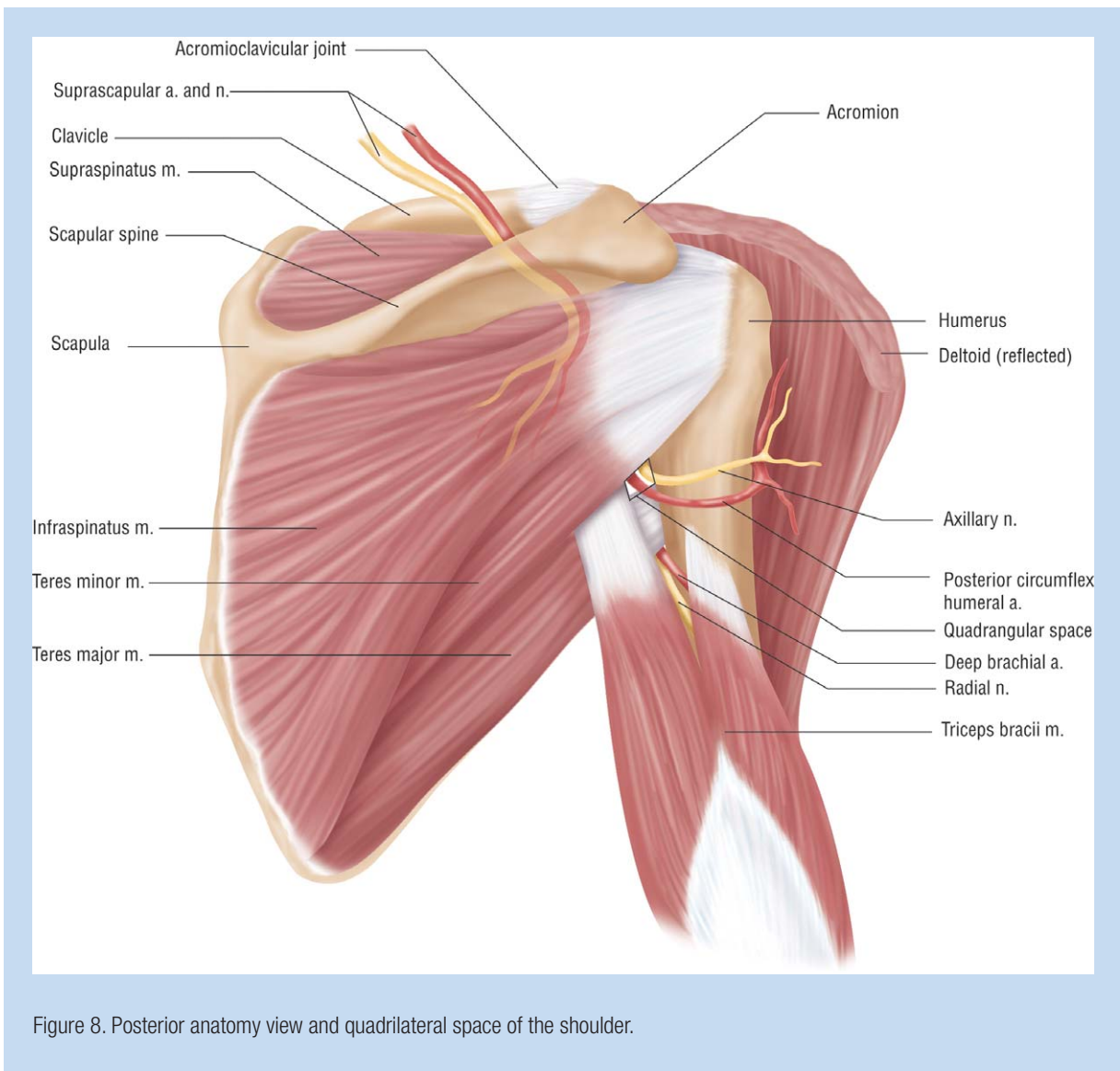
Figure 7. Neuralvascular anatomy view of the shoulder.

may be compressed by the overlying pectoralis minor muscle as the arm is elevated^{57,85} or by the humeral head in abduction and external rotation; the artery is tethered by the anterior and posterior circumflex arteries as they encircle the humeral neck.⁸⁰ In the vast majority of subjects tested, duplex Doppler scans can demonstrate compression of the axillary artery by the humeral head with the arm in the throwing position.⁶⁸ This compression may predispose the axillary artery to thrombosis.⁶⁸ Hypertrophy of the muscle has been seen in baseball pitchers and should be checked during the physical examination.⁴⁵

Positional angiography can also demonstrate compression, occlusion, or aneurysm. Reversed saphenous vein bypass grafting of the aneurysmal section of the vessel has been successful.^{6,80} The venous system is also subject to compression

and occlusion. The axillary vein is susceptible to compression in the costoclavicular space as it traverses the clavicle, subclavius, scalenus, and costoclavicular ligaments.⁸³ During abduction and external rotation, the humeral head is depressed and may narrow this potential space, causing venous compression resulting in intimal damage and “effort thrombosis.”^{18,23,74} This is the most common vascular problem in overhead athletes.⁷⁶

The gold standard diagnostic tool for effort thrombosis is venography.⁵⁴ Nonoperative treatment with relative rest and thrombolytic and anticoagulation therapy has been successful in treatment.^{1,18,83} Recalcitrant swelling, superficial thrombophlebitis, and even pulmonary embolism after nonoperative treatment have led to surgical decompression of the thoracic outlet.³⁹



In cases of acute vascular insufficiency or progressive neurologic dysfunction, surgical intervention is often necessary. Scalene muscle release, pectoralis minor tenotomy, first/cervical rib resection, and claviclectomy all have been performed to decompress the thoracic outlet space.

In the quadrilateral space syndrome, the thrower often complains of intermittent, poorly localized anterior shoulder pain with distally radiating paresthesias, aggravated by forward flexion, abduction, and external rotation. On examination, discrete point tenderness over the quadrilateral space will be present.¹² The quadrilateral space is bounded by the teres minor superiorly, long head of triceps medially, teres major inferiorly, and the surgical neck of the humerus laterally (Figures 8 and 9).

Initial treatment includes internal rotation stretching with posterior rotator cuff and periscapular muscle strengthening and stretching. Thirty percent of throwers will not respond to conservative measures and will require surgical intervention.¹² During surgical exploration, obliquely oriented fibrous bands have been identified tethering the neurovascular bundle in the quadrilateral space.^{32,51}

Shoulder pain and dysfunction has also been associated with palsy of the suprascapular and long thoracic nerves. Suprascapular nerve compression can occur at both the suprascapular notch^{46,77} and the spinoglenoid notch.³ The spinoglenoid notch is the more common site in the throwing athlete and may present as a partial palsy, with retention of partial infraspinatus function despite

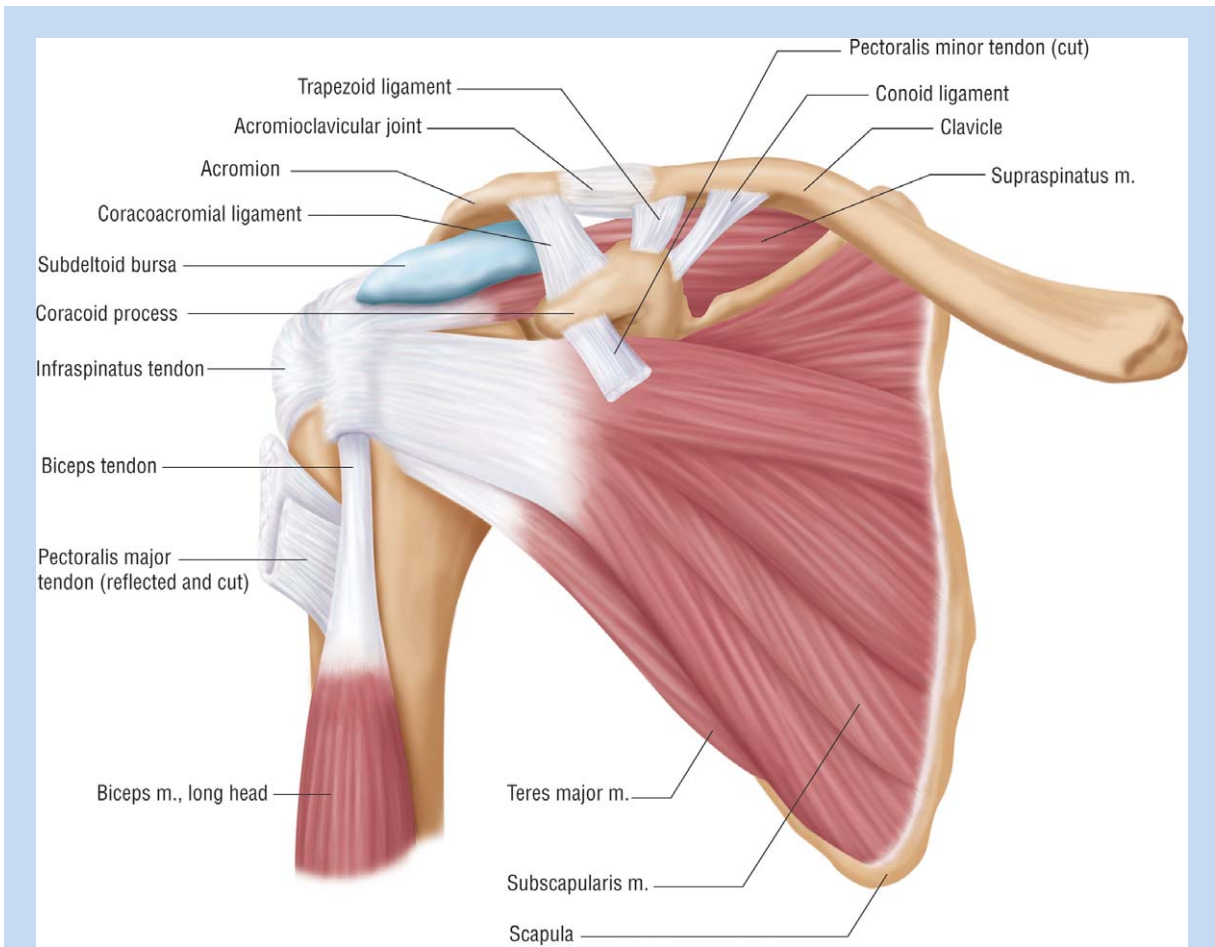


Figure 9. Anterior anatomy view of the shoulder.

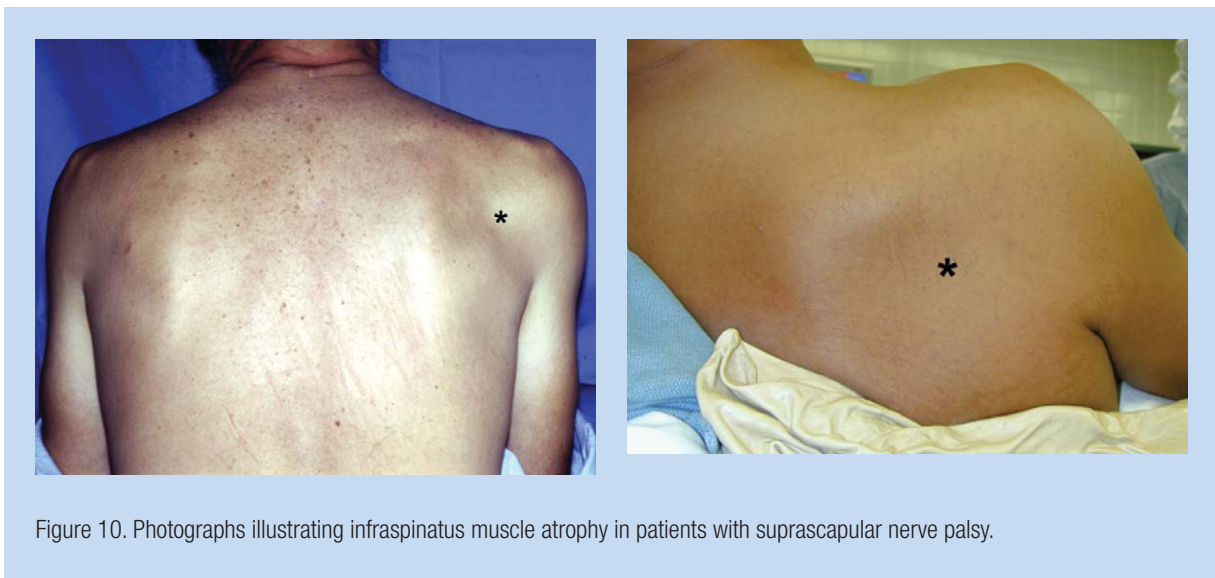


Figure 10. Photographs illustrating infraspinatus muscle atrophy in patients with suprascapular nerve palsy.

visible atrophy (Figure 10).^{26,38} Throwers usually compensate with the teres minor.^{26,38} Compression, traction, friction, or repetitive microtrauma can occur with recurrent overhead activities. The thrower may present with poorly localized dull pain over the lateral and posterior aspects of the shoulder.⁷⁰ In the follow-through phase, with the arm in adduction and internal rotation, the spinoglenoid ligament is tightened and may compress the nerve.^{17,70} Compression may also occur with the arm in abduction and external rotation between the tendinous margin of the rotator cuff and the scapular spine.⁷³ This condition may result from irritation from a posterosuperior ganglion associated with a type 2 SLAP lesion.⁷⁰ Nonoperative treatment consisting of rest, NSAIDs, range of motion, and strengthening of the shoulder provide relief in the majority of the cases.^{8,22,40} Maintenance of shoulder motion to prevent stiffness is imperative to this nonoperative approach, along with posterior capsular stretching with the arm in abduction to relax the spinoglenoid ligament.⁷⁰ In recalcitrant cases, with electromyographic localization to the spinoglenoid notch, if no ganglion is found, release of a hypertrophied spinoglenoid ligament often leads to symptom resolution.^{15,16}

Long thoracic nerve palsy is likely due to repetitive traction microtrauma from throwing.⁷¹ The nerve may be stretched as the head and neck are tilted away from the arm during the throwing motion.³⁴ The thrower will typically note a loss of velocity, and may complain of neck, shoulder, or scapular discomfort. Physical examination may demonstrate decreased forward elevation strength and motion.⁷¹ Inferior scapular border winging may be seen posteriorly as a wall push-up is performed. Nonoperative treatment consists of rest, NSAIDs, maintenance of glenohumeral range of motion, and strengthening of the scapular stabilizers and rotator cuff. Most cases resolve within 6 to 9 months,³¹ but surgical intervention may be needed. Muscle transfers or scapulothoracic fusion may be necessary in persistent cases if improvement is not seen on electromyography in 1 to 2 years.⁷¹

CONCLUSION

Treatment of the throwing athlete with shoulder pain remains among the more challenging aspects of orthopaedic sports medicine. Without awareness and understanding of the throwing motion, and the suprphysiologic forces to which it subjects the shoulder, detection of the source of pain can be difficult. The coordinated production and transfer of potential energy from the body to the upper

extremity in the form of kinetic energy is required to propel the ball at top velocity. The violent and rapid motion that is required of the upper extremity during these events places numerous structures in the shoulder at risk for injury. Early discovery of symptoms, followed by conservative management with rest and rehabilitation, with special attention to mechanics, may optimize results. A coordinated approach among trainers, therapists, and physicians is required for the comprehensive evaluation, diagnosis, and treatment of shoulder pain in the throwing athlete.

ACKNOWLEDGMENT

The authors would like to thank Adam Yanke and Kristen W. Marzejon for their assistance with drafting of the illustrations and Herm Schneider, head trainer for the Chicago White Sox, for his invaluable input on the rehabilitation of the elite throwing athlete.

REFERENCES

1. AbuRahma AF, Sadler D, Stuart P, Khan MZ, Boland JP. Conventional versus thrombolytic therapy in spontaneous (effort) axillary-subclavian vein thrombosis. *Am J Surg.* 1991;161:459-465.
2. Adson W. Surgical treatment for symptoms produced by cervical rib and scalenus anticus muscle. *Surg Gynecol Obstet.* 1947;85:687-700.
3. Aiello I, Serra G, Traina GC, Tugnoli V. Entrapment of the suprascapular nerve at the spinoglenoid notch. *Ann Neurol.* 1982;12:314-316.
4. Altchek DW, Dines DM. Shoulder injuries in the throwing athlete. *J Am Acad Orthop Surg.* 1995;3:159-165.
5. Andrews JR, Gidumal RH. Shoulder arthroscopy in the throwing athlete: perspectives and prognosis. *Clin Sports Med.* 1987;6:565-571.
6. Arko FR, Harris EJ, Zarins CK, Olcott C IV. Vascular complications in high-performance athletes. *J Vasc Surg.* 2001;33:935-942.
7. Birkelo JR, Padua DA, Guskiewicz KM, Karas SG. Prolonged overhead throwing alters scapular kinematics and scapular muscle strength. *J Athl Train.* 2003;38:S10-S11.
8. Black KP, Lombardo JA. Suprascapular nerve injuries with isolated paralysis of the infraspinatus. *Am J Sports Med.* 1990;18:225-228.
9. Burkhart SS, Morgan C. SLAP lesions in the overhead athlete. *Orthop Clin North Am.* 2001;32:431-441, viii.
10. Burkhart SS, Morgan CD, Kibler WB. The disabled throwing shoulder: spectrum of pathology. Part I: pathoanatomy and biomechanics. *Arthroscopy.* 2003;19:404-420.
11. Burkhart SS, Morgan CD, Kibler WB. The disabled throwing shoulder: spectrum of pathology. Part III: the SICK scapula, scapular dyskinesis, the kinetic chain, and rehabilitation. *Arthroscopy.* 2003;19:641-661.
12. Cahill BR, Palmer RE. Quadrilateral space syndrome. *J Hand Surg [Am].* 1983;8:65-69.
13. Ciullo JV, Jones E. Subscapular bursitis: conservative and endoscopic treatment of "snapping scapula" or "washboard syndrome" *Orthop Trans.* 1993;16:740.
14. Conway JE. Arthroscopic repair of partial-thickness rotator cuff tears and SLAP lesions in professional baseball players. *Orthop Clin North Am.* 2001;32:443-456.
15. Cummins CA, Anderson K, Bowen M, Nuber G, Roth SI. Anatomy and histological characteristics of the spinoglenoid ligament. *J Bone Joint Surg Am.* 1998;80:1622-1625.

16. Cummins CA, Messer TM, Nuber GW. Suprascapular nerve entrapment. *J Bone Joint Surg Am.* 2000;82:415-424.
17. Demirhan M, Imhoff AB, Debski RE, Patel PR, Fu FH, Woo SL. The spinoglenoid ligament and its relationship to the suprascapular nerve. *J Shoulder Elbow Surg.* 1998;7:238-243.
18. DiFelice GS, Paletta GA Jr, Phillips BB, Wright RW. Effort thrombosis in the elite throwing athlete. *Am J Sports Med.* 2002;30:708-712.
19. Dillman CJ, Fleisig GS, Andrews JR. Biomechanics of pitching with emphasis upon shoulder kinematics. *J Orthop Sports Phys Ther.* 1993;18:402-408.
20. Donatelli R, Ellenbecker TS, Ekedahl SR, Wilkes JS, Kocher K, Adam J. Assessment of shoulder strength in professional baseball pitchers. *J Orthop Sports Phys Ther.* 2000;30:544-551.
21. Downar JM, Sauers EL. Clinical measures of shoulder mobility in the professional baseball player. *J Athl Train.* 2005;40:23-29.
22. Drez D Jr. Suprascapular neuropathy in the differential diagnosis of rotator cuff injuries. *Am J Sports Med.* 1976;4:43-45.
23. Dunant JH. Effort thrombosis, a complication of thoracic outlet syndrome. *Vasa.* 1981;10:322-324.
24. Ellenbecker TS, Mattalino AJ. Concentric isokinetic shoulder internal and external rotation strength in professional baseball pitchers. *J Orthop Sports Phys Ther.* 1997;25:323-328.
25. Esposito MD, Arrington JA, Blackshear MN, Murtagh FR, Silbiger ML. Thoracic outlet syndrome in a throwing athlete diagnosed with MRI and MRA. *J Magn Reson Imaging.* 1997;7:598-599.
26. Ferretti A, Cerullo G, Russo G. Suprascapular neuropathy in volleyball players. *J Bone Joint Surg Am.* 1987;69:260-263.
27. Fleisig GS, Andrews JR, Dillman CJ, Escamilla RF. Kinetics of baseball pitching with implications about injury mechanisms. *Am J Sports Med.* 1995;23:233-239.
28. Fleisig GS, Barrentine SW, Escamilla RF, Andrews JR. Biomechanics of overhand throwing with implications for injuries. *Sports Med.* 1996;21:421-437.
29. Fleisig GS, Dillman CJ, Andrews JR. Biomechanics of the shoulder during throwing. In: Andrews JR, Wilk KE, eds. *The Athlete's Shoulder.* New York: Churchill Livingstone; 1994:360-365.
30. Fleisig GS, Escamilla RF, Barrentine SW. Biomechanics of pitching: mechanism and motion analysis. In: Andrews JR, Zarins B, Wilk KE, eds. *Injuries in Baseball.* Philadelphia: Lippincott-Raven; 1998:3-22.
31. Foo CL, Swann M. Isolated paralysis of the serratus anterior: a report of 20 cases. *J Bone Joint Surg Br.* 1983;65:552-556.
32. Francel TJ, Dellon AL, Campbell JN. Quadrilateral space syndrome: diagnosis and operative decompression technique. *Plast Reconstr Surg.* 1991;87:911-916.
33. Garth WP Jr, Allman FL Jr, Armstrong WS. Occult anterior subluxations of the shoulder in noncontact sports. *Am J Sports Med.* 1987;15:579-585.
34. Gregg JR, Labosky D, Harty M, et al. Serratus anterior paralysis in the young athlete. *J Bone Joint Surg Am.* 1979;61:825-832.
35. Grossman MG, Tibone JE, McGarry MH, Schneider DJ, Veneziani S, Lee TQ. A cadaveric model of the throwing shoulder: a possible etiology of superior labrum anterior-to-posterior lesions. *J Bone Joint Surg Am.* 2005;87:824-831.
36. Halbrecht JL, Tirman P, Atkin D. Internal impingement of the shoulder: comparison of findings between the throwing and nonthrowing shoulders of college baseball players. *Arthroscopy.* 1999;15:253-258.
37. Hinton RY. Isokinetic evaluation of shoulder rotational strength in high school baseball pitchers. *Am J Sports Med.* 1988;16:274-279.
38. Holzgraefe M, Kukowski B, Eggert S. Prevalence of latent and manifest suprascapular neuropathy in high-performance volleyball players. *Br J Sports Med.* 1994;28:177-179.
39. Hughes ES. Venous obstruction in the upper extremity. Paget-Schroetter's syndrome: a review of 320 cases. *Surg Gynecol Obstet.* 1949;88:89-127.
40. Jackson DL, Farrage J, Hynninen BC, Caborn DN. Suprascapular neuropathy in athletes: case reports. *Clin J Sport Med.* 1995;5:134-136.
41. Jobe CM. Posterior superior glenoid impingement: expanded spectrum. *Arthroscopy.* 1995;11:530-536.
42. Jobe FW, Giangarra CE, Kvitne RS, Glousman RE. Anterior capsulolabral reconstruction of the shoulder in athletes in overhand sports. *Am J Sports Med.* 1991;19:428-434.
43. Jobe FW, Tibone JE, Perry J, Moyness D. An EMG analysis of the shoulder in throwing and pitching: a preliminary report. *Am J Sports Med.* 1983;11:3-5.
44. Kibler WB. The role of the scapula in athletic shoulder function. *Am J Sports Med.* 1998;26:325-337.
45. King J, Brelsford HJ, Tullos HS. Analysis of the pitching arm of the professional baseball pitcher. *Clin Orthop Relat Res.* 1969;67:116-123.
46. Kopell HP, Thompson WA. Pain and the frozen shoulder. *Surg Gynecol Obstet.* 1959;109:92-96.
47. Kuhn JE, Plancher KD, Hawkins RJ. Symptomatic scapulothoracic crepitus and bursitis. *J Am Acad Orthop Surg.* 1998;6:267-273.
48. Kvitne RS, Jobe FW. The diagnosis and treatment of anterior instability in the throwing athlete. *Clin Orthop Relat Res.* 1993;291:107-123.
49. Leffert RD. Thoracic outlet syndrome. *J Am Acad Orthop Surg.* 1994;2:317-325.
50. Leffert RD, Perlmutter GS. Thoracic outlet syndrome: results of 282 transaxillary first rib resections. *Clin Orthop Relat Res.* 1999;368:66-79.
51. Lester B, Jeong GK, Weiland AJ, Wickiewicz TL. Quadrilateral space syndrome: diagnosis, pathology, and treatment. *Am J Orthop.* 1999;28:718-722.
52. Ludewig PM, Cook TM. Alterations in shoulder kinematics and associated muscle activity in people with symptoms of shoulder impingement. *Phys Ther.* 2000;80:276-291.
53. Lukasiewicz AC, McClure P, Michener L, Pratt N, Sennett B. Comparison of 3-dimensional scapular position and orientation between subjects with and without shoulder impingement. *J Orthop Sports Phys Ther.* 1999;29:574-586.
54. Machleder HI. Evaluation of a new treatment strategy for Paget-Schroetter syndrome: spontaneous thrombosis of the axillary-subclavian vein. *J Vasc Surg.* 1993;17:305-317.
55. Matsen FA 3rd, Harryman DT 2nd, Sidles JA. Mechanics of glenohumeral instability. *Clin Sports Med.* 1991;10:783-788.
56. Mazoue CG, Andrews JR. Repair of full-thickness rotator cuff tears in professional baseball players. *Am J Sports Med.* 2006;34:182-189.
57. McCarthy WJ, Yao JS, Schafer MF, et al. Upper extremity arterial injury in athletes. *J Vasc Surg.* 1989;9:317-327.
58. McCluskey GM III, Bigliani LU. Scapulothoracic disorders. In: Andrews JR, Wilk KE, eds. *The Athlete's Shoulder.* New York: Churchill Livingstone; 1994:305-315.
59. McGough EC, Pearce MB, Byrne JP. Management of thoracic outlet syndrome. *J Thorac Cardiovasc Surg.* 1979;77:169-174.
60. Meister K. Injuries to the shoulder in the throwing athlete: part one, biomechanics/pathophysiology/classification of injury. *Am J Sports Med.* 2000;28:265-275.
61. Meister K. Injuries to the shoulder in the throwing athlete: part two, evaluation/treatment. *Am J Sports Med.* 2000;28:587-601.
62. Morgan CD, Burkhart SS, Palmeri M, Gillespie M. Type II SLAP lesions: three subtypes and their relationships to superior instability and rotator cuff tears. *Arthroscopy.* 1998;14:553-565.
63. Myers JB, Laudner KG, Pasquale MR, Bradley JP, Lephart SM. Scapular position and orientation in throwing athletes. *Am J Sports Med.* 2005;33:263-271.
64. Newsham KR, Keith CS, Saunders JE, Goffinett AS. Isokinetic profile of baseball pitchers' internal/external rotation 180, 300, 450 degrees/s. *Med Sci Sports Exerc.* 1998;30:1489-1495.
65. O'Brien SJ, Schwartz RS, Warren RF, Torzilli PA. Capsular restraints to anterior-posterior motion of the abducted shoulder: a biomechanical study. *J Shoulder Elbow Surg.* 1995;4:298-308.
66. Oyama S, Myers JB, Wassinger CA, Ricci RD, Lephart SM. Asymmetric resting scapular posture in healthy overhead athletes. *J Athl Train.* 2008;43:565-570.
67. Radkowski CA, Chhabra A, Baker CL 3rd, Tejwani SG, Bradley JP. Arthroscopic capsulolabral repair for posterior shoulder instability in throwing athletes compared with nonthrowing athletes. *Am J Sports Med.* 2008;36:693-699.

68. Rohrer MJ, Cardullo PA, Pappas AM, Phillips DA, Wheeler HB. Axillary artery compression and thrombosis in throwing athletes. *J Vasc Surg.* 1990;11:761-769.
69. Roos DB. Congenital anomalies associated with thoracic outlet syndrome: anatomy, symptoms, diagnosis, and treatment. *Am J Surg.* 1976;132:771-778.
70. Safran MR. Nerve injury about the shoulder in athletes: part 1, suprascapular nerve and axillary nerve. *Am J Sports Med.* 2004;32:803-819.
71. Safran MR. Nerve injury about the shoulder in athletes: part 2, long thoracic nerve, spinal accessory nerve, burners/stingers, thoracic outlet syndrome. *Am J Sports Med.* 2004;32:1063-1076.
72. Sanders RJ, Hammond SL. Management of cervical ribs and anomalous first ribs causing neurogenic thoracic outlet syndrome. *J Vasc Surg.* 2002;36:51-56.
73. Sandow MJ, Ilic J. Suprascapular nerve rotator cuff compression syndrome in volleyball players. *J Shoulder Elbow Surg.* 1998;7:516-521.
74. Sheeran SR, Hallisey MJ, Murphy TP, Faberman RS, Sherman S. Local thrombolytic therapy as part of a multidisciplinary approach to acute axillosubclavian vein thrombosis (Paget-Schroetter syndrome). *J Vasc Interv Radiol.* 1997;8:253-260.
75. Sisto DJ, Jobe FW. The operative treatment of scapulothoracic bursitis in professional pitchers. *Am J Sports Med.* 1986;14:192-194.
76. Sotta RP. Vascular problems in the proximal upper extremity. *Clin Sports Med.* 1990;9:379-388.
77. Thompson WA, Kopell HP. Peripheral entrapment neuropathies of the upper extremity. *N Engl J Med.* 1959;260:1261-1265.
78. Tibone JE, Jobe FW, Kerlan RK, et al. Shoulder impingement syndrome in athletes treated by an anterior acromioplasty. *Clin Orthop Relat Res.* 1985 ;198:134-140.
79. Toby ED, Koman LA. Thoracic outlet compression syndrome. In: Szabo RM, ed. *Nerve Compression Syndromes: Diagnosis and Treatment.* Thorofare, NJ: Slack Publishers; 1989:209-226.
80. Todd GJ, Benvenisty AI, Hershon S, Bigliani LU. Aneurysms of the mid axillary artery in major league baseball pitchers—a report of two cases. *J Vasc Surg.* 1998;28:702-707.
81. Trakis JE, McHugh MP, Caracciolo PA, Busciacco L, Mullaney M, Nicholas SJ. Muscle Strength and range of motion in adolescent pitchers with throwing-related pain: implications for injury prevention. *Am J Sports Med.* 2008;36:2173-2178.
82. Tullos HS, Erwin WD, Woods GW, Wukasch DC, Cooley DA, King JW. Unusual lesions of the pitching arm. *Clin Orthop Relat Res.* 1972;88:169-182.
83. Urschel HC Jr, Razzuk MA. Paget-Schroetter syndrome: what is the best management? *Ann Thorac Surg.* 2000;69:1663-1669.
84. Wilk KE, Meister K, Andrews JR. Current concepts in the rehabilitation of the overhead throwing athlete. *Am J Sports Med.* 2002;30:136-151.
85. Wright I. The neurovascular syndrome produced by hyperabduction of the arms. *Am Heart J.* 1945;29:1-19.
86. Zarins B, Luallin SR. Rotator cuff and impingement. In: Andrews JR, Zarins B, Wilk KE, eds. *Injuries in Baseball.* Philadelphia: Lippincott-Raven; 1998:87-101.