

# En-masse retraction with a preformed nickel-titanium and stainless steel archwire assembly and temporary skeletal anchorage devices without posterior bonding

Jeong-Hyun Jee<sup>a</sup>  
Hyo-Won Ahn<sup>b</sup>  
Kyung-Won Seo<sup>b</sup>  
Seong-Hun Kim<sup>b</sup>  
Yoon-Ah Kook<sup>a</sup>  
Kyu-Rhim Chung<sup>c</sup>  
Gerald Nelson<sup>d</sup>

<sup>a</sup>Department of Orthodontics,  
Postgraduate School of Dentistry,  
The Catholic University of Korea,  
Seoul, Korea

<sup>b</sup>Department of Orthodontics, School  
of Dentistry, Kyung Hee University,  
Seoul, Korea

<sup>c</sup>Department of Orthodontics, Ajou  
University School of Medicine, Suwon,  
Korea

<sup>d</sup>Division of Orthodontics, Department  
of Orofacial Science, University of  
California, San Francisco, CA, USA

**Objective:** To evaluate the therapeutic effects of a preformed assembly of nickel-titanium (NiTi) and stainless steel (SS) archwires (preformed C-wire) combined with temporary skeletal anchorage devices (TSADs) as the sole source of anchorage and to compare these effects with those of a SS version of C-wire (conventional C-wire) for *en-masse* retraction. **Methods:** Thirty-one adult female patients with skeletal Class I or II dentoalveolar protrusion, mild-to-moderate anterior crowding (3.0–6.0 mm), and stable Class I posterior occlusion were divided into conventional (n = 15) and preformed (n = 16) C-wire groups. All subjects underwent first premolar extractions and *en-masse* retraction with pre-adjusted edgewise anterior brackets, the assigned C-wire, and maxillary C-tubes or C-implants; bonded mesh-tube appliances were used in the mandibular dentition. Differences in pretreatment and post-retraction measurements of skeletal, dental, and soft-tissue cephalometric variables were statistically analyzed. **Results:** Both groups showed full retraction of the maxillary anterior teeth by controlled tipping and space closure without altered posterior occlusion. However, the preformed C-wire group had a shorter retraction period (by 3.2 months). Furthermore, the maxillary molars in this group showed no significant mesialization, mesial tipping, or extrusion; some mesialization and mesial tipping occurred in the conventional C-wire group. **Conclusions:** Preformed C-wires combined with maxillary TSADs enable simultaneous leveling and space closure from the beginning of the treatment without maxillary posterior bonding. This allows for faster treatment of dentoalveolar protrusion without unwanted side effects, when compared with conventional C-wire, evidencing its clinical expediency.

[Korean J Orthod 2014;44(5):236-245]

**Key words:** Anchorage, Orthodontic mini-implant, Tooth movement, Orthodontic treatment

Received October 9, 2013; Revised November 13, 2013; Accepted December 17, 2013.

**Corresponding author:** Seong-Hun Kim.

Associate Professor and Chairman, Department of Orthodontics, School of Dentistry, Kyung Hee University, 26 Kyungheedae-ro, Dongdaemun-gu, Seoul 130-701, Korea.  
Tel +82-2-958-9392 e-mail bravortho@gmail.com

Jeong-Hyun Jee and Hyo-Won Ahn contributed equally to this work.

\*This study is based on a thesis (J.J.H) completed at the Catholic University of Korea.

\*\*The work was supported by the National Research Foundation of Korea (NRF) and funded by the Korean Ministry of Science and Technology (MEST) (No. 2012R1A5A2051388).

The authors report no commercial, proprietary, or financial interest in the products or companies described in this article.

© 2014 The Korean Association of Orthodontists.

This is an Open Access article distributed under the terms of the Creative Commons Attribution Non-Commercial License (<http://creativecommons.org/licenses/by-nc/3.0>) which permits unrestricted non-commercial use, distribution, and reproduction in any medium, provided the original work is properly cited.

## INTRODUCTION

Anchorage control is essential for a good outcome in extraction cases. The most challenging situation is to achieve *en-masse* retraction with minimal or no anchorage loss.<sup>1,2</sup> Conventional anchorage techniques include headgears, transpalatal arches, and Nance buttons combined with full-arch bonding. More recently, temporary skeletal anchorage devices (TSADs) were introduced for biomechanical therapy.<sup>3-7</sup> TSADs are commonly used in contemporary orthodontics, but can exhibit failure and weakness when multidirectional or heavy forces are applied.

In many cases of dentoalveolar protrusion, patients have Class I molar relationships with good interdigitation of the posterior teeth. Once brackets are bonded, the occlusion is inevitably altered and requires further correction. The periodontal challenge to posterior teeth should also not be overlooked. In 2007, Chung et al.<sup>8</sup> proposed an approach to TSAD-dependent *en-masse* retraction (biocreative orthodontics). In their protocol, the maxillary anterior teeth are retracted *en-masse*, but no orthodontic appliances are attached to the posterior teeth during retraction.<sup>8,9</sup> This concept evolved after the development of the C-implant, because a partially osseointegrated mini-implant or miniplate can easily endure multidirectional or heavy forces applied by archwires and springs.<sup>7-11</sup>

Although the biocreative therapy using conventional

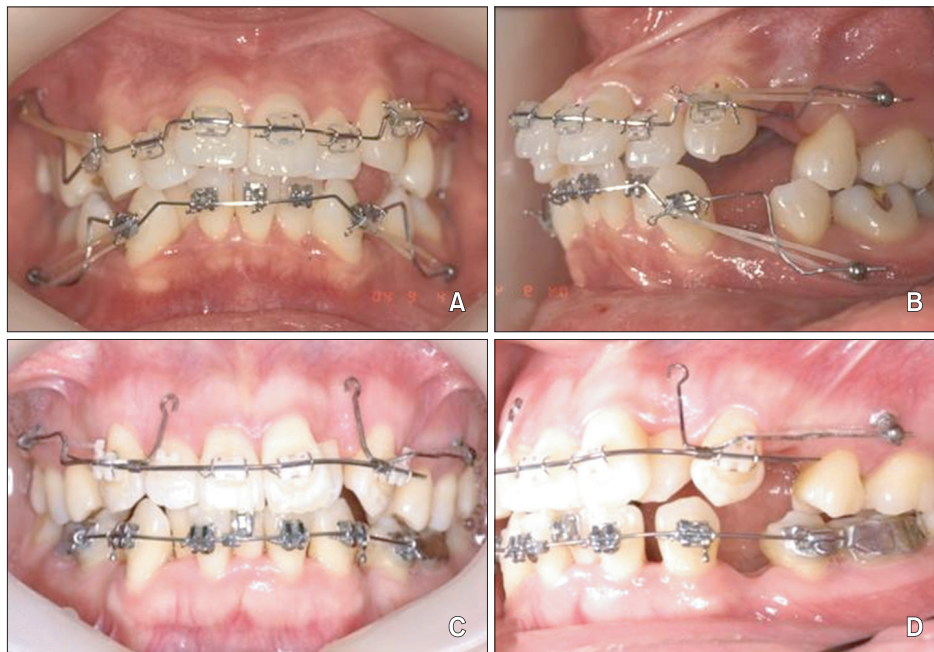
C-wires has many advantages, such as low friction, reduced periodontal challenges to the posterior teeth, and no impact on normal posterior occlusions, extra training regarding the placement of steps and bends in the stainless steel (SS) archwires may be required of clinicians to properly engage crowded and unlevelled anterior teeth (Figure 1A and 1B).<sup>12,13</sup> The high load-deflection rate of conventional C-wires necessitates regular and sometimes tedious archwire adjustments at each visit, increasing chairside time. To overcome these shortcomings, we designed a preformed assembly of nickel-titanium (NiTi) and SS archwires (preformed C-wire; Figure 1C and 1D).

The aim of this retrospective study was to evaluate the therapeutic effects of preformed C-wires combined with TSADs as the sole source of anchorage and to compare these effects against those of conventional C-wires for *en-masse* retraction. The null hypothesis was that the two archwire systems would show no differences in therapeutic effects.

## MATERIALS AND METHODS

### Patients

Thirty-one female patients with skeletal Class I or II dentoalveolar protrusion, mild-to-moderate anterior crowding (3.0–6.0 mm), and stable Class I posterior occlusions were divided into conventional C-wire (n = 15; mean age = 20.0 ± 3.3 years) and preformed C-wire



**Figure 1.** Temporary skeletal anchorage device-dependent *en-masse* retraction mechanics. A and B, Biocreative therapy with conventional C-wires; note the bends and steps in the archwire. C and D, Biocreative therapy with preformed C-wires.

( $n = 16$ ; mean age =  $21.5 \pm 3.6$  years) groups. The patients underwent extraction of all the first premolars. Then, one orthodontist (J.J.H) retracted the maxillary anterior teeth *en-masse* using 0.022-inch-slot preadjusted edgewise anterior brackets, the assigned C-wire, and maxillary TSADs; no appliances were bonded to the maxillary posterior teeth during retraction. The retraction distance and number of clinical visits were controlled between groups. This study was reviewed and approved by the Institutional Review Board of The Catholic University of Korea, Seoul St. Mary's Hospital (KIRB-00384-20-008).

### Maxillary appliances

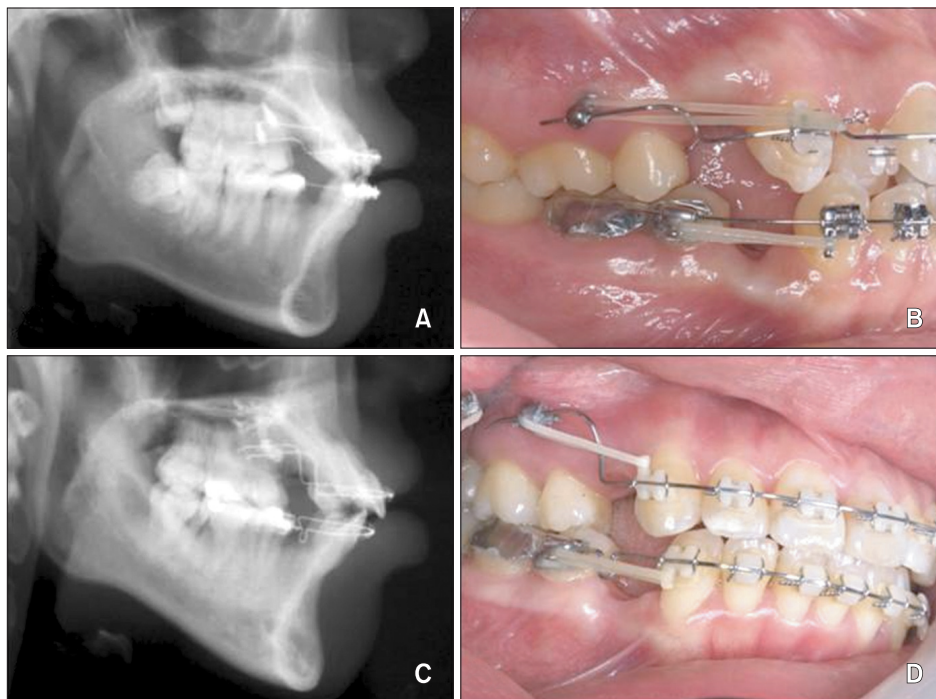
Two-component C-implants (Cimplant Co., Seoul, Korea) or C-tubes (Jin Biomed Co., Bucheon, Korea) were used for direct anchorage (Figure 2). The C-implant (1.8 mm in diameter and 8.5 mm in length) is a sandblasted, large-grit, acid-etched mini-implant. The C-tube is a miniplate with an extended arm that includes an adjustable tube to accept a wire. The TSADs were placed at the beginning of the treatment for simultaneous leveling and space closure. The C-implants were placed in the maxillary interseptal bone between the second premolars and the first molars bilaterally. If C-tubes were used, the fixation screws were located more apically, and the heads of C-tubes were placed in the same vertical level as that of C-implants.

Preformed C-wires have two components, as shown in

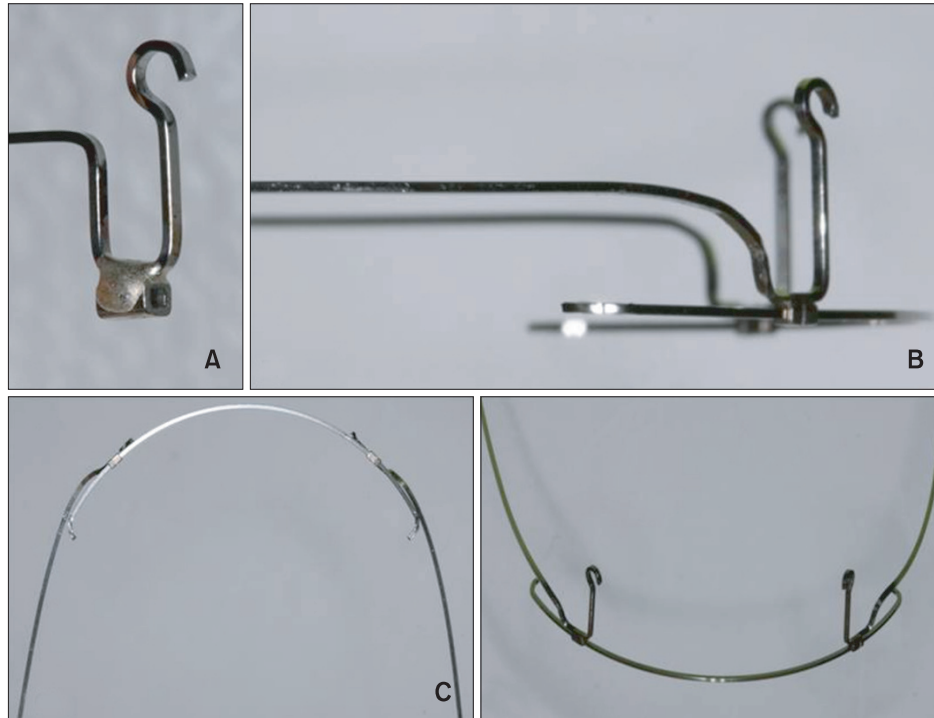
Figure 3. One component is the NiTi archwire, designed to engage the maxillary anterior teeth (canine to canine). In this study, we used 0.016 × 0.022-inch superelastic NiTi archwires without built in torque (BioTorque; Forestadent Bernhard Förster GmbH, Pforzheim, Germany), which can be easily ligated to crowded teeth. The other component consisted of 0.017 × 0.025-inch SS archwires with retraction hooks. Furthermore, 0.022-inch crimpable inside diameter tubes were soldered to the SS archwire and the NiTi archwire was inserted into the tubes. We positioned the tubes on the NiTi archwire between the lateral incisors and the canines bilaterally and crimped them firmly in place. The SS archwire was then inserted into the TSADs, creating a rigid sliding section with a built in power arm. The archwire did not need to be bent for vertical correction of high canines during retraction. During the initial alignment, 2.5-oz elastics or elastic chains delivering 0.7 N of force were applied to the canines. The canines were retracted while the incisors were aligned. Once all the anterior teeth were aligned with the archwire, closed-coil NiTi springs (1.2 N) or 4.5-oz elastics were used for *en-masse* retraction.

### Mandibular appliances

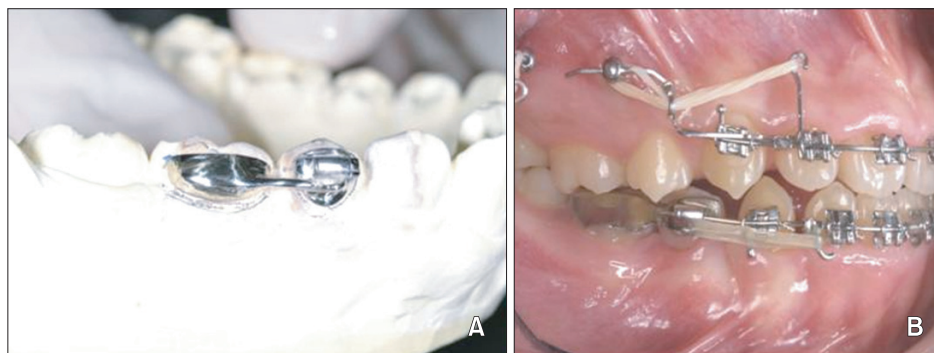
Bonded mesh-tube appliances (BMTAs), comprising 0.022-inch buccal tubes on the mandibular second premolars and metal mesh on the mandibular first molars, were used bilaterally for anchorage reinforce-



**Figure 2.** Temporary skeletal anchorage devices used in this study. A and B, Two-component C-implants. C and D, C-tubes.



**Figure 3.** Preformed C-wire fabrication. A, Bending of stainless steel (SS) archwire for the retraction hooks and soldering of the crimpable stop tubes. B, Insertion of nickel-titanium archwire into the tubes and contouring of the hooks for passive sliding according to the height of the C-tubes. C, Contouring of the remaining SS section. D, Final configuration of preformed C-wire.



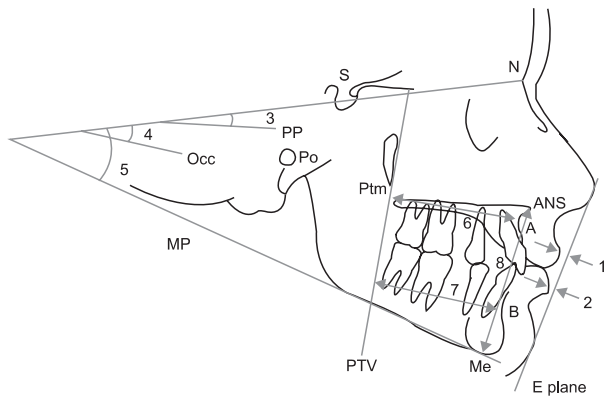
**Figure 4.** (A) Bonded mesh-tube appliance (BMTA) on the mandibular arch. The BMTA is comprised of a 0.022-inch single tube on the mandibular second premolar connected to metal mesh on the mandibular first molar (B).

ment and maintenance of normal posterior occlusion in the preformed C-wire group (Figure 4). During leveling, 0.018-inch reverse curve NiTi archwires and Class III elastics attached to the TSADs were used to prevent mesial tipping of the mandibular molars. During retraction, bilateral Class I elastics were used between the canines and the hooks of the BMTAs. After space closure, short-term fixed appliances, tooth positioners, or clear aligners were used for finishing. In the

conventional C-wire group, conventional brackets were bonded to the mandibular dentition and space closure was performed with power chains.

#### Data collection

Lateral cephalograms were obtained before treatment (pretreatment) and after space closure (post-retraction). Soft tissue, skeletal, and dental variables were measured as previously described (Figures 5 and 6).<sup>11</sup> In particular,



**Figure 5.** Soft tissue and skeletal cephalometric measurements. 1, Upper lip to E-line (UL to E-line); 2, lower lip to E-line (LL to E-line); 3, sella-nasion to palatal plane angle (SN-PP); 4, SN to anatomic occlusal plane angle (SN-Occ); 5, SN to mandibular plane angle (SN-MP); 6, pterygoid vertical plane to A point distance (PTV-A); 7, pterygoid vertical plane to B point distance (PTV-B); 8, lower anterior facial height (anterior nasal spine to menton; ANS-Me).

lip protrusion, vertical or horizontal skeletal pattern, and positional changes of the first molars and central incisors were assessed.

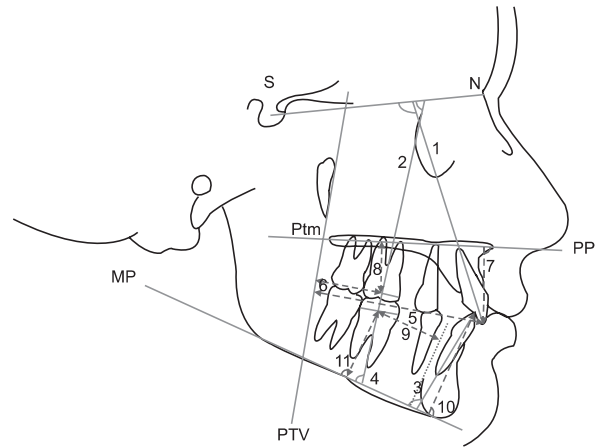
### Statistics

The means and standard deviations of 19 cephalometric variables were calculated. To evaluate tracing and measurement errors, all variables were re-measured after 3 weeks. Agreement was quantified by calculating intraclass correlation coefficients (ICCs); ICCs greater than 0.95 indicated reliable measurements. Normal distribution was confirmed by using the Shapiro-Wilk test ( $p > 0.05$ ). Intragroup pretreatment and post-retraction data were compared using the paired *t*-test, and the pretreatment data and amount of change between the groups were analyzed with the independent *t*-test.  $p < 0.05$  was used to indicate a significant difference.

## RESULTS

Figures 7, 8 and 9 depict progress from the beginning of treatment to space closure in a 23-yr-old patient from the preformed C-wire group; her chief complaint was protrusive lips and crowded teeth. We used C-tubes designed for SS archwire insertion in the maxillary posterior region to achieve direct skeletal anchorage. Mandibular anchorage was reinforced with the BMTAs during retraction. Crowding was controlled along with retraction of the maxillary anterior teeth.

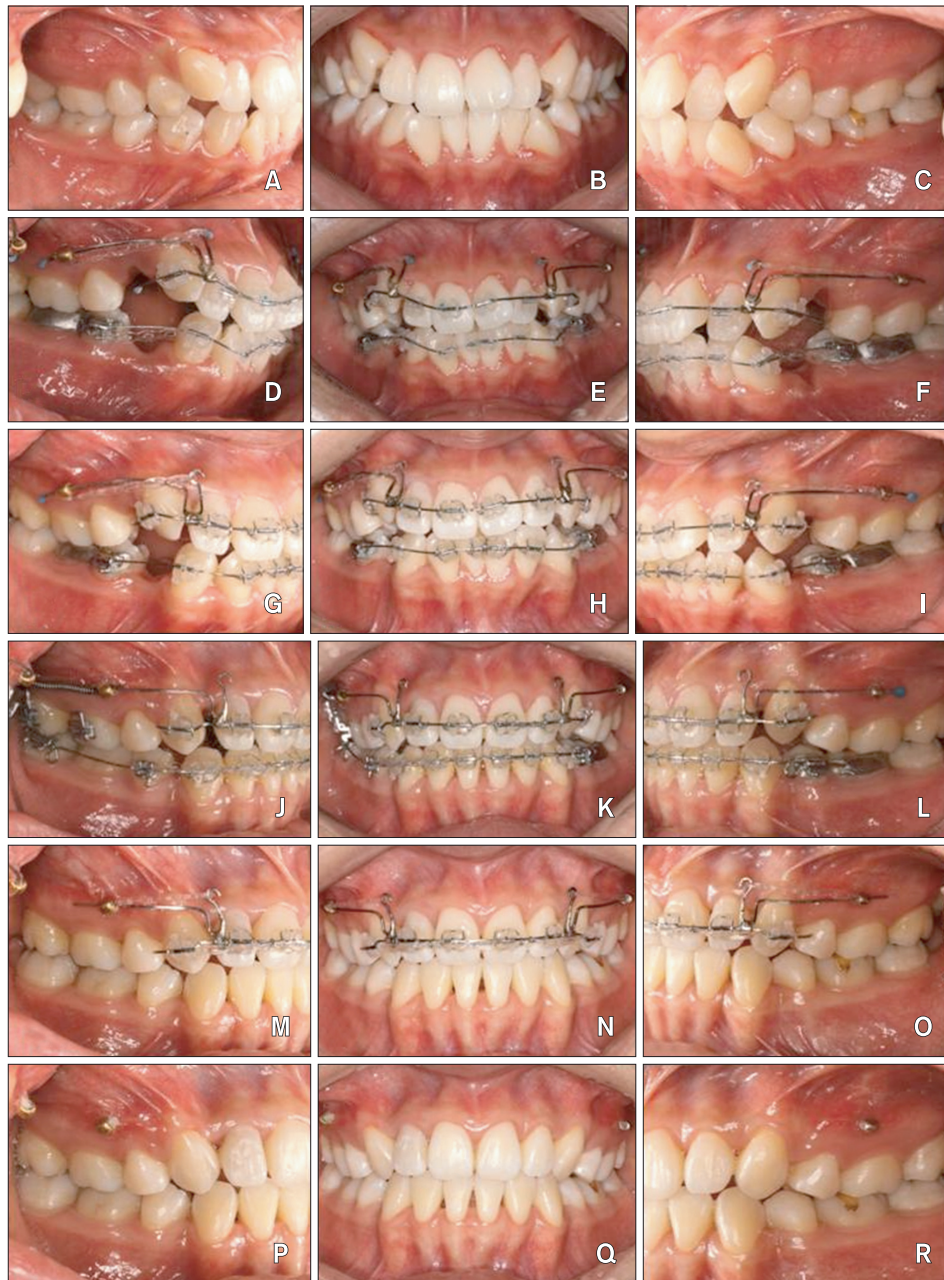No failure of the TSADs was observed in either group



**Figure 6.** Dental cephalometric measurements. 1, Sella-nasion to maxillary incisor angle (SN-U1); 2, SN to maxillary first molar angle (SN-U6); 3, mandibular plane to mandibular incisor angle (MP-L1); 4, mandibular plane to mandibular first molar angle (MP-L6); 5, pterygoid vertical plane to maxillary incisor tip distance (PTV-U1); 6, pterygoid vertical plane to maxillary first molar centroid distance (PTV-U6); 7, palatal plane to maxillary incisor tip distance (PP-U1); 8, palatal plane to maxillary first molar centroid distance (PP-U6); 9, mandibular lingual cortex to mandibular first molar centroid distance (LC-L6); 10, mandibular plane to mandibular incisor tip distance (MP-L1v); 11, mandibular plane to mandibular first molar centroid distance (MP-L6v).

during treatment. In the conventional C-wire group, the mean retraction period was  $13.44 \pm 4.30$  months and the mean overall treatment time was  $23.45 \pm 4.31$  months; these periods were shortened by 3.2 and 2.5 months, respectively, in the preformed C-wire group.

The groups did not show significant differences in anteroposterior and vertical skeletal patterns and inclination of anterior teeth before treatment (Table 1), except LC-L6 ( $p < 0.01$ , data not shown). The maxillary anterior teeth were fully retracted to close the extraction spaces (PTV-U1,  $p < 0.001$  for both groups). Uprighting of the maxillary anterior teeth by controlled tipping was observed (SN-U1:  $p < 0.001$  for the conventional C-wire group;  $p < 0.01$  for the preformed C-wire group). The maxillary molars in the preformed C-wire group showed no significant mesialization, mesial tipping, or extrusion. However, some mesialization and mesial tipping of the maxillary molars was observed in the conventional C-wire group (PTV-U6,  $p < 0.001$ ; SN-U6,  $p < 0.05$ ). Linguoversion of the mandibular anterior teeth was obvious in both groups (MP-L1,  $p < 0.001$ ), but mesialization and mesial tipping of the mandibular molars were significant only in the conventional C-wire group (MP-L6,  $p < 0.01$ ; LC-L6,  $p < 0.001$ ). Furthermore,

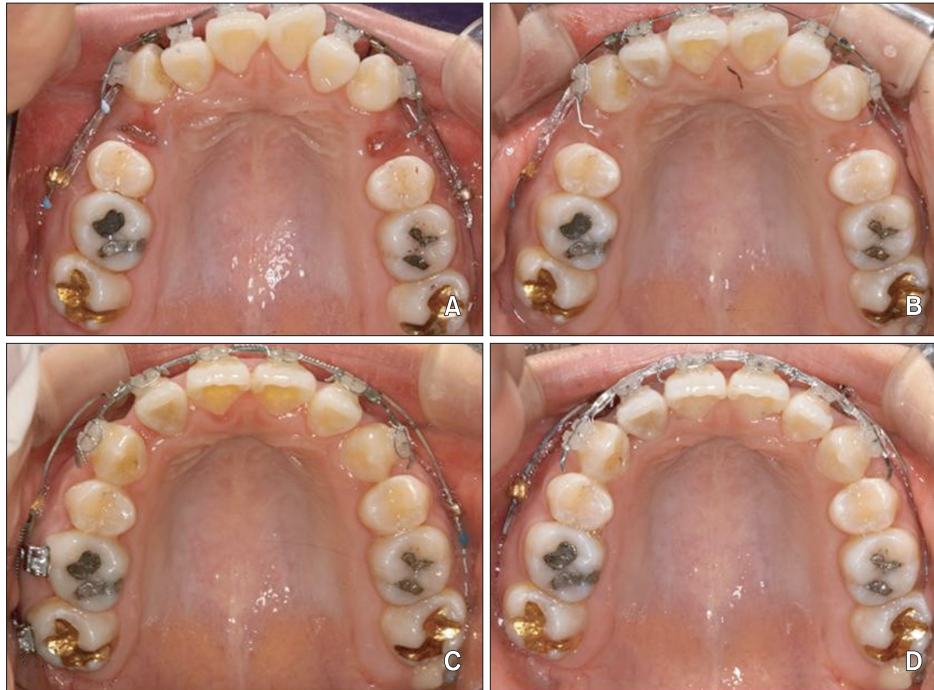

**Figure 7.** Therapeutic progress with one preformed C-wire. A to C, Pretreatment. D to F, Immediately after bonding. G to I, Three months after treatment. J to L, Nine months after treatment. M to O, Fifteen months after treatment. P to R, Posttreatment (nineteen month after treatment).

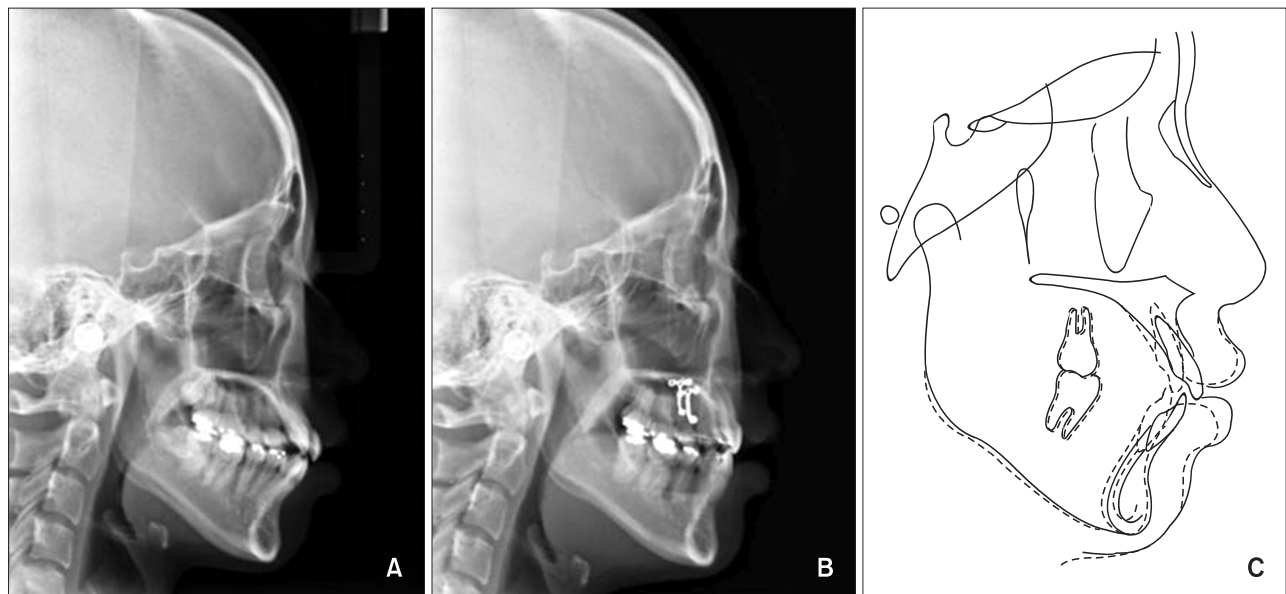
slight extrusion of the mandibular teeth was observed in both groups (MP-L1v and MP-L6v,  $p < 0.01$  for the conventional C-wire group; MP-L6v,  $p < 0.05$  for the preformed C-wire group), except in the anterior region in the preformed C-wire group.

In the skeletal analysis, A and B points remodeled posteriorly because of retraction of the anterior teeth; the change was significant only at A point (PTV-A,  $p < 0.05$ ) in the preformed C-wire group and B point

(PTV-B,  $p < 0.01$ ) in the conventional C-wire group. No significant vertical skeletal change was noted in both groups despite slight extrusion of the mandibular molars. With regard to the soft-tissue changes, the upper and lower lips moved posteriorly (UL to E-line and LL to E-line,  $p < 0.001$  for both groups). No significant intergroup difference was observed except for the change in mandibular incisor angulation (Table 1).



**Figure 8.** Occlusal views showing relief of crowding and retraction of the maxillary anterior teeth. A, Immediately after bonding. B, Three months after bonding. C, Nine months after bonding. D, Fifteen months after bonding.



**Figure 9.** Lateral cephalograms and superimposed tracings. A, Pretreatment lateral cephalogram. B, Post-retraction lateral cephalogram. C, Superimposition of the pretreatment (solid line) and post-retraction (dotted line) tracings.

## DISCUSSION

Various protocols using different wires and brackets have been developed to control tooth movements, such

as biometric and bidimensional systems.<sup>14,15</sup> These systems concern posterior “play” and three-dimensional control of anterior teeth during space closure.<sup>13</sup> Preformed C-wires are an effective option for posterior

**Table 1.** Comparison of the variables before treatment (T0) and after retraction (T1) in each group and intergroup comparison of the variables at T0 and mean differences between groups

	Intra-group comparison between T0 and T1*						p-value <sup>†</sup>	
	Conventional C-wire (n = 15)			Preformed C-wire (n = 16)			Comparison between groups at T0	Comparison of the difference between groups
	T0	T1	p-value	T0	T1	p-value		
<b>Soft tissue</b>								
UL to E line	2.57 ± 1.53	0.53 ± 2.18	0.0000 <sup>  </sup>	2.59 ± 1.76	0.94 ± 1.26	0.0001 <sup>  </sup>	0.9729	0.3870
LL to E line	5.93 ± 2.54	2.73 ± 1.57	0.0001 <sup>  </sup>	5.03 ± 2.22	2.22 ± 1.64	0.0001 <sup>  </sup>	0.3041	0.6732
<b>Skeletal</b>								
SN-PP	10.20 ± 3.24	10.03 ± 3.35	0.7012	11.63 ± 2.20	10.72 ± 3.14	0.1489	0.1600	0.3364
SN-Occ	19.75 ± 3.53	20.13 ± 4.17	0.6379	21.44 ± 5.01	21.66 ± 5.70	0.8222	0.2913	0.6370
SN-Mn	39.69 ± 4.59	40.20 ± 4.75	0.0903	42.50 ± 7.22	41.56 ± 7.64	0.1863	0.2099	0.0625
PTV-A	50.41 ± 4.59	49.91 ± 4.28	0.1014	51.66 ± 3.23	50.13 ± 3.45	0.0112 <sup>‡</sup>	0.3854	0.0969
PTV-B	42.65 ± 6.91	41.77 ± 6.98	0.0045 <sup>§</sup>	41.56 ± 3.02	40.47 ± 3.46	0.0670	0.5823	0.7220
ANS-Me	78.43 ± 3.76	79.07 ± 3.53	0.2220	75.66 ± 5.76	75.80 ± 6.09	0.4781	0.5525	0.5708
<b>Dental angular</b>								
SN-U1	109.22 ± 5.45	95.45 ± 5.88	0.0000 <sup>  </sup>	106.09 ± 8.20	95.59 ± 9.88	0.0030 <sup>§</sup>	0.9102	0.7423
SN-U6	68.47 ± 5.84	71.06 ± 6.10	0.0450 <sup>‡</sup>	66.00 ± 4.95	67.44 ± 5.18	0.1172	0.3128	0.6073
MP-L1	99.47 ± 3.72	88.83 ± 4.68	0.0000 <sup>  </sup>	96.47 ± 5.51	89.88 ± 6.76	0.0004 <sup>  </sup>	0.0619	0.0235 <sup>‡</sup>
MP-L6	74.79 ± 4.34	70.45 ± 6.31	0.0036 <sup>§</sup>	79.13 ± 5.29	76.50 ± 6.60	0.1599	0.9420	0.5391
<b>Dental linear</b>								
PTV-U1	58.86 ± 4.90	52.02 ± 5.57	0.0000 <sup>  </sup>	58.69 ± 4.17	51.53 ± 4.49	0.0000 <sup>  </sup>	0.8808	0.1700
PTV-U6	21.47 ± 3.74	23.80 ± 4.24	0.0001 <sup>  </sup>	21.03 ± 2.84	21.41 ± 3.50	0.6332	0.3470	0.6728
PP-U1	32.73 ± 2.83	33.55 ± 2.34	0.0847	32.16 ± 2.39	32.72 ± 2.86	0.2009	0.5054	0.3162
PP-U6	22.07 ± 1.96	22.79 ± 1.42	0.0819	23.59 ± 4.05	24.04 ± 3.94	0.0859	0.3181	0.6779
LC-L6	15.21 ± 3.00	13.21 ± 3.08	0.0000 <sup>  </sup>	18.56 ± 3.08	17.34 ± 4.40	0.1365	0.0068 <sup>§</sup>	0.2871
MP-L1v	48.79 ± 2.28	47.17 ± 2.21	0.0027 <sup>§</sup>	46.44 ± 3.21	45.53 ± 3.94	0.0306 <sup>‡</sup>	0.2140	0.8898
MP-L6v	34.79 ± 2.08	36.15 ± 1.81	0.0025 <sup>§</sup>	32.47 ± 4.01	33.69 ± 3.41	0.0282 <sup>‡</sup>	0.1618	0.3469

Values are presented as mean ± standard deviation. Paired *t*-test\* and independent *t*-test<sup>†</sup> were done for statistical analysis. <sup>‡</sup>*p* < 0.05; <sup>§</sup>*p* < 0.01; <sup>||</sup>*p* < 0.001. Refer to Figures 5 and 6 for the definitions of each measurement.

sliding mechanics and good torque control of anterior teeth while applying light alignment forces.

In this study, the null hypothesis was proved; preformed C-wires yielded similar therapeutic outcomes to conventional C-wires during retraction. However, preformed C-wires enabled initiation of leveling and space closure on the same day as bracket placement and maintenance of one archwire until the extraction spaces were fully closed, in contrast to the three or four archwires typically required to align teeth (6–9 months) before initiating retraction or space closure.<sup>15</sup> In anterior crowding, selective or loose ligation of crowded

teeth (especially the lateral incisors) and retraction of the canines with light elastics are initiated first until all of the anterior teeth are engaged on the archwire. The preformed C-wire technique with minimum retraction force reduced the risk of root resorption of the lateral incisors and as well as distal tipping of the canines. During alignment, proclination or round-tripping of crowded incisors was prevented with light elastic chains or ligature wire from the retraction hooks to the TSADs. *En-masse* retraction with elastics or springs from the TSADs to the retraction hooks was then performed to close the remaining extraction spaces.



Several factors influence the choice of archwire progression, such as personal preference, cost, and wire characteristics for ideal force generation. Clinicians typically use smaller round wires to generate lighter forces during the preliminary alignment stage. Rectangular superelastic NiTi archwires offer an interesting advantage. Flexural rigidity dependence on cross-sectional dimension differs from linear elasticity prediction because of martensitic transformation.<sup>16,17</sup> The rigidity decreases with increasing deflection, and this phenomenon is accentuated in the unloading process. With NiTi alloys, flexural rigidity is not constant and the influence of size is not as important as might be expected.<sup>16,17</sup> Therefore, in some cases, treatment can begin with rectangular wires that nearly fill the bracket slot and still deliver a force deemed to be physiologically desirable for tooth movement and compatible with patient comfort. This is the basis for using rectangular NiTi archwires as the anterior component of preformed C-wires as they offer simultaneous alignment, leveling, and torque from the beginning of treatment.

Torque control of the anterior segment is important during space closure. Torque loss of the anterior teeth and intrusion of the canines can easily occur in the sectional retraction approach. While developing the preformed C-wires, we first tried using only NiTi archwires on the anterior teeth and through the holes in the TSADs. However, the result was vertical bowing and bite deepening.<sup>18</sup> Use of pretorqued NiTi archwires (30–45°) in the anterior section of the assembly caused labial flaring of the canines. Subsequently, we combined the non-torqued NiTi section with SS archwires for improved control of canine movements.

The vector of the retraction force (and thus, the moment applied to the anterior segment) can be altered with the height of the retraction hook and/or level of force. We found that a 7- to 10-mm-high retraction hook provides the best torque control. A longer power arm will rotate the anterior segment counterclockwise, extruding the canines.<sup>19,20</sup> To lower the vector of the retraction force from the TSADs to the retraction hooks, crimpable stops can be placed on the retraction hooks at any level. For greater incisor intrusion, we used an overlay occlusal curve NiTi archwire anterior to the TSADs and fixed it to the central incisor area. The C-tube has an adequate hole size (0.032 inches) to accommodate both SS and overlay NiTi archwires.

With regard to the behavior of the posterior teeth during *en-masse* retraction, Kim et al.<sup>11</sup> reported that maxillary and mandibular molars show some mesialization and extrusion with conventional C-wires, which is similar to our results. Use of preformed C-wires did not lead to significant mesial movement or tipping of the maxillary and mandibular molars. The BMTA had a

splinting effect on the posterior teeth, effectively preventing mesialization or mesial tipping of the molars. Occasionally, some extrusion of the mandibular molars and intrusion of the mandibular anterior teeth occurred. This could be attributed to poor cooperation with the Class III elastics while leveling with the 0.018-inch reverse curve NiTi archwires.

Although patient selection was based on specific criteria, further study with a proper randomization and double-blinding process is necessary from the beginning of the experimental design phase. Root resorption of the anterior teeth should also be evaluated accurately by using cone-beam computed tomography.

## CONCLUSION

Preformed C-wires combined with maxillary TSADs enabled maximum retraction of the maxillary anterior teeth and maintenance of physiologic posterior occlusions without mesialization of the molars. It shortened the overall treatment time and allowed for comparatively easy and simultaneous leveling and space closure when compared with conventional C-wires.

## REFERENCES

1. Bennett JC, McLaughlin RP. Controlled space closure with a preadjusted appliance system. *J Clin Orthod* 1990;24:251-60.
2. Klontz HA. Tweed-Merrifield sequential directional force treatment. *Semin Orthod* 1996;2:254-67.
3. Kanomi R. Mini-implant for orthodontic anchorage. *J Clin Orthod* 1997;31:763-7.
4. Yao CC, Lai EH, Chang JZ, Chen I, Chen YJ. Comparison of treatment outcomes between skeletal anchorage and extraoral anchorage in adults with maxillary dentoalveolar protrusion. *Am J Orthod Dentofacial Orthop* 2008;134:615-24.
5. Block MS, Hoffman DR. A new device for absolute anchorage for orthodontics. *Am J Orthod Dentofacial Orthop* 1995;107:251-8.
6. Chung KR, Kim YS, Linton JL, Lee YJ. The miniplate with tube for skeletal anchorage. *J Clin Orthod* 2002;36:407-12.
7. Ahn HW, Chung KR, Kang SM, Lin L, Nelson G, Kim SH. Correction of dental Class III with posterior open bite by simple biomechanics using an anterior C-tube miniplate. *Korean J Orthod* 2012;42:270-8.
8. Chung KR, Cho JH, Kim SH, Kook YA, Cozzani M. Unusual extraction treatment in Class II division 1 using C-orthodontic mini-implants. *Angle Orthod* 2007;77:155-66.
9. Chung KR, Choo H, Lee JH, Kim SH. Atypical orthodontic extraction pattern managed by differential

- en-masse* retraction against a temporary skeletal anchorage device in the treatment of bimaxillary protrusion. *Am J Orthod Dentofacial Orthop* 2011; 140:423-32.
10. Chung KR, Jeong DM, Kim SH, Ko YI, Nelson G. *En-masse* retraction dependent on a temporary skeletal anchorage device without posterior bonding or banding in an adult with severe bidentoalveolar protrusion: seven years posttreatment. *Am J Orthod Dentofacial Orthop* 2012;141:484-94.
  11. Kim SH, Hwang YS, Ferreira A, Chung KR. Analysis of temporary skeletal anchorage devices used for *en-masse* retraction: a preliminary study. *Am J Orthod Dentofacial Orthop* 2009;136:268-76.
  12. Chung KR, Kim SH, Kook YA. C-orthodontic mini-implant. In: Cope JB, ed. *OrthoTADs book: Clinical guideline and atlas*. Dallas, TX: Under Dog Media; 2007. p. 248.
  13. Chung KR, Kim SH, Kook YA. The C-orthodontic micro-implant. *J Clin Orthod* 2004;38:478-86.
  14. Giancotti A, Greco M. Modified sliding mechanics in extraction cases with a bidimensional approach. *Prog Orthod* 2010;11:157-65.
  15. Mandall N, Lowe C, Worthington H, Sandler J, Derwent S, Abdi-Oskouei M, et al. Which orthodontic archwire sequence? A randomized clinical trial. *Eur J Orthod* 2006;28:561-6.
  16. Garrec P, Tavernier B, Jordan L. Evolution of flexural rigidity according to the cross-sectional dimension of a superelastic nickel titanium orthodontic wire. *Eur J Orthod* 2005;27:402-7.
  17. Gurgel JA, Kerr S, Powers JM, LeCrone V. Force-deflection properties of superelastic nickel-titanium archwires. *Am J Orthod Dentofacial Orthop* 2001; 120:378-82.
  18. Sia S, Shibazaki T, Koga Y, Yoshida N. Experimental determination of optimal force system required for control of anterior tooth movement in sliding mechanics. *Am J Orthod Dentofacial Orthop* 2009; 135:36-41.
  19. Mo SS, Kim SH, Sung SJ, Chung KR, Chun YS, Kook YA, et al. Factors controlling anterior torque during C-implant-dependent *en-masse* retraction without posterior appliances. *Am J Orthod Dentofacial Orthop* 2011;140:72-80.
  20. Mo SS, Kim SH, Sung SJ, Chung KR, Chun YS, Kook YA, et al. Factors controlling anterior torque with C-implants depend on *en-masse* retraction without posterior appliances: biocreative therapy type II technique. *Am J Orthod Dentofacial Orthop* 2011;139:e183-91.