


Long-Term Control of Macular Edema With Adalimumab After Cataract Surgery in a Japanese Child With Juvenile Idiopathic Arthritis: Case Report and Review of 26 Japanese Patients

Journal of Investigative Medicine High
Impact Case Reports
Volume 8: 1–10
© 2020 American Federation for
Medical Research
DOI: 10.1177/2324709620953283
journals.sagepub.com/home/hic


Toshihiko Matsuo, MD, PhD^{1,2}  and Masato Yashiro, MD, PhD³

Abstract

Juvenile idiopathic arthritis–associated uveitis is rare in the Japanese population. In this article, we report a child whose macular edema was controlled for years after cataract surgery with adalimumab, and reviewed 26 Japanese patients in the literature. In this case report, a 4-year-old boy developed band keratopathy, posterior iris synechiae, and complicated cataract in both eyes. Oral prednisolone prescribed at another hospital was discontinued due to high intraocular pressure in both eyes as a steroid responder. At the age of 5 years, he started oral methotrexate 8 mg weekly for recurrent bilateral iridocyclitis and then underwent lensectomy with core vitrectomy in both eyes. Planned intraocular lens implantation was cancelled at surgery because the anterior vitreous had severe inflammatory opacity with diffuse retinal edema in both eyes. Due to persistent macular edema in both eyes 5 months postoperatively, at the age of 6 years, he began to use adalimumab injection 20 mg every 2 weeks. The macular structure depicted by optical coherence tomography became normal in 2 months. At final visit at the age of 11 years, he had the best-corrected visual acuity of 0.8 in the right eye and 0.4 in the left eye, with adalimumab 40 mg every 2 weeks and methotrexate 8 mg weekly. In conclusion, macular edema persistent despite oral methotrexate after cataract surgery could be controlled for long term by adalimumab in a child with juvenile idiopathic arthritis. In the Japanese literature, only 26 additional cases with juvenile idiopathic arthritis–associated uveitis have been reported so far.

Keywords

juvenile idiopathic arthritis, JIA, macular edema, uveitis, adalimumab, steroid responder, cataract surgery, methotrexate, literature review, Japanese

Background

Juvenile idiopathic arthritis is relatively common in the Caucasian population but appears to be rare in the Japanese population.^{1–3} Caucasian ethnicity is a risk factor for developing juvenile idiopathic arthritis,¹ but the incidence of juvenile idiopathic arthritis in different populations is yet to be determined. To establish the common ground for the diagnosis, the International League of Associations for Rheumatology (ILAR) has published classification criteria for juvenile idiopathic arthritis.⁴ Recently, the Pediatric Rheumatology Association of Japan (PRAJ) has surveyed the prevalence of uveitis as 6.1% in Japanese patients with the diagnosis of juvenile idiopathic arthritis, based on the ILAR classification criteria.⁵ The prevalence of juvenile idiopathic arthritis–associated uveitis in the Japanese population is at the lower end of the prevalence in the other populations (4.7% to 20.5%).⁵

In the field of ophthalmology, band keratopathy, posterior iris synechiae, and complicated cataract in both eyes have

been described in textbooks as hallmark features of uveitis in children with juvenile idiopathic arthritis.^{6–8} Indeed, these clinical features are sequelae to persistent iridocyclitis. Recent advances in clinical imaging such as optical coherence tomography have demonstrated macular edema as

¹Okayama University Graduate School of Interdisciplinary Science and Engineering in Health Systems, Okayama City, Japan

²Ophthalmology, Okayama University Hospital and Okayama University Medical School, Okayama City, Japan

³Pediatrics, Okayama University Hospital and Okayama University Graduate School of Medicine, Dentistry, and Pharmaceutical Sciences, Okayama City, Japan

Received June 7, 2020. Revised June 28, 2020. Accepted August 2, 2020.

Corresponding Author:

Toshihiko Matsuo, Regenerative and Reconstructive Medicine (Ophthalmology), Okayama University Graduate School of Interdisciplinary Science and Engineering in Health Systems, Shikata-cho 2-5-1, Okayama City 700-8558, Japan.

Email: matsuo@cc.okayama-u.ac.jp



a vision-threatening feature of uveitis in children with juvenile idiopathic arthritis.⁹⁻¹⁵ Uveitis is more dominant at younger ages and often associated with oligoarticular (pauciarticular) juvenile idiopathic arthritis that tends to lack apparent systemic manifestations such as fever.⁵ Arthritis may appear after the onset of uveitis. Therefore, children with juvenile idiopathic arthritis-associated uveitis have more chance to be presented first to ophthalmologists and to be referred later to pediatricians.

In this study, we report a Japanese child with oligoarticular juvenile idiopathic arthritis who underwent cataract surgery during the course of oral methotrexate. Persistent macular edema was dramatically controlled with the induction of adalimumab for the following years. We also reviewed Japanese patients with juvenile idiopathic arthritis-associated uveitis in the literature.

Case Report

A 4-year and 8-month boy was referred from a local eye doctor to our hospital for band keratopathy, posterior iris synechiae, and complicated cataract in both eyes. The best-corrected visual acuity was 0.3 with +1.75 diopters and cylindrical -1.0 diopters at axis of 30° in the right eye and 0.1 with +3.75 diopters and cylindrical -2.25 diopters at axis of 170°, determined by cycloplegic refraction with topical 1% cyclopentolate. The intraocular pressure was 10 mm Hg in both eyes. He had no active inflammation in both eyes as evidenced by neither aqueous cells nor keratic precipitates. The retina in both eyes could be visualized as normal through the pupil with synechiae. The patient was referred to a pediatric rheumatologist and was diagnosed as juvenile idiopathic arthritis because he had intermittent joint symptoms. At the time of the diagnosis, he had no arthritis, and thus was followed with no medication. Antinuclear antibody, rheumatoid factor, and anti-cyclic citrullinated peptide (anti-CCP) antibody were negative throughout the course.

He was delivered with the birthweight of 2420 g by emergency Cesarean section at 41 weeks of gestation because of a reduced heart rate to 50 per minute when the mother suffered from the exacerbation of pregnancy-induced hypertension, proteinuria, and lower limb edema. He had been well except for hand, foot, and mouth disease at the age of 1 year and 9 months, and varicella at the age of 3 years and 8 months. Family history had nothing particular except for the mother who later developed immunoglobulin A (IgA) nephropathy at the age of 40 years.

At the age of 5 years and 1 month, oral prednisolone at daily dose of 20 mg (1 mg/kg of body weight) for 2 weeks, followed by 15 mg daily, was prescribed at another hospital where the mother sought the consultation at her own discretion. At the visit back to our hospital in 3 weeks after the start of oral prednisolone, the intraocular pressure was 40 mmHg in the right eye and 30 mmHg in the left eye. No iridocyclitis was noted in both eyes. With the diagnosis of a steroid responder who showed the elevation of intraocular pressure

in response to corticosteroid administration, the dose of oral prednisolone was reduced to 5 mg daily and discontinued in a week. Topical 0.1% fluorometholone 4 times daily was replaced by topical bromfenac twice daily. The intraocular pressure became 9 mmHg in both eyes. Oral ibuprofen 600 mg daily was prescribed by the pediatrician.

At the age of 5 years and 6 months (Figure 1A and B), oral methotrexate 10 mg/m² (8 mg) weekly was initiated by the pediatrician for recurrent bilateral iridocyclitis in both eyes, and 2 months later (Figure 1C and D), he underwent posterior synechialysis, anterior capsulotomy, and lens cortex aspiration with a 25-gauge vitrectomy cutter under the irrigation with a 25-gauge irrigating cannula, both of which were inserted through 2 ports at the corneal limbus.¹⁶ Planned intraocular lens implantation was cancelled at this time point of surgery because the anterior vitreous was visualized through the posterior capsule to have severe inflammatory opacity with diffuse retinal edema in both eyes. Total posterior capsulectomy and core vitrectomy was done through the limbal side ports (Figure 1E and F).

Postoperative visual acuity by correction with glasses (+14.75 diopters in the right eye and +14.25 diopters in the left eye on the focus of 50 cm from the eyes) remained at 0.04 in both eyes due to macular edema (Figure 2A and B) when he used oral methotrexate 10 mg in a week and topical 0.1% fluorometholone 4 times daily. At the age of 6 years, 5 months postoperatively, he began to use subcutaneous injection of adalimumab 20 mg every 2 weeks. In 2 months with scheduled injection of adalimumab, the macular retina was demonstrated to have normal structure by optical coherence tomography (Figure 2C and D). He gained the best-corrected visual acuity of 0.5 in the right eye and 0.2 in the left eye at the age of 6 years and 4 months when he was admitted to a local elementary school. The intraocular pressure in both eyes was kept in the normal range by occasional switching of topical bromfenac to topical 0.1% fluorometholone when keratic precipitates as a sign of iritis appeared.

At the age of 7 years and 4 months, he started topical latanoprost once daily when the intraocular pressure in the right eye had tendency to show a higher value of 25 mmHg. One month later, 0.5% timolol gel-forming solution once daily was prescribed in addition to latanoprost but was discontinued in the event of an asthma attack. At the final visit at the age of 11 years and 6 months, he had the best-corrected visual acuity of 0.8 in the right eye and 0.4 in the left eye (Figure 2E and F), with adalimumab 40 mg every 2 weeks and methotrexate 8 mg in a week. He had no intraocular inflammation with no topical steroid and maintained normal intraocular pressure in the range of 10 to 15 mmHg in both eyes with topical latanoprost and brinzolamide (Figure 1G and H). He had experienced no systemic adverse event in the course of adalimumab.

Methods

To analyze historical cases from the literature, the Japanese literature was searched for the keywords

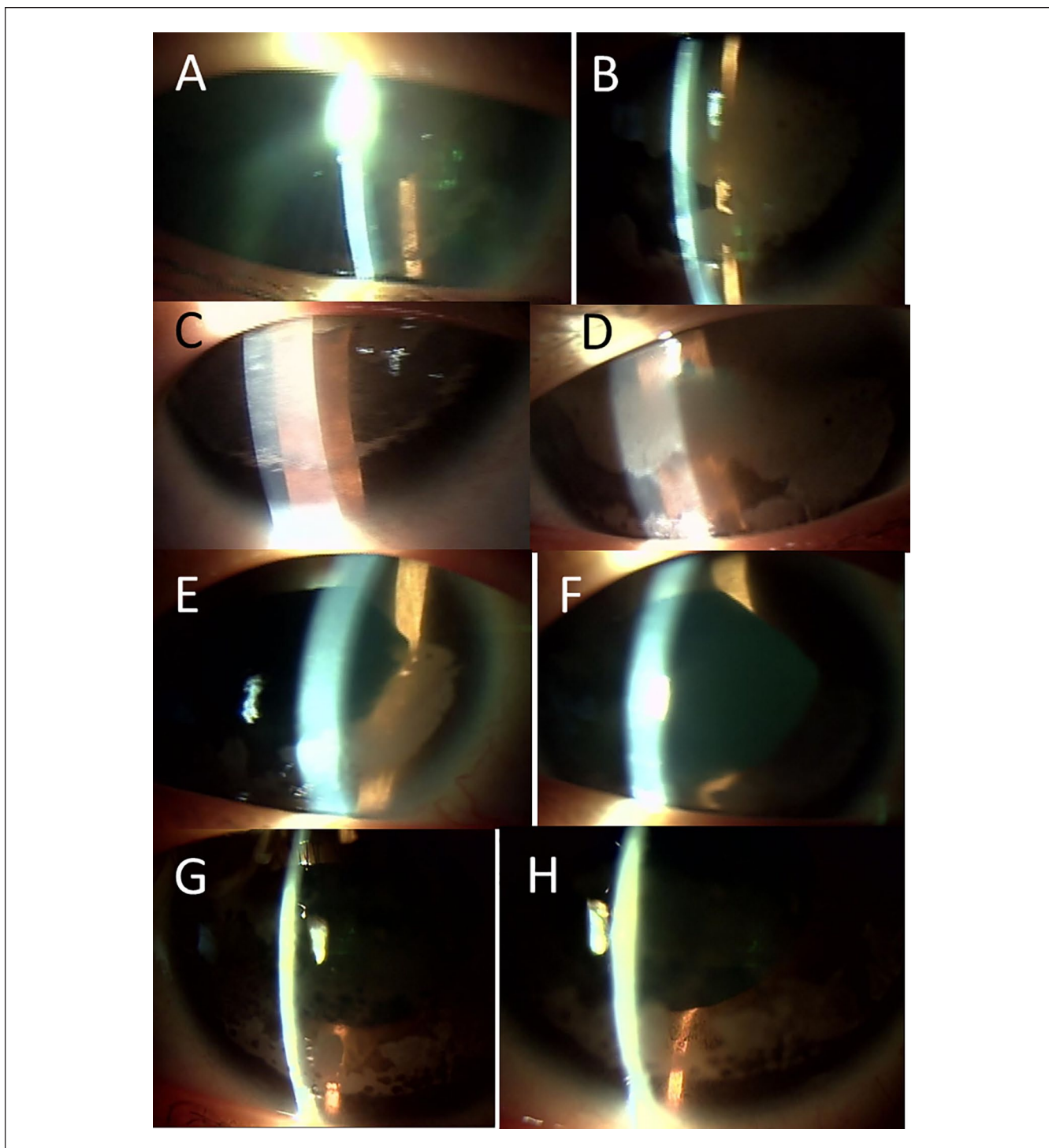


Figure 1. Slit-lamp biomicroscopic photographs. At the age of 5 years and 6 months (A, right eye; B, left eye) when oral methotrexate was started. At the age of 5 years and 8 months just before cataract surgery (C, right eye; D, left eye) and 5 days after the surgery (E, right eye; F, left eye). At the age of 7 years (G, right eye; H, left eye), 1 year after the start of adalimumab. Note that dense band keratopathy in both eyes (C, D) has been scaled off and that inflammation has subsided in aphakic eyes (E, F).

“juvenile idiopathic arthritis (in Japanese)” or “juvenile rheumatoid arthritis (in Japanese)” and “uveitis (in Japanese)” in the bibliographic database of medical

literature in Japanese (Igaku Chuo Zasshi, Japana Centra Revuo Medicina, Ichushi-Web), published by the Japan Medical Abstracts Society (JAMAS). Old literatures were

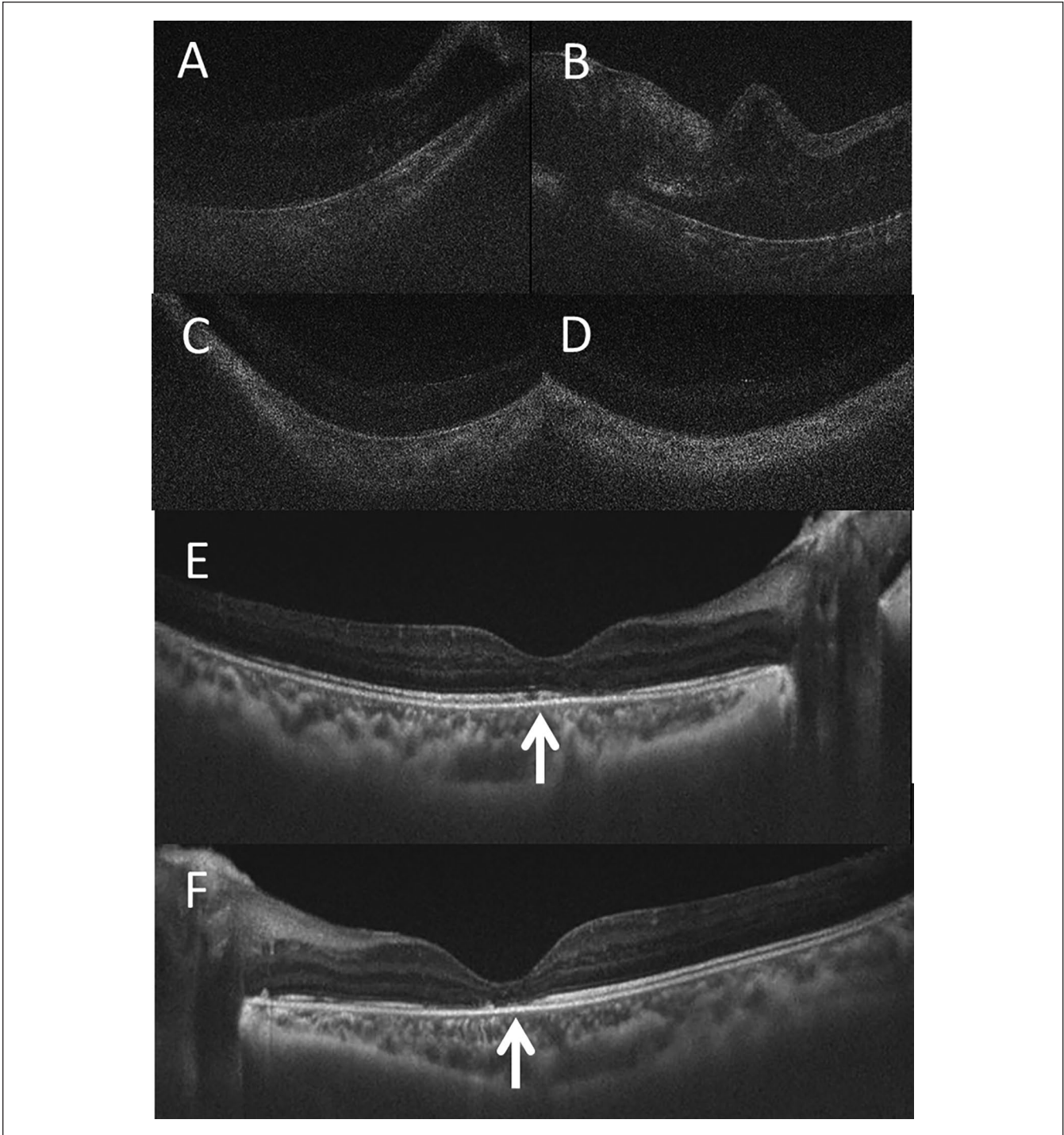


Figure 2. Optical coherence tomography. At the age of 5 years of 11 months (A, right eye; B, left eye), 1 month before the start of adalimumab. At the age of 6 years and 2 months (C, right eye; D, left eye), 2 months after the start of adalimumab. At the age of 8 years and 1 month (E, right eye; F, left eye). Note that macular edema in both eyes (A, B) has been resolved in 2 months (C, D) after the start of adalimumab. Note also that ellipsoid zone at the fovea (arrows in E, F), indicative of photoreceptor outer segments, is more well visualized in the right eye (E) compared with the left eye (F), explaining better visual acuity in the right eye.

further collected from references cited in the articles identified during the literature search. PubMed was also searched for the keywords “juvenile idiopathic arthritis” and “uveitis” or “juvenile rheumatoid arthritis” and

“uveitis.” The sufficient description was found in 26 Japanese patients with juvenile idiopathic arthritis–associated uveitis in 22 case reports written in Japanese except for one in English (Table 1).^{17–38}

Table 1. Review of 27 Japanese Patients With Juvenile Idiopathic Arthritis–Associated Uveitis Including the Present Patient.

Case no./gender	Age at onset	Category	ANA	RF	Preceding treatment before uveitis	Age at uveitis	Eye manifestations	Eye(s) involved	Systemic treatment for uveitis ^a	Eye surgery	Visual acuity at final visit, right/Left	Author
1/Male	3 years	Systemic	ND	ND	ND	7 years	Band keratopathy Iridocyclitis Subretinal exudates Optic papillitis	Bilateral	Prednisolone	Left iridectomy	0.9/0.1	Urayama and Sakuragi ¹⁷
2/Female	3 years	Oligo	ND	No	Simultaneous onset		Band keratopathy Iridocyclitis Cataract	Right	No	No	0.03/1.5	Urayama and Sakuragi ¹⁷
3/Female	7 years	Systemic	Yes	No	Simultaneous onset		Optic papillitis Iridocyclitis Retinal vasculitis Optic papillitis Iridocyclitis	Bilateral	Betamethasone	No	0.9/0.9	Tabuchi et al ¹⁸
4/Female	4 years 1 month	Systemic	ND	ND	Simultaneous onset		Iridocyclitis	Bilateral	Prednisolone	No	1.2/0.4	Fujiwara et al ¹⁹
5/Female	6 years	Oligo	Yes	No	Simultaneous onset		Iridocyclitis Retinal vasculitis	Bilateral	Prednisolone Aspirin	Bilateral trabeculectomy	0.1/0.7	Takano et al ²⁰
6/Female	2 years	Systemic	No	No	Aspirin	4 years	Iridocyclitis Retinal vasculitis Optic papillitis	Bilateral	No	No	1.5/1.5	Takano et al ²⁰
7/Female	2 years	Oligo	Yes	No	Aspirin	5 years	Band keratopathy Iridocyclitis Cataract	Bilateral	Aspirin	Left cataract surgery	1.2/0.1	Takano et al ²⁰
8/Female	3 years	Poly	ND	ND	Prednisolone	15 years	Retinal vasculitis Band keratopathy Iridocyclitis Cataract	Bilateral	ND	Left trabeculectomy Bilateral cataract surgery	0.02/0.04	Sakai et al ²¹
9/Female	9 years	Systemic	Yes	No	Simultaneous onset		Retinal vasculitis Iridocyclitis Retinal vasculitis Optic papillitis	Right	Dexamethasone	No	1.5/1.5	Uezato et al ²²
10/Male	12 years	Oligo	No	No	ND	13 years	Iridocyclitis Retinal vasculitis	Bilateral	ND	No	1.0/1.2	Akaki et al ²³
11/Male	17 years	Systemic	No	No	Methylprednisolone pulse	18 years	Retinal vasculitis	Bilateral	Prednisolone	No	1.0/1.0	Iizuka et al ²⁴
12/Female	3 years	Systemic	No	No	Simultaneous onset		Iridocyclitis Retinal vasculitis Subretinal exudates Optic papillitis	Bilateral	Prednisolone Aspirin	No	0.8/0.8	Nakayama et al ²⁵
13/Female	20 years	Systemic	Yes	No	Simultaneous onset		Iridocyclitis Optic papillitis	Bilateral	Methylprednisolone pulse Aspirin	No	1.2/1.5	Igari et al ²⁶
14/Female	2 years	Oligo	Yes	No	ND	7 years	Iridocyclitis Cataract	Bilateral	Levothyroxine for Hashimoto disease	Bilateral cataract surgery	1.5/1.5	Honda et al ²⁷

(continued)

Table 1. (continued)

Case no./gender	Age at onset	Category	ANA	RF	Preceding treatment before uveitis	Age at uveitis	Eye manifestations	Eye(s) involved	Systemic treatment for uveitis ^a	Eye surgery	Visual acuity at final visit, right/Left	Author
15/Male	12 years	Poly	No	No	Simultaneous onset		Iridocyclitis Retinal vasculitis Optic papillitis	Bilateral	Prednisolone	No	1.2/1.2	Amano and Mochizuki ²⁸
16/Female	10 years	Systemic	No	No	Simultaneous onset		Subretinal exudates	Bilateral	Aspirin	No	1.0/1.2	Higuchi et al ²⁹
17/Female	5 years	Systemic	No	No	Simultaneous onset		Iridocyclitis Retinal vasculitis Optic papillitis	Bilateral	Aspirin Prednisolone	No	1.5/1.2	Sakaguchi et al ³⁰
18/Male	2 years	Systemic	Yes	No	Aspirin	3 years	Subretinal exudates (brain basal ganglia mass)	Right	Prednisolone	No	ND/ND	Hirabayashi et al ³¹
19/Female	12 years	Systemic	Yes	No	ND	15 years	Iridocyclitis Subretinal exudates	Bilateral	No	No	1.0/1.0	Ishihara et al ³²
20/Female	5 years	Systemic	No	No	ND	11 years	Optic papillitis Iridocyclitis Retinal vasculitis Subretinal exudates	Bilateral	Prednisolone Aspirin	No	0.8/0.6	Sekine et al ³³
21/Male	19 years	Systemic	No	No	Simultaneous onset		Optic papillitis Iridocyclitis Retinal vasculitis	Bilateral	Prednisolone Methotrexate	No	1.0/1.0	Namba et al ³⁴
22/Female	4 years	Oligo	Yes	ND	Simultaneous onset		Iridocyclitis Subretinal exudates Vitreous opacity	Bilateral	Prednisolone Cyclosporine	No	2.0/2.0	Matsushita et al ³⁵
23/Female	1 year 7 months	Oligo	Yes	No	Ibuprofen Prednisolone Methotrexate	11 years	Iridocyclitis Retinal vasculitis Macular edema	Bilateral	Etanercept	No	1.0/1.0	Kinouchi et al ³⁶
24/Female	4 years	Poly	Yes	ND	Simultaneous onset		Optic papillitis Band keratopathy Iridocyclitis	Bilateral	Prednisolone	Bilateral cataract surgery with IOL	0.09/0.1	Ishikura et al ³⁷
25/Female	2 years 9 months	Oligo	Yes	No	Simultaneous onset	5 years	Iridocyclitis Cataract Retinal vasculitis Macular edema	Right	Ibuprofen Prednisolone Adalimumab	Bilateral PTK Right cataract surgery	0.9/ND	Shimizu ³⁸
26/Male	5 years 1 month	Oligo	Yes	No	Simultaneous onset		Band keratopathy Iridocyclitis Macular edema	Left	Ibuprofen Methotrexate Adalimumab	Left therapeutic keratectomy	ND/0.4	Shimizu et al ³⁸
27/Male	4 years 8 months	Oligo	No	No	Simultaneous onset		Band keratopathy Iridocyclitis Cataract Retinal vasculitis Macular edema	Bilateral	Methotrexate Adalimumab	Bilateral cataract surgery Bilateral therapeutic keratectomy	0.8/0.4	Matsuo and Yashiro (this case)

Abbreviations: ANA, antinuclear antibody; RF, rheumatoid factor; ND, not described; systemic, systemic arthritis; oligo, oligoarthritis; poly, polyarthritis; IOL, intraocular lens implantation; PTK, phototherapeutic keratectomy.
^a"No" in systemic treatment for uveitis indicates topical medication only.

Results

In review of the literature, 27 patients with juvenile idiopathic arthritis–associated uveitis, including the present patient, were 8 male and 19 female, with the age at the diagnosis of juvenile idiopathic arthritis, ranging from 1 year and 7 months to 20 years (median = 5 years). The timing at the diagnosis of uveitis was the same as the onset of systemic manifestations and, hence, as the diagnosis of juvenile idiopathic arthritis in 15 patients, while the diagnosis of uveitis was delayed in 12 patients by the range from 1 year to 12 years (median = 2.5 years) after the onset of systemic manifestations. The category of juvenile idiopathic arthritis was systemic arthritis in 14 patients, oligoarthritis in 10 patients, and polyarthritis (rheumatoid factor–negative) in 3 patients. Antinuclear antibody was positive in 13 patients and negative in 10 patients, while the remaining 4 patients had no description. Rheumatoid factor was negative in all 22 patients with its description.

All 27 patients, including the present patient, showed iridocyclitis manifested as keratic precipitates and aqueous cells sometimes with synechia iris posterior. Both eyes were involved in 22 patients, only the right eye in 4 patients, and only the left eye in 1 patient. Persistent iridocyclitis was associated with band keratopathy in 7 patients and complicated cataract in 6 patients. Only 3 patients had iridocyclitis with no description of fundus (posterior segment) manifestations. Lens extraction with no intraocular lens implantation as cataract surgery was done in 4 patients while intraocular lens implantation was done in 1 patient (Case 24). Phototherapeutic keratectomy using laser was done in both eyes of 1 patient with dense band keratopathy (Case 24).

The other 24 patients had fundus manifestations: 2 of these 24 patients had fundus manifestations only and did not have iridocyclitis, one with retinal vasculitis (Case 11) and another with subretinal exudates (Case 16) in both eyes. As for fundus (posterior segment) manifestations, retinal vasculitis was described in 16 patients, optic papillitis in 12 patients, subretinal exudates in 7 patients, and macular edema in 3 patients. The retinal vasculitis manifested as vascular leakage on fluorescein angiography, diffuse retinal edema, and vascular sheathing. The optic papillitis manifested as blurred hyperemic swollen optic disc and occasionally as exudates around the optic disc. The subretinal exudates manifested usually as multiple spotty white lesions and occasionally as diffuse large exudation. The macular edema in recent patients was detected by optical coherence tomography.

In treatment for uveitis, adalimumab was prescribed in 3 most recent patients including the present patient. Oral steroids were given in 16 patients, cyclosporine combined with prednisolone in 1 patient (Case 22), and etanercept only in another patient (Case 23). Aspirin (salicylate) was given in 7 patients: independently in 2 patients and combined with

prednisolone in 5 patients. Ibuprofen was used in 2 most recent patients.

Discussion

The present patient was diagnosed as antinuclear antibody–negative oligoarticular juvenile idiopathic arthritis, based on intermittent joint symptoms and typical eye signs after the exclusion of infectious uveitis and other types of noninfectious uveitis. In the field of ophthalmology, pediatric uveitis is rare, and it is mandatory to make differential diagnosis of other types of uveitis from juvenile idiopathic arthritis–associated uveitis. Bilateral iridocyclitis with retinal capillaritis in juveniles³⁹ and tubulointerstitial nephritis and uveitis syndrome⁴⁰ are 2 entities of pediatric uveitis that must be considered at this setting. In contrast with juvenile idiopathic arthritis–associated uveitis, these 2 types of uveitis have tendency not to cause severe complications of band keratopathy and cataract.

The present patient developed retinal vasculitis and macular edema, concurrently with iridocyclitis that resulted in band keratopathy and complicated cataract in both eyes. The retinal involvement was noted at the time of cataract surgery in which diffuse retinal edema, together with severe anterior vitreous inflammation, was visualized. Male gender has been shown as a risk factor for developing complicated cataract and optic papillitis associated with uveitis.⁴¹ Intraocular lens implantation was cancelled in the present patient with severe anterior vitreous inflammation involving the posterior capsule of the lens. Intraocular lens implantation at cataract surgery might not be a risk factor for macular edema and optic papillitis as well as glaucoma under the maximum control of inflammation,⁴² but we avoided taking a risk in the present patient under the circumstances of severe vitreous inflammation.

After cataract surgery to remove the entire lens in addition to core vitrectomy in both eyes, the intraocular inflammation became calm during the course of oral methotrexate. However, the patient had poor visual acuity in both eyes due to persistent macular edema revealed by optical coherence tomography. After 2 months of adalimumab therapy, the structure of the macula in both eyes had dramatically normalized, leading to good visual acuity that satisfied the standard for the elementary school admission. As shown in the present patient, adalimumab is now the standard therapy for juvenile idiopathic arthritis–associated uveitis with retinal complications such as macular edema.^{43–49} In this context, liaison between ophthalmologists and pediatricians is crucial not to miss a chance to rescue the vision by starting adalimumab. Concurrent with the present report, case series of Japanese patients with juvenile idiopathic arthritis–associated uveitis were reported by pediatricians.⁵⁰ Those 9 patients were all in the category of oligoarthritis, and 8 of them received biologics such as adalimumab. The authors emphasized the planned transitional care for children with juvenile

idiopathic arthritis to avoid the blindness caused by sequelae to uveitis.

In review of the literature¹⁷⁻³⁸ in the present study, most Japanese patients with juvenile idiopathic arthritis-associated uveitis had fundus manifestations such as retinal vasculitis, optic papillitis, and subretinal exudates. A high rate of fundus manifestations in juvenile idiopathic arthritis-associated uveitis might be attributed to reporting bias to describe rarer presentations. Indeed until now, fundus manifestations in juvenile idiopathic arthritis-associated uveitis have not been well described in the textbooks. Optical coherence tomography in widespread use at ophthalmology clinics would help accurate diagnosis of macular edema, which is a vision-threatening condition in uveitis associated with juvenile idiopathic arthritis, as shown in the present patient.

The present patient had 2 risk factors for developing juvenile idiopathic arthritis-associated uveitis: the younger age of onset at 4 years and the category of oligoarthritis.⁵ It should be noted in review of the literature that about a half of the historical Japanese patients with juvenile idiopathic arthritis-associated uveitis belonged to the category of systemic arthritis.¹⁷⁻³⁸ This finding is in marked contrast with the recent reports that the category of oligoarthritis was predominant also in Japanese patients with juvenile idiopathic arthritis-associated uveitis,^{5,50} in parallel with the Caucasian population.¹ The reason for the categorical difference between the historical cohort and the recent cohort⁵ in the Japanese population remains unknown. As described above, the historical cohort in the present study is indeed the collection of case reports that tended to describe fundus manifestations as a rare event, and thus would have reporting bias from the viewpoint of the disease category.

In conclusion, the present study focused on the Japanese patients with juvenile idiopathic arthritis-associated uveitis. In the historical Japanese patients, the category of systemic arthritis was dominant and was followed by the category of oligoarthritis. The fundus manifestations, such as retinal vasculitis, subretinal exudates, and optic papillitis, were common in addition to well-recognized features of iridocyclitis, band keratopathy, and complicated cataract in the younger ages.

Authors' Note

Data are available on reasonable request to the corresponding author.

Author Contributions

TM, as an ophthalmologist, followed the patient and did the surgery. MY, as a pediatrician, introduced methotrexate and adalimumab and followed the patient. TM wrote the manuscript, and MY did critical review of the manuscript. Both authors read and approved the manuscript.

Declaration of Conflicting Interests

The author(s) declared no potential conflicts of interest with respect to the research, authorship, and/or publication of this article.

Funding

The author(s) received no financial support for the research, authorship, and/or publication of this article.

Ethics Approval

Ethics committee review was not applicable to case reports, based on the Ethical Guidelines for Medical and Health Research Involving Human Subjects, issued by the Government of Japan.

Informed Consent

Oral informed consent was obtained from the patient and the mother.

ORCID iD

Toshihiko Matsuo  <https://orcid.org/0000-0001-6570-0030>

References

1. Saurenmann RK, Rose JB, Tyrrell P, et al. Epidemiology of juvenile idiopathic arthritis in a multiethnic cohort: ethnicity as a risk factor. *Arthritis Rheum.* 2007;56:1974-1984.
2. Kobayashi T, Tanaka S, Maeda M, Okubo H, Matsuyama T, Watanabe N. A study of prognosis in 52 cases with juvenile rheumatoid arthritis. *Acta Paediatr Jpn.* 1993;35:439-446.
3. Fujikawa S, Okuni M. Clinical analysis of 570 cases with juvenile rheumatoid arthritis: results of a nationwide retrospective survey in Japan. *Acta Paediatr Jpn.* 1997;39:245-249.
4. Petty RE, Southwood TR, Manners P, et al. International League of Associations for Rheumatology classification of juvenile idiopathic arthritis: second revision, Edmonton, 2001. *J Rheumatol.* 2004;31:390-392.
5. Yasumura J, Yashiro M, Okamoto N, et al. Clinical features and characteristics of uveitis associated with juvenile idiopathic arthritis in Japan: first report of the Pediatric Rheumatology Association of Japan (PRAJ). *Pediatr Rheumatol Online J.* 2019;17:15.
6. Rosenberg AM. Uveitis associated with juvenile rheumatoid arthritis. *Semin Arthritis Rheum.* 1987;16:158-173.
7. Kanski JJ. Juvenile arthritis and uveitis. *Surv Ophthalmol.* 1990;34:253-267.
8. Kump LI, Castañeda RAC, Androudi SN, Reed GF, Foster CS. Visual outcomes in children with juvenile idiopathic arthritis-associated uveitis. *Ophthalmology.* 2006;113:1874-1877.
9. Woreta F, Thorne JE, Jabs DA, Kedhar SR, Dunn JP. Risk factors for ocular complications and poor visual acuity at presentation among patients with uveitis associated with juvenile idiopathic arthritis (JIA). *Am J Ophthalmol.* 2007;143:647-655.
10. de Lahitte GD, Terrada C, Tran THC, et al. Maculopathy in uveitis of juvenile idiopathic arthritis: an optical coherence tomography study. *Br J Ophthalmol.* 2008;92:64-69.
11. Sabri K, Saurenmann RK, Silverman ED, Levin AV. Course, complications, and outcome of juvenile arthritis-related uveitis. *J AAPOS.* 2008;12:539-545.
12. Paroli MP, Spinucci G, Fabiani C, Pivetti-Pezzi P. Retinal complications of juvenile idiopathic arthritis-related uveitis: a microperimetry and optical coherence tomography study. *Ocul Immunol Inflamm.* 2010;18:54-59.

13. Vitale AT, Graham E, de Boer JH. Juvenile idiopathic arthritis-associated uveitis: clinical features and complications, risk factors for severe course, and visual outcome. *Ocul Immunol Inflamm*. 2013;21:478-485.
14. Paroli MP, Fabiani C, Spinucci G, Abicca I, Sapia A, Spadea L. Severe macular edema in patients with juvenile idiopathic arthritis-related uveitis. *Case Rep Ophthalmol Med*. 2013;2013:803989.
15. de Boer J, Steijaert A, van den Bor R, Stellato R, van Norel JO. Development of macular edema and impact on visual acuity in uveitis associated with juvenile idiopathic arthritis. *Ocul Immunol Inflamm*. 2015;23:67-73.
16. Matsuo T. Intraocular lens implantation in unilateral congenital cataract with minimal levels of persistent fetal vasculature in the first 18 months of life. *Springerplus*. 2014;3:361.
17. Urayama A, Sakuragi S. Pediatric uveitis: especially regarding Still's disease [in Japanese]. *Ganka*. 1969;11:358-363.
18. Tabuchi A, Takeda J, Takagi K, et al. A case of juvenile rheumatoid arthritis with papillitis and retinal vasculitis [in Japanese]. *Nippon Ganka Kiyo (Folia Ophthalmol Jpn)*. 1979;30:497-502.
19. Fujiwara H, Ota T, Okamoto S. Ocular complications in the cases with juvenile rheumatoid arthritis [in Japanese]. *Nippon Ganka Kiyo (Folia Ophthalmol Jpn)*. 1980;31:333-337.
20. Takano S, Ohnishi Y, Mitsuhashi M, et al. Three cases of juvenile rheumatoid arthritis-associated uveitis [in Japanese]. *Ganka*. 1984;26:77-84.
21. Sakai M, Kanari T, Yaginuma Y, et al. Sister cases of arthropathy and uveitis associated either with sarcoidosis or juvenile rheumatoid arthritis [in Japanese]. *Ganka Rinsho Iho (Jpn Rev Clin Ophthalmol)*. 1986;80:1077-1081.
22. Uezato T, Kuwae Y, Uehara M, et al. A case of juvenile rheumatoid arthritis with fundus involvement [in Japanese]. *Rinsho Ganka (Jpn J Clin Ophthalmol)*. 1986;40:378-379.
23. Akaki Y, Haruta Y, Nakagawa Y, et al. Eight cases of chronic recurrent uveitis with hypopyon [in Japanese]. *Nippon Ganka Kiyo (Folia Ophthalmol Jpn)*. 1986;37:201-206.
24. Iizuka M, Hayakawa M, Yoshiike A, et al. A case of retinal vasculitis associated with juvenile rheumatoid arthritis [in Japanese]. *Ganka Rinsho Iho (Jpn Rev Clin Ophthalmol)*. 1989;83:84-87.
25. Nakayama T, Otaki C, Makino S. Posterior uveitis in juvenile rheumatoid arthritis [in Japanese]. *Ganka Rinsho Iho (Jpn Rev Clin Ophthalmol)*. 1989;83:284-287.
26. Igari S, Onizawa N, Yoshida T, et al. A case of adult-onset Still's disease with iridocyclitis and papillitis [in Japanese]. *Ryumachika (Rheumatology, Tokyo)*. 1989;1:527-533.
27. Honda T, Ishibashi T, Inomata H, et al. A case of juvenile rheumatoid arthritis associated with iridocyclitis, cataract and Hashimoto's disease [in Japanese]. *Nippon Ganka Kiyo (Folia Ophthalmol Jpn)*. 1989;40:663-667.
28. Amano S, Mochizuki M. A case of juvenile rheumatoid arthritis with panuveitis [in Japanese]. *Rinsho Ganka (Jpn J Clin Ophthalmol)*. 1990;44:205-208.
29. Higuchi H, Kimura S, Mukuno K, et al. A case of juvenile rheumatoid arthritis manifested isolated retinochoroidal lesions. *Rinsho Ganka (Jpn J Clin Ophthalmol)*. 1990;44:1969-1973.
30. Sakaguchi S, Hara T, Saishin M, et al. A case of juvenile rheumatoid arthritis with papilledema and retinal vasculitis. *Rinsho Ganka (Jpn J Clin Ophthalmol)*. 1991;45:723-726.
31. Hirabayashi S, Kasai S, Tsukahara T, Fujisawa N, Watanabe T. Basal ganglia mass lesions in juvenile rheumatoid arthritis. *Pediatr Neurol*. 1991;7:141-143.
32. Ishihara M, Nakamura S, Okada K, et al. A case of juvenile rheumatoid arthritis with panuveitis [in Japanese]. *Nippon Ganka Gakkai Zasshi (Acta Soc Ophthalmol Jpn)*. 1992;96:109-113.
33. Sekine N, Takeda M, Suzuki J. Iridocyclitis with subretinal flecked lesions in a case of juvenile rheumatoid arthritis [in Japanese]. *Rinsho Ganka (Jpn J Clin Ophthalmol)*. 1993;47:131-134.
34. Namba K, Tsuda K, Ohnishi K, et al. Iridocyclitis, papilledema and retinal phlebitis in a case of adult-onset Still's disease [in Japanese]. *Rinsho Ganka (Jpn J Clin Ophthalmol)*. 1996;50:1687-1690.
35. Matsushita E, Fushishima A, Hayashi N, et al. Panuveitis in a case of juvenile rheumatoid arthritis [in Japanese]. *Rinsho Ganka (Jpn J Clin Ophthalmol)*. 2002;56:617-620.
36. Kinouchi R, Hirokawa H, Igarashi S, et al. A case of panuveitis with optic disc neovascularization associated with juvenile idiopathic arthritis which progressed during a clinical trial of etanercept. *Nippon Ganka Gakkai Zasshi (J Jpn Ophthalmol Soc)*. 2007;111:970-975.
37. Ishikura R, Miyazaki D, Inoue Y, et al. A case of juvenile rheumatoid arthritis with cataract surgery after phototherapeutic keratectomy [in Japanese]. *Ganka Rinsho Kiyo (Folia Jpn Ophthalmol Clin)*. 2008;1:1163-1167.
38. Shimizu M, Takemoto Y, Takakura M, et al. Usefulness of adalimumab in the treatment of refractory uveitis associated with juvenile idiopathic arthritis [in Japanese]. *Shoni Ryumachi (J Clin Pediatr Rheumatol)*. 2015;6:33-38.
39. Matsuo T, Matsuo N. Bilateral iridocyclitis with retinal capillaritis in juveniles. *Ophthalmology*. 1997;104:939-944.
40. Matsuo T. Fluorescein angiographic features of tubulointerstitial nephritis and uveitis syndrome. *Ophthalmology*. 2002;109:132-136.
41. Ayuso VK, Cate HATT, van der Does P, Rothova A, de Boer JK. Male gender as a risk factor for complications in uveitis associated with juvenile idiopathic arthritis. *Am J Ophthalmol*. 2010;149:994-999.e5.
42. Sijssens KM, Los LI, Rothova A, et al. Long-term ocular complications in aphakic versus pseudophakic eyes of children with juvenile idiopathic arthritis-associated uveitis. *Br J Ophthalmol*. 2010;94:1145-1149.
43. Samra KA, Maghsoudlou A, Roohipoor R, Valdes-Navarro M, Lee S, Foster CS. Current treatment modalities of JIA-associated uveitis and its complications: literature review. *Ocul Immunol Inflamm*. 2016;24:431-439.
44. Asproudis I, Katsanos A, Kozeis N, Tantou A, Konstas AG. Update on the treatment of uveitis in patients with juvenile idiopathic arthritis: a review. *Adv Ther*. 2017;34:2558-2565.
45. Tynjala P, Kotaniemi K, Lindahl P, et al. Adalimumab in juvenile idiopathic arthritis-associated chronic anterior uveitis. *Rheumatology (Oxford)*. 2008;47:339-344.
46. Diaz-Llopis M, Salom D, Garcia-de-Vicuña C, et al. Treatment of refractory uveitis with adalimumab: a prospective multicenter study of 131 patients. *Ophthalmology*. 2012;119:1575-1581.
47. Zannin ME, Birolo C, Gerloni VM, et al. Safety and efficacy of infliximab and adalimumab for refractory uveitis in juvenile idiopathic arthritis: 1-year follow-up data from the Italian registry. *J Rheumatol*. 2013;40:74-79.

48. Muñoz-Gallego A, Barral E, Enríquez E, Tejada P, Barceló A, de Inocencio J. Adalimumab for the treatment of refractory noninfectious pediatric uveitis. *Int Ophthalmol*. 2017;37:719-725.
49. Zierhut M, Heiligenhaus A, de Boer J, Cunningham ET, Tugal-Tutkan I. Controversies in juvenile idiopathic arthritis-associated uveitis. *Ocul Immunol Inflamm* 2013;21:167-179.
50. Yamazaki S, Shimbo A, Akutsu Y, Takase H, Morio T, Mori M. Importance of pediatric rheumatologists and transitional care for juvenile idiopathic arthritis-associated uveitis: a retrospective series of 9 cases. *Pediatr Rheumatol Online J*. 2020;18:26.