

Groin abscess, a rare complication of strangulated femoral hernia: Case report

SAGE Open Medical Case Reports
Volume 9: 1–5
© The Author(s) 2021
Article reuse guidelines:
sagepub.com/journals-permissions
DOI: 10.1177/2050313X211036769
journals.sagepub.com/home/sco



Khaled S Ahmad¹ , Naif A Alenazi²
and Mohamed S Essa³

Abstract

Femoral hernias account for 8%–11% of all groin hernias and 3%–5% of all anterior abdominal wall hernias. While groin hernias are more common in males, femoral hernias are developed more commonly in female, accounting for 22%–34% of all groin hernias compared with 1.1% in male. The lifetime risk of developing groin hernia in male is approximately 25% but in female less than 5%, so in all female patients with groin hernias, femoral hernias should be included in the differential diagnosis until proven otherwise. The main concern of a femoral hernia is the higher risk of bowel strangulation, presenting emergently in 32%–39% of patients. We report a case of strangulated femoral hernia in a 78-year-old female who was presented to emergency department with groin abscess based on ultrasound image; patient was then diagnosed as having strangulated femoral hernia and taken to the operating theater, where she was found having strangulated segment of small intestine, so the patient underwent bowel resection and anastomosis with repair of the defect extraperitoneally, and ultimately, the patient improved and discharged from the hospital. Strangulated femoral hernia can present with groin abscess. Furthermore, femoral hernia should be ruled out in elderly patient presented with groin abscess, especially female patients.

Keywords

Strangulated, femoral, hernia, inguinal, abscess

Date received: 1 May 2021; accepted: 12 July 2021

Introduction

Femoral hernia (FH) is an acquired hernia and it passes through femoral canal. It is usually an insidious hernia, generally asymptomatic, because of a small dimension within the femoral area; a late diagnosis in up to 30% of patients is common. Although FH is rarer than the inguinal hernia (IH), it has a higher mortality rate (more than 25%) due to difficult and late diagnosis which most commonly occurs at the time of complications.¹

From the time of diagnosis, the risk of FH incarceration has been identified in up to 22% and 45% of patients at 3 and 21 months, respectively. Acute incarcerated FHs are associated with high morbidity, approximately 30%, including intestinal resection, wound surgical site infection (SSI), and cardiovascular and pulmonary complication, compared with those repaired on elective surgery. Furthermore, emergency repair of strangulated FH is associated with higher mortality, approximately 10 to 20 fold, compared with patients treated with elective repair, even in very elderly patients (≥ 80 years of age). For this reason, all patients diagnosed with an FH on elective setting and

all female and older patients proved to have a groin hernia should be offered surgical repair as early as possible.^{2,3} In this case, we describe groin abscess as a rare complication of strangulated FH which is rarely reported; in addition, any groin abscess should undergo imaging to rule out strangulated FH.

Case presentation

A 78-year-old female patient with a known case of diabetes mellitus (DM) presented to emergency department with

¹Department of General Surgery, Prince Mohammed Bin Abdulaziz Hospital, Riyadh, Saudi Arabia

²Department of General Surgery, Ad Diriyah Hospital, ArRihab, Riyadh, Saudi Arabia

³Department of General Surgery, Faculty of Medicine, Benha University, Benha, Egypt

Corresponding Author:

Khaled S Ahmad, Department of General Surgery, Prince Mohammed Bin Abdulaziz Hospital, Riyadh 14214, Saudi Arabia.
Email: khaled.ahmad.md@gmail.com



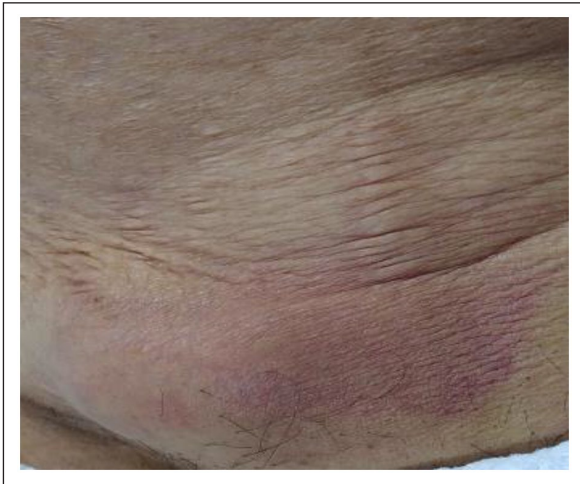


Figure 1. Groin abscess.

groin abscess (Figure 1). On examination, vital signs were normal in addition to red tender swelling at the left groin area. Abdominal examination revealed mildly distended abdomen, resonant on percussion, and exaggerated bowel sound in addition to small paraumbilical hernia. Per-rectal (P/R) examination showed empty rectum. The laboratory examination showed that her white blood cells (WBCs) were $20 \times 10^9/L$, her hemoglobin was 10.5 g/dL, and her platelets were $462 \times 10^9/L$. The total serum sodium was 133 mmol/L and potassium was 3.3 mmol/L. The prothrombin time (PT) was 13.4 s, the partial thromboplastin time (PTT) was 26.6 s, and the international normalized ratio (INR) was 0.97. The total serum bilirubin was $6 \mu\text{mol/L}$ and the direct bilirubin was $2.8 \mu\text{mol/L}$. Alkaline phosphatase was 68 IU/L, aspartate transaminase was 24 IU/L, alanine transaminase was 16 IU/L, amylase was 43 IU/L, and lipase was 8 IU/L. The blood urea nitrogen was 6.4 mg/dL and the serum creatinine was $54.8 \mu\text{mol/L}$. Chest x-ray was unremarkable. Ultrasound examination showed a left groin collection with septations and echoes measuring around $4.5 \times 3.3 \text{ cm}$ and an umbilical collection containing debris measuring $7.5 \times 2.3 \text{ cm}$ with a neck measuring 1.4 cm (Figure 2). Based on our suspicion of strangulated left FH because of the site of the swelling related to FH orifice, computed tomography (CT) of abdomen and pelvis was recommended. The CT showed strangulated FH with evidence of bowel obstruction (Figure 3).

Patient was taken to the operating theater after obtaining informed consent. She underwent exploratory laparotomy through midline incision, which showed a part of the small bowel strangulated within the left femoral canal; reduction was done and a 5 cm gangrenous segment was found which was resected and re-anastomosed; a gangrenous sac was found and resected, and hernia was repaired through preperitoneal approach by closure of the femoral ring via approximation of conjoint tendon and pectineal ligaments (Figures 4 and 5). Drain was inserted and then the abdomen was closed after repairing the paraumbilical defect (no contents in the

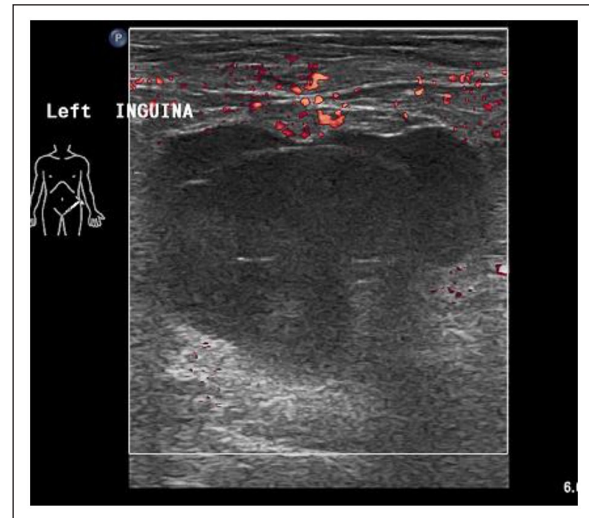

Figure 2. US of left groin area showed left groin abscess.

sac). The groin abscess was drained via 2 cm incision without drain insertion, with daily dressing. Culture revealed *Escherichia coli* (*E. coli*) that is sensitive to ceftriaxone.

The patient's recovery and postoperative course were uneventful and she was discharged 7 days following surgery with follow-up in outpatient clinic, and no recurrence of the hernia has been found to date.

Discussion

The femoral canal forms the medial compartment of the femoral sheath. Femoral ring is the proximal opening of the femoral canal which is covered by condensed extraperitoneal fatty tissue known as femoral septum. The contents of the femoral canal are loose areolar tissue, few lymphatics, and Cloquet's lymph node. The FH is formed by peritoneal sac herniation through the femoral ring into the femoral canal.⁴

FH accounts for 4% of all groin hernia while IH represents approximately 96%. FH accounts for only 2%–4% of all repairs of groin hernia. FH represents approximately 20%–31% of repairs in female while it represents 1% of repairs in male. FH is usually present later in life compared with IH. In those above 70 years, FH accounts for 52% of repairs in female compared with 7% of repairs in male.^{5–10} Lean females in fourth to sixth decades of their life are at high risk of developing the FH and in rare consequences femorocele, due to enlarged femoral ring.^{4,11}

Patients with a hernia usually present with a swelling and the surgeon should confirm the presence of hernia on physical examination. The hernia that is difficult to be discovered on physical examination is known as occult hernia, but it can produce symptoms such as a feeling of a bulge or pain which is consistent with groin hernia; this is due to either the small size of the hernia or obesity. In this scenario, additional investigation such as ultrasonography (US) or CT should be performed because there are several causes of groin pain that

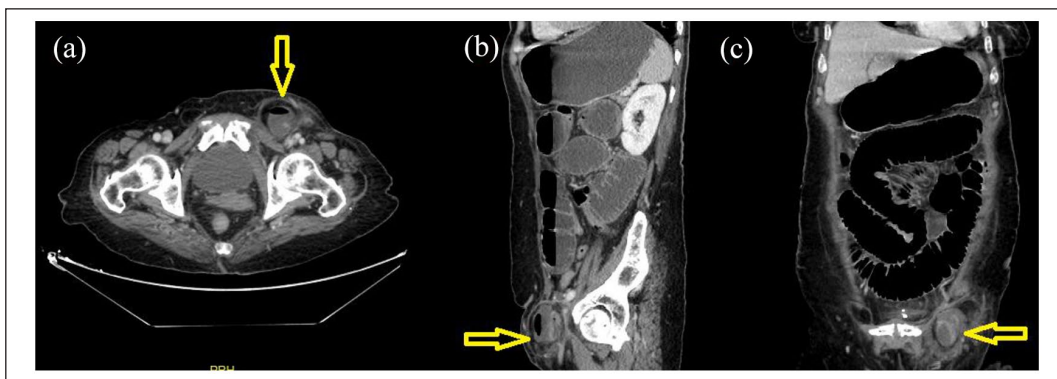


Figure 3. CT abdomen showed femoral hernia (yellow arrow).

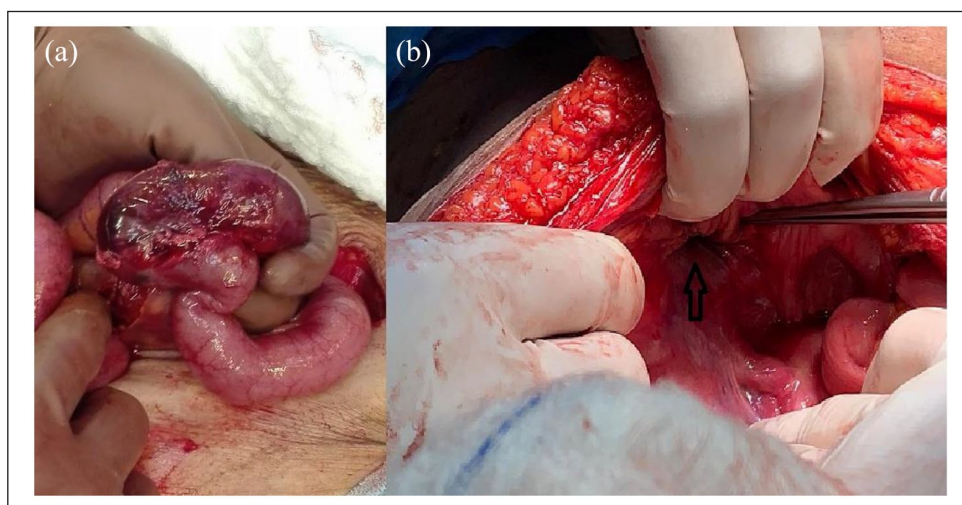


Figure 4. Intraoperative findings: (a) Ischemic small bowel, (b) femoral defect (transperitoneal view).

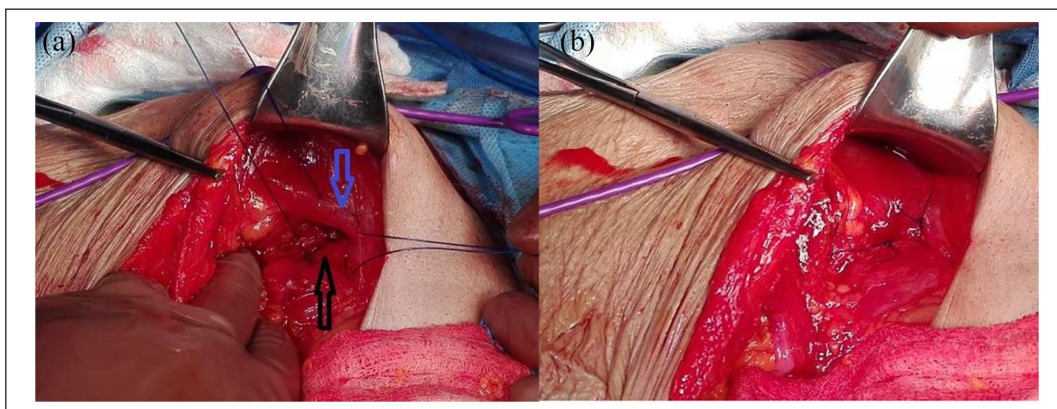


Figure 5. Femoral ring closure (extraperitoneal): (a) Approximation of conjoint tendon (blue arrow) with Cooper's ligament (black arrow), (b) after repair.

cannot be managed with surgery.^{12,13} In our case, the patient presented with groin abscess due to necrosis of the small bowel segment that lead to infected fluid inside hernia sac. Groin abscess presentation in our case denoting long time before diagnosis.

Several series of patients operated for groin hernia (series including FH) reported and defined risk factors associated with worse outcome in patients who underwent either elective (majority) or emergency hernia repair. Incarceration and strangulation are usually more common in females and American

Society of Anesthesiologists (ASA) 3 and 4 groups. Major postoperative complications generally develop in patients with severe preexisting diseases. Emergency surgery for hernia repairs, particularly in elderly patients, has a high risk for both morbidity and mortality, especially in the presence of coexisting cardiac and pulmonary diseases. In one report, the 30-day mortality rate was higher for FH than IH repairs in both males (6.81 versus 1.29) and females (7.16 versus 2.82).¹²⁻¹⁴

Midline incision for FH repair was first reported by Annandale in 1876 and then modified by Nyhus and Stoppa. Midline preperitoneal approach helps us to completely close the preperitoneal space between the peritoneum and fascia transversalis, and then to incise peritoneum for exploratory laparotomy. For incarcerated or strangulated FH, the inguinal (Poupart's) and lacunar ligaments can be incised to enlarge the femoral ring for reduction of the contents. These incisions should be done under direct vision to avoid injury of femoral vessels and aberrant obturator artery. Knowledge of anatomy of the preperitoneal space and the sites of releasing incision is essential to proceed with this approach. Midline preperitoneal approach could be the ideal approach for both incarcerated and strangulated FH as in our case. Dissection through an open incision makes the release of strangulation easier, and the anatomical structures are widely visible. Combined preperitoneal mesh with bowel resection can be performed through the same approach, but in our case, we preferred to avoid mesh insertion to avoid SSI. When FH is wrongly diagnosed as the cause of abdominal pain, this approach allows for proper evaluation of the intra-abdominal contents, and no additional incision is needed. The dissection of preperitoneal space is away from the inferior epigastric vessels and the triangle of doom. Chronic groin pain (CGP) was reduced by decreasing the risk of injury to the iliohypogastric nerve, ilioinguinal nerve, and genitofemoral nerve by posterior dissection. This approach helps the surgeons to apply a wide mesh to cover all the myopectineal orifices which include Hesselbach's triangle, indirect, femoral and obturator rings in the groin. Thus, the risk of recurrence, development of another groin hernia, and foreign body sensation would be reduced. Exploratory laparotomy with preperitoneal repair would reduce the risk of contamination from bowel ischemia and perforation. Furthermore, it can improve the rate of one-stage tension-free repair in incarcerated and strangulated FH with a lower postoperative complication rate. The preperitoneal approach could reveal other groin hernia not obvious on preoperative physical examination and avoid the adhesions of the previous inguinal surgery.¹³

Laparoscopic management for elective groin hernia is an accepted approach with low complications and excellent long-term outcome. The two most common approaches for repair of groin hernia are transabdominal preperitoneal (TAPP) and totally extraperitoneal (TEP). While laparoscopic repair of groin hernia has comparable results compared with open repair, it has several advantages over open repair such as

its ability to detect any concurrent contra-lateral hernias intra-operatively and the mesh placement is better than open repair since it covers all myopectineal orifices like inguinal, femoral, and obturator orifices. So laparoscopic approach is the treatment of choice for elective groin hernia repair all over the world.¹⁵⁻¹⁸

With the experience acquired in elective groin hernias repair laparoscopically, there is an increasing reliance on both the surgical technique and understanding the anatomy of the preperitoneal space. In addition, the experience gained from laparoscopic treatment of other surgical emergencies has led expert surgeons to manage emergency groin hernia laparoscopically. The first laparoscopic repair for emergency groin hernia was reported by Watson et al. in 1993. They reported totally laparoscopic approach for hernia repair combined with intestinal resection.¹⁹ In our case, we preferred open approach because of the age of the patient, dilated bowel in addition to our limited experience in laparoscopy in emergency situations.

Conclusion

The presence of a tender red swelling below the inguinal ligament should raise suspicion of strangulated FH particularly in elderly. Further investigations are required before incision and drainage.

Author contributions

M.S.E. contributed to study concept, design, data collection, interpretation, literature review, and writing. K.S.A. contributed to literature review and revision of the manuscript. N.A.A. contributed to revision of manuscript.

Availability of supporting data

The data sets used and/or analyzed during the current study are available from the corresponding author on reasonable request.

Declaration of conflicting interests

The author(s) declared no potential conflicts of interest with respect to the research, authorship, and/or publication of this article.

Ethical approval

Our institution does not require ethical approval for reporting individual cases or case series.

Funding

The author(s) received no financial support for the research, authorship, and/or publication of this article.

Informed consent

Written informed consent was obtained from the patient(s) for their anonymized information to be published in this article.

ORCID iD

Khaled S Ahmad  <https://orcid.org/0000-0002-7835-9422>

References

1. Campanelli G (ed.) *The art of hernia surgery: a step-by-step guide*. New York: Springer, 2018.
2. Jacob BP and Ramshaw B (eds) *The SAGES manual of hernia repair*. New York: Springer, 2012.
3. Henriksen NA, Thorup J and Jorgensen LN. Unsuspected femoral hernia in patients with a preoperative diagnosis of recurrent inguinal hernia. *Hernia* 2012; 16(4): 381–385.
4. Bakshi S. Infected femorocele: case report of an extremely rare surgical condition in a middle-aged lady suffering from a painful inguinal swelling. *Surgical Case Reports* 2019; 5(1): 1–5.
5. Rutkow IM. Demographic and socioeconomic aspects of hernia repair in the United States in 2003. *Surg Clin North Am* 2003; 83(5): 1045–1051v.
6. Dahlstrand U, Wollert S, Nordin P, et al. Emergency femoral hernia repair: a study based on a national register. *Ann Surg* 2009; 249(4): 672–676.
7. Kark AE and Kurzer M. Groin hernias in women. *Hernia* 2008; 12(3): 267–270.
8. Arenal JJ, Rodr -guez-Vielba P, Gallo E, et al. Hernias of the abdominal wall in patients over the age of 70 years. *Eur J Surg* 2002; 168(8-9): 460–463.
9. Koch A, Edwards A, Haapaniemi S, et al. Prospective evaluation of 6895 groin hernia repairs in women. *Br J Surg* 2005; 92(12): 1553–1558.
10. Bendavid R. Femoral pseudo-hernias. *Hernia* 2002; 6(3): 141–143.
11. Cooper A. *The anatomy and surgical treatment of abdominal hernia*. Philadelphia, PA: Lea & Blanchard, 1844.
12. Akinci M, Erg -l Z, Kulah B, et al. Risk factors related with unfavorable outcomes in groin hernia repairs. *Hernia* 2010; 14(5): 489–493.
13. Jiang XM, Sun RX, Huang WH, et al. Midline preperitoneal repair for incarcerated and strangulated femoral hernia. *Hernia* 2019; 23(2): 323–328.
14. Calik B, Karaman K, Atci R, et al. Visceral organ resection during femoral hernia surgery is a predictor of morbidity. *Int Surg* 2015; 100(3): 455–460.
15. Stoker DL, Spiegelhalter DJ, Singh R, et al. Laparoscopic versus open inguinal hernia repair: randomised prospective trial. *Lancet* 1994; 343(8908): 1243–1245.
16. Yang GP. Laparoscopy in emergency hernia repair. *Ann Laparoscop Endoscop Surg* 2017; 2: 107.
17. Schmedt CG, Leibl BJ and Bittner R. Endoscopic inguinal hernia repair in comparison with Shouldice and Lichtenstein repair. *Dig Surg* 2002; 19(6): 511–517.
18. Tschudi JF, Wagner M, Klaiber C, et al. Randomized controlled trial of laparoscopic transabdominal preperitoneal hernioplasty vs Shouldice repair. *Surg Endosc* 2001; 15(11): 1263–1266.
19. Watson SD, Saye W and Hollier PA. Combined laparoscopic incarcerated herniorrhaphy and small bowel resection. *Surg Laparosc Endosc* 1993; 3(2): 106–108.