

Porencephaly in dogs and cats: relationships between magnetic resonance imaging (MRI) features and hippocampal atrophy

Ai HORI¹⁾, Kiwamu HANAZONO^{1)**}, Kenjirou MIYOSHI¹⁾ and Tetsuya NAKADE^{1)*}

¹⁾Department of Small Animal Clinical Sciences, School of Veterinary Medicine, Rakuno Gakuen University, 582-1 Bunkyou-dai-Midorimachi, Ebetsu, Hokkaido 069-8501, Japan

(Received 11 July 2014/Accepted 26 February 2015/Published online in J-STAGE 16 March 2015)

ABSTRACT. Porencephaly is the congenital cerebral defect and a rare malformation and described few MRI reports in veterinary medicine. MRI features of porencephaly are recognized the coexistence with the unilateral/bilateral hippocampal atrophy, caused by the seizure symptoms in human medicine. We studied 2 dogs and 1 cat with congenital porencephaly to characterize the clinical signs and MRI, and to discuss the associated MRI with hippocampal atrophy. The main clinical sign was the seizure symptoms, and all had hippocampal atrophy at the lesion side or the larger defect side. There is association between hippocampal atrophy or the cyst volume and the severe of clinical signs, and it is suggested that porencephaly coexists with hippocampal atrophy as well as humans in this study.

KEY WORDS: canine, feline, hippocampus, MRI, porencephaly

doi: 10.1292/jvms.14-0359; *J. Vet. Med. Sci.* 77(7): 889–892, 2015

Porencephaly and hydranencephaly are recognized as the congenital cerebral cavities, filled with cerebrospinal fluid (CSF), usually connecting the ventricles to the subarachnoid space [2, 12, 13, 17]. Porencephaly and hydranencephaly are described similar morphological findings, but porencephaly is defined focal and less extensive defect in the cerebral walls compared with hydranencephaly [2, 12, 13, 17]. Porencephaly is caused by fetal or perinatal brain destruction, and the cerebral parenchyma defects can follow developmental or encephaloclastic disorder [2, 17]. Developmental porencephaly is based on neuronal migration disorder in the developing cerebral hemisphere, while encephaloclastic porencephaly is associated with cerebral injury resulting from ischemia, toxicity, trauma and infection (usually virus) during fetal stage [12, 13, 17]. In particular, there is frequently porencephaly following virus infections in cattle, sheep and goats; Akabane virus, bovine viral diarrhoea virus and schmallenberg virus [6, 8, 9, 12, 16]. On the other hand, there are few reports of porencephaly in dogs and cats [13]. Especially, magnetic resonance imaging (MRI) reports of these defects are less in veterinary medicine [17]. MRI is the most sensitive method for the detection of intracranial lesion, and it is suggested that porencephaly is often observed with the hippocampal atrophy in MRI features in humans

[7, 10]. Hippocampal atrophy is the remarkable findings in MRI, because the atrophy often causes medically refractory temporal lobe epilepsy (mesial temporal lobe epilepsy: MTLE). MTLE is different from other types of seizures in signs, symptoms and treatment [20]. MTLE tends to cause focal seizure, and the patients who underwent surgery for temporal lobe had significantly fewer seizures than the patients who had medical therapy [20]. Therefore, the hippocampal findings in MRI are necessary to decide treatment in humans [1, 7, 10]. In veterinary medicine, it is revealed that hippocampus would have damage after seizures in cats [5, 19]. Especially, in familial spontaneous epileptic cats, the visual hippocampal asymmetries are seen in MRI, and the significant asymmetry of hippocampal volume indicates hippocampal atrophy as well as humans [15]. However, hippocampal atrophy is controversial in epilepsy in dogs [11]. Thus, the purpose of this study was to characterize the clinical signs and MRI features of porencephaly in dogs and cats, and to discuss the associated MRI with hippocampal atrophy.

The cases included 2 dogs and 1 cat which were diagnosed with porencephaly at Rakuno Gakuen University Veterinary Teaching Hospital between 2005 and 2013. All cases were searched for breed, age, sex, body weight, clinical signs and MRI findings. The case summary is shown in Table 1. All animals were examined MRI of the brain under anesthesia. The MRI was a 0.2 Tesla open type (Signa Profile Open Spirit, GE Medical Systems, Tokyo, Japan). Images included transverse T2-weighted (First spin Echo, TR: 3500–4000, TE: 90–130, slice thickness 4.0–5.0 mm), T1-weighted (TR: 280, TE: 16) and T2-fluid-attenuated inversion recovery (T2-FLAIR) sequences. The MRI evaluated the presence of porencephaly, hippocampal atrophy and signal alterations (signal hyperintensity on T2-weighted and T2-FLAIR sequences) [10, 11]. In volumetric analysis, the cyst and hippocampus were outlined using a Dicom Viewer

*CORRESPONDENCE TO: NAKADE, T., Department of Small Animal Clinical Sciences, School of Veterinary Medicine, Rakuno Gakuen University, 582-1 Bunkyou-dai-Midorimachi, Ebetsu, Hokkaido 069-8501, Japan. e-mail: tnakade@rakuno.ac.jp

**PRESENT ADDRESS: Hanazono, K., Veterinary Teaching Hospital, Hokkaido University, Nishi 10, Kita 19, Kita-ku, Sapporo, Hokkaido 060-0819, Japan.

©2015 The Japanese Society of Veterinary Science

This is an open-access article distributed under the terms of the Creative Commons Attribution Non-Commercial No Derivatives (by-nc-nd) License <<http://creativecommons.org/licenses/by-nc-nd/3.0/>>.

Table 1. Case summary

Case number	Breed	Age/Sex	BW (kg)
dog 1	Cavalier King Charles spaniel	9m/F	5.80
dog 2	Toy Poodle	6m/F	3.20
cat 1	Mixed breed cat	2y2m/M	5.85

Table 2. Seizure and neurological findings

Case number	Seizure symptoms	Neurological findings
dog 1	Secondary generalized seizures	Chewing, excitement, fly-biting
dog 2	Complex focal seizures	Aggression, facial paralysis at the right side
cat 1	Generalized tonic-clonic seizures	Reduced vision (oculus dexter)

Table 3. MRI features

Case number	Location	Cyst ratio	Asymmetric ratio
dog 1	Left temporal, parietal, occipital lobes	0.17	32.5
dog 2	Left rostral, frontal, parietal lobes	0.1	15.5
cat 1	Left rostral, frontal, parietal, temporal, occipital lobes, connected with the right lateral ventricle	0.53	100

(AZE Virtual Place Lexus, Tokyo, Japan), and the volumes were multiplying the area of each slice (mm^2) with the slice interval. We evaluated cyst ratio as cyst volumes divided by total intracranial volume, and asymmetric ratio as the difference between right and left hippocampal volume divided by the larger hippocampus [10, 11]. In asymmetric ratio, 6% or more was regarded as the pathologic hippocampal atrophy according to Kuwabara *et al.* [11].

Although there was no considerable overlap with the breeds and age in dogs, there was generally a great preponderance of young age (Table 1). All cases were presented seizures without consciousness; dog 1 had secondary generalized seizures as focal seizures, dog 2 had complex focal seizures, and cat 1 had generalized tonic-clonic seizures (Table 2). Dog 1 had abnormal behavior, such as chewing and excitement, before generalized seizures, and the dog showed “fly-biting” after the seizures for 5–6 min. On the other hand, dog 2 had no generalized seizures, but had abnormal behavior, such as aggression. The behavior was thought as complex focal seizures like altered mentation. In addition, the dog was observed facial paralysis at the right side. Cat 1 had no neurological signs before generalized seizures, but the cat became excited for a period of time after seizures. The cat showed an increasing frequency of the seizures despite of treatment. The seizures were uncontrolled with phenobarbital (1.28 mg/kg twice per day). Also, the cat had reduced right vision in neurological examinations, since the cat was 6-month-old. In MRI features, the presence of porencephalic defect was cortical-subcortical cavitation at the left side in all animals (Table 3). The main extent of cyst was unilateral in all cases (Fig. 1). Cat 1 had the extended lateral ventricle like hydrocephalus, because the left cortical-subcortical defect at the temporal lobe connected with right lateral ventricle. There was also no preponderance of the location in all cases, but there was association with cyst ratio

and asymmetric ratio (Table 3). Hippocampus was visually detected in all cases, but the left hippocampus in cat 1 was not described. The less hippocampal volume or hippocampal loss was recognized at the main cyst side, and the asymmetric ratio had relevance to cyst ratio in all cases. In another matter, the right middle ear cavity in dog 2 had abnormal signals (Fig. 2).

Porencephaly is an unusual intracranial defect in dogs and cats, which described few reports in veterinary literature. In humans, it is recognized that the patients with congenital porencephaly have amygdalar-hippocampal atrophy and MTLE is secondary to the atrophy [10]. In this study, the seizure symptoms were striking. Dog 1 and dog 2 had focal seizures, whereas cat 1 had generalized seizures, which was uncontrolled. These abnormal neurological findings seem temporal lobe epilepsy [10]. It is reported that the main clinical sign in porencephaly is vestibulo-cerebellar sign [2–4, 12, 17]. However, there was no vestibulo-cerebellar sign in all cases, and compared with MRI, the clinical signs corresponded to the lesion: focal/generalized tonic-clonic seizures showed a forebrain disorder, in particular, reduced vision at oculus dexter in cat 1 was consistent with the left occipital lobe lesion. Though dog 2 had facial paralysis at the right side, otitis interna which was unrelated to porencephaly was observed as incidental findings in MRI. In addition, the otitis inflammation was located in part of tympanic bulla, so vestibular signs could have not been observed. In hippocampal volumetric analysis, we found a high prevalence of asymmetric hippocampus. All cases had the less hippocampal volume or hippocampal loss at the lesion side or the larger defect side. Furthermore, the severity of seizure symptoms was attributed to cyst ratio and asymmetric ratio; cat 1 had uncontrolled and increasing frequency of the seizures that were most serious, and the asymmetric ratio was the highest in all cases. In a recent report, it is suggested

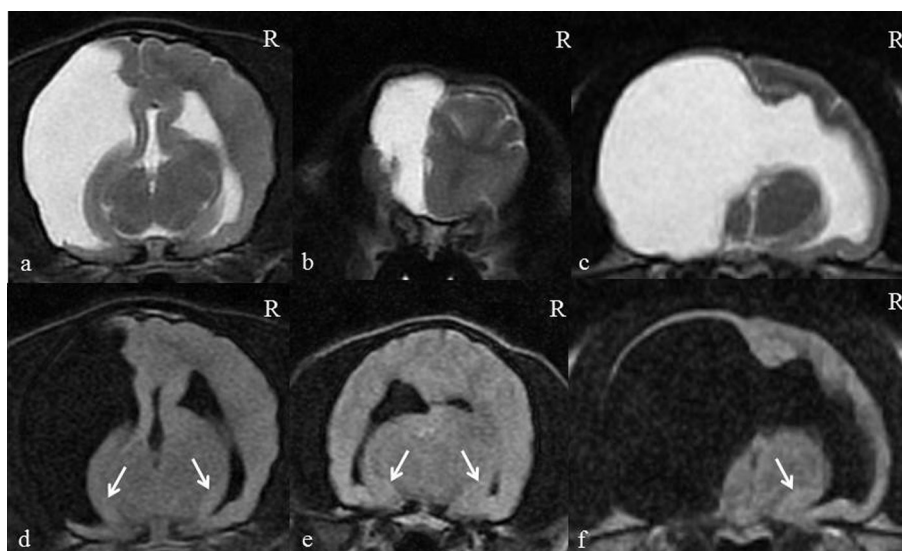


Fig. 1. MRI of cases with porencephaly. a, b; The lesion on transverse T2-weighted image in dogs 1–2, respectively. c; The lesion on transverse T2-weighted image in cat 1. d, e: The hippocampus (arrow) on transverse T2-FLAIR image in dogs 1–2, respectively. f: The right hippocampus (arrow) on transverse T2-FLAIR image in cat 1. The left hippocampus was not described, and it was suggested hippocampal loss.

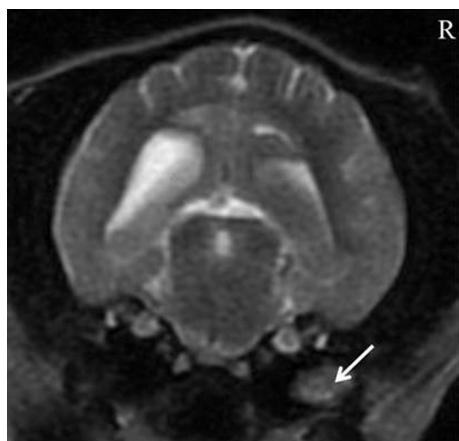


Fig. 2. T2-weighted MRI in dog 1. The lesion (arrow) was hyperintense on T2-weighted, T2-FLAIR and T1-weighted images at the right middle ear cavity. The enhancement was not seen.

that the seizure symptoms have relevance to hippocampal atrophy, but not the porencephalic location or morphology [10]. However, both cyst ratio and asymmetric ratio had correlation with the seizure symptoms in this study. In humans, the focus of seizures could be identified by electroencephalography (EEG), but the cases in this study did not undergo EEG because EEG studies with animals have needed sedation, which can affect cognitive processing [18]. Thus, we are required to suspect the lesion by the pattern of seizures. It is not possible to identify the focus of seizures in only MRI, but the cases in this study showed focal seizures and uncon-

trolled seizures like MTL. It suggests that mesial temporal lobe in the cases with porencephaly may cause the focus of seizures. In humans, the cause of mesial temporal sclerosis is not revealed, but it is indicated that hippocampal atrophy occurs due to ischemic or/and cerebral vascular occlusion [10]. Actually, cyst ratio had relevance to the asymmetric ratio as well as the severity of seizure symptoms. It means that the atrophy or loss may be caused by the cyst or seizures. The signal abnormalities were recognized in hippocampus after seizures, but there was no correlation between hippocampal atrophy and the damage of focal seizures in the patients with porencephaly [10]. In veterinary medicine, it is cleared that frequent seizures tend to cause necrosis of hippocampus and piriform lobe in cats with idiopathic epilepsy, but the lesions in the study were observed in bilateral, in contrast to the lesions of porencephaly [5]. Furthermore, it is revealed that the cats with typical limbic seizures have hippocampal atrophy [15]. However, the left hippocampus in cat 1 was not described completely in MRI, so it is suggested that the cat had congenital hippocampal loss in connection with porencephaly. According to Ho *et al.*, it is suggested that the reduced cerebral blood flow may damage the washed area [10]. In this study, the defect side corresponded with the hippocampal atrophy side, and the defects in all cases were located in the area, where the middle cerebral artery provides the blood supply [3]. Hippocampus is supplied the blood by the rostral choroidal artery, which is the branches of the middle cerebral artery [3]. Therefore, the reduced blood supply can cause porencephaly and the atrophy or loss like humans. We discussed few cases in this study, so we have to need evaluate hippocampal volume in more animals with porencephaly. Also, we used a spin-echo method, but we may have described the hippocampal atrophy more

clearly [14]. Unfortunately, the MRI volumetric analysis of the hippocampus is not measured generally by a gradient-echo method, because the importance of the hippocampus is controversial in veterinary medicine [10]. A gradient-echo method enables the measuring of the hippocampus in detail [14]. Furthermore, the pathogenesis may ensure whether the severity of the clinical sign has correlation with hippocampal atrophy or loss.

In conclusion, it is suggest that porencephaly coexists with the hippocampal atrophy as well as humans. We should evaluate carefully the hippocampal volume and asymmetry in MRI, because the atrophy may have relationships with porencephaly-related seizures.

REFERENCES

- Chan, S., Chin, S. S., Kartha, K., Nordli, D. R., Goodman, R. R., Pedley, T. A. and Hilal, S. K. 1996. Reversible signal abnormalities in the hippocampus and neocortex after prolonged seizures. *AJNR Am. J. Neuroradiol.* **17**: 1725–1731. [[Medline](#)]
- Davies, E. S. S., Volk, H. A., Behr, S., Summers, B., de Lahunta, A., Syme, H., Jull, P. and Garosi, L. 2012. Porencephaly and hydranencephaly in six dogs. *Vet. Rec.* **170**: 179–184. [[Medline](#)] [[CrossRef](#)]
- DeLahunta, A., Glass, E. and Kent, M. 2014. Neuroanatomy Gross Description and Atlas of Transverse Sections and Magnetic Resonance Images. pp. 6–44. *In: Veterinary Neuroanatomy and Clinical Neurology*, 4th ed., Saunders, Philadelphia.
- DeLahunta, A., Glass, E. and Kent, M. 2014. Cerebellum. pp. 368–408. *In: Veterinary Neuroanatomy and Clinical Neurology*, 4th ed., Saunders, Philadelphia.
- Fatzer, R., Gandini, G., Jaggy, A., Doherr, M. and Vandeveld, M. 2000. Necrosis of hippocampus and piliform lobe in 38 domestic cats with seizures: a retrospective study on clinical and pathologic findings. *J. Vet. Intern. Med.* **14**: 100–104. [[Medline](#)] [[CrossRef](#)]
- Garigliany, M. M., Hoffmann, B., Drive, M., Sartelet, A., Bayrou, C., Cassart, D., Beer, M. and Desmecht, D. 2012. Schmallenberg virus in calf born at term with porencephaly, Belgium. *Emerg. Infect. Dis.* **18**: 1005–1006. [[Medline](#)]
- Grattan-Smith, J. D., Harvey, A. S., Desmond, P. M. and Chow, C. W. 1993. Hippocampal sclerosis in children with intractable temporal lobe epilepsy: detection with MR imaging. *AJR Am. J. Roentgenol.* **161**: 1045–1048. [[Medline](#)] [[CrossRef](#)]
- Herder, V., Wohlsein, P., Peters, M., Hansmann, F. and Baumgartner, W. 2012. Salient lesions in domestic ruminants infected with the emerging so-called Schmallenberg virus in Germany. *Vet. Pathol.* **49**: 588–591. [[Medline](#)] [[CrossRef](#)]
- Hewicker-Trautwein, M. and Trautwein, G. 1994. Porencephaly, hydranencephaly and leukoencephalopathy in ovine fetuses following transplacental infection with bovine virus diarrhoea virus: distribution of viral antigen and characterization of cellular response. *Acta Neuropathol.* **87**: 385–397. [[Medline](#)] [[CrossRef](#)]
- Ho, S. S., Kuzniecky, R. I., Gilliam, F., Faught, E., Bebin, M. and Morawetz, R. 1998. Congenital porencephaly: MR features and relationship to hippocampal sclerosis. *AJNR Am. J. Neuro-radiol.* **19**: 135–141. [[Medline](#)]
- Kuwabara, T., Hasegawa, D., Kobayashi, M., Fujita, M. and Orima, H. 2010. Clinical magnetic resonance volumetry of the hippocampus in 58 epileptic dogs. *Vet. Radiol. Ultrasound* **51**: 485–490. [[Medline](#)] [[CrossRef](#)]
- Machado, G. F., Laranjeira, M. G., Schweigert, A. and de Melo, G. D. 2012. Porencephaly and cortical dysplasia as cause of seizures in a dog. *BMC Vet. Res.* **8**: 246–250. [[Medline](#)] [[CrossRef](#)]
- MacKillop, E. 2011. Magnetic resonance imaging of intracranial malformations in dogs and cats. *Vet. Radiol. Ultrasound* **52**: S42–51. [[Medline](#)] [[CrossRef](#)]
- Milne, M. E., Anderson, G. A., Chow, K. E., O'Brien, T. J., Moffat, B. A. and Long, S. N. 2013. Description of technique and lower reference limit for magnetic resonance imaging of hippocampal volumetry in dogs. *Am. J. Vet. Res.* **74**: 224–231. [[Medline](#)] [[CrossRef](#)]
- Mizoguchi, S., Hasegawa, D., Kuwabara, T., Hamamoto, Y., Ogawa, F., Fujiwara, A., Matsuki, N. and Fujita, M. 2014. Magnetic resonance volumetry of the hippocampus in familial spontaneous epileptic cats. *Epilepsy Res.* **108**: 1940–1944. [[Medline](#)] [[CrossRef](#)]
- Parsonson, I. M., Della-Porta, A. J. and Snowdon, W. A. 1977. Congenital abnormalities in newborn lambs after infection of pregnant sheep with Akabane virus. *Infect. Immun.* **15**: 254–262. [[Medline](#)]
- Schmidt, M. J., Klumpp, S., Amort, K., Jawinski, S. and Kramer, M. 2012. Porencephaly in dogs and cats: magnetic resonance imaging findings and clinical signs. *Vet. Radiol. Ultrasound* **53**: 142–149. [[Medline](#)] [[CrossRef](#)]
- Törnqvist, H., Kujala, M. V., Somppi, S., Hanninen, L., Pastell, M., Krause, C. M., Kujala, J. and Vainio, O. 2013. Visual event-potentials of dogs: a non-invasive electroencephalography. *Anim. Cogn.* **16**: 973–982. [[Medline](#)] [[CrossRef](#)]
- Wagner, E., Rosati, M., Molin, J., Foitzik, U., Wahle, A. M., Fischer, A., Matiasek, L. A., Reese, S., Flegel, T. and Matiasek, K. 2014. Hippocampal sclerosis in feline epilepsy. *Brain Pathol.* **24**: 607–619. [[Medline](#)] [[CrossRef](#)]
- Wiebe, S., Blume, W. T., Girvin, J. P. and Eliasziw, M. 2001. A randomized, controlled trial of surgery for temporal-lobe epilepsy. *N. Engl. J. Med.* **345**: 311–318. [[Medline](#)] [[CrossRef](#)]