



Original Article

Evaluation of effects of a modified asymmetric rapid maxillary expansion appliance on the upper airway volume by cone beam computed tomography



Mehmet Ali Yavan ^a, Seda Kaya ^b, Piraye Kervancioglu ^c,
Sayad Kocahan ^{d,e*}

^a Department of Orthodontics, Faculty of Dentistry, Adiyaman University, Adiyaman, Turkey

^b Department of Dentomaxillofacial Radiology, Hospital of Okmeydanı, Istanbul, Turkey

^c Department of Anatomy, Faculty of Medicine, Gaziantep University, Gaziantep, Turkey

^d Department of Physiology, Faculty of Medicine, Adiyaman University, Adiyaman, Turkey

^e International Scientific Center, Baku State University, Baku, Azerbaijan

Received 13 February 2020; Final revision received 19 May 2020

Available online 15 August 2020

KEYWORDS

Asymmetric rapid maxillary expansion;
Cone beam computed tomography;
Maxilla;
Upper airway volume

Abstract *Background/purpose:* The rapid maxillary expansion is accepted as the gold standard for the treatment of unilateral posterior crossbite in growing children. This study used cone beam computed tomography (CBCT) to evaluate the effects of a modified asymmetric rapid maxillary expansion (ARME) appliance on the upper airway volumes.

Materials and methods: A modified ARME appliance was used on 12 adolescent male patients (mean age: 13.92 ± 0.82 years) with a class I skeletal relationship and posterior unilateral crossbite. Lateral cephalometric measurements and upper airway volume were evaluated using CBCT images. The posterior airway volumes of the oropharyngeal and nasopharyngeal airways were measured.

Results: Cephalometric measurements showed significant ($P < 0.05$) posterior rotation of the mandible. There was no significant movement of the maxilla according to the cranial base on the sagittal plane. Nasopharyngeal and oropharyngeal airway volumes increased significantly ($P < 0.05$).

Conclusion: The results of this study demonstrate that treatment with the modified ARME has no significant effect on the maxilla but may increase the upper airway volume.

© 2020 Association for Dental Sciences of the Republic of China. Publishing services by Elsevier B.V. This is an open access article under the CC BY-NC-ND license (<http://creativecommons.org/licenses/by-nc-nd/4.0/>).

* Corresponding author. Department of Physiology, Faculty of Medicine, University of Adiyaman, Adiyaman, Turkey.

E-mail addresses: sayadkocahan@gmail.com, skocahan@adiyaman.edu.tr (S. Kocahan).

Introduction

Unilateral posterior crossbite (CB) is a common anomaly in orthodontics, seen in deciduous and early mixed dentition with a prevalence between 8% and 22%.^{1–3} Functional lateral shifts of the mandible accompanies this malocclusion in nearly 80% of cases induced by maxillary constriction.^{4,5} Rapid maxillary expansion is accepted as the gold standard for the treatment of unilateral posterior CB in growing children.^{6–9}

True unilateral maxillary CB does not show a mandibular functional shift, and therefore bilateral expansion may result in undesirable buccal nonocclusion on the non-CB (NCB) side.¹⁰ In the literature, several authors have designed various appliances that are reinforced by anchoring the mandible on the NCB side to achieve unilateral expansion.^{10–12} Marshall et al.¹² proposed a bonded RME device made of acrylic supported by mandible and occlusal locking on the NCB side. İleri and Başçiftçi¹¹ designed a tooth- and tissue-borne Asymmetric Rapid Maxillary Expansion (ARME) appliance with a locked mechanism on the NCB side and achieved satisfactory skeletal and dental unilateral expansion.

Researchers have used CBCT technology extensively in recent years to measure not only hard tissues but also upper airway volumes because of its lower radiation doses, shorter screening time, and total accuracy.^{13–15} Several studies have investigated the effects of RME appliances on dentoskeletal structures and upper airway volume^{16–19} however, no studies have yet reported the effects of asymmetric RME on upper airway volume.

The objectives of this study were to evaluate the effects of treatment with a modified ARME appliance on nasopharyngeal airway volume using CBCT.

Materials and methods

The experimental protocol used in this study was approved by the Regional Ethical Committee ofUniversity (No. 174). Information about the study design was given to patients and their parents, and each signed an informed consent form at the beginning of the study.

CBCT records were taken from 12 male patients (mean age: 13.92 ± 0.82 years) before and after being treated with a modified ARME. Patients were clinically evaluated and selected according to the following criteria: true unilateral CB (absence of crossbite on one side); the presence of a crossbite or cusp-to-cusp relationship involving at least three teeth on the contralateral side) with coincident midlines but without functional mandibular shift; class I skeletal relationship (ANB: 0° – 5°); normal vertical growth direction (SN-GoGn: 26° – 38°); normal or increased overbite; and erupted maxillary premolars.

Patients with craniofacial anomaly, cleft lip/palate, systemic or chronic diseases, physical or mental disorder, or previous orthodontic treatment were excluded from the study.

All patients were treated with modified ARME appliances. In the laboratory, upper and lower casts were placed with the fixator, guided by centric relation. Hyrax maxillary screws were placed at the level of second premolars and as close as possible to the palate. McNamara-type¹⁴ tooth-

borne acrylic splint RMEs were modified by adding a lingual acrylic block to the NCB side for unilateral expansion (Fig. 1). The thickness of the lingual acrylic block was 2 mm and extended from the palatal side of the maxillary posterior teeth to the lingual side of the mandibular posterior teeth on the unaffected side. The distance of the lingual acrylic block from the lingual aspects of the mandibular teeth was 2 mm, and the lower border of the appliance extended to a depth 3 mm apical to the lingual gingival margins of the mandibular posterior teeth. After occlusal adjustments, each appliance was cemented (T0).

Each expander was activated twice a day in the first week to overcome the resistance of the sutures and once per day after the sutures were mobilized. When the level of the palatal cusps of maxillary posterior teeth occluded with the buccal cusps of mandibular posterior teeth on the CB side, expansion was terminated. The average duration of activation was 3–4 weeks. The lingual acrylic block was then removed, and the screws were subsequently stabilized. Each expander was left as a retention appliance for the next 3 months. The modified ARME appliances were removed after an average of 3.8 months (T1).

CBCT images were taken with a Planmeca ProMax 3D Mid CBCT unit (Planmeca, Helsinki, Finland) operated at voxel size 0.2 mm, FOV 100×150 mm, and high resolution with 90 kV, 10 mA, and 18 sn with an axial slice thickness of 0.6 mm. The Frankfurt horizontal plane of patients was parallel to the floor with teeth in maximum intercuspation and patients were instructed not to swallow during imaging. Observations were carried out with dimmed lighting and a black background. Images were viewed with a 24-inch UltraSharp LED TFT Monitor (Dell, Austin, TX, USA) featuring a 2-megapixel camera and a 0.27-pixel pitch.

Romexis software (Planmeca, Helsinki, Finland) was utilized to acquire lateral cephalometric radiograms of patients from CBCT data for pretreatment (T0) and post-treatment (T1) appointments (Fig. 2). Custom transverse skeletal measurements were performed by separating CBCT images as crossbite (CB) and noncrossbite (NCB) according to the vertical plane as described by İleri and Başçiftçi¹¹ using Romexis software program (Fig. 3).

The lateral cephalograms were evaluated using the Dolphin Imaging 10.0 program (Dolphin Imaging & Management Solutions, Chatsworth, CA, USA) (Fig. 1). Eight linear and five angular measurements were evaluated (Fig. 4).

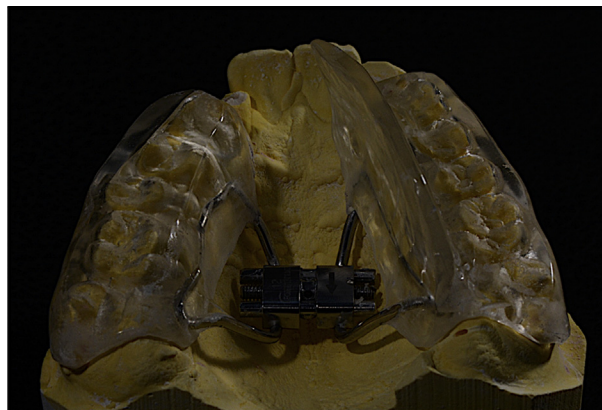


Figure 1 Modified asymmetric rapid maxillary expander.

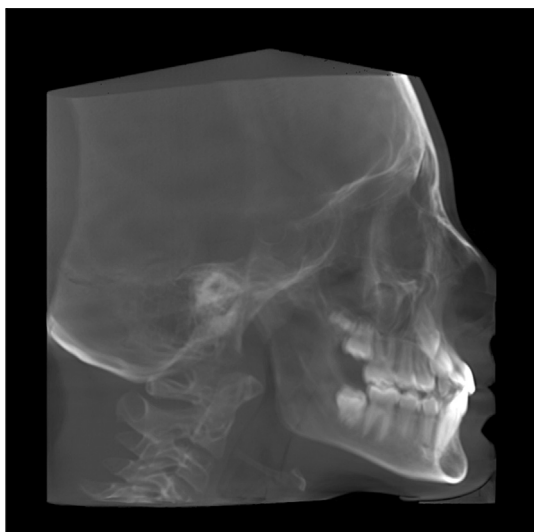


Figure 2 Lateral cephalometric radiogram.

Three-dimensional volumetric and area measurements (Fig. 5) were obtained using Stereoinvestigator software version 8.0 (Microbrightfield, Williston, VT, USA) by an experienced anatomist who had no knowledge of the

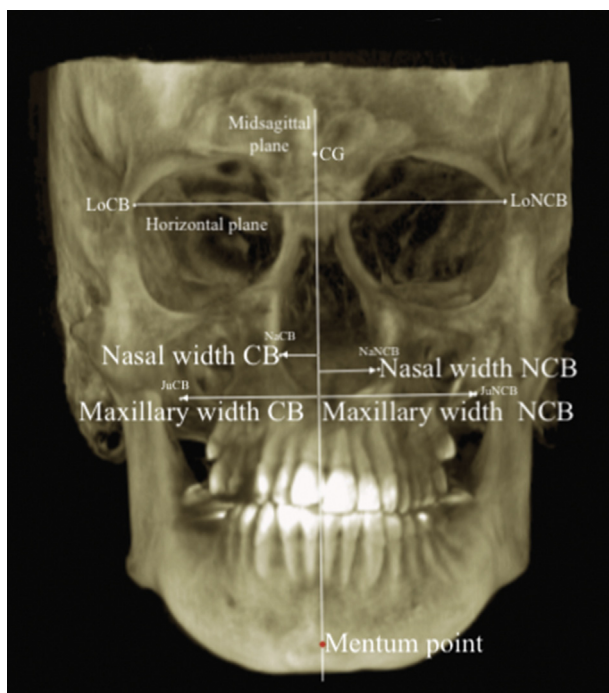


Figure 3 Transverse skeletal measurements of crossbite (CB) and noncrossbite (NCB) sides used in this study. Horizontal plane was constructed through the points LoCB and LoNCB; Midsagittal plane (MP) was constructed through Crista Galli (CG), perpendicular to horizontal plane; Nasal width CB, the distance between NaCB point to MP; Nasal width NCB, the distance between NaNCB point to MP; Maxillary width CB, the distance between JuCB point to MP; Maxillary width NCB, the distance between JuNCB point to MP; Me–MP, the distance between Mentum point to MP.

treatment. Upper airway volume was measured separately in the oropharyngeal and nasopharyngeal airways. The superior and inferior limits of oropharyngeal and nasopharyngeal airway volumes were determined based on a study by El and Palomo.²⁰

All measurements were repeated 5 weeks after the first evaluation to assess for method error by the same investigator (M.A.Y). The reliability of the measurements was evaluated with intraclass correlation coefficients as described by Houston.²¹ The coefficients of reliability for the measurements were greater than 0.936, confirming intraobserver reliability. The normality of the distribution of continuous variables was tested using the Shapiro–Wilk test. A paired *t*-test was used to compare two dependent groups of variables with normal distribution, but the Wilcoxon test was preferred when the distribution was not normal. Descriptive statistic parameters were presented as frequency, percentage (%), and mean \pm standard deviation (mean \pm SD). Statistical analysis was performed with SPSS for Windows version 22.0 and a *P* value $<$ 0.05 was accepted as statistically significant.

Results

Transversal skeletal measurements revealed that while maxillary and nasal widths in CB and NCB sides increased significantly ($P <$ 0.05) (Table 1), no significant differences were observed in these transversal expansions between the CB and NCB sides (Table 2). No significant change was observed in the Me–MP value ($P >$ 0.05) (Table 1).

Cephalometric measurements indicated that after treatment with the modified ARME, there was no significant movement of maxilla (SNA°) according to the cranial base in the sagittal plane ($P >$ 0.05). However, the mandible (SNB°) showed significant backward movement ($P <$ 0.05). There were no significant changes in upper and lower incisors positions and angulations according to the maxillary and mandibular base ($P >$ 0.05) (Table 1).

The effective maxillary (Co-A) and mandibular (Co-Gn) lengths increased significantly during the treatment ($P <$ 0.05) and significant mandibular posterior rotation ($SN/GoGn^\circ$) was observed ($P <$ 0.05). However, no significant change was seen in the palatal plane angle (SN/PP°) ($P >$ 0.05) (Table 1).

Changes in nasopharyngeal and oropharyngeal area measurements did not show any significant differences between time points ($P >$ 0.05). Volumetric evaluation showed that significant increases were found in the nasopharyngeal airway volume (1864 mm³) and oropharyngeal airway volume (1340 mm³) after treatment with the modified ARME (Table 1).

Discussion

For the treatment of true unilateral crossbite cases, several designs and methods have been explored that expand the CB side but prevent the expansion of the NCB side.^{10,11,22,23} İleri and Başçiftçi¹¹ suggested an appliance for unilateral expansion called ARME that is teeth- and tissue-borne. To prevent the expansion of the NCB side, a lingual acrylic block was added, the acrylic part was extended to the

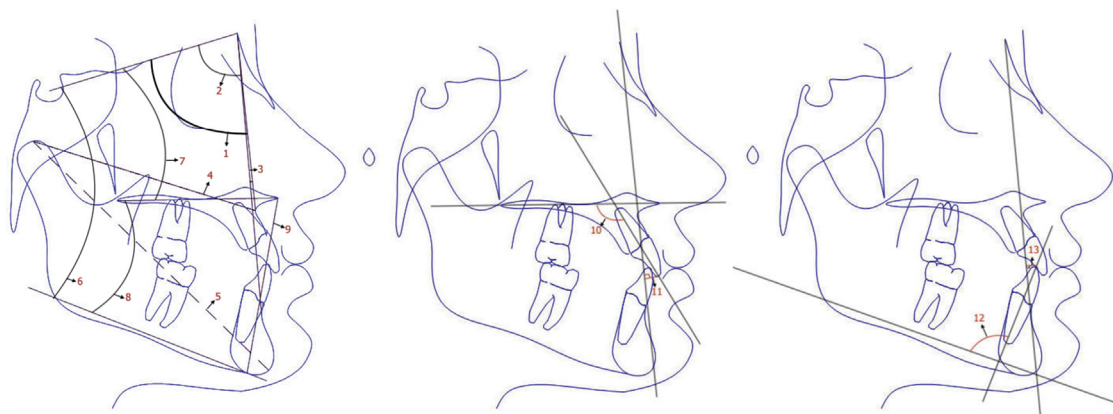


Figure 4 Lateral cephalometric measurements used in this study. 1, SNA in degrees, angle formed by the planes of sella-nasion and nasion-point A; 2, SNB in degrees, angle formed by the planes of sella-nasion and nasion-point B; 3, ANB in degrees, angle formed by the planes of nasion-point A and nasion-point B; 4, Midface length (Co-A) in millimeters, the distance between condylion point and A point; 5, Effective mandibular length (Co-Gn) in millimeters, the distance between condylion point and gnathion point; 6, SN/GoGn in degrees, angle formed by the planes of sella-nasion plane and gonion-gnathion; 7, SN/PP in degrees, angle formed by the planes of sella-nasion and ANS-PNS; 8, PP/MP in degrees, angle formed by the planes of gonion-gnathion and ANS-PNS; 9, ANS-Me in millimeters, distance between ANS point and menton point; 10, U1/PP in degrees, angle formed between the ANS-PNS plane and U1 plane; 11, U1-NA in millimeters, the perpendicular distance of U1 point to the nasion-point A plane; 12, IMPA in degrees, angle formed between the mandibular plane and L1 plane; 13, L1-NB in millimeters, the perpendicular distance of L1 point to the nasion-point B plane.

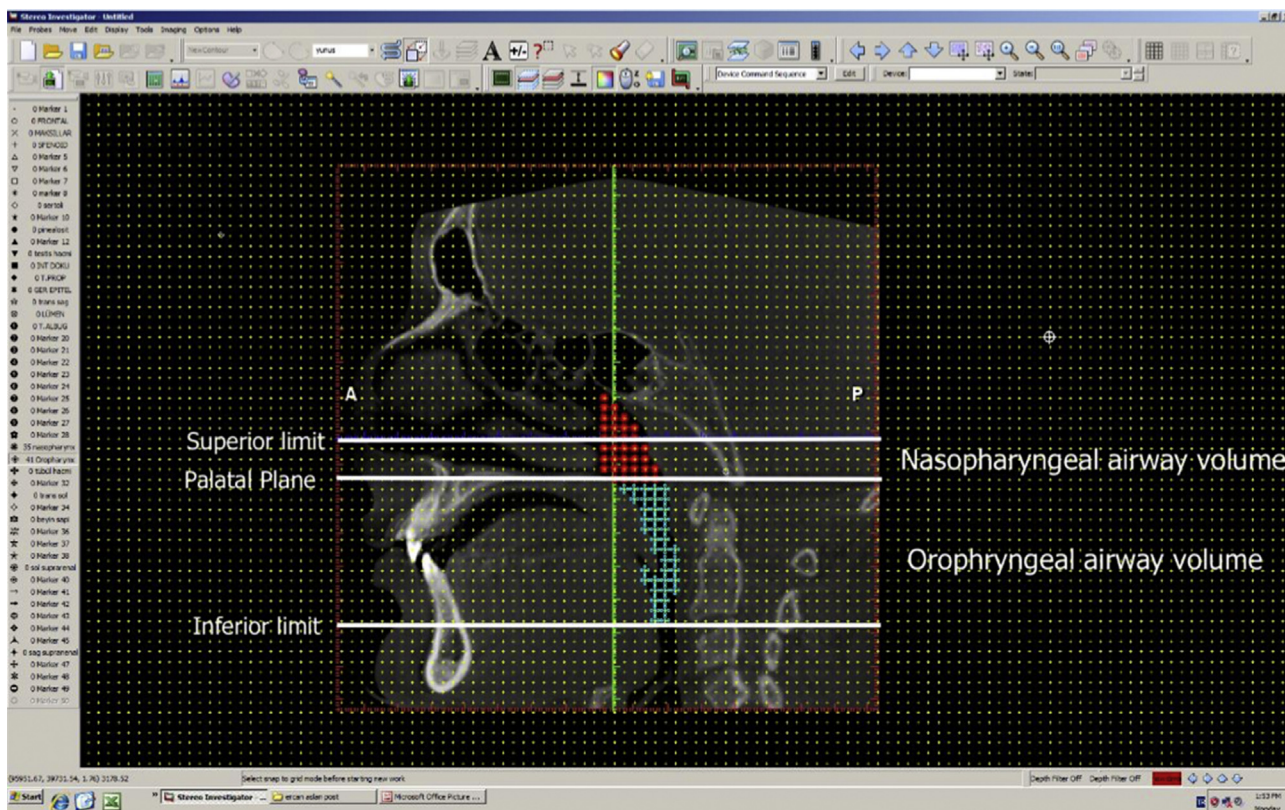


Figure 5 Stereoinvestigator software program. Superior limit represents the line passing from the nasal septum fuses with the posterior wall of the pharynx and parallel to Palatal plane. Inferior limit represents the line passing from the most anteroinferior aspect of the second cervical vertebrae and parallel to Palatal plane.

Table 1 Descriptive statistics and statistical comparisons of cephalometric measurements and airway volumes before and after treatment with ARME.

	T0		T1		Difference	Significance
	Mean	SD	Mean	SD	Mean \pm SD	
Cephalometric measurements						
SNA ($^{\circ}$)	79.20	4.06	79.36	3.86	0.16 \pm 0.91	NS
SNB ($^{\circ}$)	76.45	2.43	76.05	2.16	-0.39 \pm 0.72	NS
ANB ($^{\circ}$)	2.72	2.68	3.25	2.24	0.52 \pm 1.09	NS
Co-A (mm)	91.16	6.43	92.23	5.94	1.06 \pm 1.48	*
Co-Gn (mm)	130.07	7.03	131.22	7.05	1.15 \pm 1.49	*
SN/GoGn ($^{\circ}$)	34.42	3.58	35.84	3.27	1.41 \pm 0.73	**
SN/PP ($^{\circ}$)	9.88	2.50	9.80	2.27	-0.07 \pm 0.55	NS
PP/MP ($^{\circ}$)	28.64	5.34	30.95	5.24	2.31 \pm 1.65	***
ANS-Me (mm)	70.35	5.19	72.64	5.11	2.28 \pm 2.21	**
U1/PP ($^{\circ}$)	109.52	6.16	108.9	5.63	-0.62 \pm 0.79	NS
U1-NA (mm)	4.59	2.98	3.79	2.40	-0.80 \pm 1.92	NS
IMPA ($^{\circ}$)	87.54	4.83	87.48	5.27	-0.06 \pm 1.06	NS
L1-NB (mm)	5.06	2.20	5.15	2.23	-0.08 \pm 0.54	NS
Transverse skeletal measurements						
Maxillary CB (mm)	30.91	2.61	32.97	2.48	2.06 \pm 1.26	**
Maxillary NCB (mm)	30.40	1.56	31.41	1.94	1.01 \pm 1.67	*
Intermaxillary width (mm)	61.31	2.91	64.40	2.98	3.09 \pm 1.95	**
Nasal CB (mm)	13.01	1.99	14.37	1.82	1.35 \pm 0.82	**
Nasal NCB (mm)	13.08	2.10	14.08	2.29	1.00 \pm 0.94	**
Internasal width (mm)	27.01	3.65	28.49	2.97	1.47 \pm 2.67	*
Me-MP (mm)	1.78	1.26	1.58	1.31	-0.20 \pm 1.28	NS
Upper airway measurements						
Nasopharyngeal airway volume (mm ³)	8431.5	309.6	10295.3	342.4	1864.2 \pm 155.3	**
Oropharyngeal airway volume (mm ³)	18104.4	767.6	19443.2	795.8	1340.5 \pm 129.6	**
Nazopharynx area (mm ²)	430.9	166.3	426.9	153.0	-4.0 \pm 12.02	NS
Oropharynx area (mm ²)	876.5	371.2	875.3	291.7	-1.2 \pm 18.9	NS

SD: Standard deviation, mm: milimeter, CB: Crossbite side, NCB: Noncrossbite side, NS: Not significant, *: P < 0.05, **P < 0.005.

vestibule surface, and an occlusal bite was formed on the NCB side.

In the present study, a McNamara-type teeth-borne, splint-type bonded RME was modified because it is more hygienic and previous studies showed no significant differences between teeth-borne and teeth-tissue-borne RME appliances.^{24,25} Only a lingual acrylic block was added to strengthen the anchorage on the NCB side by including the mandibular dentoalveolar structure, because our goal was not to completely prevent the expansion of NCB side but only to prevent buccal nonocclusion. This modification was thought to be more comfortable for and better-tolerated by patients.

Previous studies investigating the effects of asymmetric expansion appliances evaluated changes in dentoskeletal structures using dental casts, cephalometric radiographs,

and CBCT.^{10-12,22} However, no studies were found that dealt with the effects of asymmetric RME on upper airway volume. Therefore, oropharyngeal and nasopharyngeal airway volumes were evaluated in addition to maxillary and mandibular skeletal linear and axial measurements in this study.

The midsagittal plane was used as a vertical reference to evaluate interskeletal differences between the CB and NCB sides after treatment with the ARME appliance. The midsagittal plane has been used in previous CBCT studies to assess asymmetry and asymmetric expansion studies.^{4,15-17}

The maxillary arch was expanded by separating the maxillary suture using a modified ARME. Transversal skeletal linear measurements demonstrated that total maxillary and nasal expansions were significant, in accordance with other RME studies.^{10,18,19} The maxillary and nasal

Table 2 Comparison of changes in maxillary and mandibular measurements between the crossbite and noncrossbite sides.

	Crossbite side		Noncrossbite side		Significance
	Mean	SD	Mean	SD	
Maxillary width (mm)	2.06	1.26	1.01	1.67	NS
Nasal width (mm)	1.35	0.82	1.00	0.94	NS

NS: Not significant, mm: milimeter

widths of the CB and NCB sides were increased significantly. In our study, expansion of the CB side (maxillary width expansion: 2.06 mm, nasal width expansion: 1.35 mm) surpassed that of the NCB side (maxillary width expansion: 1.01 mm, nasal width expansion: 1.00 mm); however, no significant differences were observed between the CB and NCB sides in the final maxillary and nasal widths post-treatment. Contrary to our findings, Baka et al.²⁶ and İleri and Başçiftçi¹¹ found significant differences between the CB and NCB sides in their skeletal measurements of maxilla. These different findings may be explained by the varied modification of RME appliances. In previous studies, anchorage was strengthened more rigidly with an occlusal locking mechanism that included acrylic blocks that were extended not only on the lingual side but also buccally.^{4,16} In contrast to the appliances used in previous studies,^{11,26} our device had a^{11,26} non-rigid acrylic block added onto the NCB therefore we did not observe significant differences in expansion between two sides.

There were no significant changes in the mentum point position at the midsagittal plane in this study. This outcome may be attributed to the removal of the acrylic block from the NCB side immediately after active expansion, which may have shifted force onto the mandibular alveolar bone on the NCB side. Contrary to our findings; İleri and Başçiftçi¹¹ showed significant increment in NCB side but significant decreasing in CB side. This outcome may be caused by applying rigid anchorage unit which caused shifting mandible to NCB side.

Cephalometric results showed that after treatment with the modified ARME, maxilla did not change significantly in the sagittal (SNA) plane according to the cranial base, and no significant change was observed in maxillary rotation (SN/PP). These outcomes were in accordance with the findings of İleri and Başçiftçi.¹¹ There was a significant decrease in the SNB angle, which shows mandibular position according to the cranial base, and therefore a significant increase was seen in the mandibular plane angle (SN/GoGn). Early premature contacts of posterior teeth after treatment with the modified ARME may result in these outcomes, which is in agreement with İleri and Başçiftçi.¹¹ Changes in the position of the upper and lower incisors were not significant; these results are also in accordance with those of İleri and Başçiftçi.¹¹ The effective maxillary (Co-A) and mandibular (Co-Gn) lengths increased significantly during the treatment, possibly due to the inclusion of subjects undergoing a growth period. McNamara²⁷ reported that males experienced their highest rates of effective maxillary and mandibular length increases between the ages of 12–16 years.

The effects of RME treatments on nasopharyngeal airway volume have been investigated in numerous CBCT studies.^{18–20,28,29} Maxillary expansion may decrease nasal resistance and encourages the alteration of respiratory modality from mouth to nose breathing.^{30–32} Therefore, expansion of maxilla by opening midpalatal suture and widening nasal floor was thought to increase the nasal airway. A significant increase in nasal airway volume was found (1864 mm³) in this study. Our results confirm those of El and Palomo,²⁰ who found that nasopharyngeal airway volume doubled (1719 mm³), a significant increase compared to control subjects after RME treatment. There

was no significant change in nasopharyngeal area after treatment with an ARME. There was no correlation between two and three-dimensional airway measurement changes in this study, which is in agreement with Lenza et al.³³

Obstructive sleep apnea (OSA) arises from an impairment of pharyngeal dilator function and airway decline at the hypopharynx (base of the tongue) or at the oropharynx (soft palate).³⁴ Numerous studies have suggested that maxillary transversal deficiency may underlie the development of OSA.^{35–37} Recently, RME has been recommended as a treatment for OSA. Maxillary expansion can increase the volume of the nasal cavity and enlarge the chamber of the tongue.^{18,20,28} Such anatomical alterations result in the anterior repositioning of the tongue and lead to a widening of the oropharyngeal space.³⁸

In this study, a significant increase of 1340 mm³ was observed in oropharyngeal airway volume after treatment with the modified ARME. Despite the posterior mandibular rotation, this increment may be related to growth and forward position of tongue. While Zhao et al.¹⁹ concluded that oropharyngeal airway volume wouldn't be increased by RME; Ribeiro et al.³⁹ noted significant change in the oropharynx after the RME. El and Palomo also²⁰ indicated that the oropharyngeal airway increased to 1273 mm³ in the RME group but no significant difference was found between RME and control groups in oropharyngeal airway volume increments.

The most important limitations of this study were the lack of control group with a unilateral CB to compare growth changes; however, exposing such patients to radiation without treating them is not ethically acceptable. This study demonstrated the short-term effects of a modified ARME appliance. Future studies with longer follow-up times and larger sample sizes are needed to assess the relapse rate, changes in the hypopharyngeal airway volume, and effects of age and gender as well as to compare different asymmetric RME appliances and their effects on condyles.

In conclusion, a Modified ARME appliance produces significant skeletal expansions in true unilateral crossbite cases and significant volumetric increases were observed in nasopharyngeal and oropharyngeal airways.

Declaration of Competing Interest

There is no potential conflict of interests.

References

1. Egermark-Eriksson I, Carlsson G, Magnusson T, Thilander B. A longitudinal study on malocclusion in relation to signs and symptoms of cranio-mandibular disorders in children and adolescents. *Eur J Orthod* 1990;12:399–407.
2. Kutin G, Hawes RR. Posterior cross-bites in the deciduous and mixed dentitions. *Am J Orthod* 1969;56:491–504.
3. Thilander B, Myrberg N. The prevalence of malocclusion in Swedish schoolchildren. *Eur J Oral Sci* 1973;81:12–20.
4. Kuroi J, Berglund L. Longitudinal study and cost-benefit analysis of the effect of early treatment of posterior cross-bites in the primary dentition. *Eur J Orthod* 1992;14:173–9.

5. Thilander B, Wahlund S, Lennartsson B. The effect of early interceptive treatment in children with posterior cross-bite. *Eur J Orthod* 1984;6:25–34.
6. Bell RA. A review of maxillary expansion in relation to rate of expansion and patient's age. *Am J Orthod* 1982;81:32–7.
7. Hesse KL, Årtun J, Joondoph DR, Kennedy DB. Changes in condylar position and occlusion associated with maxillary expansion for correction of functional unilateral posterior crossbite. *Am J Orthod Dentofacial Orthop* 1997;111:410–8.
8. Myers DR, Barenie JT, Bell RA, Williamson EH. Condylar position in children with functional posterior crossbites: before and after crossbite correction. *Pediatr Dent* 1980;2:190–4.
9. Wong CA, Sinclair PM, Keim RG, Kennedy DB. Arch dimension changes from successful slow maxillary expansion of unilateral posterior crossbite. *Angle Orthod* 2011;81:616–23.
10. Toroglu MS, Uzel E, Kayalioglu M, Uzel I. Asymmetric maxillary expansion (AMEX) appliance for treatment of true unilateral posterior crossbite. *Am J Orthod Dentofacial Orthop* 2002;122:164–73.
11. Ileri Z, Basciftci FA. Asymmetric rapid maxillary expansion in true unilateral crossbite malocclusion: a prospective controlled clinical study. *Angle Orthod* 2014;85:245–52.
12. Marshall SD, Southard KA, Southard TE. Early transverse treatment. In: *Proceedings from the seminars in orthodontics*. Abstract, 2005.
13. El H, Palomo JM. Measuring the airway in 3 dimensions: a reliability and accuracy study. *Am J Orthod Dentofacial Orthop* 2010;137: S50. e1-9.
14. Kwong JC, Palomo JM, Landers MA, Figueroa A, Hans MG. Image quality produced by different cone-beam computed tomography settings. *Am J Orthod Dentofacial Orthop* 2008;133:317–27.
15. Osorio F, Perilla M, Doyle DJ, Palomo JM. Cone beam computed tomography: an innovative tool for airway assessment. *Anesth Analg* 2008;106:1803–7.
16. Christie KF, Boucher N, Chung C-H. Effects of bonded rapid palatal expansion on the transverse dimensions of the maxilla: a cone-beam computed tomography study. *Am J Orthod Dentofacial Orthop* 2010;137:79–85.
17. Gohl E, Nguyen M, Enciso R. Three-dimensional computed tomography comparison of the maxillary palatal vault between patients with rapid palatal expansion and orthodontically treated controls. *Am J Orthod Dentofacial Orthop* 2010;138:477–85.
18. Görgülü S, Gokce SM, Olmez H, Sagdic D, Ors F. Nasal cavity volume changes after rapid maxillary expansion in adolescents evaluated with 3-dimensional simulation and modeling programs. *Am J Orthod Dentofacial Orthop* 2011;140:633–40.
19. Zhao Y, Nguyen M, Gohl E, Mah JK, Sameshima G, Enciso R. Oropharyngeal airway changes after rapid palatal expansion evaluated with cone-beam computed tomography. *Am J Orthod Dentofacial Orthop* 2010;137:71–8.
20. El H, Palomo JM. Three-dimensional evaluation of upper airway following rapid maxillary expansion: a CBCT study. *Angle Orthod* 2013;84:265–73.
21. Houston W. The analysis of errors in orthodontic measurements. *Am J Orthod* 1983;83:382–90.
22. Akin M, Baka ZM, Ileri Z, Basciftci FA. Alveolar bone changes after asymmetric rapid maxillary expansion. *Angle Orthod* 2014;85:799–805.
23. Hassan AH, AlGhamdi AT, Al-Fraidi AA, Al-Hubail A, Hajrassy MK. Unilateral cross bite treated by corticotomy-assisted expansion: two case reports. *Head Face Med* 2010;6:6.
24. Huynh T, Kennedy DB, Joondoph DR, Bollen AM. Treatment response and stability of slow maxillary expansion using Haas, hyrax, and quad-helix appliances: a retrospective study. *Am J Orthod Dentofacial Orthop* 2009;136:331–9.
25. Kanomi R, Deguchi T, Kakuno E, Takano-Yamamoto T, Roberts WE. CBCT of skeletal changes following rapid maxillary expansion to increase arch-length with a development-dependent bonded or banded appliance. *Angle Orthod* 2013;83:851–7.
26. Baka ZM, Akin M, Ucar FI, Ileri Z. Cone-beam computed tomography evaluation of dentoskeletal changes after asymmetric rapid maxillary expansion. *Am J Orthod Dentofacial Orthop* 2015;147:61–71.
27. McNamara JA, Brudon WL, Kokich VG. *Orthodontics and dentofacial orthopedics*. Michigan: Needham Press Ann Arbor, 2001:64–86.
28. Kurt G, Altug-Ataç AT, Atac MS, Karasu HA. Changes in nasopharyngeal airway following orthopedic and surgically assisted rapid maxillary expansion. *J Craniofac Surg* 2010;21:312–7.
29. Smith T, Ghoneima A, Stewart K, et al. Three-dimensional computed tomography analysis of airway volume changes after rapid maxillary expansion. *Am J Orthod Dentofacial Orthop* 2012;141:618–26.
30. Compadretti GC, Tasca I, Bonetti GA. Nasal airway measurements in children treated by rapid maxillary expansion. *Am J Rhinol* 2006;20:385–93.
31. De Felipe NL, Bhushan N, Da Silveira AC, Viana G, Smith B. Long-term effects of orthodontic therapy on the maxillary dental arch and nasal cavity. *Am J Orthod Dentofacial Orthop* 2009;136: 490. e1-8.
32. Monini S, Malagola C, Villa MP, et al. Rapid maxillary expansion for the treatment of nasal obstruction in children younger than 12 years. *Arch Otolaryngol Head Neck Surg* 2009;135:22–7.
33. Lenza M, Lenza MdO, Dalstra M, Melsen B, Cattaneo P. An analysis of different approaches to the assessment of upper airway morphology: a CBCT study. *Orthod Craniofac Res* 2010;13:96–105.
34. Riley RW, Powell NB, Guilleminault C. Obstructive sleep apnea and the hyoid: a revised surgical procedure. *Otolaryngol Head Neck Surg* 1994;111:717–21.
35. Luzzi V, Di Carlo G, Saccucci M, et al. Craniofacial morphology and airflow in children with primary snoring. *Eur Rev Med Pharmacol Sci* 2016;20:3965–71.
36. Johal A, Conaghan C. Maxillary morphology in obstructive sleep apnea: a cephalometric and model study. *Angle Orthod* 2004;74:648–56.
37. Seto BH, Gotsopoulos H, Sims MR, Cistulli PA. Maxillary morphology in obstructive sleep apnoea syndrome. *Eur J Orthod* 2001;23:703–14.
38. Camacho M, Chang ET, Song SA, et al. Rapid maxillary expansion for pediatric obstructive sleep apnea: a systematic review and meta-analysis. *Laryngoscope* 2017;127:1712–9.
39. Ribeiro AN, De Paiva JB, Rino-Neto J, Illipronti-Filho E, Trivino T, Fantini SM. Upper airway expansion after rapid maxillary expansion evaluated with cone beam computed tomography. *Angle Orthod* 2011;82:458–63.