

Haemorrhagic Pseudotumour Following Metal-on-Metal Hip Replacement

Joshua L. Filer¹, James Berstock¹, Ynyr Hughes-Roberts², Julian Foote¹, Harvey Sandhu¹

1. Trauma and Orthopaedics, Royal United Hospitals Bath, Bath, GBR 2. Radiology, Royal United Hospitals Bath, Bath, GBR

Corresponding author: Joshua L. Filer, joshua.filer@doctors.org.uk

Abstract

We present a unique report of a spontaneous haemorrhage into a pseudotumour five years following revision surgery for failed metal-on-metal hip arthroplasty. The patient sustained no trauma, was not taking anticoagulants and had no bleeding disorder. Rapid progression in the size of the pseudotumour caused significant symptoms and functional impairment. Surgical excision was recommended by a national specialist centre, but with conservative management, significant regression of the pseudotumour was noted, with complete resolution of symptoms. This case is the first report of haemorrhage into a pseudotumour, which is an important differential and can be managed non-operatively.

Categories: Radiology, Orthopedics

Keywords: pseudotumour, haemorrhage, bleeding, hip arthroplasty, metal-on-metal

Introduction

It has been widely documented that metal-on-metal hip arthroplasty is associated with adverse reactions to metal debris [1-5]. This reaction can lead to local tissue necrosis, fluid collection and the formation of inflammatory soft tissue masses known as 'pseudotumours' [2,3,5]. These pseudotumours are not uncommon although reported incidences vary with different implants, ranging from 0.6% to 61% [6-8].

Pseudotumours can be asymptomatic, but they can also cause pain, instability and gait disturbances, leading to the need for revision arthroplasty and/or excision of the soft tissue mass [3,9]. Although pseudotumours have also been implicated in lymphovascular complications resulting in venous thromboembolic events and swelling [10,11], to the best of our knowledge, spontaneous haemorrhage into a pseudotumour has not been described in the literature.

Although pseudotumours have been studied extensively [5,12-15], little is known about their natural history and controversy exists over their management, especially in asymptomatic patients [3,13,16]. Reports in the literature show that pseudotumours can grow in size, remain static, reduce in size and spontaneously resolve [13,16,17]. As a result of this varied natural history, it is difficult to decide how best to manage them both in the short and long term.

We describe a case of a pseudotumour that occurred at the site of a metal-on-metal hip replacement, which five years later had a large bleed into it with a late presentation. To our knowledge, this is the first case report of a haemorrhage into a pseudotumour. This is an important differential to recognise on cross-sectional imaging because it may not require surgical intervention.

Case Presentation

A 62-year-old woman underwent a left metal-on-metal total hip replacement in 2008 (CORAIL®, PINNACLE with a 36 mm bearing). After three years, in 2011, this patient presented with significant ongoing symptoms. She reported that she had suffered from pain and a sensation of clicking and clunking since her initial surgery. On questioning, she felt it was never right and thought it felt too big. As a result, she was fully investigated. As part of the workup, metal artefact reduction sequence magnetic resonance imaging (MARS-MRI) showed there was a metal-on-metal reaction with a pseudotumour present within the pelvis (Figure 1). The mass, albeit small, was cystic in nature with a characteristic rim of low signal on both T1 and short T1 inversion recovery sequences in keeping with haemosiderin deposition. Revision of the hip replacement was then performed in 2012 and the bearing was changed from a metal-on-metal bearing to a ceramic on highly cross-linked polyethylene bearing (trabecular metal component with the BioBall® system applied to the CORAIL® stem). Intra-operatively, there was a hip joint effusion, with markedly darkened abnormal intracapsular tissue. There was no other significant macroscopic pathology seen with no evidence of significant muscle or bone damage using the posterior approach. Following this revision procedure, the patient felt significantly better.

Review began 05/18/2021

Review ended 06/07/2021

Published 06/09/2021

© Copyright 2021

Filer et al. This is an open access article distributed under the terms of the Creative Commons Attribution License CC-BY 4.0., which permits unrestricted use, distribution, and reproduction in any medium, provided the original author and source are credited.

How to cite this article

Filer J L, Berstock J, Hughes-Roberts Y, et al. (June 09, 2021) Haemorrhagic Pseudotumour Following Metal-on-Metal Hip Replacement. Cureus 13(6): e15541. DOI 10.7759/cureus.15541

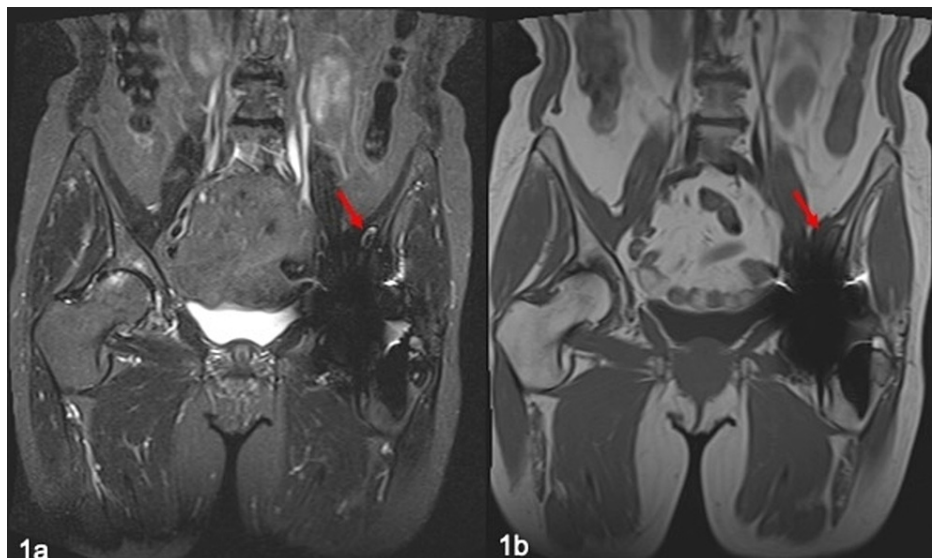


FIGURE 1: MRI of pseudotumour (red arrows) following metal-on-metal left hip arthroplasty in 2011.

(a) Coronal STIR; (b) coronal T1.

MRI: magnetic resonance imaging; STIR: short T1 inversion recovery

The patient returned to a high level of activity including gardening. However, five years later, the patient presented with spontaneous substantial bruising at the lateral aspect of the hip as well as bruising medially in the thigh. There was no history of trauma or injury. The pain was so severe that her mobility and ability to perform daily living activities were significantly impaired and morphine patches were required for a period of six months.

The patient was investigated with MARS-MRI, which showed a substantial interval increase in the size of the residual pseudotumour. The persistence of the characteristic low signal rim confirmed the expansion of the mass. New, diffuse areas of high T1 signal were seen throughout the mass in keeping with areas of haemorrhage. The pseudotumour was retroperitoneal, extending into the femoral canal measuring $30 \times 30 \times 140$ mm (Figure 2). Inflammatory markers and metal ion concentrations were reassuringly low. An aspiration of the hip was performed which confirmed blood products. Subsequent microscopy and culture investigations failed to detect any evidence of infection. A further MARS-MRI showed an increase in the size of this pseudotumour to $48 \times 42 \times 150$ mm.

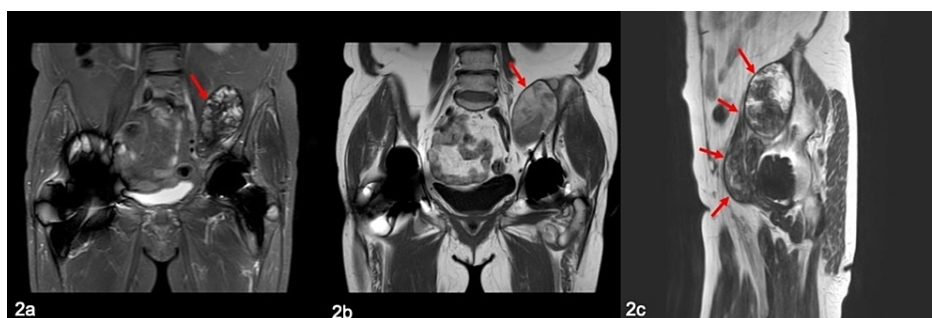

FIGURE 2: MRI of enlarging pseudotumour (red arrows) with evidence of haemorrhage in 2018.

(a) Coronal STIR; (b) coronal T1; (c) sagittal T2.

MRI: magnetic resonance imaging; STIR: short T1 inversion recovery

The patient was referred for a second opinion at a national unit renowned for its experience with metal-on-metal pathology. Haemorrhagic pseudotumours had not previously been identified at that unit either. After

careful consideration, surgery was offered to the patient to excise this tumour in a combined approach with the orthopaedic and vascular teams. However, the patient was concerned with the invasiveness of the surgery that was required and declined.

The patient was closely followed up, and at her last review, her symptoms had improved. The improvement in symptoms has allowed the patient to return to a good level of function such as gardening, albeit with mild intermittent discomfort.

Follow-up MARS-MRI scans have been performed, most recently in 2020, and there has been a substantial regression in the size of the pseudotumour, reducing to a size of 20 × 18 × 63 mm, which correlates with the improvement in the clinical picture, with the pseudotumour now barely visible on MRI (Figure 3).

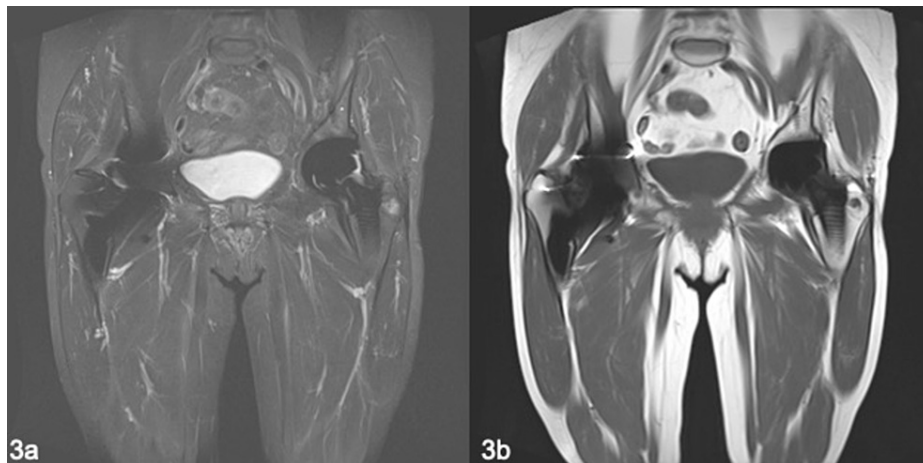


FIGURE 3: MRI of the pseudotumour in 2020 showing significant regression in size.

(a) Coronal STIR; (b) coronal T1.

MRI: magnetic resonance imaging; STIR: short T1 inversion recovery

Discussion

The purpose of this paper is to highlight an unusual case of haemorrhage into a pseudotumour, and how this was managed conservatively with activity modification and analgesia with good outcomes, despite operative treatment initially being considered.

Although it is recognised that pseudotumours can progress, regress, resolve or remain static [16,17], this case adds to our knowledge of the natural history and pathology of pseudotumours arising following metal-on-metal hip arthroplasty. In the case presented here, the pseudotumour was found to progress initially, causing significant pain and functional impairment. However, over a longer follow-up, it spontaneously regressed, with a commensurate improvement in symptoms and function.

Conclusions

To the best of our knowledge, there are no other reported cases of bleeding into a pseudotumour associated with metal-on-metal hip arthroplasty. This case presented a significant clinical challenge in decision-making regarding the appropriate management. Accordingly, appropriate multidisciplinary team advice and input were sought from radiologists, vascular surgeons and a national specialist unit with good experience managing metal-on-metal arthroplasty-related complications. Although it was felt that surgical excision of the pseudotumour would be beneficial, the patient declined the proposed treatment and decided to be managed conservatively with good outcomes both clinically and radiographically.

This case shows that a haemorrhagic pseudotumour is an important differential of a growing pseudotumour, which can be successfully managed conservatively.

Additional Information

Disclosures

Human subjects: Consent was obtained or waived by all participants in this study. **Conflicts of interest:** In

compliance with the ICMJE uniform disclosure form, all authors declare the following: **Payment/services info:** All authors have declared that no financial support was received from any organization for the submitted work. **Financial relationships:** All authors have declared that they have no financial relationships at present or within the previous three years with any organizations that might have an interest in the submitted work. **Other relationships:** All authors have declared that there are no other relationships or activities that could appear to have influenced the submitted work.

References

- Haddad FS, Thakrar RR, Hart AJ, et al.: Metal-on-metal bearings: the evidence so far. *J Bone Joint Surg Br.* 2011, 93:572-9. [10.1302/0301-620X.93B4.26429](https://doi.org/10.1302/0301-620X.93B4.26429)
- Natu S, Sidaginamale RP, Gandhi J, Langton DJ, Nargol AV: Adverse reactions to metal debris: histopathological features of periprosthetic soft tissue reactions seen in association with failed metal on metal hip arthroplasties. *J Clin Pathol.* 2012, 65:409-18. [10.1136/clinpath-2011-200398](https://doi.org/10.1136/clinpath-2011-200398)
- Sassoon AA, Barrack RL: Pseudotumour formation and subsequent resolution in metal-on-metal total hip arthroplasty following revision: instructional review and an illustrative case report with revision using a dual mobility design. *Bone Joint J.* 2016, 98-B:736-40. [10.1302/0301-620X.98B6.36908](https://doi.org/10.1302/0301-620X.98B6.36908)
- Langton DJ, Joyce TJ, Jameson SS, et al.: Adverse reaction to metal debris following hip resurfacing: the influence of component type, orientation and volumetric wear. *J Bone Joint Surg Br.* 2011, 93:164-71. [10.1302/0301-620X.93B2.25099](https://doi.org/10.1302/0301-620X.93B2.25099)
- Pandit H, Glyn-Jones S, McLardy-Smith P, et al.: Pseudotumours associated with metal-on-metal hip resurfacings. *J Bone Joint Surg Br.* 2008, 90:847-51. [10.1302/0301-620X.90B7.20213](https://doi.org/10.1302/0301-620X.90B7.20213)
- Wiley KF, Ding K, Stoner JA, Teague DC, Yousuf KM: Incidence of pseudotumor and acute lymphocytic vasculitis associated lesion (ALVAL) reactions in metal-on-metal hip articulations: a meta-analysis. *J Arthroplasty.* 2013, 28:1238-45. [10.1016/j.arth.2013.03.027](https://doi.org/10.1016/j.arth.2013.03.027)
- Hart AJ, Satchithananda K, Liddle AD, et al.: Pseudotumors in association with well-functioning metal-on-metal hip prostheses: a case-control study using three-dimensional computed tomography and magnetic resonance imaging. *J Bone Joint Surg Am.* 2012, 94:317-25. [10.2106/JBJS.J.01508](https://doi.org/10.2106/JBJS.J.01508)
- Bosker BH, Eetema HB, Boomsma MF, Kollen BJ, Maas M, Verheyen CC: High incidence of pseudotumour formation after large-diameter metal-on-metal total hip replacement: a prospective cohort study. *J Bone Joint Surg Br.* 2012, 94:755-61. [10.1302/0301-620X.94B6.28373](https://doi.org/10.1302/0301-620X.94B6.28373)
- Haynes JA, Stambough JB, Sassoon AA, Johnson SR, Clohisey JC, Nunley RM: Contemporary surgical indications and referral trends in revision total hip arthroplasty: a 10-year review. *J Arthroplasty.* 2016, 31:622-5. [10.1016/j.arth.2015.09.026](https://doi.org/10.1016/j.arth.2015.09.026)
- Maurer-Ertl W, Friesenbichler J, Liegl-Atzwanger B, Kuerzl G, Windhager R, Leithner A: Noninflammatory pseudotumor simulating venous thrombosis after metal-on-metal hip resurfacing. *Orthopedics.* 2011, 34:e678-81. [10.3928/01477447-20110826-32](https://doi.org/10.3928/01477447-20110826-32)
- Kawakita K, Shibanuma N, Tei K, Nishiyama T, Kuroda R, Kurosaka M: Leg edema due to a mass in the pelvis after a large-diameter metal-on-metal total hip arthroplasty. *J Arthroplasty.* 2013, 28:197.e1-4. [10.1016/j.arth.2012.04.016](https://doi.org/10.1016/j.arth.2012.04.016)
- Barrientos C, Brañes J, Llanos JL, Martinez A, Barahona M: Surgical treatment of intrapelvic pseudotumour after hip resurfacing arthroplasty: case report and literature review. *Case Rep Orthop.* 2018, 2018:3808362. [10.1155/2018/3808362](https://doi.org/10.1155/2018/3808362)
- Kwon YM, Liow MH, Dimitriou D, Tsai TY, Freiberg AA, Rubash HE: What is the natural history of "asymptomatic" pseudotumours in metal-on-metal hip arthroplasty? Minimum 4-year metal artifact reduction sequence magnetic resonance imaging longitudinal study. *J Arthroplasty.* 2016, 31:121-6. [10.1016/j.arth.2016.02.070](https://doi.org/10.1016/j.arth.2016.02.070)
- Matharu GS, Ostlere SJ, Pandit HG, Murray DW: What is the natural history of asymptomatic pseudotumours in metal-on-metal hip resurfacing patients?. *Hip Int.* 2016, 26:522-30. [10.5301/hipint.5000387](https://doi.org/10.5301/hipint.5000387)
- van der Veen HC, Reininga IH, Zijlstra WP, Boomsma MF, Bulstra SK, van Raay JJ: Pseudotumours, cobalt and clinical outcome in small head metal-on-metal versus conventional metal-on-polyethylene total hip arthroplasty. *Hip Int.* 2020, 30:56-63. [10.1177/1120700019832877](https://doi.org/10.1177/1120700019832877)
- Almoussa SA, Greidanus NV, Masri BA, Duncan CP, Garbuz DS: The natural history of inflammatory pseudotumors in asymptomatic patients after metal-on-metal hip arthroplasty. *Clin Orthop Relat Res.* 2013, 471:3814-21. [10.1007/s11999-013-2944-4](https://doi.org/10.1007/s11999-013-2944-4)
- van der Weegen W, Brakel K, Horn RJ, Hoekstra HJ, Sijbesma T, Pilot P, Nelissen RG: Asymptomatic pseudotumours after metal-on-metal hip resurfacing show little change within one year. *Bone Joint J.* 2015, 95-B:1626-31. [10.1302/0301-620X.95B12.32248](https://doi.org/10.1302/0301-620X.95B12.32248)