

CASE REPORT

An unusual presentation of carcinomatous meningitis

Chuan T. Foo^{1,*}, Louise M. Burrell² and Douglas F. Johnson¹¹Department of Medicine, Austin Health, Heidelberg, Victoria 3084, Australia, and ²Department of Medicine, University of Melbourne, Heidelberg, Victoria 3084, Australia

*Correspondence address. Department of Medicine, Austin Health, Heidelberg, Victoria 3084, Australia. Tel: +61-394965000; E-mail: chuan.foo@austin.org.au

Abstract

A 67-year old previously well male presented with a 1 week history of confusion on a background of 3 weeks of headache. Past history included two superficial melanomas excised 5 years ago. Treatment for meningoencephalitis was commenced based on lumbar puncture (LP) and non-contrast brain magnetic resonance imaging (MRI) results. Lack of a clinical response to antibiotics resulted in a second LP and contrast brain MRI which demonstrated hydrocephalus and leptomeningeal disease. Ongoing deterioration led to a whole-body computed tomographic and spinal MRI that showed widespread metastatic disease and extensive leptomeningeal involvement of the spinal cord. The diagnosis of metastatic melanoma with carcinomatous meningitis was made based on cytological analysis of cerebrospinal fluid. He died 2 weeks later in a palliative care facility. This case illustrates that the diagnosis of carcinomatous meningitis can be difficult to make as the heterogeneous nature of its presentation often delays the diagnosis.

INTRODUCTION

Carcinomatous meningitis is a rare and devastating complication of metastatic malignancies. It typically manifests with a mixture of neurological signs and symptoms including cranial and spinal nerve neuropathies, and cerebellar dysfunction. Failure to recognize the heterogeneous nature of the presentation can delay the diagnosis. Atypical presentations often confound the diagnostic effort further, as illustrated in this case, where the presenting complaint was confusion.

CASE REPORT

A 67-year old previously well male presented to hospital with 1 week of increasing confusion on a background of 3 weeks of tension-like headaches. A brain contrast-enhanced computed tomographic (CT) scan organized by his general practitioner three days prior to admission was normal.

On history the patient had no infective or neurological symptoms. No risk factors for atypical infections, medication or substance misuse were identified. On past medical history, a

stage IB superficial spreading melanoma and an in-situ melanoma had been excised from the right lower back and right shoulder 5 years previously (May and December 2010). He had regular follow-up by both Dermatology and Oncology including a review 6 months prior to this presentation, and no evidence of recurrence had been noted.

On examination, the patient was disorientated to time and place. Vitals were normal and there were no signs of meningism, new skin lesions or neurodeficits. The remainder of the clinical exam was normal.

The admission diagnosis was unspecified confusion. Initial investigations revealed leucocytosis 13.9×10^9 [reference interval: $4.0\text{--}10 \times 10^9$] with neutrophilia 12.1×10^9 ($2.0\text{--}7.5 \times 10^9$) and a C-reactive protein of 8.5 (<5.0). Platelets were 211×10^9 ($150\text{--}400 \times 10^9$) with an international normalized ratio of 1.0. Venous blood gas revealed carbon dioxide of 46 mmHg (35–45 mmHg) and blood glucose of 8.4 mmol/L (3.9–4.8 mmol/L). Urea and electrolytes, thyroid and liver function tests were normal.

A lumbar puncture (LP) performed on Day 1 revealed clear pale yellow cerebrospinal fluid (CSF) with a markedly low

Received: May 10, 2016. Revised: June 23, 2016. Accepted: June 25, 2016

© The Author 2016. Published by Oxford University Press.

This is an Open Access article distributed under the terms of the Creative Commons Attribution Non-Commercial License (<http://creativecommons.org/licenses/by-nc/4.0/>), which permits non-commercial re-use, distribution, and reproduction in any medium, provided the original work is properly cited. For commercial re-use, please contact journals.permissions@oup.com

glucose, high protein and a monocytic pleocytosis (Table 1). Opening pressure was not obtained. A gram stain was negative, and samples were sent for herpes viruses, *Enterovirus*, *Neisseria meningitidis*, tuberculosis (TB) and *Cryptococcus* testing. A limited non-contrast brain magnetic resonance imaging (MRI) showed a possible communicating hydrocephalus.

Following the LP, the patient was commenced on empirical treatment for meningococcal meningitis with intravenous benzylpenicillin, ceftriaxone and acyclovir. On Day 3, results of all microbiology tests returned negative. However, as the patient's clinical condition continued to deteriorate, antibiotics were continued and empiric treatment for TB meningitis was commenced on Day 5.

Differential diagnoses at this stage included progressive hydrocephalus and leptomenigeal disease. A repeat LP and gadolinium-enhanced brain MRI (Gd-MRI) were undertaken.

LP showed high opening pressure and a moderately blood-stained CSF. A markedly low glucose, high protein and monocytic pleocytosis were observed again (Table 1). The large number

Table 1: Cerebrospinal fluid analysis on Day 1 and Day 5 after admission

CSF Parameter	Day 1	Day 5
Opening Pressure	–	>30 cm/H ₂ O
Appearance	Pale Yellow	Bloodstained
Erythrocyte	1044	120 000
Leucocyte (<5)	20	130
Leucocyte Differential	19 Monocyte 1 Neutrophils	122 Monocytes 8 Neutrophils
Unidentified Cells	3	60
Gram Stain	Negative	Negative
Protein (<0.45 g/L)	4	2.3
Glucose (2.2–3.9 mmol/L)	0.4	0.3
Culture	Negative	Negative

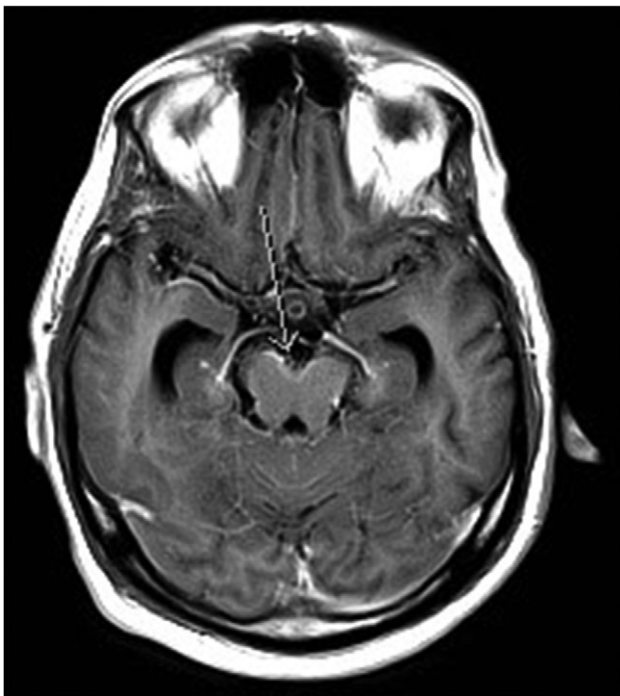


Figure 1: MRI brain T1 axial post contrast. Arrow indicates leptomenigeal enhancement in the interpeduncular cistern of the midbrain.

of unidentified cells prompted further cytopathological studies. Gd-MRI showed probable leptomenigeal enhancement within the interpeduncular cistern of the midbrain (Fig. 1) and a more definitive appearance of communicating hydrocephalus.

On Day 7, progressive deterioration resulted in intubation and transfer to the intensive care unit. An external ventricular drain was inserted and a whole-body CT was performed. This showed widespread metastases throughout the lungs, abdomen and lymph nodes. A spinal MRI also showed extensive leptomenigeal disease involving T11 to L4 (Fig. 2), and a nodular deposit at the level of L5 (Fig. 3).

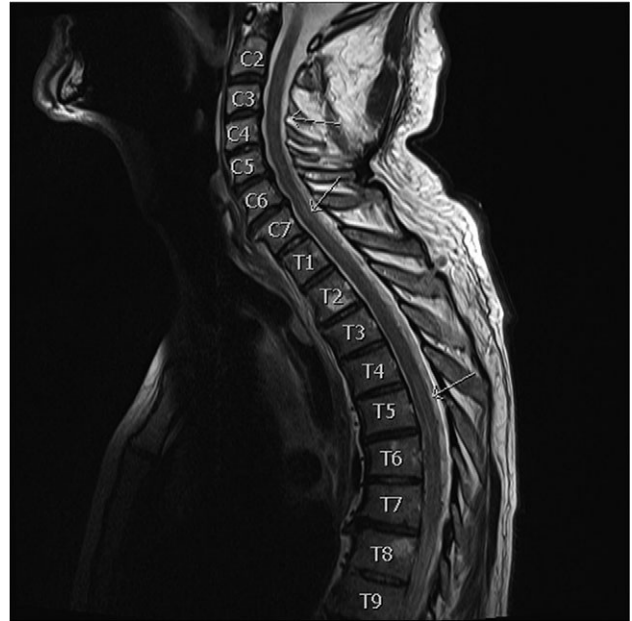

Figure 2: MRI spine T2 sagittal pre contrast. Arrow indicates areas of extensive spinal leptomenigeal involvement.

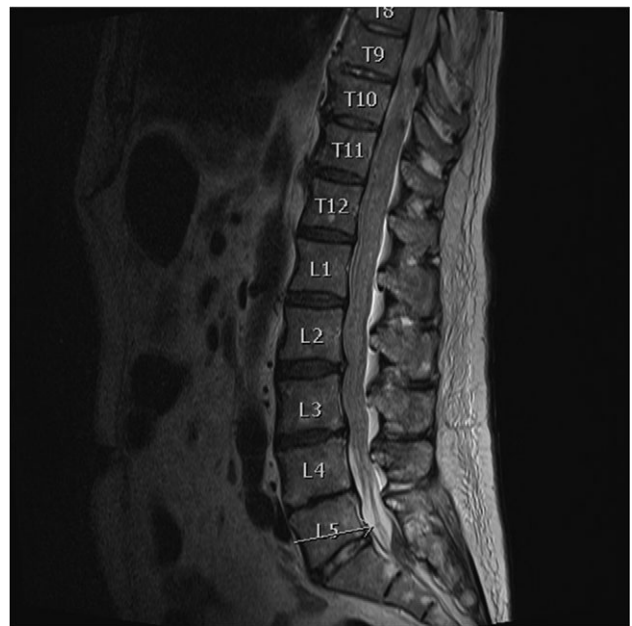


Figure 3: MRI spine T2 pre contrast. Arrow indicates possible nodular deposit at the level of L5.

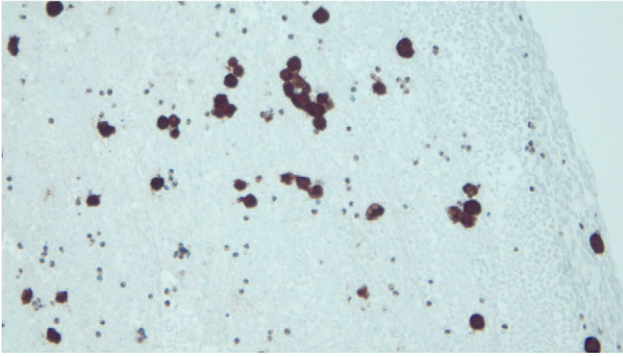


Figure 4: Melanoma cells staining positive for S-100 (black stain).

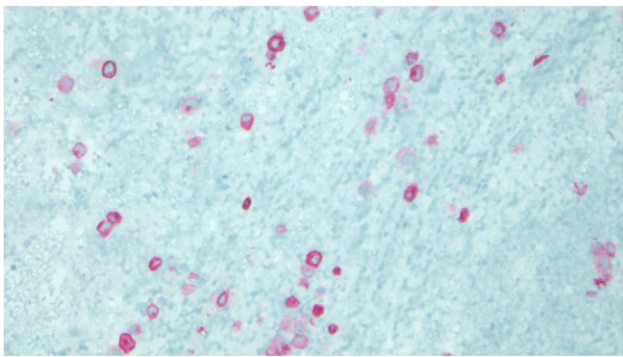


Figure 5: Melanoma cells staining positive for Melan-A (red stain).

At this point, abnormal cells staining positive for S-100 (Fig. 4), Melan-A (Fig. 5) and HMB-45 were identified in the 2nd CSF sample. A diagnosis of metastatic melanoma with carcinomatous meningitis was made.

Given the poor prognosis, he was transferred to a palliative care facility where he died 2 weeks later.

DISCUSSION

Carcinomatous meningitis (CM) is an infiltration of the leptomeninges by malignant cells. This occurs in 5% of metastatic tumours with breast (12–35%) and lung cancer (10–26%) being the most common [1].

CM usually affects multiple areas of the neuroaxis, manifesting clinically as a range of multifocal neurological signs and symptoms including cranial and spinal nerve neuropathies, altered mental status and cerebellar dysfunction [2]. Although symptoms of intracranial hypertension (headache and confusion) are frequently reported presentations, they are non-specific and rarely aid diagnosis, contributing to the diagnostic challenge in our case. Furthermore, the absence of other symptomatology despite extensive metastases is an interesting finding.

Key investigative tests include LP and Gd-MRI. The CSF typically demonstrates a low glucose (30–50% of cases), an elevated protein (70–90%) and lymphocytic pleocytosis (50–60%). Opening pressures should routinely be measured as this can be elevated in 50% of cases [3]. Definitive diagnosis requires the identification of malignant cells in the CSF. This is achieved in 50–70% of cases on initial LP, increasing to >90% after three LPs [4].

In this case, both CSF samples showed marked hypoglycorrhachia. Although hypoglycorrhachia has been reported in CM,

it is more commonly seen in infective aetiologies, with TB meningitis associated with the lowest glycorrhachia [5]. The marked similarity in CSF analysis between TB meningitis and CM in the absence of malignant cytology can be diagnostically challenging. Given our patient's deterioration, empirical TB therapy was commenced to treat this possibility.

A CSF protein of 4 g/L is noteworthy as it raises the possibility of Froin's syndrome, which is a combination of xanthochromia, high protein and heightened coagulation of CSF due to a blockage in CSF outflow [6]. While protein levels are classically >5 g/L, an evolving blockage may explain the levels seen in our case. The presence of extensive spinal leptomeningeal disease further supports this hypothesis.

Gd-MRI is the neuroimaging of choice. Typical findings include contrast enhancement of the leptomeninges and nodular deposits. As leptomeningeal disease may preferentially affect the spinal cord, spinal imaging should be considered in suspected cases despite unrevealing cranial imaging. Our case illustrates these points as leptomeningeal disease was more extensive in the spinal cord, and not visualized on either contrast-enhanced CT or non-contrast MRI.

Treatment of CM is based on the patient's condition and management of the malignancy. Options include radiotherapy, chemotherapy and supportive therapy. Overall prognosis is poor, with average survival of 4–6 weeks without treatment, increasing to 3–6 months with treatment [7].

In conclusion, this case illustrates an uncommon presentation of CM and highlights the challenges in its diagnosis. It raises the importance of recognizing late recurrence of melanoma is seen even in patients with early stage disease and may involve unexpected sites, causing atypical presentations.

CONFLICT OF INTEREST STATEMENT

None declared.

FUNDING

No funding received.

ETHICAL APPROVAL

No ethical approval required.

CONSENT

Next-of-kin consented.

GUARANTOR

C.F. is a guarantor.

REFERENCES

- Clarke JL, Perez HR, Jacks LM, Panageas KS, Deangelis LM. Leptomeningeal metastases in the MRI era. *Neurology* 2010; 74(18):1449–54.
- Clarke JL. Leptomeningeal metastasis from systemic cancer. *Continuum (Minneapolis Minn)* 2012;18(2):328–42.
- Taillibert S, Laigle-Donadey F, Chodkiewicz C, Sanson M, Hoang-Xuan K, Delattre JY. Leptomeningeal Metastases from solid malignancy: a review. *J Neurooncol* 2005;2005(75):85–99.
- Deisenhammer F, Bartos A, Egg R, Gilhus NE, Giovannoni G, Rauer S, et al. Routine cerebrospinal fluid analysis. In: Gilhus NE, Barnes MR, Brainin M, eds. *European Handbook of Neurological*

- Management*, Vol. 1. Hoboken, New Jersey, USA: Wiley-Blackwell, 2010; 5–17.
5. Chow E, Troy SB. The differential diagnosis of hypoglycorrhachia in adult patients. *Am J Med Sci* 2014;**348**(3): 186–90.
 6. Mohee K, Sekar V, Williams S, Goulding P. An unusual casue of raised CSF Protein. *Pract Neurol* 2013;**0**:1–3.
 7. Rhun EL, Taillibert S, Chamberlain MC. Carcinomatous meningitis: leptomeningeal metastases in solid tumors. *Surg Neurol Int* 2013;**4**(Suppl 4):S265–88.