



## Case report

## Clinical presentation of Churg–Strauss syndrome in children A 12-year-old-boy with ANCA-negative Churg–Strauss syndrome

Femke G.E.M. Razenberg<sup>a</sup>, Jan W.C.M. Heynens<sup>a</sup>, Geuwke Jan de Vries<sup>b</sup>, Liesbeth Duijts<sup>c,d</sup>,  
Johan C. de Jongste<sup>c</sup>, Jacques de Blic<sup>e</sup>, Philippe P.R. Rosias<sup>a,\*</sup>

<sup>a</sup> Department of Pediatrics, Orbis Medical Center, PO Box 5500, 6130 MB Sittard, The Netherlands

<sup>b</sup> Department of Pulmonology, Orbis Medical Center, Sittard, The Netherlands

<sup>c</sup> Department of Pediatrics, Division of Respiratory Medicine, Erasmus Medical Center, Rotterdam, The Netherlands

<sup>d</sup> Department of Epidemiology, Erasmus Medical Center, Rotterdam, The Netherlands

<sup>e</sup> Université Paris Descartes, Assistance Publique des Hôpitaux de Paris, Service de Pneumologie et Allergologie Pédiatriques, Hôpital Necker Enfants Malades, Paris, France

## ARTICLE INFO

## Article history:

Received 16 March 2012

Received in revised form

7 September 2012

Accepted 18 September 2012

## Keywords:

Asthma

Churg–Strauss syndrome

Child

Eosinophilia

Eosinophilic lung disease

Pulmonary infiltrate

Vasculitis

## ABSTRACT

Churg–Strauss syndrome is an uncommon multisystem disorder characterized by asthma, eosinophilia and vasculitis. We report on a 12-year-old boy with asthma and deterioration of his general condition, who was eventually diagnosed with an ANCA-negative Churg–Strauss syndrome. The propositus included, 50 cases of childhood Churg–Strauss syndrome have been reported. The patient characteristics and clinical characteristics of these children are summarized. The respiratory tract is most frequently involved with pulmonary infiltrates, asthma and sinusitis. Early recognition of childhood Churg–Strauss syndrome is important as delayed diagnosis can lead to severe organ involvement, and possible fatal outcome.

© 2012 Elsevier Ltd. Open access under [CC BY-NC-ND license](http://creativecommons.org/licenses/by-nc-nd/4.0/).

## 1. Introduction

Churg–Strauss syndrome (CSS), also called allergic granulomatosis and angiitis, is an uncommon multisystem disorder of unknown etiology, characterized by necrotizing vasculitis affecting small to medium-sized vessels (1). Patients usually present with a history of asthma, allergic rhinitis and prominent peripheral blood eosinophilia.<sup>2</sup>

CSS in childhood is rare and the clinical presentation can be quite diverse. Although CSS is an antineutrophil cytoplasmic antibody (ANCA)-associated vasculitis, ANCA in children are only found

in 40% of the cases.<sup>3,4</sup> Therefore, diagnosing CSS in children may be difficult. However, early recognition of the disease is important, as delayed diagnosis can lead to severe organ involvement, and sometimes fatal outcome.<sup>2</sup>

We report on a 12-year-old boy with asthma and deterioration of his general condition, who was eventually diagnosed with an ANCA-negative Churg–Strauss syndrome.

## 2. Case report

A 12-year-old boy presented with a dramatic deterioration of his general condition, characterized by extreme fatigue, weight loss (2.6 kg in three weeks), fever, a typical respiratory symptoms and abdominal pain.

Eleven months earlier, he presented with his first acute asthma exacerbation, which was treated with frequent nebulisation of ipratropium and salbutamol, and oxygen. Laboratory and pulmonary investigations showed a total immunoglobulin (Ig) E of 228 kU/l. Allergy tests were positive for grass and tree pollen. Spirometry demonstrated a reversible airway obstruction. Fractional exhaled nitric oxide (FeNO) was increased (38.5 ppb) at a time

*Abbreviations:* ACR, American College of Rheumatology; ANCA, antineutrophil cytoplasmic antibody; CCS, Churg–Strauss syndrome; CT, computed tomography; ELD, eosinophilic lung disease; FeNO, fractional exhaled nitric oxide; Ig, immunoglobulin.

\* Corresponding author. Tel.: +31 88 459783; fax: +31 88 4598623.

*E-mail addresses:* [femkerazenberg@hotmail.com](mailto:femkerazenberg@hotmail.com) (F.G.E.M. Razenberg), [j.heyne@orbisconcern.nl](mailto:j.heyne@orbisconcern.nl) (J.W.C.M. Heynens), [mi.devries@orbisconcern.nl](mailto:mi.devries@orbisconcern.nl) (G. Jan de Vries), [l.duijts@erasmumc.nl](mailto:l.duijts@erasmumc.nl) (L. Duijts), [j.c.dejongste@erasmumc.nl](mailto:j.c.dejongste@erasmumc.nl) (J.C. de Jongste), [j.deblic@nck.aphp.fr](mailto:j.deblic@nck.aphp.fr) (J. de Blic), [p.rosias@orbisconcern.nl](mailto:p.rosias@orbisconcern.nl) (P.P.R. Rosias).

when no steroids were taken, and normalized under maintenance therapy with salmeterol/fluticasone to 5.6 ppb (reference range of FeNO: low < 5 ppb; normal 5–20 ppb; increased 20–35 ppb; high > 35 ppb).

During summer holidays abroad, his general condition deteriorated progressively. Additional examinations revealed a leukocytosis ( $26.5 \times 10^9/L$ ) with nearly 50% eosinophils, whereas the total IgE increased to 2901 kU/L. One day after return from holidays he presented at our emergency department with respiratory distress, and was subsequently hospitalized for further investigations and therapeutical intervention.

Physical examination revealed cachexia, several skin lesions on the elbows, back and feet (Fig. 1), and two palpable subcutaneous nodules on the back. Breathing frequency was 23 per minute, transcutaneous oxygen saturation was 97%. Auscultation of lungs, heart and abdomen was normal. There was no hepatosplenomegaly. Neurological examination was normal.

White blood cell differentiation and blood smear confirmed leukocytosis ( $31.9 \times 10^9/L$ ) and hypereosinophilia ( $12.4 \times 10^9/l$ , 39% eosinophils). C-reactive protein and erythrocyte sedimentation rate were raised (66 mg/L and 64 mm/h, respectively). IgG and E levels were elevated (27.7 g/L and 2445 kU/l, respectively). Complement C3 and C4 were normal. Anti-nuclear antibody, anti-streptolysine-O, anti-DNAse B, p-ANCA, c-ANCA, MPO-ANCA and PR3-ANCA were all negative. Rheumatic factor was minimally elevated (22 U/L). Urinalysis, renal and liver function tests were normal.

Chest radiography and computed tomography (CT) revealed bilateral infiltrates with lower lobe predominance and peripheral consolidations, as well as some pericardial effusion (Fig. 2). Bronchoalveolar lavage fluid demonstrated leukocytes of  $1.8 \times 10^9/lL$  with 76% eosinophils. Biopsy of the skin lesion showed capillaritis with fibrin thrombi and eosinophilic inflammation. Biopsy of the subcutaneous nodule showed multinodular basophilic necrosis with eosinophilic inflammation. Both biopsies were suggestive of eosinophilic vasculitis (Fig. 3a, b).

The diagnosis of pulmonary infiltrates with eosinophilia, or eosinophilic lung disease (ELD) was made, based on eosinophilia in peripheral blood, pulmonary infiltrates, eosinophilia in bronchoalveolar lavage fluid, and eosinophilia in skin biopsy. ELD can be classified according to known and unknown etiology, and miscellaneous. Known causes of ELD are mostly infectious, e.g. parasitic infections or aspergillosis. Because ELD encompass a wide variety of disorders, broad therapeutical intervention was initially started with prednisone, ceftriaxone, azithromycin and itraconazole. Symptoms improved rapidly. Blood eosinophilia disappeared

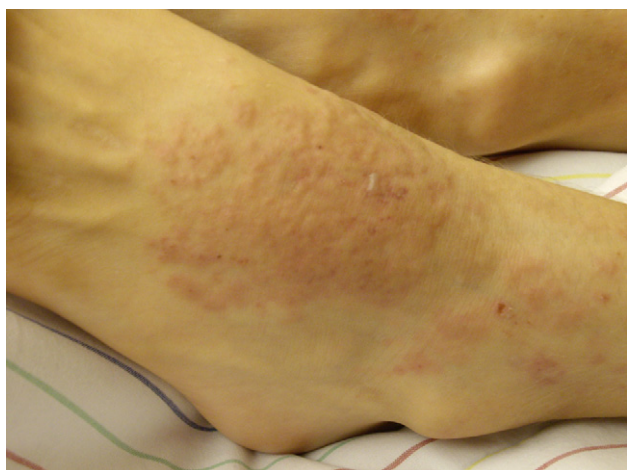

Fig. 1. Elevated skin lesions on the feet, compatible with vasculitis.

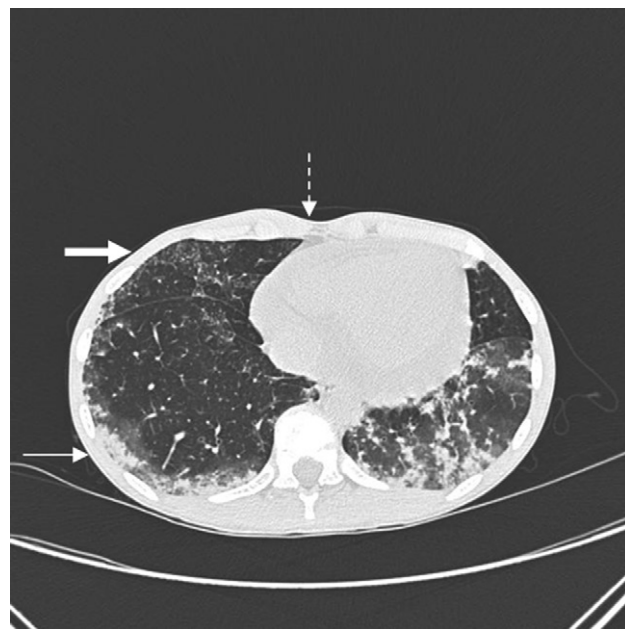


Fig. 2. Chest computed tomography (before treatment with prednisone) revealing bilateral pulmonary infiltrates with lower lobe predominance (small arrow), peripheral consolidations (thick arrow) and some pericardial effusion (interrupted arrow).

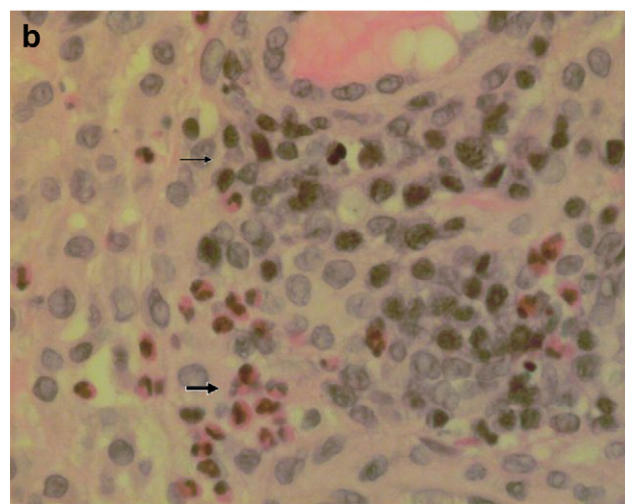
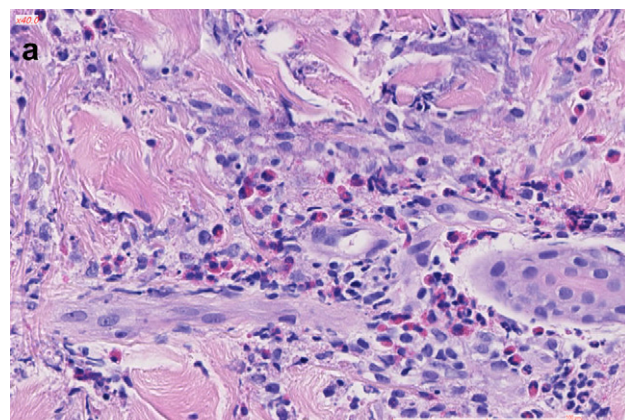


Fig. 3. (a): Biopsy of the skin lesion, showing dermal eosinophilic infiltrate. (b): Biopsy of subcutaneous nodule, showing multinodular basophilic necrosis (small arrow) with eosinophilic inflammation (thick arrow).

within one week. Chest CT was repeated after six days and revealed substantial improvement. This indicated a rapid steroid responsiveness. Extensive cultures and serologic tests showed no evidence of infectious diseases, including negative specific IgE to *Aspergillus*.

After 9 days of hospitalization, the child was discharged to home. He was treated with oral prednisone (2 mg/kg/day) maintenance therapy for 10 weeks, and thereafter, the dose was slowly reduced to 0.3 mg/kg every other day for 26 weeks after diagnosis. Twenty-eight weeks after diagnosis, the child presented with progressive coughing and blood eosinophilia ( $2.75 \times 10^9/L$ ). He was hospitalized and needed extra oxygen. Symptoms improved rapidly after increasing prednisone to 1 mg/kg/day and blood eosinophilia disappeared within one week. Until present, he remained steroid dependent despite interventions with additional consecutive immunosuppressive therapy: azathioprine at 50 mg/m<sup>2</sup>/day for 4 months (discontinued due to increased transaminases); mycophenolate-mofetil at 1200 mg/m<sup>2</sup>/day for 2 months; methylprednisolone 600 mg pulses intravenously during 3 consecutive days, monthly for 3 months; cyclophosphamide (600 mg/m<sup>2</sup>, monthly for 8 months).<sup>5</sup> Currently, 24 months after diagnosis, he is treated with methotrexate (25 mg subcutaneously, once a week), beclomethasone (1 mg/twice a day nebulized), long-acting bronchodilators, and the use of prednisolone is being tapered.

### 3. Discussion

We present a boy with asthma, prominent eosinophilia and pulmonary infiltrates. Because of the cutaneous involvement and a history of asthma, Churg–Strauss syndrome was considered.

The combination of allergic granulomatosis, allergic angiitis and periarteritis nodosa was described by Churg and Strauss in 1951 as a clinical syndrome consisting of severe asthma, fever, and hyper-eosinophilia, in association with symptoms of vascular involvement in various organ systems.<sup>1</sup>

The exact pathogenesis of CSS is unknown. At least three potential mechanisms have been implicated: 1) asthma, involving Th2 lymphocytes; 2) the contribution of ANCA in the development of vasculitis; and 3) the role of eosinophils.<sup>6</sup> Several asthma medications have been associated with the appearance of CSS. It has been suggested that improved asthma control by adding leukotriene modifying agents and/or inhaled glucocorticoids allows tapering of the systemic steroid dose, but consequently unmasking an underlying systemic inflammatory process.<sup>7</sup>

In CSS, three sequential phases are described: 1) the prodromal phase characterized by allergic rhinitis and asthma; 2) the eosinophilic phase with eosinophilic infiltration in multiple organs especially in the respiratory and gastrointestinal tract; and 3) the vasculitic phase in which a systemic vasculitis of the small and medium vessels develops, often with malaise, weight loss, and fever.<sup>8</sup>

The American College of Rheumatology (ACR) proposed 6 criteria for the Churg–Strauss syndrome: asthma, peripheral blood eosinophilia (more than 10% on differential white blood cell count), mononeuropathy or polyneuropathy, non-fixed pulmonary infiltrates, paranasal sinus abnormalities, and extravascular eosinophilia.<sup>9</sup> The presence of 4 or more of these criteria yielded a sensitivity of 85% and a specificity of 99.7%.<sup>9</sup> Histologically, there is a typical triad of necrotizing vasculitis, granulomas, and extravascular eosinophilia.<sup>2</sup> Our patient met 4 of the 6 criteria for CSS and had 2 histological signs of CSS (vasculitis, eosinophilia). ANCA in our patient was negative.

CSS is rare in childhood and the clinical presentation can be quite diverse. In 2008, Zwerina et al reported 33 cases of CSS in children. To our knowledge, sixteen other cases have subsequently been reported.<sup>6,10–24</sup> In total, 50 cases of childhood CSS are

summarized: the mean age at presentation was 10 years (range 2–18 yr) and childhood CSS occurred more frequently in girls than in boys (22 boys, 28 girls, male-to-female ratio 0.79). The most frequent clinical characteristics were: pulmonary involvement (90%, i.e. pulmonary infiltrates, wheezing, pleural effusions and alveolar hemorrhage), asthma (88%), sinusitis (76%), and skin involvement (73%, i.e. rash, purpura, nodules and ulceration). Cardiac involvement was seen in 22 of 44 patients (50%), most often pericardial effusions and cardiomyopathy, but also myocarditis, valve regurgitation and cardiac thrombosis. Neurological involvement was seen in 21 of 42 patients (50%), i.e. mononeuritis multiplex, polyneuropathy, hemichorea, bilateral optic neuropathy and loss of vision. In declining order of frequency, gastrointestinal (45%, i.e. abdominal pain, diarrhea, ulceration, abdominal mass and hepatic venous outflow obstruction) and musculoskeletal (45%, i.e. myalgia and arthralgia) symptoms were reported. Renal involvement was seen less frequent (21%, i.e. proteinuria, hematuria, glomerulonephritis and IgA-nephropathy). Results of ANCA testing were reported in 26 patients, of whom 6 were positive (23%). Miscellaneous symptoms are: lymphadenopathy, testicular pain, thymic mass, orbital pseudotumor, deep venous thrombosis and Raynaud phenomenon.

Initially, all patients received corticosteroids, usually prednisone 1–2 mg/kg/d. Corticosteroids and additional immunosuppressive therapy were initially given in 10 out of 47 patients (21%). Disease relapse was reported in 23 out of 46 patients (50%) within a half to 26 months. At relapse, 8 patients received corticosteroids monotherapy (35%) and 15 patients received additional immunosuppressive therapy (65%), usually cyclophosphamide, and in one case mycophenolate-mofetil. The mortality of CSS is substantial, 10 out of 47 patients (21%) died after a disease duration of 2–26 months. Two patients died within short time when therapy was refused or stopped. Reported causes of death are: respiratory insufficiency ( $n = 1$ ), pulmonary abscess and sepsis ( $n = 1$ ), cardiac failure ( $n = 3$ ), cardiac arrest and severe myocarditis ( $n = 1$ ), intestinal perforation ( $n = 2$ ), intestinal perforation and septicaemia ( $n = 1$ ), and gastrointestinal inflammation with necrosis and sepsis ( $n = 1$ ).

Zwerina et al compared CSS in childhood with CSS in adults.<sup>2</sup> Asthma is frequent in all patients.<sup>2</sup> Other organ involvement is different among children and adults.<sup>2</sup> Pulmonary infiltrates and cardiac disease are seen more frequently in children.<sup>2</sup> Peripheral nerve and musculoskeletal symptoms are seen more frequently in adults.<sup>2</sup> ANCA are found in about 1/3 of adult and in 1/4 of childhood patients with CSS, respectively.<sup>2</sup> The outcome in childhood seems to be worse.<sup>2</sup> Reasons for these differences remains elusive.<sup>2</sup>

In conclusion, we present a 12-year-old boy with an ANCA-negative Churg–Strauss syndrome. The clinical presentation of childhood CSS can be diverse, with involvement of different organ systems. The respiratory tract is most frequently involved, with pulmonary infiltrates, asthma symptoms and sinusitis. Early recognition of childhood CSS is important as delayed diagnosis can lead to severe organ involvement and a fatal outcome.

### Consent

Written informed consent was obtained from the patient and his parents for publication of this case report and images. A copy of the written consent is available for review by the Editor-in-Chief of this journal.

### Funding

The authors did not receive any funding.

## Authors' contributions

FR, JH, GJV, LD, JJ, JB and PR were involved in diagnostics and treatment of the patient. FR and PR drafted the manuscript. All authors contributed to writing and editing the manuscript. All authors read and approved the final manuscript.

## Competing interests

The authors have no conflict of interest.

## Acknowledgements

We wish to thank our patient and his parents for their approval and collaboration.

## Educational aims

- Churg–Strauss syndrome is a multisystem disorder of unknown etiology characterized by asthma, eosinophilia and vasculitis.
- In childhood, Churg–Strauss syndrome is rare and the clinical presentation diverse.
- In children with Churg–Strauss syndrome, the respiratory tract is most frequently involved with pulmonary infiltrates, asthma and sinusitis.
- Early recognition of childhood Churg–Strauss syndrome is important as delayed diagnosis can lead to severe organ involvement and fatal outcome.

## Educational questions

1. Churg–Strauss syndrome is an antineutrophil cytoplasmic antibody (ANCA)-associated vasculitis. ANCA in children are found in the majority of the cases.  
Answer: False. Although Churg–Strauss syndrome is an ANCA-associated vasculitis, ANCA are only found in 40% of the cases.
2. The American College of Rheumatology developed six criteria for Churg–Strauss syndrome: asthma, peripheral blood eosinophilia, mononeuropathy or polyneuropathy, non-fixed pulmonary infiltrates, and extravascular eosinophils. The sixth criterium is paranasal sinus abnormalities.  
Answer: True. The presence of four or more of these six criteria yielded a sensitivity of 85% and a specificity of 99.7%.
3. Typical histology in Churg–Strauss syndrome is characterized by non-necrotizing vasculitis and extravascular eosinophilia.  
Answer: False. Typically a triad is found of necrotizing vasculitis, granulomas and extravascular eosinophilia.
4. Churg–Strauss syndrome is a multisystem disorder. In children, neurological and gastrointestinal symptoms are the most frequent extra-pulmonary manifestations.  
Answer: False. In declining order of frequency, extra-pulmonary manifestations in children are: skin involvement (73%), cardiac involvement (50%), neurological (50%), gastrointestinal (45%), musculoskeletal (45%) and renal involvement (21%).
5. In general, the treatment of Churg–Strauss syndrome is primarily based on corticosteroids and sometimes combined with additional immunosuppressive therapy. During childhood, disease relapse is rare.

Answer: False. Disease relapse was reported in 50% of the children, and occurred within 0.5–26 months of time.

6. The mortality of childhood Churg–Strauss syndrome is less than 5%.

Answer: False. The mortality of Churg–Strauss syndrome is substantial: 21% of the children (10 out of 47) died after a disease duration of 2–26 months.

## References

1. Churg J, Strauss L. Allergic granulomatosis, allergic angiitis, and periarteritis nodosa. *The American Journal of Pathology* 1951;**27**(2):277–301.
2. Zwerina J, Eger G, Englbrecht M, Manger B, Schett G. Churg–Strauss syndrome in childhood: a systematic literature review and clinical comparison with adult patients. *Seminars in Arthritis and Rheumatism* 2009;**39**(2):108–15.
3. Sinico RA, Di Toma L, Maggiore U, Tosoni C, Bottero P, Sabadini E, et al. Prevalence and clinical significance of antineutrophil cytoplasmic antibodies in Churg–Strauss syndrome. *Arthritis and Rheumatism* 2005;**52**(9):2926–35.
4. Sable-Fourtassou R, Cohen P, Mahr A, Pagnoux C, Mouthon L, Jayne D, et al. Antineutrophil cytoplasmic antibodies and the Churg–Strauss syndrome. *Annals of Internal Medicine* 2005;**143**(9):632–8.
5. Cohen P, Pagnoux C, Mahr A, Arène JP, Mouthon L, Le Guern V, et al. Churg–Strauss syndrome with poor-prognosis factors: a prospective multicenter trial comparing glucocorticoids and six or twelve cyclophosphamide pulses in forty-eight patients. *Arthritis and Rheumatism* 2007;**57**(4):686–93.
6. Yim HE, Yoo KH, Won NH, Hong YS, Lee JW. Churg–Strauss syndrome in a child with IgA nephropathy. *Clinical Nephrology* 2009;**71**(3):306–9.
7. Boyer D, Vargas SO, Slattery D, Rivera-Sanchez YM, Colin AA. Churg–Strauss syndrome in children: a clinical and pathologic review. *Pediatrics* 2006;**118**(3):e914–20.
8. Vries de, Drent, Tervaert. Vasculitis induced by drugs. In: Camus Rosenow, editor. *Drug-induced and iatrogenic respiratory disease*. London: Hodder Education; 2010. p. 308–17.
9. Masi AT, Hunder GG, Lie JT, Michel BA, Bloch DA, Arend WP, et al. The American College of Rheumatology 1990 criteria for the classification of Churg–Strauss syndrome (allergic granulomatosis and angiitis). *Arthritis and Rheumatism* 1990;**33**(8):1094–100.
10. Basak RB, Narchi H, Bakir M, Joshi S, Conca W. Churg–Strauss syndrome without respiratory symptoms in a child. *Indian* 2011;**56**(1):84–6.
11. Ghaffar TY, Elfaramawy AA, El Saied S, El Adawy M, Sakr MA, Zalata K. Hepatic venous outflow obstruction complicating Churg–Strauss syndrome in a 5-year-old child. *Journal of Pediatric Gastroenterology Nutrition* 2011;**52**(2):217–8.
12. Demircin G, Baysun S, Bulbul M, Erdogan O, Oner A. Mycophenolate mofetil therapy in a child with Churg–Strauss syndrome. *Pediatrics* 2010;**52**(3):e164–6.
13. Partal A, Moshfeghi DM, Alcorn D. Churg–Strauss syndrome in a child: retina and optic nerve findings. *British Journal of Ophthalmology* 2004;**88**(7):971–2.
14. Rabusin M, Lepore L, Costantinides F, Bussani R. A child with severe asthma. *Lancet* 1998;**351**(9095):32.
15. Waseem M, Laureta E. An asthmatic adolescent with a rash and eosinophilia. *Pediatric Emergency Care* 2007;**23**(10):727–30.
16. Hamdan MA, Al-Rumaithi S, Tolaymat N, Ionescu G, Al-Ashari M, El-Teraifi H. Churg–Strauss syndrome presenting as an abdominal mass in a non-asthmatic child. *Annals of Tropical Paediatrics* 2007;**27**(4):311–4.
17. Martinez-Bone Montero E, Picchi Rodriguez F, Mier Palacios M, Lopez Diaz R. Early-onset of Churg–Strauss syndrome. *Anales de Pediatría Barcelona* 2008;**69**(2):192–3.
18. Lu S, Zhou WY, Zhou W, Li ZP, Chang YM, Wei L, et al. Churg–Strauss syndrome in children: a case evolving in endomyocardiopathy. *Zhongguo Dang Dai Er Ke Za Zhi* 2008;**10**(5):625–8.
19. Al-Amman AY, Yasin SS, Al-Muhsen SZ, Al-Saadi MM, Al-Sohaibani MO. A laryngeal presentation of Churg–Strauss syndrome in childhood. *Annals of Saudi Medicine* 2009;**29**(2):142–5.
20. Mutsaers ER, Witteveen R, van den Bosch-Ruis W, Kuijpers TW, van Houten MA, van den Berg JM. A pseudoleukemic blood differentiation in a 13-year-old child: an extraordinary presentation of Churg–Strauss syndrome. *Clinical Rheumatology* 2009. <http://dx.doi.org/10.1007/s10067-009-1265-1> [Epub ahead of print].
21. Salerno T, Cutrera R, Schiavino A, Pedace C, Rossi FP, Cortis E, et al. Churg–Strauss syndrome in a 14-year-old girl. *Pediatric Pulmonology* 2010;**45**(5):518–20.
22. Twardowsky AO, Paz JA, Pastorino AC, Jacob CM, Marques-Dias MJ, Silva CA. Chorea in a child with Churg–Strauss syndrome. *Acta Reumatologica Port* 2010;**35**(1):72–5.
23. Sharma MC, Safaya R, Sidhu BS. Perforation of small intestine caused by Churg–Strauss syndrome. *Journal of Clinical Gastroenterology* 1996;**23**(3):232–5.
24. Kawakami T, Soma Y. Churg–Strauss Syndrome in childhood: a clinical review. *The Journal of Rheumatology* 2009;**36**(11):2622–3.