

# Severe Craniofacial Morbidity from a Bean Bag Projectile

Santiago R. Gonzalez, MD, MPH\*

Vishalli Loomba, MPH†

Osita Obi-Osuagwu, MD\*

Abdl-Rawf Al-Nowaylati, MD\*

Paymon Rahgozar, MD\*

**Summary:** Bean bag munitions, less-lethal weapons primarily used by law enforcement, can cause severe morbidity. Although bean bag munitions are less likely to cause severe injury when compared with regular gunshot rounds, it is crucial to understand that bean bag munitions may be life-threatening. In this case, we describe our experience with a patient who suffered a zygomaticomaxillary complex fracture, facial nerve injury, and retained munition round in his maxillary sinus from a bean bag projectile shot during an altercation with the police. The patient was urgently transferred to the operating room for extraction of the bean bag munition, and although fracture repair was successful, the patient sustained significant damage to facial nerves, leading to lagophthalmos. To our knowledge, this is the first case report describing a penetrating injury from a bean bag munition that was retained within a facial structure. We will discuss the surgical intervention used for this patient and the review of the current literature on these less-lethal munitions. (*Plast Reconstr Surg Glob Open* 2021;9:e3589; doi: [10.1097/GOX.0000000000003589](https://doi.org/10.1097/GOX.0000000000003589); Published online 21 May 2021.)

## INTRODUCTION

Bean bag munitions are thought to be safer alternatives for crowd control because they deliver less force than standard munition rounds. The basic composition of a bean bag is a synthetic bag filled with lead pellets that is fired from a shotgun.<sup>1</sup> Although bean bag munitions are less likely to cause severe injury when compared with standard ones, it is crucial to become aware that bean bag munitions may be life-threatening.<sup>2</sup> The current literature has reported severe injuries such as thoracic damage,<sup>3</sup> epidural hematomas,<sup>4</sup> and penetrating ocular traumas.<sup>5</sup> In this article, we describe our experience with a patient who suffered a zygomaticomaxillary complex fracture, facial nerve injury, and retained munition round in maxillary sinus from a bean bag projectile.

## CASE DESCRIPTION

A 35-year-old man with no significant prior medical history presented to the emergency department (ED)

after being shot in the face with a bean bag munition during an altercation with law enforcement (Fig. 1). Upon arrival to the ED, the patient's Glasgow Coma Scale was 13. He was too agitated to undergo a formal motor and sensory examination of his facial structures, to cooperate with his care, and soon became a risk for himself and others. As a result, he was given antipsychotics, ketamine, and was eventually intubated to manage his uninhibited agitation. He was then evaluated in the emergency room with computed tomography (CT) of the brain, face, and cervical spine (Fig. 2). These revealed a left zygomaticomaxillary complex fracture with a retained foreign body in the left maxillary sinus, a frontal calvarium and sphenoid fractures, proptosis of left globe with displaced osseous fragment contacting the left lateral rectus muscles, and a small frontal intracerebral hemorrhage. On ophthalmological examination, he was found to have elevated left globe intraocular pressure (IOP) measuring 47 and 54 on a repeat read, and had no evidence of pupil peaking, vitreous hemorrhage, retrobulbar hemorrhage, or retinal detachment. Due to the elevated IOP, a lateral canthotomy was performed by the Ophthalmology team. Following the canthotomy, the IOP was decreased to 17. The frontal intracerebral hemorrhage was stable at a 6-hour repeat head CT, and as a result, no further management or surgical interventions were recommended by the Neurosurgery team. He was then transferred to the surgical intensive care unit for ventilation management and pain control.

Eight hours after his initial presentation to the ED, he was taken to the operating room for surgical removal

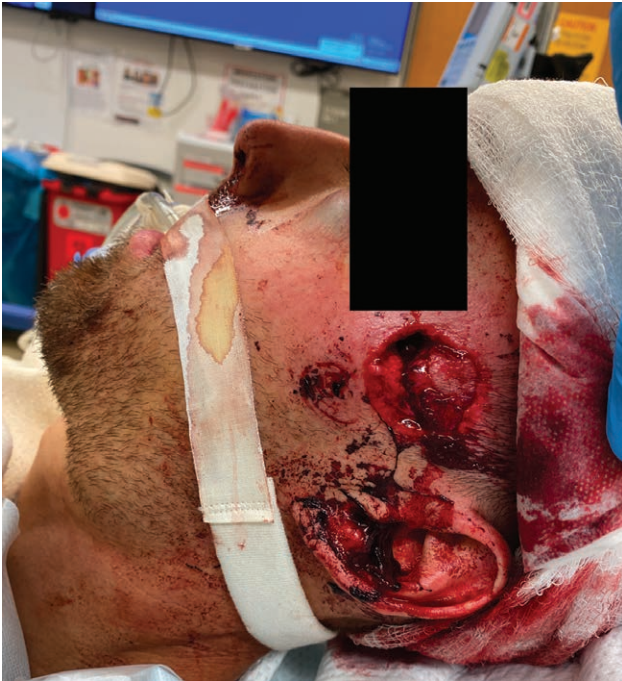From the \*Division of Plastic and Reconstructive Surgery, Department of Surgery, University of California San Francisco, San Francisco, Calif.; †College of Medicine, University of California San Francisco, San Francisco, Calif.

Received for publication December 8, 2020; accepted March 18, 2021.

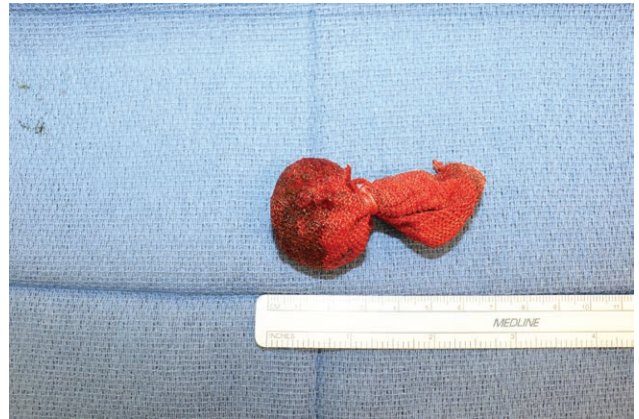Copyright © 2021 The Authors. Published by Wolters Kluwer Health, Inc. on behalf of The American Society of Plastic Surgeons. This is an open-access article distributed under the terms of the [Creative Commons Attribution-Non Commercial-No Derivatives License 4.0 \(CCBY-NC-ND\)](https://creativecommons.org/licenses/by-nc-nd/4.0/), where it is permissible to download and share the work provided it is properly cited. The work cannot be changed in any way or used commercially without permission from the journal.

DOI: [10.1097/GOX.0000000000003589](https://doi.org/10.1097/GOX.0000000000003589)

**Disclosure:** All the authors have no financial interest in relation to the contents of this article.

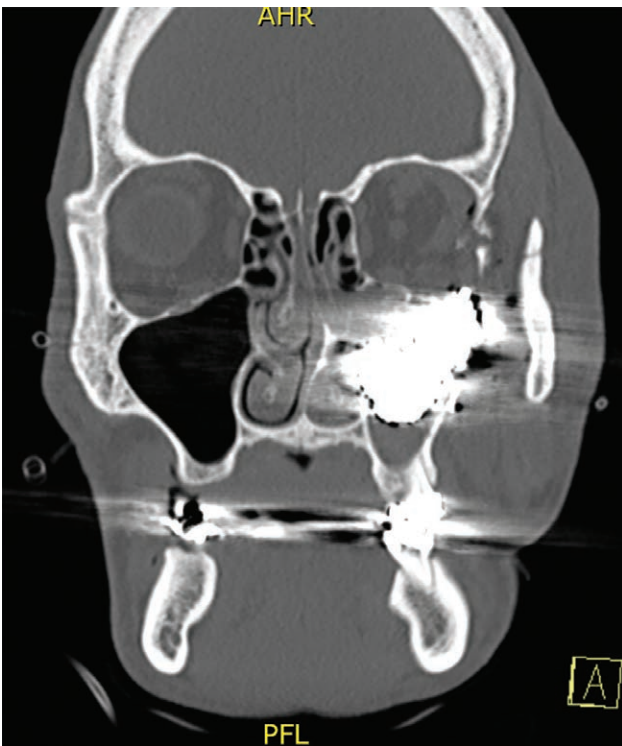


**Fig. 1.** External appearance of the patient's injury upon initial presentation. On digital examination of the wound, a depth of approximately 4 cm was palpated.

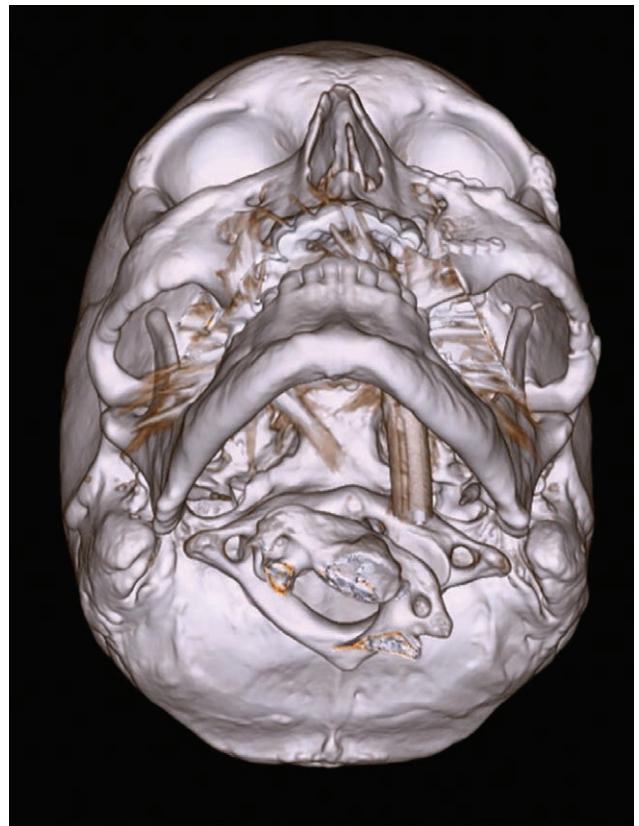


**Fig. 3.** Bean bag munition extracted from the patient's left maxillary sinus.

of the foreign object retained in his maxillary sinus, and for open reduction and internal fixation of his zygomaticomaxillary complex fracture. The first step in the operation was to retrieve the foreign body through the open wound created by the initial impact from the munition on the left side of his face. The bean bag munition that was removed from his left maxillary sinus can be seen in [Figure 3](#). Upon removal of the bean bag, the fracture sites were exposed through the infraorbital mid lid, eyebrow, and intraoral vestibular approaches. A 3-point



**Fig. 2.** Coronal view of the patient's CT scan, which showcases the facial fractures upon initial presentation. A foreign body is visible in the left maxillary sinus, and a zygomaticomaxillary complex fracture is noted.



**Fig. 4.** 3D CT reconstruction of the patient's facial bones following the removal of the bean bag, and open reduction internal fixation of the zygomaticomaxillary complex fractures.

fixation was performed at the zygomaticofrontal junction, infraorbital rim, and zygomaticomaxillary buttress (Fig. 4). Although attempts were made, no responsive branches of the facial nerve were found in the region. The procedure was completed successfully, and the patient was discharged without complications 4 days after presentation.

## DISCUSSION

Bean bag munitions are considered to be less-harmful munitions, and are used by law enforcement agencies for crowd control in all 50 states.<sup>1</sup> Moreover, the use of these projectiles has also been documented in Europe, Southeast Asia, and Northeast Asia.<sup>6</sup> Despite widespread use of bean bag munitions, there is a lack of literature describing the potential impact of these “less-lethal” munitions. A 2004 report by the National Institute of Justice describing 373 injuries caused by less-lethal munitions documented in police reports is the most inclusive report to date.<sup>7</sup> Bean bag munitions were a staggering 65% of these injuries, and the number of injuries has likely increased significantly in recent years given law enforcement’s preference for these weapons for crowd control and civil unrest.

Although these munitions are designed to inflict superficial painful injuries, a wide range of serious penetrating injuries have been reported.<sup>1–3,5</sup> The standard model is a 5 × 5 bean bag filled with lead pellets, shot from a 12-gauge-shot-gun with a velocity of approximately 90 m/s.<sup>8</sup> Though law enforcement agencies train officers to shoot from 30-feet away, there is more accuracy and greater resulting injuries from shorter distances.<sup>7</sup> Additionally, due to bean bag munitions’ lower velocity compared with traditional gun shot rounds, they can be a significant source of infection and immediate surgical removal is often warranted.<sup>9,10</sup>

Of the cases reported in the literature, there are few reports of facial and ocular trauma from a bean bag injury.<sup>5</sup> To our knowledge, this is the first case report describing a penetrating foreign body that was retained within a sinus. In this case, the patient suffered a penetrating shot through the left maxillary sinus, leading to a comminuted zygomaticomaxillary complex fracture and facial nerve damage. Although the urgent surgical removal of the bean bag and fixation of facial fractures was successful, the injury to his facial nerve now requires the placement of an upper eyelid weighted implant for the treatment of the significant lagophthalmos he developed.

## CONCLUSIONS

Although bean bag munitions are described as “non-lethal” and have reduced morbidity and mortality compared with traditional gun shot rounds, there have been a number of reports of serious injury and death caused by these weapons. In this study, we described the serious maxillofacial injuries that can be caused by bean bag munitions, and the crucial role that plastic surgeons may play in the management of complex facial fractures in such cases. Additional studies are needed to further evaluate the safety of bean bag munitions used as means for crowd control.

**Santiago R. Gonzalez, MD**

505 Parnassus Ave #M593

San Francisco, CA 94143

E-mail: [santiago.gonzalez2@ucsf.edu](mailto:santiago.gonzalez2@ucsf.edu)

## PATIENT CONSENT

*The patient provided written consent for the use of his image.*

## REFERENCES

1. de Brito D, Challoner KR, Sehgal A, et al. The injury pattern of a new law enforcement weapon: the police bean bag. *Ann Emerg Med.* 2001;38:383–390.
2. Olson KA, Haselden LE, Zaunbrecher RD, et al. Penetrating injuries from “less lethal” beanbag munitions. *N Engl J Med.* 2020;383:1081–1083.
3. Guenther TM, Gustafson JD, Wozniak CJ, et al. Penetrating thoracic injury from a bean bag round complicated by development of post-operative empyema. *J Surg Case Rep.* 2020;2020:rjaa078.
4. Drazin D, Shirzadi A, Hanna G, et al. Epidural hematoma and surgical evacuation from a bean bag weapon. *Am Surg.* 2012;78:E33–E35.
5. Wehrmann D, Antisdell J, Walen S, et al. Penetrating ocular trauma from a bean bag gun: a case report and review of less-lethal force and their consequences. *Mo Med.* 2017;114:308–310.
6. Haar RJ, Iacopino V, Ranadive N, et al. Death, injury and disability from kinetic impact projectiles in crowd-control settings: a systematic review. *BMJ Open.* 2017;7:e018154.
7. Hubbs K, Klinger D. Impact munitions data base of use and effects. Technical Report 204433, U.S. Department of Justice, 2004.
8. Marrufo AS, Boyd WD, Leshikar DE. Minimally invasive surgical management of penetrating chest injury from kinetic impact bean bag projectile. *Trauma Case Rep.* 2019;22:100210.
9. Charles A, Asensio J, Forno W, et al. Penetrating bean bag injury: intrathoracic complication of a nonlethal weapon. *J Trauma.* 2002;53:997–1000.
10. Thakur S, Teloken PE, Gilfillan I, et al. Non-lethal? Penetrating chest injury due to beanbag bullet. *BMJ Case Rep.* 2013;2013:bcr2012008482.