

# Hybrid repair for a complex infection aortic pseudoaneurysm with continued antibiotic therapy

## A case report and literature review

Xiyang Chen, MD, Ding Yuan, MD, PhD, Jichun Zhao, MD, PhD\*, Bin Huang, MD, Yi Yang, MD, PhD

### Abstract

**Introduction:** Treatment of infection aortic pseudoaneurysm (PSA) is a great challenge to surgeons for 3 reasons: high mortality for rupture or threatened rupture; potential risk for infection of prosthetic material which probably bring a devastating result for patients; and long-term antibiotic therapy requirement. Endovascular repair is an alternative to open surgery for a less invasive, which is a trouble procedure for aortic PSA with complex aortic anatomy. The purpose of this article is to report the novel hybrid repair of an infection aortic PSA and antibiotics therapy.

**Clinical finding:** A 61-year-old man with complaints of repeated abdominal pain and fever for 3 months was admitted. He had a fever of 39.0°C and normal blood pressure. The blood leukocyte count was  $14.9 \times 10^9/L$ , C-reactive protein was 132 mg/L. There was no evidence for urinary tract infection. The small effusion was identified in bilateral thoracic cavity and pelvis cavity, and the severe lung function impairment was detected. *Klebsiella pneumoniae* was identified in blood cultures. Computer tomographic (CT) angiography showed a 6 cm × 6 cm aortic PSA involving bilateral renal arteries and a subhepatic inflammatory mass (identified by percutaneous puncture).

**Diagnosis:** According to the symptoms, CT and lab test, the main diagnosis for this patient were: infective aortic PSA involving bilateral renal arteries, and Bacteremia with *K pneumoniae*.

**Intervention and outcomes:** A hybrid procedure combined open surgical and endovascular was performed for managing the paravisceral infection aortic PSA in a 61-year-old man with high risk. To decrease the risk of graft infection, autologous saphenous vein graft was adopted, and long-term antibiotic therapy was used. At 2 years follow-up, the patient was in good clinical condition with continued antibiotic therapy.

**Conclusion:** Hybrid procedure is an alternative approach according to high risk patients with complex anatomy for open repair of infection aortic PSA. The postoperative long-time continued antibiotic therapy must be emphasized for infection PSA.

**Abbreviations:** CRP = C-reactive protein, CTA = computer tomographic angiography, DIA = diameters, PSA = pseudoaneurysm, PTFE = polytetrafluoroethylene, SMA = superior mesenteric artery.

**Keywords:** antibiotics therapy, endovascular, hybrid, infection aortic pseudoaneurysm, reconstruction

Editor: N/A.

XYC and DY contributed equally to this work and should be considered for co-first authors.

Informed written consent was obtained from the patient for publication of this case report and accompanying images.

The authors have no funding and conflicts of interest to disclose.

Department of Vascular Surgery, West China Hospital of Sichuan University, Chengdu, Sichuan, China.

\* Correspondence: Jichun Zhao, Department of Vascular Surgery, West China Hospital of Sichuan University, Chengdu, Sichuan, China, No 37, Guoxuexiang, 610041 Chengdu, China (e-mail: zhaojc3@163.com).

Copyright © 2019 the Author(s). Published by Wolters Kluwer Health, Inc. This is an open access article distributed under the terms of the Creative Commons Attribution-Non Commercial License 4.0 (CCBY-NC), where it is permissible to download, share, remix, transform, and buildup the work provided it is properly cited. The work cannot be used commercially without permission from the journal.

Medicine (2019) 98:6(e14330)

Received: 5 October 2018 / Received in final form: 27 December 2018 /

Accepted: 8 January 2019

<http://dx.doi.org/10.1097/MD.0000000000014330>

## 1. Introduction

Infection aortic pseudoaneurysm (PSA) is a challenging and rare disease for surgeons, especially when the symptom is acute with a high risk of threatened rupture, fatal bleeding. Either the potential risk of rupture or graft infection will bring patients a devastating outcome. Standard surgical treatment consists of debridement with extra-anatomic bypass or in situ graft placement, followed by long-term antibiotic therapy.<sup>[1,2]</sup> In addition, endovascular repair is an alternative to open surgery for less invasive.<sup>[3,4]</sup> However, an endovascular procedure is a tough challenge for aortic PSA with involving visceral arteries. In these complex cases (PSA involving visceral arteries or patients with severe comorbidities), the combination of open surgical and endovascular techniques as a hybrid procedure may facilitate a good outcome. However, few with hybrid repair of infection aortic PSA have been reported. The present report described the successful treatment of a patient with symptomatic, infection aortic PSA using a hybrid procedure and continued antibiotic therapy.

## 2. Case report

A 61-year-old man was admitted with complaints of repeated abdominal pain and fever for 3 months. A mild tenderness and pulsating mass in the mid abdomen, no rebound abdominal tenderness was detected. Vital signs showed temperature: 39.0°C, blood pressure, and heart rate were normal.

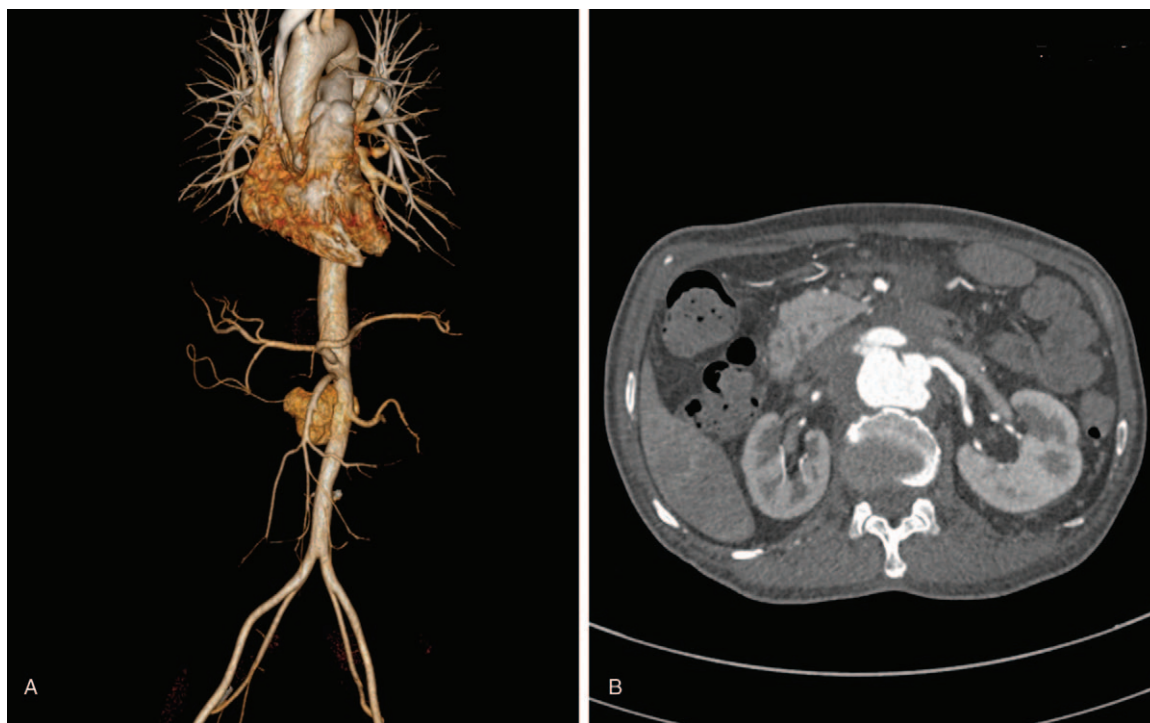
### 2.1. Clinical findings and diagnostic assessment

The aortic PSA was identified to measuring 6 cm × 6 cm on a computer tomographic (CT) scan. The aortic PSA extended from the inferior border level of the superior mesenteric artery (SMA) to the infrarenal aortic artery, involving the bilateral renal arteries and approaching SMA. The aorta diameters (DIA) of the level of celiac artery and SMA were 18 and 13 mm, respectively. The DIA of normal infrarenal aorta was 13 mm, and the DIA of bilateral common iliac arteries was 11 mm (Fig. 1).

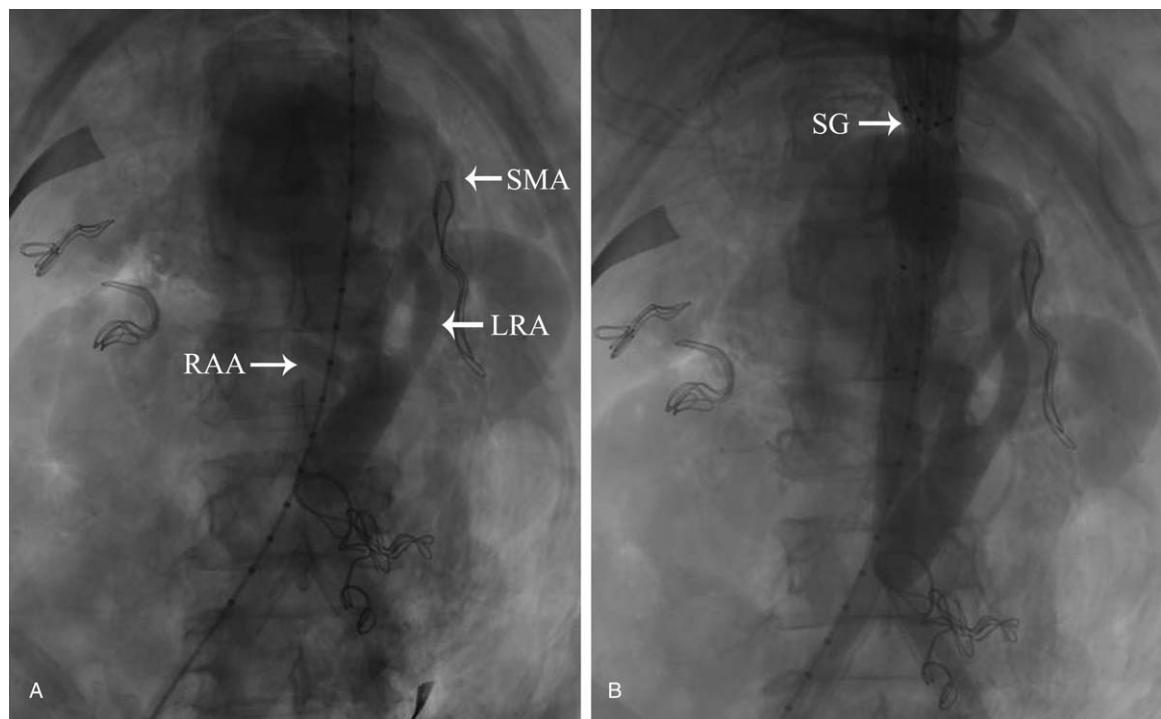
The blood leukocyte count was  $14.9 \times 10^9/L$ , C-reactive protein (CRP) was 132 mg/L. There was no evidence for urinary tract infection. The small effusion was identified in bilateral thoracic cavity and pelvis cavity, and the severe lung function impairment was diagnosed. *Klebsiella pneumoniae* was identified in blood cultures. The cardiac, liver, and renal functions were normal. The patient had a complicated medical history and a long history of smoking. The patient presented to another hospital with a 3-week history of abdominal pain. The subhepatic mass was diagnosed by CT scan, and a percutaneous ultrasound-guided puncture demonstrated an inflammatory lesion from the mass. According to the symptoms, CT, and lab test, the main diagnosis for this patient was: infective aortic PSA involving bilateral renal arteries and bacteremia with *K pneumoniae*.

### 2.2. Therapeutic assessment

Institutional review board approval was granted for this therapy procedure and report. Informed consent was obtained for the hybrid procedures. Hybrid approach was planned because of patient being potential high risk for standard open repair. The intravenous antibiotic therapy with Meropenem was keeping for 2 weeks and the negative results were determined by 3 times of blood cultures. Open surgical visceral revascularization was performed under general anesthesia without spinal drainage. The clear hydrops and the edematous retroperitoneal with lymphadenectasis were found in the abdominal cavity. The severe inflammatory adhesion was showed between the PSA wall and the retroperitoneal. The origins of the visceral and renal arteries were only exposed, and the PSA wall was not isolated. The DIA of infrarenal normal aorta was 13 mm and the maximum DIA of PSA was 6 cm, which involved right renal artery (DIA=4 mm) and left renal artery (DIA=4.5 mm) and approaching the SMA (DIA=4.5 mm). One 8 mm polytetrafluoroethylene (PTFE) graft was sewn side-to-end to the main body of a 16 × 8 mm Y-shaped bifurcated PTFE graft (GORE-TEX; WL Gore & Associates, Inc); thus the trichotomous graft was constructed. The main body side of the trichotomous graft was anastomosed side-to-end to the infrarenal aorta with CV3 suture to serve as the visceral inflow blood source. The 3 limbs of grafts were, respectively, anastomosed side-to-end to right renal artery, SMA, and left renal artery. To prevent subsequent type II endoleaks, the origins of each of the vessels were suture ligated after color Doppler identifying vessel graft patency. The blocked time of the vessels was: abdominal aorta (15 minutes), SMA (28 minutes), right renal artery (31 minutes), and left renal artery (25 minutes).



**Figure 1.** The preoperative computed tomography (CT) angiography of infection pseudoaneurysm (PSA). (A) CT angiography showed the aortic PSA involved superior mesenteric artery (SMA) and bilateral renal arteries and extruded the abdominal aortic artery. (B) The tear of PSA was the level between renal artery and SMA.



**Figure 2.** Endovascular procedure of hybrid treatment. (A) The angiography showed the good patency of blood vessel prostheses from visceral arteries before endovascular procedures (arrow). (B) The angiography following endovascular procedure showed that complete exclusion of the PSA and good patency of the bilateral right renal arteries and superior mesenteric artery (SMA). The sent graft (SG) was indicated by an arrow.

Endovascular procedure was performed. The right femoral arteries were exposed, and the angiography was from the access of right femoral artery. The patency of blood vessel prostheses and visceral arteries were demonstrated (Fig. 2A). The stent-grafts were placed from the right femoral artery. The proximal end of the 1st stent-graft (ENEW2020C80EE; Medtronic) was located at the celiac artery level. Subsequently, the Cuff stent-graft (ENCF2323C45EE, Medtronic) was located at the proximal end of the 1st stent-graft for enhancing the radial force of the 1st stent-graft. The angiography results showed complete exclusion of the PSA and good patency of visceral arteries (Fig. 2B). The total operative time was about 6 hours. Estimated blood loss was 1500 mL, and blood transfusion (600 mL of erythrocyte suspension and 600 mL of fresh plasma) was performed. The ICU duration was 5 days and no ischemia signs of spinal-cord were present in postoperative course. The computer tomographic angiography (CTA) on postoperative 9th day revealed a patent stent-graft without endoleaks, but the prostheses limb of the right renal artery was blocked (Fig. 3). The whole renal function was still normal. The patient had the uneventful postoperative course and was discharged on postoperative 12th day.

### 2.3. Follow-up and outcome

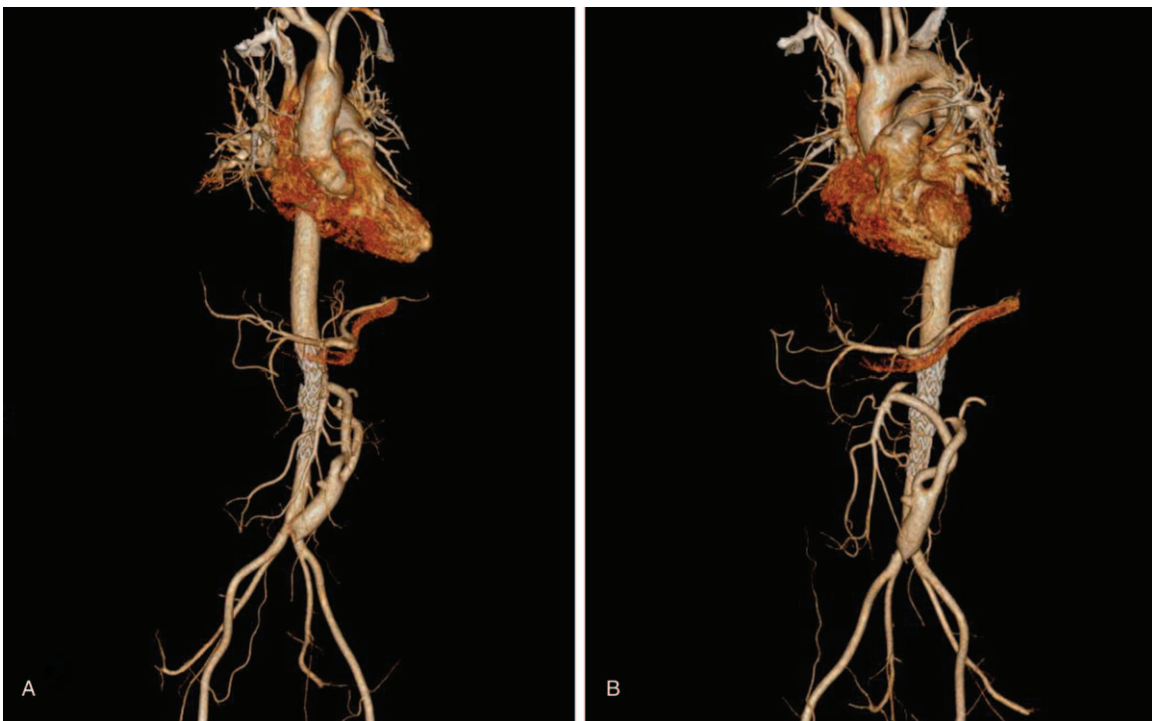
The patient was ordered for long-term antibiotic therapy. The patient was receiving oral administration of warfarin for long-term anticoagulation, maintaining INR between 2.0 and 2.5. Following 3 months, the patient was readmitted with complaints of fever because of the interrupted antibiotic treatment by himself, and *K pneumoniae* was again identified in this blood culture. The oral antibiotic therapy (Cefuroxime, 500mg, bid)

was further emphasized for the patient and was further continued for 3 months until clinical signs of the infection absent evident and the normal level of CRP and calcitonin. The patient was doing well without evidence of clinical problems related to the procedure in 1.5 years follow-up, which was normal renal function and body temperature. No obstruction of left renal artery and SMA and no endoleak was found using CTA after 2 years (Fig. 4).

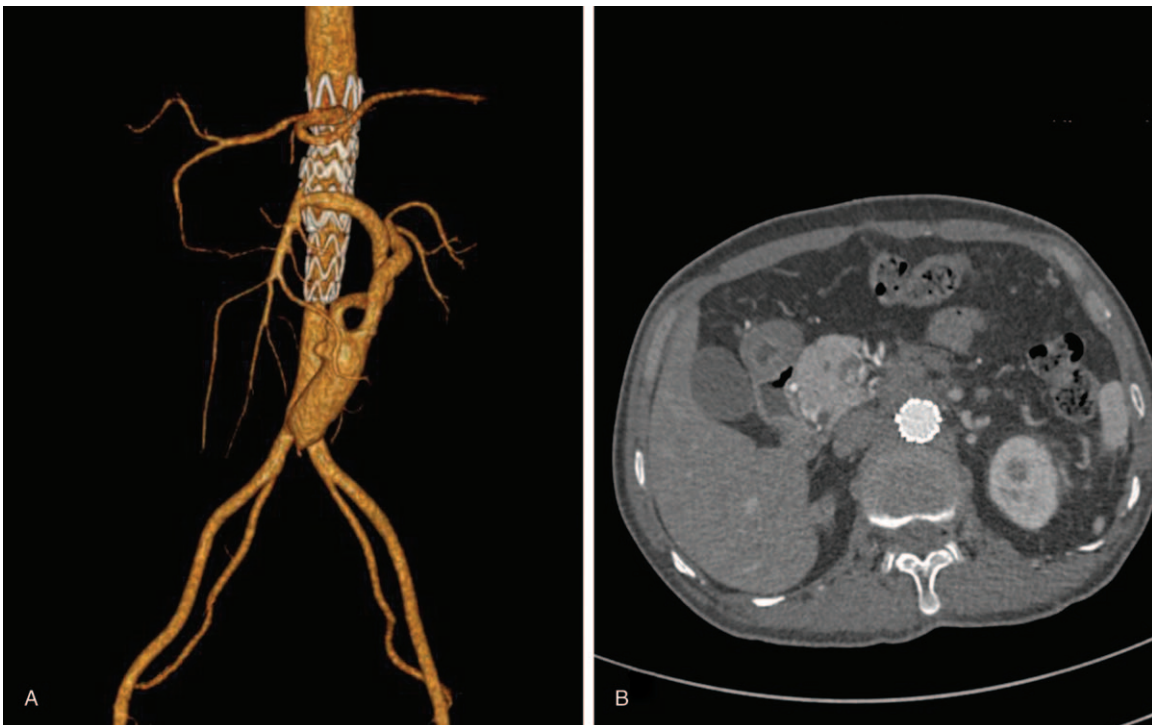
### 3. Discussion

In patients not suitable for conventional open surgery, an infection aortic PSA may be possible to be managed by endovascular treatment.<sup>[3,5,6]</sup> However, it could trouble endovascular procedure for complex aortic PSA involving visceral arteries. Based on our results, the hybrid procedure is a possible alternative to open surgery or endovascular repair. A hybrid technique to treat infected aortic PSA is limited reported, but long-term outcomes were disappointingly shown.<sup>[7]</sup>

Hybrid procedure plan for this case was identified based on the following patient-specific characteristic: the older patient and impaired pulmonary function unfit to large surgical burden; the infection aortic PSA involving the visceral arteries; the PSA infected from gram-negative bacteria. The endovascular treatment should be considered for this case from recent reports.<sup>[3,8]</sup> Patients without sufficient proximal neck, who underwent a tubular endovascular procedure, had the trouble operation schedule. A fenestrated or branched endografts should be the 1st endovascular consideration. However, the use of these endografts was not an option because they are custom made. In addition, a hybrid treatment experience for TAAAs was successfully performed in our center.<sup>[9]</sup>



**Figure 3.** The angiography on postoperative 9th day. The angiography following endovascular procedure showed that complete exclusion of the pseudoaneurysm, but the prostheses limb occlusion of the right renal artery.



**Figure 4.** The angiography on 2 years of follow-up. The computed tomography angiography showed complete exclusion of the pseudoaneurysm and good patency of the left renal artery and superior mesenteric artery and no endoleaks. No aggravation was further showed for the prostheses of the right renal artery.

The treatment literature information of paravisceral infection pseudoaneurysm.												
Authors	Year	Location	Case	Age	Gender	Clinical symptoms	Infection location	Infection agent	Procedure type	Follow-up, mo	Cause of death	Antibiotic duration, mo
Ting et al <sup>[10]</sup>	2005	Hong Kong	4	37–87	NA	NA	Visceral aorta	Major <i>Salmonella</i>	Open Surgery: Situ reconstruction, visceral artery revascularization	77–94	Pneumonia (1)*	Life-long
Sedivy et al <sup>[3]</sup>	2012	Czech	1	61	Female	Pain, fever	Descending thoracic	<i>Proteus</i>	Hybrid procedure: tubular SG + aorto-mesenteric	4	Meningioma, cavernous sinus thrombosis, hepatorenal failure, decubital sepsis	4
Reijnen and van Sterkenburg <sup>[6]</sup>	2014	The Netherlands	1	56	Male	Pain, fever	Visceral aorta	<i>Klebsiella pneumoniae</i>	Hybrid procedure: tubular SG + branched bypass to CT, SMA, and RA	11	Recurrent sepsis, abscess in both psoatic muscles	6
Kahn et al <sup>[5]</sup>	2015	USA	1	64	Female	Pain, fever, chill	Visceral aorta	<i>Salmonella</i>	Multilayer stent	18	None	3
						Pain	Visceral aorta	<i>Escherichia coli</i>	Multilayer stent	21	None	Life-long

NA = not available, RA = renal artery, SG = stent graft, SMA = superior mesenteric artery.

\* One patient died from pneumonia.

Most patients with an infected aortic PSA are usually hemodynamically unstable and in poor general condition, which increases the surgical risk associated with high morbidity and mortality. A less invasive endovascular approach using stent-grafts has been reported for the repair of infected aneurysms or pseudoaneurysms.<sup>[3,10–12]</sup> However, therapy procedures of infection PSA with complex aortic anatomy were still limited published. We searched the endovascular and hybrid treatment literature of infection PSA with involved visceral arteries using PubMed and the detail information of literatures are summarized in Table 1. A multilayer bare-metal stent for the treatment of an aortic infection PSA was recently reported for protecting visceral artery patency with multilayer bare-metal stents; in addition, the theoretic advantage is absence of graft fabric that could provide a platform for bacterial colonization.<sup>[5,6]</sup> Because the multilayer stent is not available in the China, we designed for surgical reconstruction for the visceral arteries.

Hybrid repair for infection aortic PSA combined surgical reconstructing visceral artery and endovascular aneurysm exclusion. The advantages included are as follows: avoiding situ or extra-anatomic bypass by a prosthesis with great burden; the bypass for visceral arteries improved the trouble from stent-grafts reconstruction. Two patients of infection aortic PSA were treated by hybrid repair, but regrettably died on postoperative 4 and 11 months<sup>[3]</sup> (Table 1). The positive outcome of this case indicated that the hybrid treatment of infected aortic PSA is a possible alternative to open surgery or endovascular repair.

The criteria concerning the length of antibiotic therapy following the PSA treatment were not clear (Table 1),<sup>[3,5,6,10]</sup> but the long-time continued antibiotic therapy should be executed for infection PSA in our center. The clinical signs of infection were absent, and once the antibiotic stopped by patient himself during follow-up, the recurrent infection was detected. The continued antibiotic therapy was further emphasized, and the course of treatment should be depended on the clinical signs, blood analysis of the infection evident, and the CT image around the stent-grafted segment.

#### 4. Conclusion

Despite the successful and life-saving treatment of our patient, longer term results were still needed to further characterize late efficacy of hybrid procedure. Nevertheless, at least hybrid procedure was an alternative approach according to high risk patients for open repair of infection aortic PSA with continued antibiotic therapy.

#### Author contributions

**Conceptualization:** Yi Yang.

**Data curation:** Ding Yuan.

**Formal analysis:** Yi Yang.

**Investigation:** Xiyang Chen, Bin Huang.

**Writing – original draft:** Xiyang Chen, Ding Yuan.

**Writing – review & editing:** Xiyang Chen, Ding Yuan, Jichun Zhao.

#### References

- [1] Vogt PR, Brunner-LaRocca HP, Lachat M, et al. Technical details with the use of cryopreserved arterial allografts for aortic infection: influence on early and midterm mortality. *J Vasc Surg* 2002;35:80–6.
- [2] Müller BT, Wegener OR, Grabitz K, et al. Mycotic aneurysms of the thoracic and abdominal aorta and iliac arteries: experience with

- anatomic and extra-anatomic repair in 33 cases. *J Vasc Surg* 2001;33:106–13.
- [3] Sedivy P, Spacek M, El SK, et al. Endovascular treatment of infected aortic aneurysms. *Eur J Vasc Endovasc Surg* 2012;44:385–94.
- [4] Sanada J, Matsui O, Arakawa F, et al. Endovascular stent-grafting for infected iliac artery pseudoaneurysms. *Cardiovasc Intervent Radiol* 2005;28:83–6.
- [5] Kahn SL, Peeran S, Smolinski S, et al. In vivo construction of a multilayer bare-metal stent for the treatment of an aortic mycotic pseudoaneurysm. *J Vasc Surg* 2015;62:744–6.
- [6] Reijnen MM, van Sterkenburg SM. Treatment of a *Salmonella*-induced rapidly expanding aortic pseudoaneurysm involving the visceral arteries using the Cardiatis multilayer stent. *J Vasc Surg* 2014;60:1056–8.
- [7] Han K, Lee DY, Kim MD, et al. Hybrid treatment: expanding the armamentarium for infected infrarenal abdominal aortic and iliac aneurysms. *J Vasc Interv Radiol* 2017;28:564–9.
- [8] Kan CD, Lee HL, Yang YJ. Outcome after endovascular stent graft treatment for mycotic aortic aneurysm: a systematic review. *J Vasc Surg* 2007;46:906–12.
- [9] Huang B, Yuan D, Zhao J, et al. Hybrid treatment of a thoracoabdominal aortic aneurysm in China: report of the first successful case. *Surg Today* 2012;42:1219–24.
- [10] Ting AC, Cheng SW, Ho P, et al. Surgical treatment of infected aneurysms and pseudoaneurysms of the thoracic and abdominal aorta. *Am J Surg* 2005;189:150–4.
- [11] Berchtold C, Eibl C, Seelig MH, et al. Endovascular treatment and complete regression of an infected abdominal aortic aneurysm. *J Endovasc Ther* 2002;9:543–8.
- [12] Bell RE, Taylor PR, Aukett M, et al. Successful endoluminal repair of an infected thoracic pseudoaneurysm caused by methicillin-resistant *Staphylococcus aureus*. *J Endovasc Ther* 2003;10:29–32.