

A comparison of voxel- and surface-based cone-beam computed tomography mandibular superimposition in adult orthodontic patients

Gaofeng Han^{1,#}, Jing Li^{1,#}, Shuo Wang¹,
Linchuan Wang², Yanheng Zhou¹ and
Yan Liu¹ 

Abstract

Objective: To evaluate the accuracy, reliability, and efficiency of voxel- and surface-based registrations for cone-beam computed tomography (CBCT) mandibular superimposition in adult orthodontic patients.

Methods: Pre- and post-orthodontic treatment CBCT scans of 27 adult patients were obtained. Voxel- and surface-based CBCT mandibular superimpositions were performed using the mandibular basal bone as a reference. The accuracy of the two methods was evaluated using the absolute mean distance measured. The time that was required to perform the measurements using these methods was also compared. Statistical differences were determined using paired *t*-tests, and inter-observer reliability was assessed by intraclass correlation coefficients (ICCs).

Results: The absolute mean distance on seven mandible surface areas between voxel- and surface-based registrations was similar but not significantly different. ICC values of the surface-based registration were 0.918 to 0.990, which were slightly lower than those of voxel-based registration that ranged from 0.984 to 0.996. The time required for voxel-based registration and surface-based registration was 44.6 ± 2.5 s and 252.3 ± 7.1 s, respectively.

¹Laboratory of Biomimetic Nanomaterials, Department of Orthodontics, Peking University School and Hospital of Stomatology, National Engineering Laboratory for Digital and Material Technology of Stomatology, Beijing Key Laboratory of Digital Stomatology, Beijing, China

²Department of General Dentistry, University of Rochester Eastman Institute for Oral Health Rochester, Rochester, NY, USA

[#]These authors contributed equally to this paper.

Corresponding author:

Yan Liu, Laboratory of Biomimetic Nanomaterials, Department of Orthodontics, Peking University School and Hospital of Stomatology, 22# Zhongguancun South Avenue, Haidian District, Beijing 100081, China.
Email: orthoyan@bjmu.edu.cn



Conclusions: Both methods are accurate and reliable and not significantly different from each other. However, voxel-based registration is more efficient than surface-based registration for CBCT mandibular superimposition.

Keywords

Cone-beam computed tomography (CBCT), mandibular superimposition, voxel registration, surface registration, adult orthodontic patients, anterior cranial base structures

Date received: 20 August 2020; accepted: 30 November 2020

Introduction

Cephalometric analysis is conventionally used to evaluate orthodontic tooth movement. However, problems associated with two-dimensional (2D) cephalometric radiographs such as errors in superimposition of craniofacial structures, bilateral structure magnification, and landmark identification, severely impair their use in orthodontic treatment.¹

Three-dimensional (3D) cone-beam computed tomography (CBCT) is now widely applied to construct a skeletal model for treatment planning and outcome evaluation based on serial image superimposition, which can avoid anatomic superimposition and differential magnification.² However, the superimposition technique that is used for 3D images is much more complex than that of 2D images. Currently, there is no gold standard or generally acknowledged method for CBCT superimposition. CBCT images can be superimposed using point-, surface-, and voxel-based registration.³ However, point-based registration depends on the precision of landmark identification, while surface-based registration is limited by segmentation error of the 3D surface models. Voxel-based registration, which is a recently developed technique, is different from the surface-based registration, and it uses volumetric units that are stored in

CBCT digital imaging and communications in medicine (DICOM) format. Moreover, voxel-based registration can automatically align two CBCT images by comparing the gray values in a defined volume of interest to calculate the rotation and translation without considering the chance of operator error,^{4,5} which is the main problem with point-based registration.

By comparing different methods of CBCT superimposition, Ghoneima et al.⁶ found that the surface- and voxel-based registration methods that use the anterior cranial base as a reference structure are accurate and reliable for detecting changes in landmark positions when superimposing, while the landmark-based superimposition method is reliable but less accurate. Almukhtar et al.⁷ demonstrated that no statistically significant differences are detected between the precision of the voxel- and surface-based registration methods, but the voxel-based registration is less variable by comparing the precision of the voxel- and surface-based CBCT superimposition with those of the anterior cranial base structures. The anterior cranial base has been traditionally considered to be a stable structure for serial cephalometric radiograph superimposition, which could also be regarded as a reliable reference for CBCT superimposition.³ However, the anterior cranial base is only visible in a large field

of view (FOV) CBCT scan. Ludlow et al.⁸ reported that the CBCT radiation dose decreases with a reduction in the scanning field, and the dose of a 13-cm FOV is 50% lower than that of a 22-cm FOV. CBCT superimposition on anterior cranial base structures can be used to detect the displacement of skeletal and dental positions that are related to the cranial base but that cannot be used to detect tooth movement in the maxilla or mandible.

Recently, a new and quick method for voxel-based CBCT registration on mandible structures was shown to be accurate and reliable.⁹ It is different from those processed on the anterior cranial base structure, and the mandibular regional superimposition method can be used to detect mandibular tooth movement with smaller FOV scans. However, no previous publications have compared the voxel- and surface-based registration methods for CBCT mandibular superimposition. The aim of this study was to evaluate the accuracy, reliability, and efficiency of the voxel- and surface-based registration methods for CBCT mandibular superimposition in adult orthodontic patients.

Methods

Subjects

This retrospective study was approved by the bioethics committee at the Peking University School and Hospital of Stomatology (No. PKUSSIRB-201839130). Adult patients, who had received a fixed appliance treatment at the Department of Orthodontics, Peking University School and Hospital of Stomatology from 2014 to 2018, were screened. The subjects were evaluated based on the following inclusion and exclusion criteria: (1) full permanent dentition (excluding third molars, extracted or not erupted); (2) no previous orthodontic treatment; (3) no periodontal disease or

morphologic tooth anomaly; (4) no dental restoration or crown; (5) no mandibular asymmetry; and (6) pre- and post-treatment CBCT scans were taken. The purpose of taking CBCT scans before and after the orthodontic treatment was to detect the risk factors for high-suspected dehiscence and fenestration in the anterior region of both the upper and lower jaws.¹⁰⁻¹² A pilot study and power analysis showed that a sample size of at least 24 patients is required for a 20% effect-size variation to indicate a statistically significant difference. The sample size was calculated with a power of 80% at a significance level of 0.05. Therefore, 27 adult participants were enrolled after providing written informed consent.

Data acquisition

CBCT volumes were acquired using a NewTom VG scanner (Aperio Services, Verona, Italy) with the following scanning parameters: 110 kVp; 1 to 3 mA; 15 × 15-cm FOV; 10-s scan time; and 0.3-mm voxel size. The axial images were exported in DICOM format. The average time interval between the two CBCT scans was 25.0 ± 5.5 months. All the superimpositions were performed using the same computer (DELL, Intel® Core™ i5-3450 CPU@3.10GHz, 8.00 GB; Round Rock, TX, USA).

Voxel-based CBCT mandibular superimposition

The DICOM files were imported into Dolphin Imaging software (ver. 11.9; Dolphin Imaging & Management Solutions, Chatsworth, CA, USA) for subsequent processing. The pre-treatment CBCT image (CT1) was reoriented with the inferior border of the mandible parallel to the floor (Figure 1). The post-treatment CBCT image (CT2) was opened using the

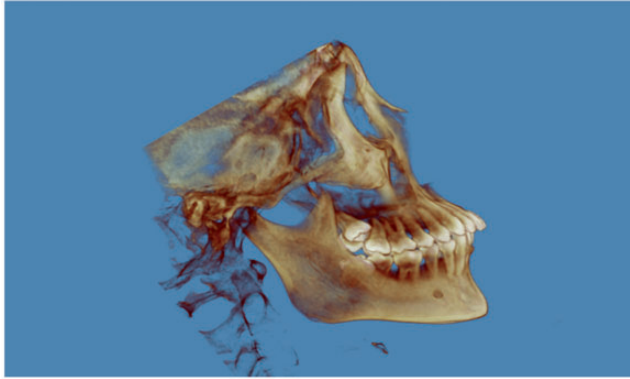


Figure 1. Re-orientation of the pre-treatment CBCT scan with the inferior border of the mandible parallel to the floor.

CBCT, cone-beam computed tomography.

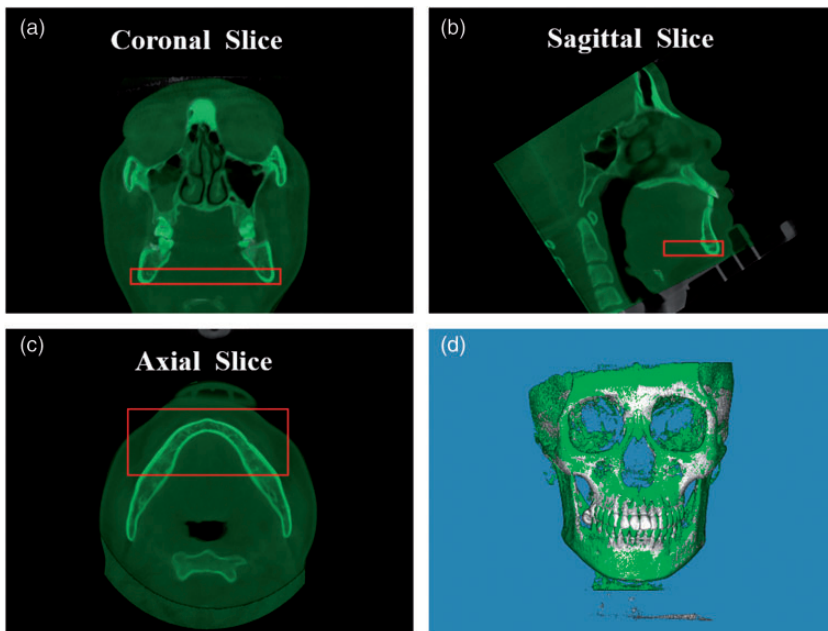


Figure 2. Voxel-based registration (a–c) Reconstruction of the CBCT image in coronal (a), sagittal (b), and axial (c) views. The red frame indicates the registration reference area. (d) Image of voxel-based CBCT mandible superimposition.

CBCT, cone-beam computed tomography.

fusion module tab in the software. The observer first manually moved CT2 as close as possible to CT1 and then performed the voxel-based registration

using the basal bone of the mandibular body, from the external part of the symphysis to the first molar as the reference (Figure 2). This reference region was not

influenced by orthodontic tooth movement and alveolar bone remodeling in adult patients. CT2 was saved in a new orientation. Using the segmentation tool in the 3D module of the Dolphin software, the skeletal models were generated at the same threshold. The acquired images were exported as standard tessellation language (STL) files.

Surface-based CBCT mandible superimposition

The surface-based superimposition was performed using Dolphin Imaging software and Geomagic software (ver. 2012; Geomagic International, Morrisville, NC, USA). The DICOM files were first imported into the Dolphin software and reconstructed at the same threshold using the segmentation tool, and the STL files were then imported into the Geomagic software. The superimposition process involved

the following two steps: i) Manually pointed at the mandibular body corresponding to each surface models to bring the models close to each other; and ii) Global registration was then applied until the two models matched as closely as possible using the buccal and lingual surface of the mandibular body basal bone from the external part of the symphysis to the first molar as the reference (Figure 3).

Comparison of accuracy, reliability, and efficiency of the voxel- and surface-based registrations

To evaluate the accuracy, the absolute mean distance between the two models' surfaces was measured using an iterative closest point (ICP) algorithm technique, and it was represented by a color-coded map. The pre- and post-treatment models superimposed by the two methods were imported into the Geomagic software. Seven round




Figure 3. Surface-based registration (a, b) Initial registration: Three selected reference points on the pre- (a) and post-treatment (b) CBCT models to superimpose two models initially. (c) The yellow area indicates the registration reference area. (d) Image of the surface-based CBCT mandible superimposition CBCT, cone-beam computed tomography.

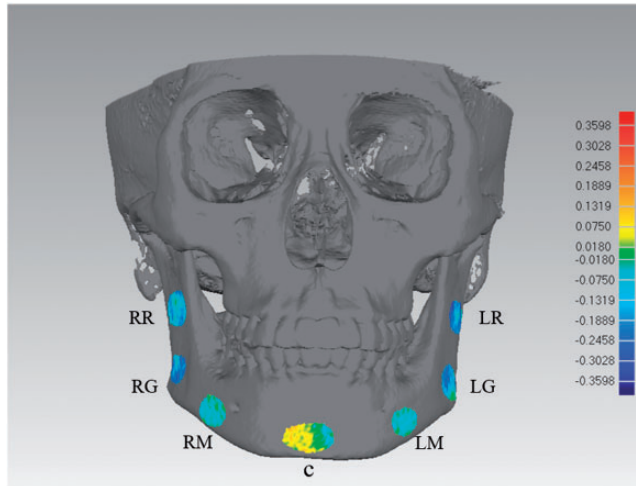


Figure 4. Color-coded map and the absolute mean distance values of the registration procedure. The yellow and red regions represent the positive error areas, and the blue region represents the negative error areas. Seven areas were measured including the basal bone at the mandibular symphysis (C, chin), areas distal to the mental foramen on each side (LM, left side of the mental foramen region; RM, right side of the mental foramen region), areas around mandibular angle on each side (LG, left side of the gonion region; RG, right side of the gonion region), and areas of the buccal side of the ramus (RR, right side of the ramus region; LR, left side of the ramus region).

areas that were about 100 mm^2 were selected around the chin, bilateral mental foramen, bilateral gonion region, and bilateral ramus region of the mandible with the standard selecting tool in the software. The absolute mean distance between the two models' surfaces of these seven areas were measured to compare the accuracy of the voxel- and surface-based registrations. The 3D deviation was also analyzed on the basis of a color-coded map (Figure 4). These selected areas were not influenced by orthodontic tooth movement and alveolar bone remodeling. This method of assessment has previously been reported and is an acceptable parameter.^{9,13} To compare the reliability of the two methods, two observers performed the superimposition, and the measurements were then made by the same observer after 2 weeks. To evaluate the efficiency of the two approaches, 10 out of 27 cases were randomly selected and the time required by the same observer to use the

voxel- and surface-based registration methods was compared.

Statistical analysis

Statistical analysis was performed using IBM SPSS Statistics software (ver. 22.0; IBM Corp., Armonk, NY, USA). After confirming normality of the data distribution using the Shapiro–Wilk test, the paired *t*-test was used to test the accuracy and efficiency of the two registration methods. The level of significance was set at $P < 0.05$. The inter-observer reliability of the measurements was assessed using intraclass correlation coefficients (ICCs, Model: two-way mixed, Type: consistency).

Results

Twenty-seven adult participants (11 men and 16 women; mean age, 22.5 ± 4.5 years) were included in this study.

Table 1. Descriptive statistics for differences between the two images after the registration procedure (mm).

Regions	Voxel registration		Surface registration	
	Mean	SD	Mean	SD
RR	0.163	0.070	0.160	0.100
RG	0.140	0.063	0.145	0.090
RM	0.082	0.046	0.072	0.047
C	0.103	0.059	0.103	0.061
LM	0.078	0.046	0.076	0.044
LG	0.152	0.077	0.155	0.072
LR	0.176	0.089	0.185	0.105

SD, standard deviation; C, chin; LM, left side of the mental foramen region; RM, right side of the mental foramen region; LG, left side of the gonion region; RG: right side of the gonion region; RR, right side of the ramus region; LR, left side of the ramus region.

Three-dimensional superimposition error

Table 1 shows the descriptive analysis for the absolute mean distance values of the two registration methods. The results for the right side of the ramus region (RR), right side of the gonion region (RG), right side of the mental foramen region (RM), chin (C), left side of the mental foramen region (LM), left side of the gonion region (LG), and left side of the ramus region (LR) for the voxel-based registration were 0.163 ± 0.070 mm, 0.140 ± 0.063 mm, 0.082 ± 0.046 mm, 0.103 ± 0.059 mm, 0.078 ± 0.046 mm, 0.152 ± 0.077 mm, and 0.176 ± 0.089 mm, respectively. For surface-based registration, the values were 0.160 ± 0.100 mm (RR), 0.145 ± 0.090 mm (RG), 0.072 ± 0.047 mm (RM), 0.103 ± 0.061 mm (C), 0.076 ± 0.044 mm (LM), 0.155 ± 0.072 mm of (LG), and 0.185 ± 0.105 mm (LR), respectively.

Accuracy comparison

A statistical description and the inferred absolute mean distance differences between the voxel- and surface-based registration methods is shown in Table 2. The differences between the two registration methods were not significant in the RR, RG, RM,

Table 2. Differences in the absolute mean distance between the voxel-based and surface-based registration methods (mm).

	Mean	SD	t	P
RR	0.033	0.112	0.153	0.880
RG	-0.006	0.071	-0.411	0.685
RM	0.010	0.026	1.896	0.069
C	0	0.026	0.067	0.947
LM	0.003	0.027	0.573	0.572
LG	-0.003	0.072	-0.212	0.833
LR	-0.009	0.110	-0.411	0.684

SD, standard deviation; C, chin; LM, left side of the mental foramen region; RM, right side of the mental foramen region; LG, left side of the gonion region; RG: right side of the gonion region; RR, right side of the ramus region; LR, left side of the ramus region.

C, LM, LG, and LR, and the mean values were all below 0.1 mm.

Reliability comparison

To evaluate the reliability of the method, the two observers performed the superimposition procedure independently. The inter-observer reliability of the method was determined by comparing the absolute mean distance measurements of the two observers, using ICCs and 95% confidence intervals. Table 3 shows the ICC results for the inter-observer reliability of all

Table 3. Intraclass correlation coefficients and 95% confidence intervals for repeated measurements.

Regions	Voxel registration		Surface registration	
	ICC	95% Confidence interval	ICC	95% Confidence interval
RR	0.990	0.960–0.998	0.929	0.714–0.982
RG	0.995	0.981–0.999	0.918	0.668–0.980
RM	0.988	0.950–0.997	0.922	0.686–0.981
C	0.984	0.935–0.996	0.982	0.929–0.996
LM	0.994	0.977–0.999	0.990	0.961–0.998
LG	0.993	0.973–0.998	0.940	0.757–0.985
LR	0.996	0.985–0.999	0.990	0.958–0.997

ICC, intraclass correlation coefficient; C, chin; LM, left side of the mental foramen region; RM, right side of the mental foramen region; LG, left side of the gonion region; RG, right side of the gonion region; RR, right side of the ramus region; LR, left side of the ramus region.

Table 4. Differences in the time required to use the voxel-based or surface-based registration method.

	Minimum	Maximum	Mean	SD	t	P
Voxel registration (s)	41	49	44.6	2.5	-78.4	<0.001
Surface registration (s)	242	262	252.3	7.1		

SD, standard deviation.

measurements. The ICC values were consistently above 0.91, indicating that both of the methods had high reliability. The ICC results of the surface-based registration (from 0.918–0.990) were slightly lower than those of the voxel-based registration (from 0.984–0.996).

Efficiency comparison

A statistical description of the time required between the voxel- and surface-based registration methods was shown in Table 4. The time required for the voxel-based registration was 44.6 ± 2.5 s, which was much shorter than that taken for the surface-based registration (252.3 ± 7.1 s). This time had already excluded any time that was needed to transfer the data from one software program to the other, indicating that the voxel-based registration achieved using the Dolphin software was more efficient than the surface-based method that

was achieved using both the Dolphin and Geomagic software ($P < 0.05$).

Discussion

This study aimed to compare the accuracy, reliability, and efficiency of CBCT mandibular superimposition between the voxel- and surface-based registration methods in adult orthodontic patients. The surface-based registration method, which is initially described for 3D image superimposition, uses an ICP algorithm,¹⁴ while the voxel-based registration method uses the volume intensities that are stored in a CBCT DICOM format.⁴ In the voxel registration, the gray-scale differences in the voxels are used to align the two DICOM images based on a maximum mutual information algorithm because each voxel has an individual gray-scale value depending on the structure opacity.^{15,16} Several researchers have described superimposition of the voxel-

based CBCT registration images on those of anterior cranial base structures in both growing and non-growing patients, and it was shown to be accurate and reliable.¹⁷⁻²⁰

The surface-based registration deals with the surface mesh of the 3D structure while the voxel-based registration deals with all the contents of the volume of interest, which may increase the accuracy of the method theoretically. Comparison of two registration methods based on an anterior cranial base in patients who were treated by orthognathic surgery has been reported previously.⁷ No significant difference between the accuracy of the two methods has been found. Similar to the results that were found by the previous studies concerning an anterior cranial base structure, there is no significant difference for the mandibular CBCT superimposition when comparing the accuracy of the voxel- and surface-based registration methods in the present study. The ICC values were all above 0.91, indicating that both of the methods are reliable.

In our study, the research method was based on 27 pairs of pre- and post-treatment CBCT scans of adult orthodontic patients. We measured the accuracy and reliability of both registration methods. In the previous studies, the absolute mean distances of two superimposed surfaces were chosen to be an index to evaluate the accuracy. To compare the accuracy of CBCT voxel superimposition on the zygomatic arches and anterior cranial base, Nada et al.²¹ tested the absolute mean distances of the two surfaces. Similarly, Almkhtar et al.⁷ measured the absolute mean distances of superimposed anterior cranial base surfaces to evaluate the accuracy between voxel registration and surface registration method on anterior cranial base structure. The evaluation process of this study is similar to these previous publications. Because rotation and translation of two images in three dimensions are involved in 3D

superimposition, the anterior and posterior as well as bilateral areas should be selected as evaluation areas, as we have done in this study. The absolute mean distance for the voxel-based registration was from 0.078 mm to 0.176 mm, and the value for the surface-based registration ranged from 0.072 mm to 0.185 mm, which are similar to those reported in previous publications.^{9,13} However, the absolute mean distance cannot fully represent the characteristics of all boundaries and surface distances, and the value has no direction, so it is necessary to observe the registration qualitatively in combination with the analysis of the color-coded map.

Although the accuracy of the two registration methods is similar, the voxel-based registration is selected more frequently. First, the voxel-based registration is more efficient because it reduces processing time and decreases the software that is required without creating an extra surface model. To execute the voxel-based superimposition, only the Dolphin software was required, while both the Dolphin and Geomagic software programs were included in the surface-based superimposition. Inaccurate segmentation of the surface model may be a possible source of error because the algorithm depends on the Hounsfield value (HU value) of CBCT images,²² which can cause a false superimposition result. Second, it is much easier to assess the inner surfaces using the voxel-based registration, which allows the superimposed structures to be viewed in the multiplanar slices.

The voxel-based registration method allows accurate structure matching using high gray-scale levels. It could be applied well to mandibles to evaluate the orthodontic tooth movement and treatment outcomes. For cephalometric radiograph superimposition, the anterior cranial base is considered to be a stable structure. However, the stable regions for 3D image superimposition are still controversial,

especially for mandibular regional superimposition in growing patients. As reported by Björk,²³ the following structures of the mandible are believed to be stable on a cephalometric radiograph in growing patients: (1) the anterosuperior contour of the chin; (2) the inner cortical structure of the inferior border of the mandibular symphysis; (3) the trabecular structure in the symphysis; (4) the contour of the mandibular canal; and (5) the lower contour of the developing third molar tooth germ before root development begins. However, they may not be reliable for 3D superimposition, which also involves the transverse dimension.²⁴ Ruellas et al.²⁵ evaluated three reference regions for mandibular superimposition based on voxel registration in growing patients, and they concluded that the mandibular body mask is a reliable reference for 3D regional registration. The samples in this study were obtained from adult patients; the mandibular basal bone in adults was selected as the registration area because it should be stable and unaffected by treatment or growth. Therefore, the two methods require further comparison in growing patients in a future study because the stable registration area has been confirmed.

Conclusions

The voxel- and surface-based registration methods for CBCT mandibular superimposition are accurate and reliable. However, the voxel-based registration method is more efficient, and therefore, it has advantages over the surface-based registration method for CBCT mandibular superimposition analysis of orthodontic tooth movement.

Acknowledgements

We thank SW for the statistical analysis support.


Declaration of conflicting interest

The authors declare that there is no conflict of interest.

Funding

This work was supported by the Projects of Ten-Thousand Talents Program No. QNBJ2019-2 (Y. L.), the National Natural Science Foundation of China No. 81871492 (Y.L.) and No. 62076011 (Y. Z.), the Beijing Municipal Natural Science Foundation No. L182005 (Y.L.), the Youth Fund of Peking University School of Stomatology No. PKUSS20200114 (J.L.), and the New Clinical Techniques and Therapies of Peking University School and Hospital of Stomatology No. PKUSSNCT-17B14 (J.L.).

ORCID iD

Yan Liu  <https://orcid.org/0000-0002-8193-6729>

References

1. Ludlow JB, Gubler M, Cevidanes L, et al. Precision of cephalometric landmark identification: cone-beam computed tomography vs conventional cephalometric views. *Am J Orthod Dentofacial Orthop* 2009; 136: 312.e1-10.
2. Hwang HS, Hwang CH, Lee KH, et al. Maxillofacial 3-dimensional image analysis for the diagnosis of facial asymmetry. *Am J Orthod Dentofacial Orthop* 2006; 130: 779–785.
3. Park JH, Tai K and Owtad P. 3-Dimensional cone-beam computed tomography superimposition: a review. *Semin Orthod* 2015; 21: 263–273.
4. Cevidanes LH, Bailey LJ, Tucker GR Jr, et al. Superimposition of 3D cone-beam CT models of orthognathic surgery patients. *Dentomaxillofac Radiol* 2005; 34: 369–375.
5. Swennen GR, Mollemans W, De Clercq C, et al. A cone-beam computed tomography triple scan procedure to obtain a three dimensional augmented virtual skull model appropriate for orthognathic surgery planning. *J Craniofac Surg* 2009; 20: 297–307.
6. Ghoneima A, Cho H, Farouk K, et al. precision and reliability of landmark-based, surface-based and voxel-based 3D cone-

- beam computed tomography superimposition methods. *Orthod Craniofac Res* 2017; 20: 227–236.
7. Almukhtar A, Ju X, Khambay B, et al. Comparison of the precision of voxel based registration and surface based registration for 3D assessment of surgical change following orthognathic surgery. *PLoS One* 2014; 9: e93402.
 8. Ludlow JB, Davies-Ludlow LE, Brooks SL, et al. Dosimetry of 3 CBCT devices for oral and maxillofacial radiology: CB Mercuray, NewTom 3G and i-CAT. *Dentomaxillofac Radiol* 2006; 35: 219–226.
 9. Koerich L, Burns D, Weissheimer A, et al. Three-dimensional maxillary and mandibular regional superimposition using cone beam computed tomography: a validation study. *Int J Oral Maxillofac Surg* 2016; 45: 662–669.
 10. Rupprecht RD, Horning GM, Nicoll BK, et al. Prevalence of dehiscences and fenestrations in modern American skulls. *J Periodontol* 2001; 72: 722–729.
 11. Sun L, Zhang L, Shen G, et al. Accuracy of cone-beam computed tomography in detecting alveolar bone dehiscences and fenestrations. *Am J Orthod Dentofacial Orthop* 2015; 147: 313–323.
 12. Leung CC, Palomo L, Griffith R, et al. Accuracy and reliability of cone-beam computed tomography for measuring alveolar bone height and detecting bony dehiscences and fenestrations. *Am J Orthod Dentofacial Orthop* 2010; 137: S109–S119.
 13. Koerich L, Weissheimer A, De Menezes LM, et al. Rapid 3D mandibular superimposition for growing patients. *Angle Orthod* 2017; 87: 473–479.
 14. Hajeer MY, Ayoub AF and Millett DT. Three-dimensional assessment of facial soft-tissue asymmetry before and after orthognathic surgery. *Br J Oral Maxillofac Surg* 2004; 42: 396–404.
 15. MacDonald-Jankowski D and Orpe EC. Computed tomography for oral and maxillofacial surgeons. Part 2: cone-beam computed tomography. *Asian J Oral Maxillofac Surg* 2006; 18: 85–92.
 16. Lee JH, Kim MJ, Kim SM, et al. The 3D CT superimposition method using image fusion based on the maximum mutual information algorithm for the assessment of oral and maxillofacial surgery treatment results. *Oral Surg Oral Med Oral Pathol Oral Radiol* 2012; 114: 167–174.
 17. Cevidanes LH, Heymann G, Cornelis MA, et al. Superimposition of 3-dimensional cone-beam computed tomography models of growing patients. *Am J Orthod Dentofacial Orthop* 2009; 136: 94–99.
 18. Cevidanes LH, Bailey LJ, Tucker SF, et al. Three dimensional cone-beam computed tomography for assessment of mandibular changes after orthognathic surgery. *Am J Orthod Dentofacial Orthop* 2007; 131: 44–50.
 19. Weissheimer A, Menezes LM, Koerich L, et al. Fast three-dimensional superimposition of cone beam computed tomography for orthopaedics and orthognathic surgery evaluation. *Int J Oral Maxillofac Surg* 2015; 44: 1188–1196.
 20. Bazina M, Cevidanes L, Ruellas A, et al. Precision and reliability of Dolphin 3-dimensional voxel-based superimposition. *Am J Orthod Dentofacial Orthop* 2018; 153: 599–606.
 21. Nada RM, Maal TJ, Breuning KH, et al. Precision and reproducibility of voxel based superimposition of cone beam computed tomography models on the anterior cranial base and the zygomatic arches. *PLoS One* 2011; 6: e16520.
 22. Molteni R. Prospects and challenges of rendering tissue density in Hounsfield units for cone beam computed tomography. *Oral Surg Oral Med Oral Pathol Oral Radiol* 2013; 116: 105–119.
 23. Björk A. Prediction of mandibular growth rotation. *Am J Orthod* 1969; 55: 585–599.
 24. Kim I, Oliveira ME, Duncan WJ, et al. 3D assessment of mandibular growth based on image registration: a feasibility study in a rabbit model. *Biomed Res Int* 2014; 2014: 276128.
 25. Ruellas AC, Yatabe MS, Souki BQ, et al. 3D mandibular superimposition: comparison of regions of reference for voxel-based registration. *PLoS One* 2016; 11: e0157625.