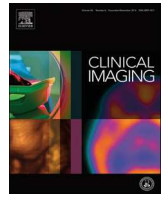




Since January 2020 Elsevier has created a COVID-19 resource centre with free information in English and Mandarin on the novel coronavirus COVID-19. The COVID-19 resource centre is hosted on Elsevier Connect, the company's public news and information website.

Elsevier hereby grants permission to make all its COVID-19-related research that is available on the COVID-19 resource centre - including this research content - immediately available in PubMed Central and other publicly funded repositories, such as the WHO COVID database with rights for unrestricted research re-use and analyses in any form or by any means with acknowledgement of the original source. These permissions are granted for free by Elsevier for as long as the COVID-19 resource centre remains active.



## Cardiothoracic Imaging

## Rare presentations of COVID-19: PRES-like leukoencephalopathy and carotid thrombosis

Florence X. Doo<sup>a,\*</sup>, Gassan Kassim<sup>b</sup>, Daniel R. Lefton<sup>a</sup>, Shanna Patterson<sup>c</sup>, Hien Pham<sup>a</sup>, Puneet Belani<sup>a</sup>

<sup>a</sup> Mount Sinai Health System, Diagnostic, Molecular and Interventional Radiology, 1000 10th Avenue, Radiology, 4B 25, New York 10019, NY, USA

<sup>b</sup> Mount Sinai Health System, Internal Medicine, 1000 10th Ave, New York 10019, NY, USA

<sup>c</sup> Mount Sinai Health System, Neurology, 1000 10th Ave, New York 10019, NY, USA

## ARTICLE INFO

## Keywords:

COVID-19

Infection

Leukoencephalopathy

Carotid thrombosis

Stroke

## ABSTRACT

Coronavirus disease 2019 (COVID-19) is a global pandemic, and it is increasingly important that physicians recognize and understand its atypical presentations. Neurological symptoms such as anosmia, altered mental status, headache, and myalgias may arise due to direct injury to the nervous system or by indirectly precipitating coagulopathies. We present the first COVID-19 related cases of carotid artery thrombosis and acute PRES-like leukoencephalopathy with multifocal hemorrhage.

## 1. Introduction

The SARS-CoV-2 virus (severe acute respiratory syndrome-coronavirus 2) and the resultant Coronavirus disease 2019 (COVID-19) was first identified in December 2019, and has subsequently spread into a world-wide pandemic with at least 1.5 million cases in 212 countries [1]. The point of entry for the SARS-CoV-2 virus is the ACE2 cell surface receptor, which is variably found in many organs including the lungs and gastrointestinal tissues, which may explain COVID-19 transmission and symptom manifestation, typically reported to be fever, cough, shortness of breath, and diarrhea [2–5].

Recent reports have additionally identified COVID-19-related neurologic symptoms such as anosmia, altered mental status, headache, and myalgias [6–9]. These neurologic findings may be attributed to both direct and indirect effects of the SARS-CoV-2 virus (Fig. 1) [10,11]. Direct nervous system injury may occur through hematogenous spread or retrograde CNS invasion as the ACE2 receptor is also expressed in skeletal muscles, vascular endothelial cells, and nerve cells such as in the olfactory bulb [12–14]. Indirectly, SARS-CoV-2 may affect coagulation cascade functionality, leading to thrombus formation or hemorrhage, including strokes and acute hemorrhagic necrotizing encephalopathy [15–20].

We report two unusual neurological presentations which may be related to these potential direct and indirect effects of COVID-19 infection, with clinicoradiological correlations. First, carotid thrombosis with large ischemic stroke; large ischemic strokes have previously been identified in the prior SARS outbreak, and may be an initial presenting finding in COVID-19 [15]. Secondly, while posterior reversible encephalopathy syndrome (PRES) has been reported in other viral illnesses, this is the first PRES-like case in COVID-19 diagnosed with imaging findings of cortical/subcortical edema in a symmetric and more dominant distribution in the parieto-occipital lobes [21–23].

## 2. Case presentations

The first case is that of a 55 year-old male with past medical history of insulin-dependent diabetes mellitus, who presented to the emergency department with left wrist droop. Initial CT head was negative. While in the emergency department, the patient developed new-onset left gaze preference, left facial droop and left arm weakness. A CT angiogram of the head and neck was obtained, which showed large thrombus in the right common carotid artery, and CT head perfusion study showed acute right frontal ischemic infarct and surrounding penumbra (Fig. 2), with lung apical findings raising suspicion for COVID-19. Catheter an-

\* Corresponding author.

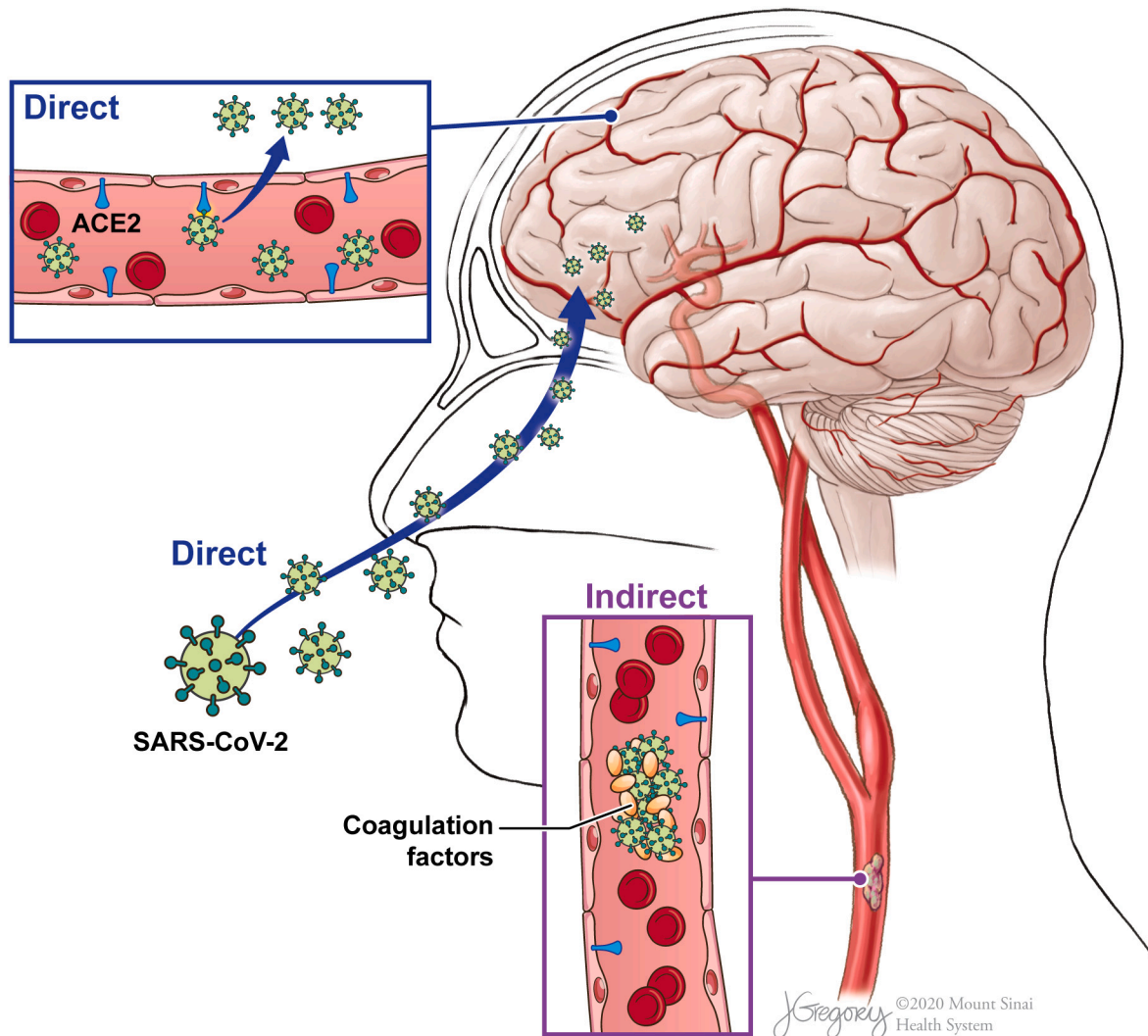
E-mail address: [florence.doo@mountsinai.org](mailto:florence.doo@mountsinai.org) (F.X. Doo).

<https://doi.org/10.1016/j.clinimag.2020.07.007>

Received 13 May 2020; Received in revised form 19 June 2020; Accepted 13 July 2020

Available online 16 July 2020

0899-7071/ © 2020 Elsevier Inc. All rights reserved.

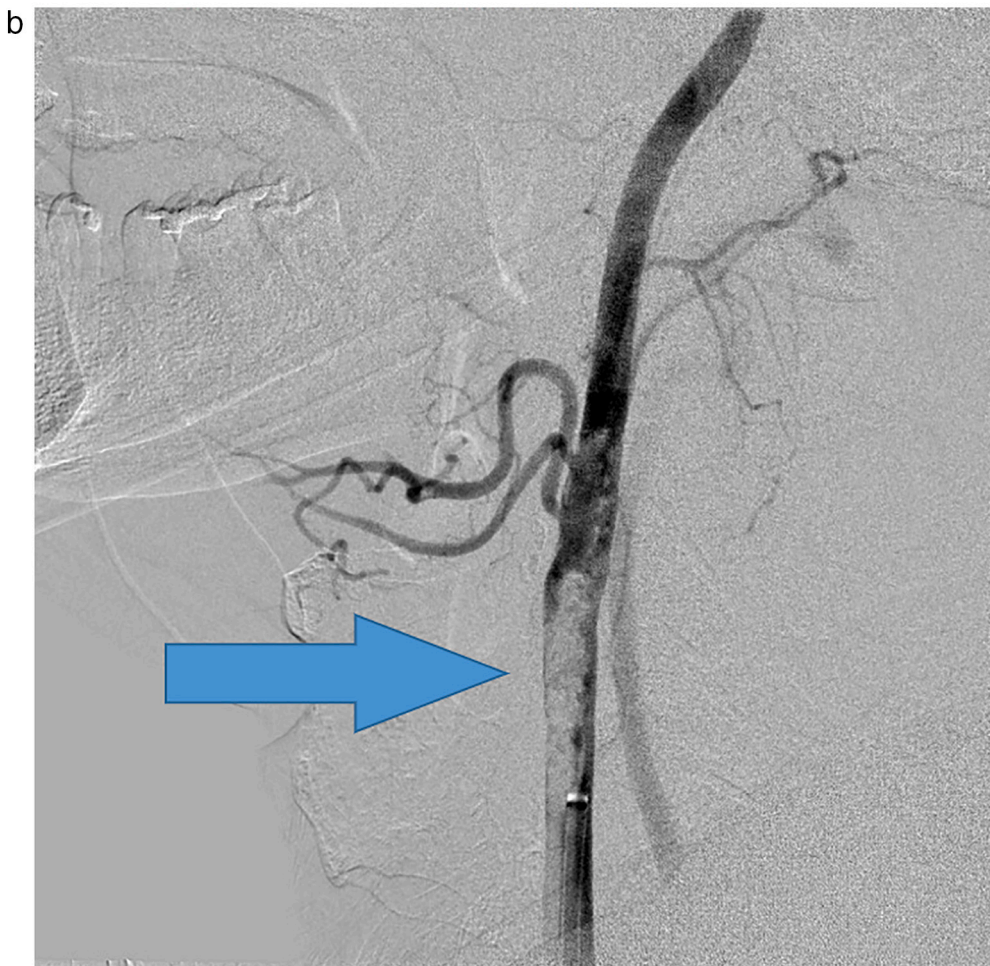
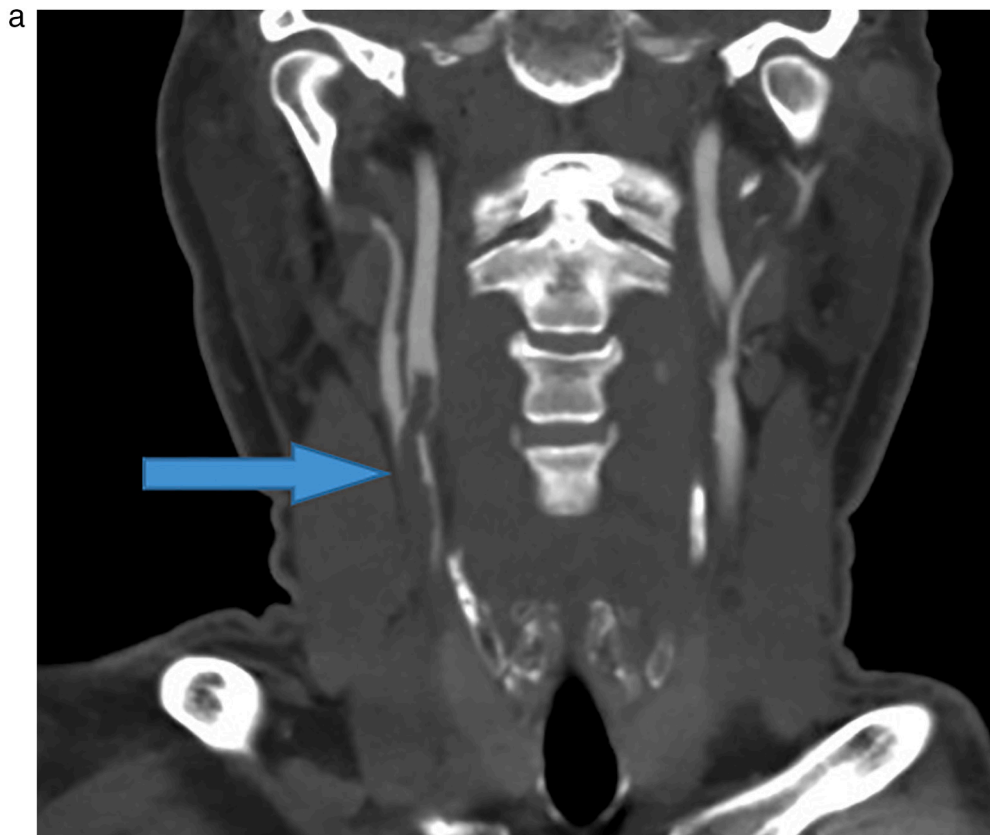


**Fig. 1.** Potential pathways for SARS-CoV-2 nervous system involvement. SARS-CoV-2 virus may directly invade through hematogenous spread or retrograde effect through ACE2 receptors on vascular endothelial cells or the nervous system. SARS-CoV-2 may also affect coagulation cascade functionality, indirectly precipitating thrombus formation or hemorrhage. (Illustration credit to Jill Gregory, printed with permission from ©Mount Sinai Health System).

giography confirmed a large thrombus in the right carotid artery for which chemical thrombolysis was performed with eptifibatide. Patient was found to be COVID-19 positive on reverse transcriptase polymerase chain reaction test of a nasopharyngeal swab. He developed fevers, and was started on aspirin, atorvastatin, plaquenil, and azithromycin. The

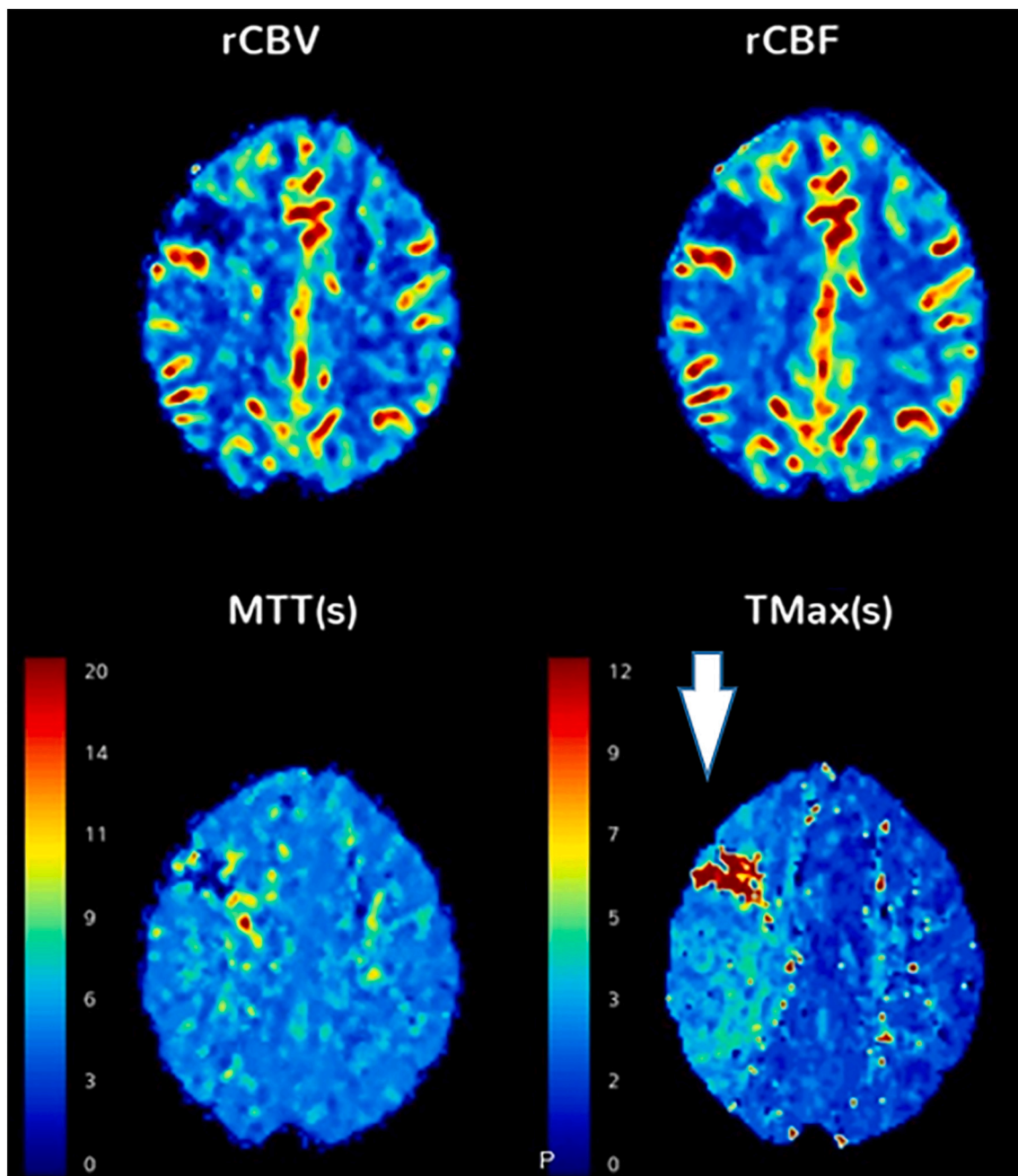
patient's dysarthria and left gaze preference began to improve. A follow-up MR angiogram (MRA) of the head and neck was performed which demonstrated significantly decreased thrombus burden.

The second case is that of a 64 year-old male, former smoker with no other past medical history or prescribed medications, who presented

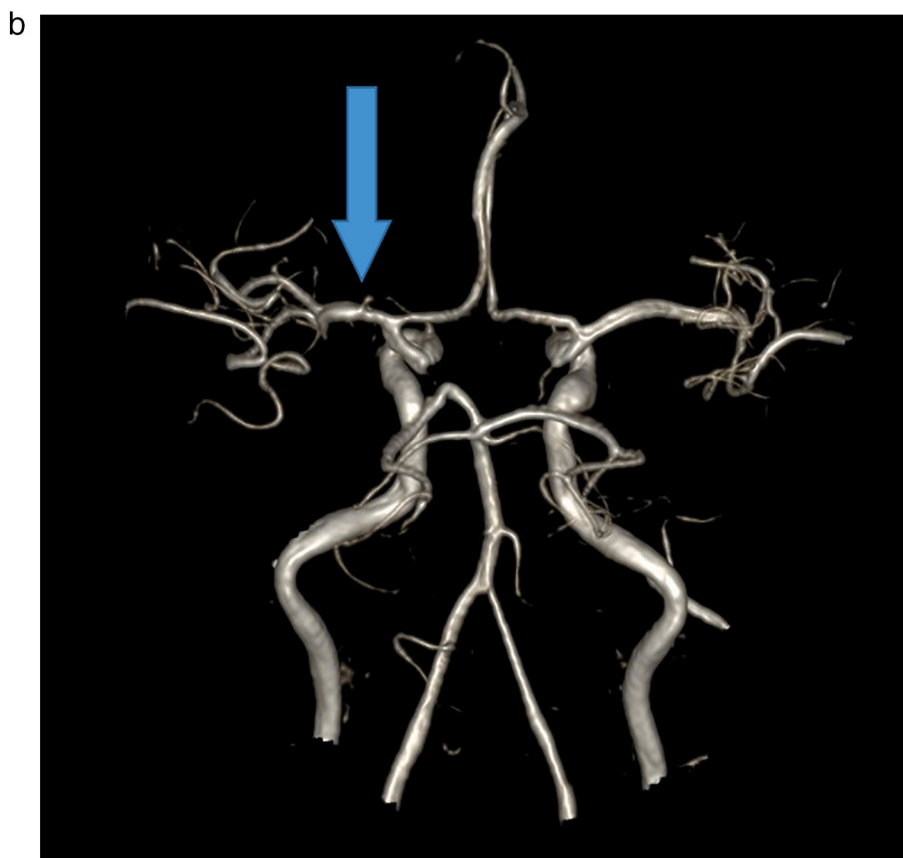
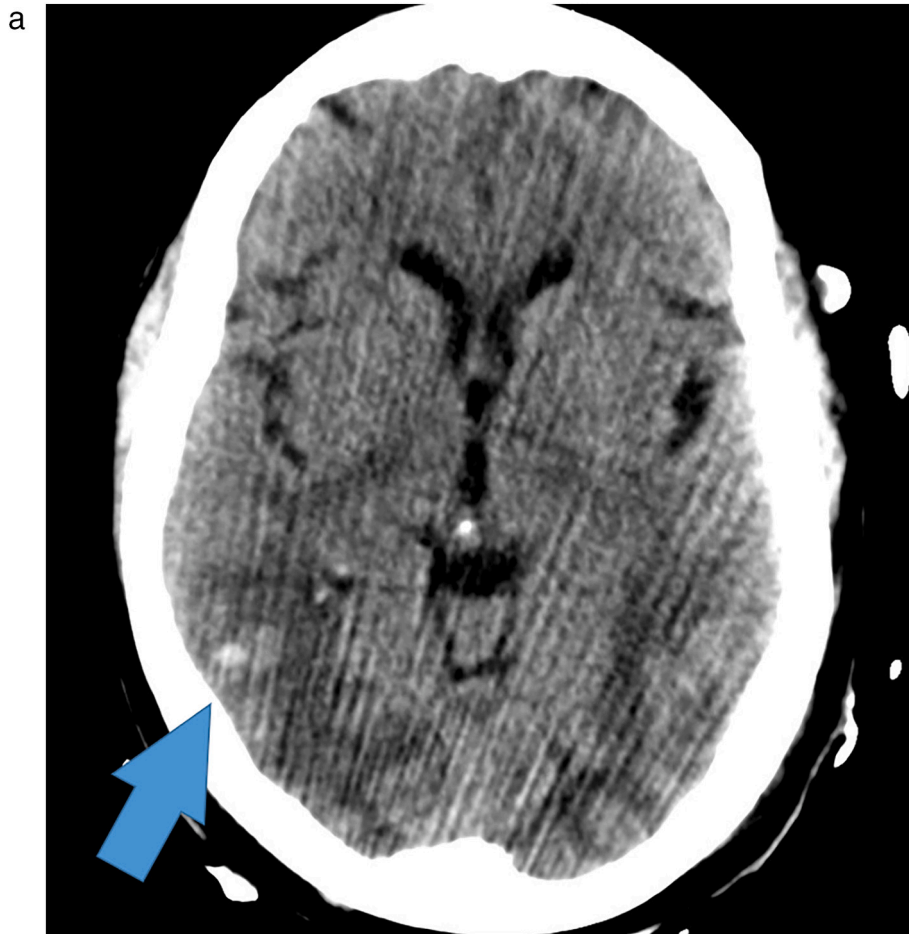
(caption on next page)

**Fig. 2.** Large thrombosis of the carotid artery. A 55 year-old male, who presented with left wrist drop, found to be COVID-19 positive by serology. (A) CT angiogram of the head and neck showed a large subocclusive thrombosis of the right common carotid artery extending into the internal and external carotid arteries (*arrows*). (B) CT perfusion study showed acute infarct in the right superior frontal lobe, with a large area of increased Tmax in the right cerebral hemisphere, involving the right frontal and parietal lobes, suggesting an area at risk for further infarction (*box*). (C) Subsequently, a right carotid endovascular chemical thrombolysis was performed.



**Fig. 2.** (continued)



(caption on next page)

**Fig. 3.** Acute PRES-like leukoencephalopathy with multifocal hemorrhage. A 64 year-old male, COVID-19 positive by serology, who initially presented to ED with cough, fever, and chills, with hypoxic respiratory failure requiring admission to MICU, subsequently had a change in mental status. (A) CT head demonstrated foci of hemorrhage with bilateral posterior cerebral vasogenic edema. (B) MRA of the brain, 3D reconstruction showing mild narrowing of the left MCA but no acute abnormalities. (C) MRI of the brain, FLAIR sequence showing symmetric cerebral edema greatest in the parieto-occipital white matter, and (D) same MR of the brain, GRE sequence showing multifocal foci of hemorrhage, together likely reflecting posterior reversible encephalopathy syndrome (PRES)-like leukoencephalopathy with hemorrhagic component.

to the hospital with one week history of ongoing productive cough, worsening shortness of breath, generalized fatigue, decreased appetite, myalgias, fevers, chills, and malaise. In the emergency department, the patient was found to be mildly tachycardic, tachypneic, and saturating at 88% on room air which improved to 96% on 4 liters nasal cannula. The patient tested positive for SARS-CoV2, and was admitted. Subsequently while on the floor, the patient continued to desaturate with higher oxygen requirements, and was transferred to the intensive care unit (ICU) for close monitoring. Given worsening respiratory failure, the patient was intubated, and placed on maximal ventilatory support. Due to ongoing desynchrony and desaturation, the patient was paralyzed with a vecuronium drip, started on inhaled nitric oxide and subsequently prone for 12 h. Early ICU course was further complicated by persistent fevers up to 103, acute kidney injury with electrolyte abnormalities, and transaminitis.

The patient was administered hydroxychloroquine, azithromycin, vancomycin and ceftriaxone. Given the severity of his condition, the patient was given two doses of tocilizumab. As the patient began to improve, ventilator support was decreased and paralysis was weaned off. Thereafter the patient developed rhythmic jerking movements that were refractory to midazolam pushes, but stopped with vecuronium push. Video electroencephalogram was consistent with status epilepticus. Multiple antiepileptic drugs including intravenous levetiracetam, lacosamide and valproic acid, along with a midazolam drip were required to stop the seizure activity.

Initial CT head showed striking hypoattenuation of the white matter consistent with bilateral posterior cerebral vasogenic edema, and repeat CT head a few days later revealed interval devolvement of multiple small foci of brain parenchymal hemorrhage, right greater than left (Fig. 3). Initial brain MRI re-demonstrated extensive symmetric cerebral edema with a parieto-occipital dominance and scattered small foci of recent hemorrhage. MRA and MR venography were both negative for any acute abnormalities. Repeat brain MRI showed slightly decreased

but persistent extensive cerebral edema with stable foci of hemorrhage. Lumbar puncture was performed and cerebrospinal fluid analysis was within normal limits except for slight nonspecific elevation of protein.

### 3. Discussion

We demonstrate two patients with unusual neurologic clinical presentations and imaging findings in the setting of COVID-19. While neurologic symptoms such as altered mental status may be an atypical presentation of COVID-19, it may be more commonly seen as the incidence of COVID-19 increases.

As seen in our first case, COVID-19 may indirectly precipitate unusual thrombotic or hemorrhagic findings in patients without other predisposing factors. Disruption of the coagulation cascade may result in thrombus formation in proximal large vessel branch points such as the distal common and cervical internal carotid arteries, causing intracranial large vessel occlusions or unusual cerebrovascular accidents. Potential SARS-CoV-2 related coagulation cascade dysfunction is beginning to be recognized for thrombus formation in COVID-19 patients, and as recent studies have shown, may adversely affect prognosis [24,25].

Our second case may be attributable to the direct entry and invasion of the SARS-CoV-2 virus. The pathophysiology of PRES itself is not entirely understood, however is thought to be related to hyperperfusion or vasospasm, with fluid extravasation through the blood-brain barrier resulting in cortical or subcortical edema [26]. In our second patient, this PRES-like appearance may be attributable to direct uptake of SARS-CoV-2 via the olfactory bulb and surface ACE2 targets on vascular endothelial cells, injuring the blood-brain barrier [14]. Additionally, the ACE2 enzyme degrades angiotensin-II in the renin-angiotensin system, which affects blood pressure regulation, and may be another potential pathophysiological explanation. The rare hemorrhagic component may have been due to superimposed COVID-19 coagulopathic abnormalities.

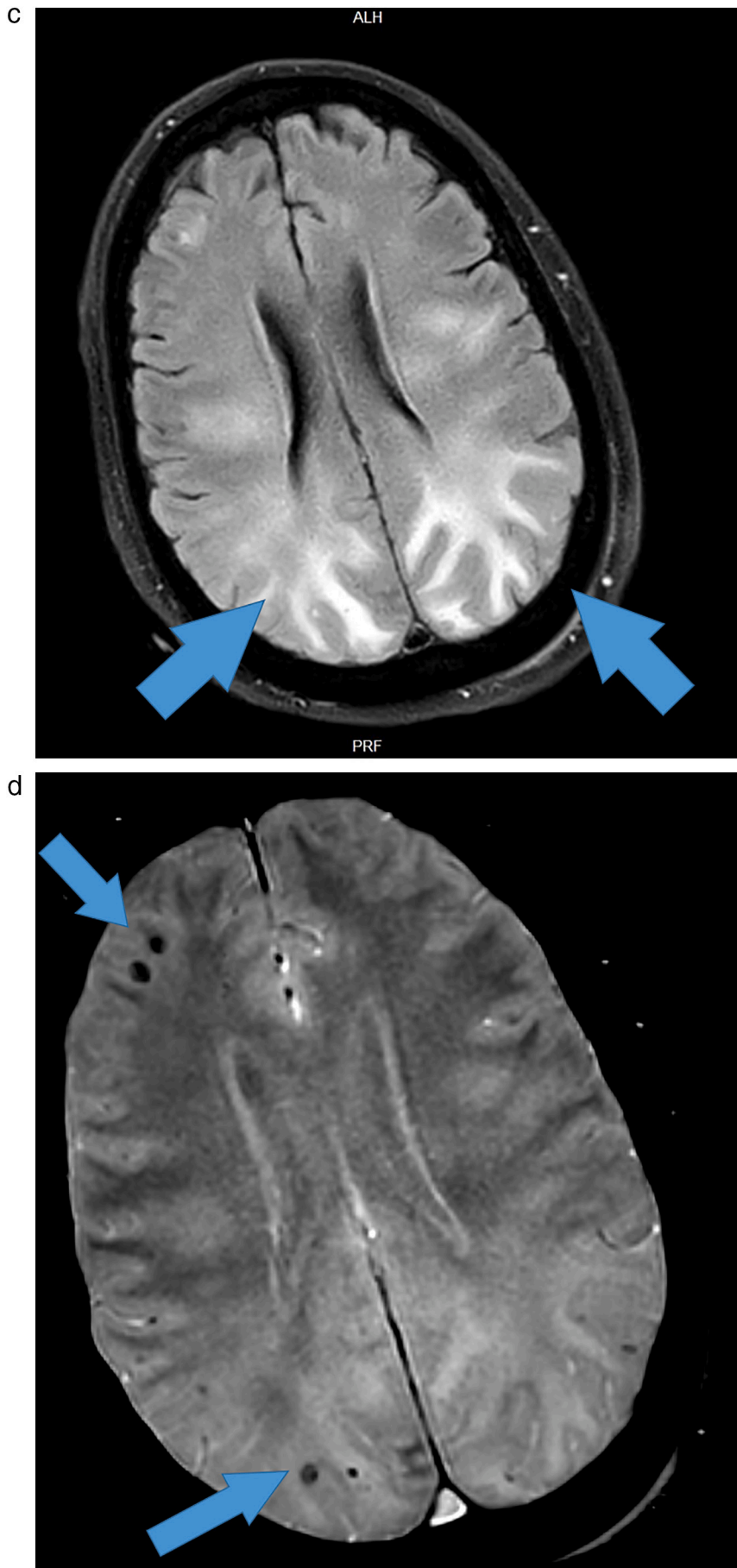


Fig. 3. (continued)



Further research is needed to confirm the mechanisms underlying SARS-CoV-2 invasion and its resultant neurological effects. Due to the potential for SARS-CoV-2 to directly and indirectly affect the nervous system as described above, physicians should be aware of these atypical neurologic presentations in COVID-19 patients.

#### Declaration of competing interest

None, for all listed authors and contributors.

#### References

- [1] World Health Organization. Coronavirus [internet] Available from <https://www.who.int/emergencies/diseases/novel-coronavirus-2019>.
- [2] Hamming I, Timens W, Bulthuis MLC, Lely AT, Navis GJ, van Goor H. Tissue distribution of ACE2 protein, the functional receptor for SARS coronavirus. A first step in understanding SARS pathogenesis. *J Pathol* 2004;203(2):631–7.
- [3] Jiang F, Deng L, Zhang L, Cai Y, Cheung CW, Xia Z. Review of the clinical characteristics of coronavirus disease 2019 (COVID-19). *J Gen Intern Med* 2020;35(5):1545–9. <https://doi.org/10.1007/s11606-020-05762-whhttps://pubmed.ncbi.nlm.nih.gov/32133578/>.
- [4] Huang C, Wang Y, Li X, et al. Clinical features of patients infected with 2019 novel coronavirus in Wuhan, China. *Lancet* 2020;395(10223):497–506.
- [5] Hoffmann M, Kleine-Weber H, Schroeder S, et al. SARS-CoV-2 cell entry depends on ACE2 and TMPRSS2 and is blocked by a clinically proven protease inhibitor. *Cell* 2020;181(2):271–80. <https://doi.org/10.1016/j.cell.2020.02.052https://pubmed.ncbi.nlm.nih.gov/32142651/>.
- [6] Wang H-Y, Li X-L, Yan Z-R, Sun X-P, Han J, Zhang B-W. Potential neurological symptoms of COVID-19. *Ther Adv Neurol Disord* 2020;13. [1756286420917830].
- [7] Mao L, Jin H, Wang M, et al. Neurologic manifestations of hospitalized patients with coronavirus disease 2019 in Wuhan, China. *JAMA Neurol* 2020;77(6):1–9<https://www.ncbi.nlm.nih.gov/pmc/articles/PMC7149362/>.
- [8] Jin H, Hong C, Chen S, et al. Consensus for prevention and management of coronavirus disease 2019 (COVID-19) for neurologists. *Stroke Vasc Neurol* 2020;94(19):809–10. <https://doi.org/10.1212/WNL.00000000000009455https://pubmed.ncbi.nlm.nih.gov/32229625/>. [svn-2020-000382].
- [9] Nath A. Neurologic complications of coronavirus infections. *Neurology* 2020. <https://doi.org/10.1212/WNL.00000000000009455>.
- [10] Asadi-Pooya AA, Simani L. Central nervous system manifestations of COVID-19: a systematic review. *J Neurol Sci* 2020;116832.
- [11] Conde G, Pájaro LDQ, Marzola IDQ, Villegas YR, Salazar LRM. Neurotropism of SARS-CoV 2: mechanisms and manifestations. *J Neurol Sci* 2020;0(0).
- [12] Gane SB, Kelly C, Hopkins C. Isolated sudden onset anosmia in COVID-19 infection. A novel syndrome? *Rhinology* 2020;58(3):299–301. <https://doi.org/10.4193/Rhin20.114https://pubmed.ncbi.nlm.nih.gov/32240279/>.
- [13] Baig AM, Khaleeq A, Ali U, Syeda H. Evidence of the COVID-19 virus targeting the CNS: tissue distribution, host–virus interaction, and proposed neurotropic mechanisms. *ACS Chem Neurosci* 2020;11(7):995–8.
- [14] Politi LS, Salsano E, Grimaldi M. Magnetic resonance imaging alteration of the brain in a patient with coronavirus disease 2019 (COVID-19) and anosmia. *JAMA Neurol* 2020. <https://doi.org/10.1001/jamaneurol.2020.2125>. (Published online May 29).
- [15] Zhang Y, Xiao M, Zhang S, et al. Coagulopathy and antiphospholipid antibodies in patients with Covid-19. *N Engl J Med* 2020;0(0). [null].
- [16] Han M, Yan W, Huang Y, et al. The nucleocapsid protein of SARS-CoV induces transcription of hfg12 prothrombinase gene dependent on C/EBP alpha. *J Biochem (Tokyo)* 2008;144(1):51–62.
- [17] Antoniak S, Mackman N. Multiple roles of the coagulation protease cascade during virus infection. *Blood* 2014;123(17):2605–13.
- [18] Poyiadji N, Shahin G, Noujaim D, Stone M, Patel S, Griffith B. COVID-19–associated acute hemorrhagic necrotizing encephalopathy: CT and MRI features. *Radiology* 2020;201187<https://doi.org/10.1148/radiol.2020201187https://pubmed.ncbi.nlm.nih.gov/32228363/>.
- [19] Giannis D, Ziovas IA, Gianni P. Coagulation disorders in coronavirus infected patients: COVID-19, SARS-CoV-1, MERS-CoV and lessons from the past. *J Clin Virol* 2020;127:104362<https://www.sciencedirect.com/science/article/pii/S1386653220301049>.
- [20] Tsai L-K, Hsieh S-T, Chang Y-C. Neurological manifestations in severe acute respiratory syndrome. *Acta Neurol Taiwan* 2005;14(3):113–9.
- [21] Bartynski WS. Posterior reversible encephalopathy syndrome, part 1: fundamental imaging and clinical features. *Am J Neuroradiol* 2008;29(6):1036–42.
- [22] McKinney AM, Short J, Truwit CL, et al. Posterior reversible encephalopathy syndrome: incidence of atypical regions of involvement and imaging findings. *Am J Roentgenol* 2007;189(4):904–12.
- [23] Bartynski WS, Upadhyaya AR, Boardman JF. Posterior reversible encephalopathy syndrome and cerebral vasculopathy associated with influenza a infection: report of a case and review of the literature. *J Comput Assist Tomogr* 2009;33(6):917–22.
- [24] Klok FA, Kruip MJHA, van der Meer NJM, et al. Incidence of thrombotic complications in critically ill ICU patients with COVID-19. *Thromb Res* 2020;191:145–7. <https://doi.org/10.1016/j.thromres.2020.04.013https://pubmed.ncbi.nlm.nih.gov/32291094/>.
- [25] Thachil J, Tang N, Gando S, et al. ISTH interim guidance on recognition and management of coagulopathy in COVID-19. *J Thromb Haemost* 2020. <https://doi.org/10.1111/jth.14860>.
- [26] Bartynski WS. Posterior reversible encephalopathy syndrome, part 2: controversies surrounding pathophysiology of vasogenic edema. *Am J Neuroradiol* 2008;29(6):1043–9.