

## CASE REPORT

# Delirium with delayed diagnosis of hereditary coproporphyrria

Seyma Eroglu<sup>1</sup>  | Ilhan Birsenogul<sup>2</sup> 

<sup>1</sup>Department of Internal Medicine, Weiss Memorial Hospital, Chicago, Illinois, USA

<sup>2</sup>Department of Internal Medicine, SBU Adana Sehir Egitim ve Arastirma Hastanesi, Adana, Turkey

**Correspondence**

Seyma Eroglu, Department of Internal Medicine, Weiss Memorial Hospital, 4646 N Marine Dr, Chicago, IL 60640, USA.

Email: [seroglu@weisshospital.com](mailto:seroglu@weisshospital.com)

**Abstract**

We present a hereditary coproporphyrria patient with acute psychiatric symptoms and skin lesions initially misdiagnosed with schizoaffective disorder and later developed hyperactive delirium and atrial fibrillation requiring intensive care unit admission. He recovered after administering glucose infusions and the discontinuation of porphyrinogenic medications.

**KEYWORDS**

atrial fibrillation, delirium, porphyria

## 1 | INTRODUCTION

Porphyrias are rare disorders and are often misdiagnosed due to nonspecific symptoms. An altered mental status is one of the presenting symptoms of acute porphyria. There are three subtypes of porphyrias related to neuropsychiatric disorders: acute intermittent porphyria, variegate porphyria (VP), and hereditary coproporphyrria (HCP). Skin lesions primarily occur in HCP and VP. The management of porphyria-related neuropsychiatric disorders is unique, and psychotropic medications can deteriorate clinical course due to their porphyrinogenic properties. Therefore, it is vital to suspect acute porphyria in a patient with unexplained neuropsychiatric symptoms for appropriate treatment and prevention of life-threatening complications.

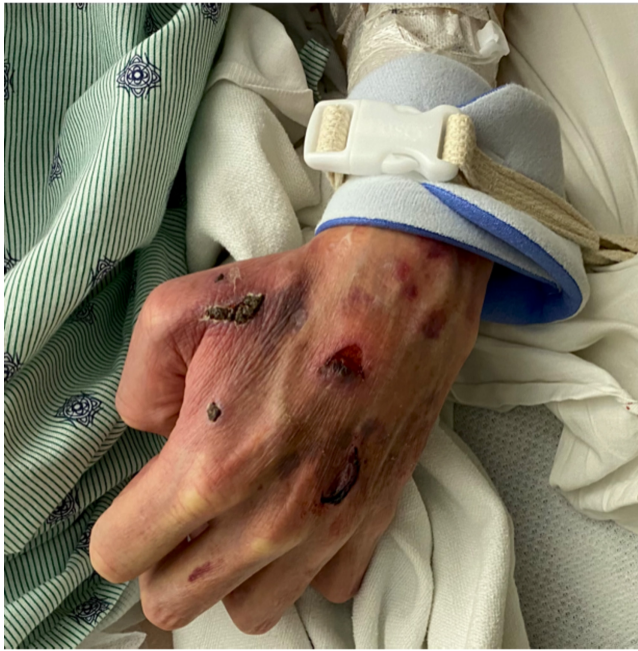## 2 | CASE PRESENTATION

A 66-year-old man was brought to the emergency department due to violent behavior. He was restless, disoriented, and had delusions and visual hallucinations. He had a past medical history of dementia, insomnia, and

depressive disorder. His family history was initially unremarkable. He did not smoke tobacco, drink alcohol, or use recreational drugs. His medications were cyanocobalamin, fluoxetine, and olanzapine. He was a renowned and award-winning cartoonist. The temperature was 36.7°C; the heart rate was 79 beats per minute; the respiratory rate was 18 breaths per minute; the blood pressure was 126/88 mmHg; and the oxygen saturation was 98% while the patient was breathing ambient air. The patient was a Caucasian male who appeared his stated age, in distress, agitated, and unable to be redirected. On mental status examination, the patient was awake and alert, disoriented, in an angry mood, and had a labile affect, limited cognition, and poor insight and judgment. His behavior was aggressive, with mixed delusions and visual hallucinations. His speech rate was rapid and pressured. A skin examination showed crusted skin lesions on the dorsum of the hands and the forearms (Figure 1). The remainder of the physical examination was unremarkable. The complete blood count was normal except for a low hemoglobin level (12.0 g/dl; normal range 13.5–17.5). The blood glucose, serum creatinine, liver function tests, total bilirubin, albumin, and protein levels were normal, as were serum

This is an open access article under the terms of the [Creative Commons Attribution-NonCommercial-NoDerivs](https://creativecommons.org/licenses/by-nc-nd/4.0/) License, which permits use and distribution in any medium, provided the original work is properly cited, the use is non-commercial and no modifications or adaptations are made.

© 2022 The Authors. *Clinical Case Reports* published by John Wiley & Sons Ltd.



**FIGURE 1** Crusted skin lesions on the back of hands due to excess porphyrin in the skin resulting in photosensitivity

magnesium and phosphorus levels, thyroid-stimulating hormone, vitamin B12, and folic acid levels. Blood ethanol level was  $<10$  mg/dl. The urine toxicology screen was negative.

The patient was admitted to the inpatient psychiatric unit with a clinical diagnosis of bipolar type of schizoaffective disorder. He was treated with haloperidol, olanzapine, divalproex sodium, lorazepam, fluoxetine, and diphenhydramine. However, his clinical condition did not improve and even worsened. The patient became tachycardic, and his symptoms progressively worsened to hyperactive delirium. The temperature was  $37.5^{\circ}\text{C}$ ; the heart rate was 150 beats per minute; the blood pressure was 166/91 mmHg; and the oxygen saturation was 95% while the patient was on oxygen at 2 liters per minute rate. The patient was severely agitated, profusely sweating, and unable to be redirected. Physical examination was unchanged, except for increased heart rate and irregular heart rhythm. An electrocardiogram showed atrial fibrillation with a rapid ventricular response and a heart rate of 123 beats per minute.

He was initially transferred to the general medicine floor for further workup and management of his hyperactive delirium and new-onset atrial fibrillation. His antipsychotic medications were continued, and amiodarone was started for atrial fibrillation. Computed tomography (CT) of the head without contrast was unremarkable for acute intracranial pathology and revealed chronic microangiopathic ischemic white matter changes. His heart rate was controlled with amiodarone; however, he became

more aggressive and violent, requiring four-point physical restraints. He was transferred to the medical intensive care unit for intravenous dexmedetomidine infusion for his hyperactive delirium. He continued to be agitated and hallucinating at the times when dexmedetomidine infusion was held. He had a high-grade fever of  $39.1^{\circ}\text{C}$ , leukocytosis of 18,700 per cubic millimeter, and an aspartate transaminase level of 42 IU/L. He also developed suppurative superficial thrombophlebitis and blistering skin lesions on dorsal bilateral upper extremities.

Infectious workup was negative, including urinalysis, chest X-ray, cerebrospinal fluid (CSF) analysis, urine, blood, sputum, and CSF cultures. Cerebrospinal fluid tests for Cytomegalovirus, West Nile virus, Herpes simplex viruses (HSV-1 and HSV-2), and John Cunningham virus were negative. The human immunodeficiency virus and hepatitis panel were also negative. Magnetic resonance imaging of the brain without contrast showed mild chronic microvascular changes in both cerebral hemispheres, mild parenchymal cerebral volume loss, and additional disproportionate atrophy of the left medial temporal region. An electroencephalogram showed diffuse slowing of the background at the theta range with superimposed theta and delta activity bilaterally without epileptiform discharges. Intravenous antibiotics were started for suspected sepsis of an unknown source, followed by oral trimethoprim-sulfamethoxazole, as the patient later developed suppurative thrombophlebitis. After initiating the treatment with trimethoprim-sulfamethoxazole, his collected urine sample turned brown color. On further questioning, his wife reported that the patient intermittently had skin lesions on his dorsal hands for the last few years and the patient's father also had a similar rash at an older age. His chronic cutaneous findings and newly developing acute blistering skin lesions along with acute neuropsychiatric symptoms led us to consider the rare causes of delirium, such as acute porphyria. Additionally, a family history of similar skin lesions, clinical deterioration, and brown discoloration of urine after administering porphyrinogenic medications highly suggested the diagnosis of acute porphyria.

According to American Porphyria Foundation, the first-line screening test is a measurement of urinary porphobilinogen (PBG) in patients suspected of acute porphyria. Technical issues are common in sample collection and storage as each specimen needs to be protected from light during collection and delivery. Even a negative screening test with urinary PBG does not exclude the diagnosis. In our case, his urine specimen needed to be resent after two days due to affected samples by exposure to light.

His spot urine PBG was normal (1.9 mg/L; normal range 0.0–2.0 mg/L). Spot urine delta-aminolevulinic acid (ALA Delta) was normal. Urine porphyrin fractionation

revealed elevated coproporphyrin (CP) I (163  $\mu\text{g/L}$ ; normal range 0–15  $\mu\text{g/L}$ ) and coproporphyrin (CP) III (778 micrograms per liter; normal range 0–49  $\mu\text{g/L}$ ). 24-h stool porphyrin fractions panel was significant for elevated coproporphyrin III: coproporphyrin I (CIII: CI) ratio (2.94; normal range <1.20).

His porphyrinogenic medications, including phenobarbital, valproic acid, trimethoprim-sulfamethoxazole, and amiodarone, were discontinued according to the porphyria foundation drug database, and glucose infusions were administered. Amiodarone was switched to sotalol for the treatment of atrial fibrillation as sotalol is determined as very likely to be safe for prolonged use by individuals with acute porphyria, based on consistent evidence provided by the American Porphyria Foundation drug database. His adjusted medications included sotalol and apixaban for atrial fibrillation, cyanocobalamin for vitamin B12 deficiency, and pantoprazole for stress ulcer prophylaxis. His room was changed with curtains drawn to protect him from sunlight. Several days later, his acute psychiatric symptoms were entirely resolved, the patient did not require restraints anymore, and his skin lesions improved.

He has not had a urine sample test positive for porphobilinogen. However, his urine has shown significantly elevated levels of coproporphyrin, and stool was positive for elevated coproporphyrin III: coproporphyrin I ratio, which supports the diagnosis of HCP. There are several

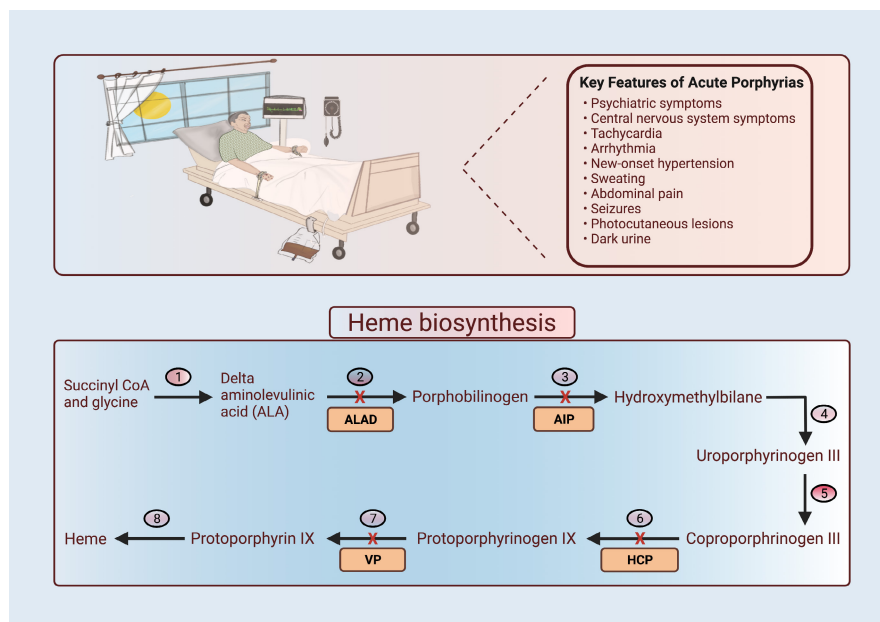
reported cases of hereditary coproporphyria with normal urine PBG levels.

After his recovery, he was discharged and instructed to avoid sun exposure and porphyrinogenic medications and wear a wrist bracelet to warn others that the patient has porphyria. Genetic testing for porphyria was advised, and outpatient follow-up with a hematologist has been arranged for administering Hemin prophylaxis or Givosiran if he has recurring acute attacks. After the discharge, he had two further episodes, short-lived and treated with IV Hemin.

### 3 | DISCUSSION

The porphyrias comprise a set of diseases, each representing an individual defect in one of the eight enzymes mediating the pathway of heme synthesis.<sup>1</sup> The diseases are genetically distinct but have in common the overproduction of heme precursors.<sup>1</sup> Defects in the four enzymes in heme biosynthesis (steps 2, 3, 6, and 7; Figure 2) can be defined as “acute porphyria.”

In all four acute porphyrias, the respective enzyme deficiency predisposes patients to certain triggering factors that lead to abnormally high accumulations of the neurotoxic porphyrin precursors, ALA and PBG, which can precipitate an acute neurovisceral attack. These include certain drugs, stress, fasting, alcohol use, smoking, and



**FIGURE 2** Pathway of heme biosynthesis. The eight steps of heme synthesis are shown below, and each number represents the enzyme that catalyzes each step. Defects in steps 2, 3, 6, and 7 cause acute porphyria; step 2 representing ALA dehydratase and its deficiency of ALA dehydratase deficiency porphyria, step 3 representing porphobilinogen deaminase and its deficiency of acute intermittent porphyria, step 6 representing coproporphyrinogen oxidase and its deficiency of hereditary coproporphyria, and step 7 representing protoporphyrinogen oxidase and its deficiency of variegate porphyria. This figure is created with BioRender.com

hormones.<sup>2,3</sup> Acute attacks typically consist of severe abdominal pain, nausea, constipation, palpitations, sweating, confusion, and other neurological manifestations such as peripheral neuropathy, seizures, paresis, tachycardia, and hypertension.<sup>4–6</sup> Psychiatric manifestations, which are present in up to 80% of acute attacks, include behavior change, agitation, depression, hallucinations, altered mental status, and acute psychosis.<sup>5</sup>

On examination, the patient may be hypertensive with tachycardia or have evidence of arrhythmias.<sup>7</sup> As porphyrias have been associated with autonomic dysfunction, it was found porphyria may be significantly associated with atrial fibrillation and atrial flutter.<sup>8</sup> Cutaneous manifestations may be found with certain types of acute porphyrias, such as VP and hereditary coproporphyria.<sup>5</sup> The skin lesions include bullous-type lesions and erosions occurring in sun-exposed areas.<sup>4,9</sup>

Initial testing includes spot urine PBG and porphyrins, and samples should be collected during an acute attack and protected from light during collection and delivery.<sup>9</sup> Once the diagnosis of acute porphyria has been made, the next step is to identify the type of acute porphyria with plasma and fecal porphyrin analysis.

Hereditary coproporphyria and variegate porphyria are due to defects in coproporphyrinogen oxidase and protoporphyrinogen oxidase, respectively, which can cause both neurovisceral symptoms and skin lesions. They are inherited as autosomal dominant traits with variable penetrance. The prevalence of HCP was estimated to be 0.2 per 100,000,<sup>10</sup> and the prevalence of VP is reported to be approximately 1.3 per 100,000.<sup>11</sup> Fecal porphyrin levels, coproporphyrin in HCP or protoporphyrin in VP, are markedly increased.<sup>12</sup> Fecal porphyrins in HCP are predominantly coproporphyrin III, whereas in VP both coproporphyrin III and protoporphyrin are both approximately equally increased.<sup>12</sup> The fecal coproporphyrin III/I ratio is sensitive for the diagnosis of HCP, even in asymptomatic stages of the disease.<sup>13</sup>

Genetic testing for mutational analysis can be used to assist in the diagnosis in an individual or to screen family members.<sup>7</sup> However, the failure to find a mutation in an individual with a diagnostic history of active acute porphyria does not exclude the diagnosis.<sup>14</sup> Genetic counseling must accompany any such testing.<sup>4</sup> Patients should be educated regarding avoidance of these trigger factors for acute attacks and the inheritable nature of the disease.

Initial management includes managing the precipitating factors such as medications, caloric deprivation, and dehydration with discontinuation of porphyrinogenic medications, glucose infusions, and hydration with intravenous normal saline. The American Porphyria

Foundation drug database provides information about the potential of drugs provoking acute porphyria attacks.

Treatment for acute porphyria is IV hemin for 3–14 days, which reverses the increase in delta-aminolevulinic acid synthase 1 (ALAS1). Givosiran, an RNA interference therapy, inhibits ALAS1 expression, and it leads to lower levels of urinary ALA and porphobilinogen, fewer days of hemin use, and better daily scores for pain than placebo.<sup>15</sup>

This patient was presented with acute psychiatric symptoms and chronic skin lesions on sun-exposed areas. He was initially misdiagnosed with schizoaffective disorder and mistreated with porphyrinogenic medications, which caused urine discoloration and worsening clinical condition. The patient later developed new-onset atrial fibrillation, which is likely secondary to acute porphyria due to autonomic dysfunction. After discontinuation of porphyrinogenic medications and administering glucose infusions, his clinical condition improved.

It is uncertain whether his normal urine PBG levels are due to delayed sampling or a variant type of hereditary coproporphyria as PBG concentrations subside rapidly after the onset of an acute attack.

## 4 | CONCLUSION

Nonspecific symptoms of acute porphyria can mimic many other diseases and lead to delayed diagnosis or misdiagnosis. Healthcare providers should be aware of the symptoms of acute porphyria in order to prevent poor outcomes and unnecessary procedures.

## AUTHOR CONTRIBUTIONS

The authors fulfill the ICMJE Criteria for Authorship and contributed equally. S.E. diagnosed the patient and wrote the case presentation. I.B. prepared the introduction and discussion of the paper.

## ACKNOWLEDGMENT

None.

## CONFLICTS OF INTEREST

The authors declare that they have no competing interests.

## DATA AVAILABILITY STATEMENT

Data sharing is not applicable to this article as no datasets were generated or analyzed during the current study.

## ETHICAL APPROVAL

None.

## CONSENT

Written informed consent was obtained from the patient's wife to publish this report in accordance with the journal's patient consent policy.

## ORCID

Seyma Eroglu  <https://orcid.org/0000-0002-9634-7708>

Ilhan Birsenogul  <https://orcid.org/0000-0002-1211-1416>

## REFERENCES

1. Bissell DM, Wang B. Acute hepatic porphyria. *J Clin Transl Hepatol*. 2015;3(1):17-26. doi:10.14218/JCTH.2014.00039
2. Anderson KE, Bloomer JR, Bonkovsky HL, et al. Recommendations for the diagnosis and treatment of the acute porphyrias. *Ann Intern Med*. 2005;142:439-450.
3. Bylesjo I, Wikberg A, Andersson C. Clinical aspects of acute intermittent porphyria in northern Sweden: a population-based study. *Scand J Clin Lab Invest*. 2009;69:612-618.
4. Balwani M, Wang B, Anderson KE, et al. Porphyrias Consortium of the Rare Diseases Clinical Research Network. Acute hepatic porphyrias: recommendations for evaluation and long-term management. *Hepatology*. 2017;66(4):1314-1322.
5. Trier H, Krishnasamy VP, Kasi PM. Clinical manifestations and diagnostic challenges in acute porphyrias. *Case Rep Hematol*. 2013;2013:628602.
6. Puy H, Gouya L, Deybach JC. *Porphyrias*. *Lancet*. 2010;375(9718):924-937.
7. Gounden V, Jialal I. Acute porphyria. In: *StatPearls* [Internet]. StatPearls Publishing; 2021. <https://www.ncbi.nlm.nih.gov/books/NBK537352/> [Updated 2021 Jul 21].
8. Dhoble A, Patel MB, Abdelmoneim SS, et al. Relation of porphyria to atrial fibrillation. *Am J Cardiol*. 2009;104(3):373-376.
9. Sandberg S, Elder GH. Diagnosing acute porphyrias. *Clin Chem*. 2004;50(5):803-805.
10. With TK. Hereditary coproporphyria and variegate porphyria in Denmark. *Dan Med Bull*. 1983;30(2):106-112.
11. Mustajoki P. Variegate porphyria. Twelve years' experience in Finland. *Q J Med*. 1980;49(194):191-203.
12. Phillips JD. Heme biosynthesis and the porphyrias. *Mol Genet Metab*. 2019;128(3):164-177. doi:10.1016/j.ymgme.2019.04.008
13. Blake D, McManus J, Cronin V, Ratnaik S. Fecal coproporphyrin isomers in hereditary coproporphyria. *Clin Chem*. 1992;38:96-100.
14. Stein PE, Badminton MN, Rees DC. Update review of the acute porphyrias. *Br J Haematol*. 2017;176(4):527-538.
15. Balwani M, Sardh E, Ventura P, et al. Phase 3 trial of RNAi therapeutic givosiran for acute intermittent porphyria. *N Engl J Med*. 2020;382:2289-2301.

**How to cite this article:** Eroglu S, Birsenogul I. Delirium with delayed diagnosis of hereditary coproporphyria. *Clin Case Rep*. 2022;10:e05937. doi:10.1002/ccr3.5937