

Macular associations of tilted disc syndrome

Vinod Kumar, Abhidnya Surve, Devesh Kumawat, Shorya Azad, Rajpal Vohra, Pradeep Venkatesh

Purpose: The aim of this study was to describe macular changes associated with tilted disc syndrome (TDS) using multimodality imaging. **Methods:** This is a retrospective observational study of the consecutive TDS cases which were studied for macular changes using color fundus photographs and optical coherence tomography (OCT). Fundus autofluorescence, fundus fluorescein angiography, and OCT angiography were performed wherever required. **Results:** Twenty consecutive TDS cases (36 eyes) were included. OCT showed inferior depression of all layers in specific scans and macular pathologies seen included lamellar macular hole, full-thickness macular hole, retinal pigment epithelial detachment, acute and resolved subretinal fluid, central serous chorioretinopathy, and choroidal neovascular membrane. Macular involvement was seen in 13 eyes (36.11%) while in the remaining 23 eyes, outer retinal changes were seen on OCT in 9 eyes and normal retinal layers in 14 eyes (38.89%). **Conclusion:** Various macular pathologies associated with TDS are described using multimodality imaging. These provide understanding of changes which can occur with TDS. It also highlights the need for recognition, differentiation from similar confusing entities, and the necessity to follow-up of these cases carefully to detect the macular changes earlier.

Key words: Choroidal neovascularisation, dome shaped macula, macular hole, optical coherence tomography, tilted disc syndrome

Tilted disc syndrome (TDS) is a constellation of fundus findings clinically seen as inferonasal tilting of the disc, inferior peripapillary crescent, nasalization of retinal vessels called situs inversus, staphyloma, asymmetric chorioretinal degeneration, and myopic astigmatism.^[1,2] Visual acuity in TDS remains unaffected unless it is complicated by macular complications. The various macular complications described in TDS include retinal pigment epithelium (RPE) atrophy, choroidal neovascular membrane (CNVM), subretinal fluid (SRF), polypoidal choroidal vasculopathy (PCV), fovea plana, foveoschisis, and lamellar macular hole (LMH).^[3-13] These macular complications are more likely to occur when upper border of the inferior staphyloma lies in the macular area.

The pathogenesis of TDS and its associated complications are not clear^[6,8]. Mechanical and hemodynamic changes in the choroid at the upper edge of staphyloma have been proposed to cause various macular complications. There has been a renewed interest in TDS as it shares clinical features and pathogenesis with another recently described entity known as dome-shaped macula (DSM). Since DSM is also associated with myopia, the two are frequently misdiagnosed.

We herein studied consecutive cases of TDS and the macular changes associated using multimodality imaging. The management of various macular pathologies and their outcome is described in the setting of TDS.

Methods

This is a retrospective observational study of consecutive TDS cases that presented to a tertiary eye care center in north

Vitreoretina, Uvea and ROP Services, Dr Rajendra Prasad Centre for Ophthalmic Sciences, AIIMS, New Delhi, India

Correspondence to: Dr. Abhidnya Surve, AIIMS, New Delhi, India. E-mail: abhidnyasurve@gmail.com

Received: 10-Jun-2020

Revision: 28-Sep-2020

Accepted: 17-Dec-2020

Published: 21-May-2021

India for 36 months (January 2017 to December 2019). The study is in accordance with the tenets of the Declaration of Helsinki and institutional guidelines for research. Written informed consent was obtained from all the patients for using their images. The diagnosis of TDS was made based on the characteristic fundus appearance. All cases underwent a complete ophthalmic examination including best-corrected visual acuity (BCVA, Snellen chart) and detailed slit lamp biomicroscopy for anterior segment and fundus examination. Retinal imaging in the form of fundus imaging and optical coherence tomography (OCT) was performed. OCT was performed either on a swept-source platform (Triton, Topcon Inc) or spectral-domain platform (Spectralis, Heidelberg Inc). Fundus fluorescein angiography (FFA) and short-wave fundus autofluorescence (FAF) were done wherever required. OCT angiography was performed on swept-source platform (Triton, Topcon Inc) wherever it was needed.

Results

Thirty-six eyes of 20 patients with TDS were included. The age group ranged from 18-66 years with a mean of 36.4 years with 14 males and 6 females. OCT showed depression/outpouching in the inferior/inferonasal area in scans going through the area of chorioretinal degenerations. The depression/outpouching was associated with thinner choroid as compared to normal area in all eyes and the change in choroidal thickness was

This is an open access journal, and articles are distributed under the terms of the Creative Commons Attribution-NonCommercial-ShareAlike 4.0 License, which allows others to remix, tweak, and build upon the work non-commercially, as long as appropriate credit is given and the new creations are licensed under the identical terms.

For reprints contact: WKHLRPMedknow_reprints@wolterskluwer.com

Cite this article as: Kumar V, Surve A, Kumawat D, Azad S, Vohra R, Venkatesh P. Macular associations of tilted disc syndrome. Indian J Ophthalmol 2021;69:1451-6.

Access this article online

Website:

www.ijo.in

DOI:

10.4103/ijo.IJO_1902_20

Quick Response Code:



prominently seen at the edge of staphyloma. The macular pathologies seen in 13 eyes (36.11%) included two eyes with central serous chorioretinopathy (CSC), three eyes with SRF, two eyes with resolved SRF, one with serous pigment epithelial detachment (PED), two with CNVM, one with LMH and two with full-thickness macular hole (FTMH). The cases are summarized further in Table 1. Of the remaining 23 eyes, OCT showed outer retinal changes at the edge of staphyloma in 9 eyes. The other 14 eyes had normal retinal layers at the edge of staphyloma.

Five eyes with TDS had presented with diminution of vision and were found to have serous detachment on OCT. While three of these did not have any leak on FFA, two eyes had typical leaks of CSC and resolved with focal laser photocoagulation with corresponding improvement in vision [Fig. 1a-f]. In one eye with CSC, the changes were at the edge of staphyloma while in other, the changes were away from the edge of staphyloma. In other three eyes, the SRF was not related to CSC.

A 30-year-old female with bilateral TDS was referred as a case of right eye (RE) myopic CNVM when she failed to respond to two injections of intravitreal Bevacizumab. She had a refractive error of -1.5DS/-2.0DC in RE and -1.25DS/-1.75DC in left eye (LE). RE OCT revealed subretinal hyper-reflective

deposit that simulated a CNVM along with SRF. While FAF showed hyperautofluorescence due to chronic SRF, FFA showed mild staining only. OCT angiography also did not show any CNVM [Fig. 2a-f]. Hence, the diagnosis was revised as TDS with chronic SRF and she underwent subthreshold micropulse laser, which led to resolution of fluid but BCVA failed to improve beyond presenting vision of 20/200. The LE was normal at baseline [Fig. 2g-i]. One year later, LE BCVA dropped to 20/30 due to development of SRF at macula [Fig. 2j]; however, no leak was seen on FFA. She was prescribed topical Dorzolamide thrice a day, which led to resolution of fluid over 4 weeks [Fig. 2k] and BCVA improved to 20/20.

Another young male with mild SRF was prescribed topical dorzolamide; however, he was lost to follow-up. Two eyes with TDS and pigmentary changes revealed mottled hyper and hypoautofluorescence at the macula which was suggestive of resolved SRF [Fig. 3a-d]. OCT in these eyes showed disrupted outer retinal layers and hyperreflective deposits over RPE [Fig. 3e-f]. One case had TDS with LMH at the edge of the localized depression [Fig. 3g]. No intervention was advised in view of good vision. PED with outer retinal abnormalities was also seen in one eye with TDS [Fig. 3h]. This patient showed a stable course over one year without any need for treatment.

Table 1: Summary of eyes with tilted disc syndrome and macular pathology

Age/sex	Eye	Visual acuity	Macular pathology	FAF/FFA/OCTA	SSOCT-other features	Management	Outcome
66/F	L	20/320	Macular hole	Hyper AF at macular hole	Macular hole	PPV with ILM peeling	Type 1 closure with final BCVA of 20/80
59/M	L	20/200	Macular hole	-	Macular Hole	PPV with ILM peeling	Type 1 closure with final BCVA of 20/60
66/M	R	20/80	Lamellar macular hole	-	Lamellar macular hole	No intervention	-
30/F	R	20/200	Chronic SRF	FAF-hyper AF area FFA-leakage	Chronic SRF	Subthreshold laser	SRF resolved but BCVA did not improve
30/F	L	20/30	SRF	-	-	Dorzolamide for 1 month	SRF resolved in one month and BCVA improved to 20/20
61/M	L	20/400	CNVM	-	Type 1 CNVM with SRF	2 doses of intravitreal bevacizumab	SRF resolved but no change in BCVA
34/F	R	20/1200	CNVM	-	Type 2 CNVM scar	Nil	-
36/M	L	20/120	Chronic CSC	FAF-Hyper AF at the temporal area with tract formation s/o chronic CSC FFA/ICG shows ink blot appearance	PED with Subretinal fibrin; Thin choroid with areas large choroidal vessels dilatation	Topical dorzolamide+Focal laser	Resolution of fluid with mild improvement of vision to 20/80
42/F	L	20/50	CSC	FFA-leak present FAF-hypo AF with hyper AF margin	PED, SRF (not at the edge of staphyloma)	Focal laser	Resolution of fluid and improvement in vision to 20/30
28/M	R	20/30	PED	-	-	Observation	No changes observed
30/M	L	20/50	SRF	-	-	Dorzolamide, lost to follow up	-
50/M	R	20/50	Resolved SRF	FAF-mottled AF at the slope of staphyloma	SRF	Observation	No changes observed
50/M	L	20/30	Resolved SRF	FAF-mottled AF at the slope of staphyloma	SRF	observation	No changes observed

M: male; F: Female; R: right; L: left; Y: Yes; TDS: Tilted Disc Syndrome; SRF: Subretinal Fluid; CSC: central serous chorioretinopathy; CNVM: Choroidal neovascular membrane; PED: Pigment epithelium detachment; FAF: Fundus autofluorescent; FFA: Fundus fluorescein angiography; ICG: Indocyanine green angiography; SSOCT: Swept source Optical coherence tomography; PPV: Pars plana vitrectomy; ILM: Internal limiting membrane

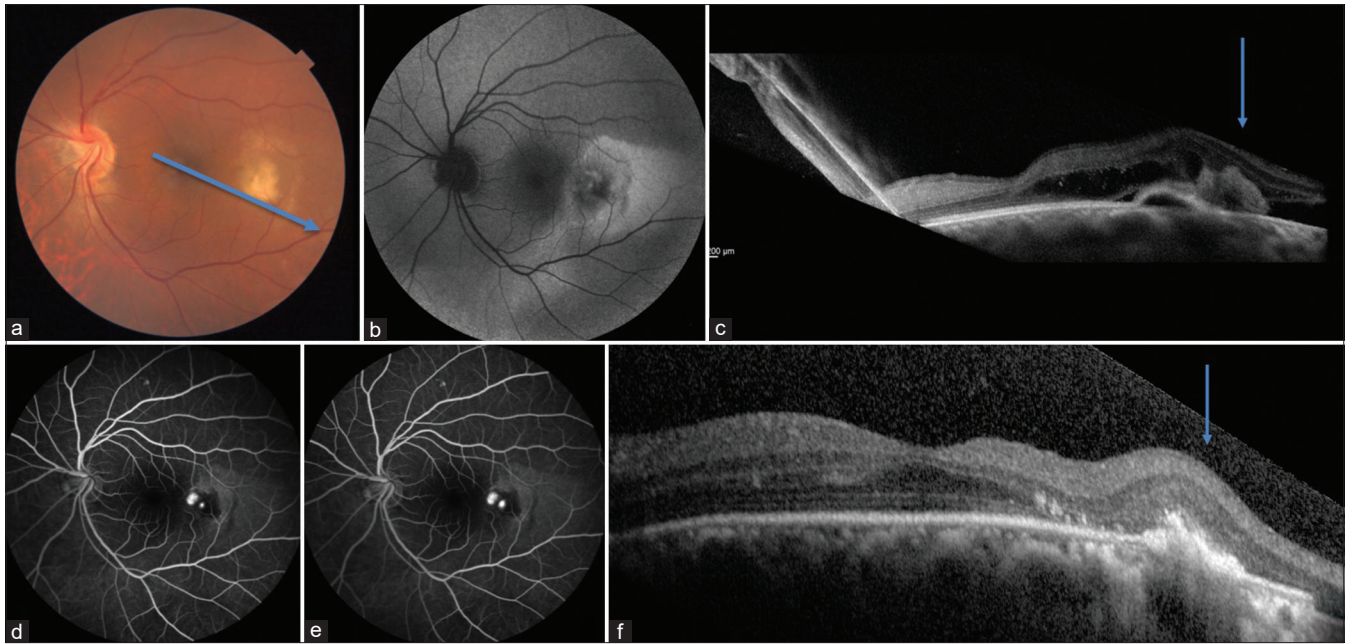


Figure 1: Color fundus image (a) shows tilted disc syndrome with chronic central serous chorioretinopathy and temporal subretinal fibrin that is seen as hypofluorescent on fundus autofluorescence. (b) Optical coherence tomography (OCT-c) showed inferior steepening (blue arrow) with subretinal fluid, intraretinal fluid and subretinal fibrin with dilated choroidal vessels beneath and fundus fluorescein angiography (FFA-d, e) showed leakage in inferotemporal area. After focal laser, resolution of intraretinal and subretinal fluid was noted at 4-weeks follow-up (f)

Another 66-old-female had TDS and FTMH with a minimum base diameter of 621 microns at the edge of the staphyloma. Hyperautofluorescent area at the macular hole was seen on FAF [Fig. 4a-c]. On examination, BCVA was 20/320 in involved eye. She underwent 25-Gauge pars-plana vitrectomy with internal limiting membrane peeling and 20% sulfur hexafluoride (SF6) gas tamponade. Three months after surgery, she gained a vision of 20/80. The macular hole had closed clinically and on OCT. Similarly, type I closure was seen in another case of TDS with FTMH after surgery [Fig. 4d, e].

Two eyes with TDS were associated with CNVM. While one of these presented with diminution of vision and active CNVM, the other was associated with scarred CNVM. OCT angiography confirmed the diagnosis of type 1 CNVM in first patient and showed vascularized membrane in outer retinal layer and choriocapillaris [Fig. 5a-c]. This patient received 2 injections of intravitreal Bevacizumab with no improvement in visual acuity. Second eye with CNVM did not require treatment, as CNVM was inactive and scarred [Fig. 5d-e].

Thus, macular changes were seen in 13 eyes (36.11%) with all except one occurring at the upper edge of the staphyloma. The remaining 23 eyes had no gross macular pathology but outer retinal layer changes especially the Ellipsoid zone abnormalities were noted at the edge of staphyloma in 9 eyes while the other 14 eyes (38.89%) did not show any retinal layer changes. However visual acuity was not affected in any of these eyes.

Discussion

TDS is an under-recognized congenital abnormality of the optic disc with a reported prevalence of 1-2% in general population.^[14] Macular complications are usually noted in the fourth to fifth decade. However, the exact pathophysiology

underlying TDS and its associated complications is unclear. Abnormality in closure of embryonic fissure, abnormal development of the RPE affecting the development of choroid and sclera, local degenerative changes in retina and choroid due to their acute bending, ischemic changes at the edge, and vitreoretinal abnormality at the inner retinal layers are the various factors proposed.^[2,6,8,15,16] The response of macular conditions to treatment also tends to be varied in TDS.^[16-19]

Since TDS is usually associated with moderate grade myopia and myopic astigmatism, it is easily confused with high/pathological myopia. As compared to TDS, myopic fundus shows temporal crescent with depigmentation of complete fundus and ectasia involving the posterior pole and peripapillary area.^[1,2] Type five - inferior staphyloma, according to original description by Curtin is sparsely detailed in literature and may be easily confused with TDS if other findings of TDS are not considered.^[20]

DSM is another progressive anomaly seen in myopic eyes; which may be easily confused with TDS. It involves convex bulge at the macula area within an area of posterior staphyloma and may be associated with RPE atrophy, CNVM, serous retinal detachment, irregular PED, and subretinal pigmentary clumps as are seen in TDS.^[1,21] In fact, some of the cases reported in the first series on DSM showed features of TDS.^[22,23] As both DSM and TDS can have different orientation, multiple radial OCT scans are required to make a tomographic diagnosis. While in DSM there is an inward elevation of macula seen on OCT as compared to the contour of the eye wall, TDS shows depression/outpouching in the eye wall corresponding to the area of inferonasal staphyloma. Differences in the choroidal thickness are also seen in both the conditions. While choroidal thickening is more commonly seen in the area of DSM, TDS cases show thinning of the choroid prominent in the area of

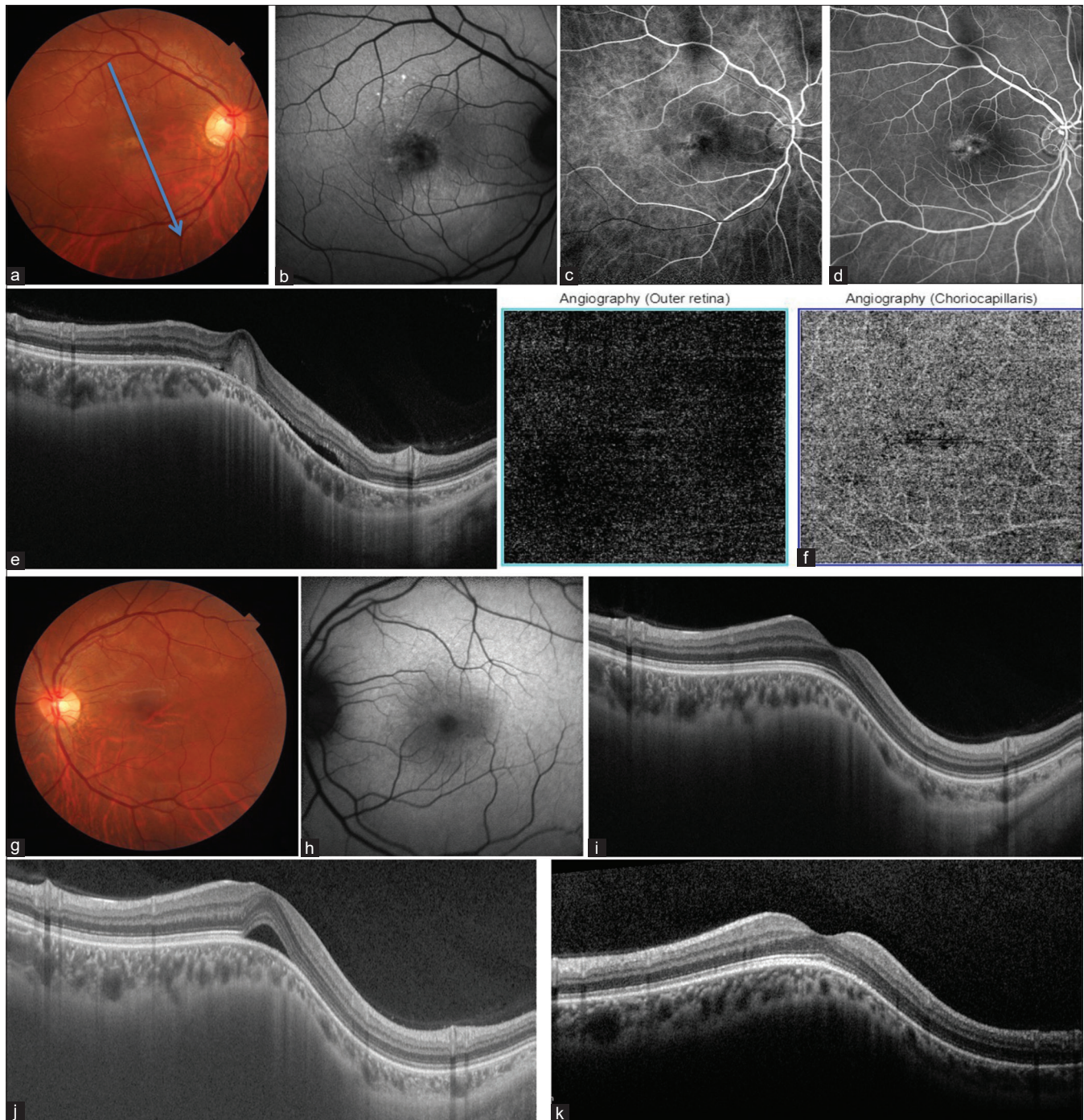


Figure 2: Color image of 30-year-old-female (a, g) showing features of TDS and FFA (b, h) showing hyperautofluorescent area inferior to fovea resulting from chronic SRF. RE FFA (c, d) showed mild staining inferonasal to fovea. OCT (e, i) vertical scan showed inferior steepening with underlying choroidal thinning. RE also had intra/subretinal hyper-reflective lesion similar to CNVM (e) at the edge of the steepening but OCTA (f) revealed no CNVM. LE was normal at baseline (g-i) LE OCT showed subretinal fluid on follow-up (j) which resolved after one-month of dorzolamide treatment (k)

inferonasal staphyloma as seen in all our cases [Figs. 1-5]. This sudden change in choroidal thickness can lead to hemodynamic changes at the edge, which may lead to various macular changes seen in both TDS and DSM. The changes in choroidal thickness in DSM have been ascribed to localized variations in scleral thickness.^[24,25] In our series, however, we could not appreciate any changes in scleral thickness despite using

swept-source OCT in several eyes. This signifies that choroidal thickness changes in TDS are as a result of change in the contour of layers rather than scleral thickness changes.

Modern-day OCT machines provide longer scans and depth is also better resolved. The longer scans are especially useful if upper edge of inferior staphyloma is away from the fovea, in which case smaller OCT scans can easily miss the changes

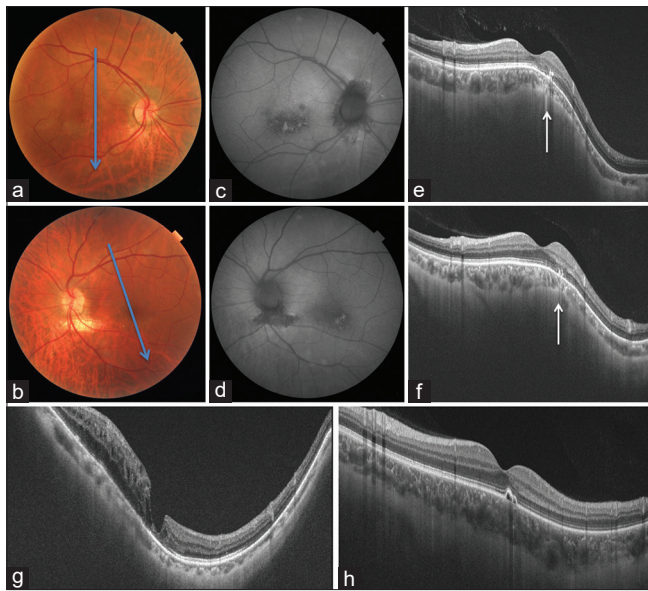


Figure 3: Color fundus image and FAF of a patient with bilateral TDS showing clinical features of TDS (a, b) and shows mottled AF suggestive of resolved subretinal fluid (c, d). OCT (e-h) showed inferior steepening with choroidal thinning and outer retinal changes at the edge of steepening. Lamellar macular hole (g) and pigment epithelial detachment (PED) (h) at edge of steepening in other eyes

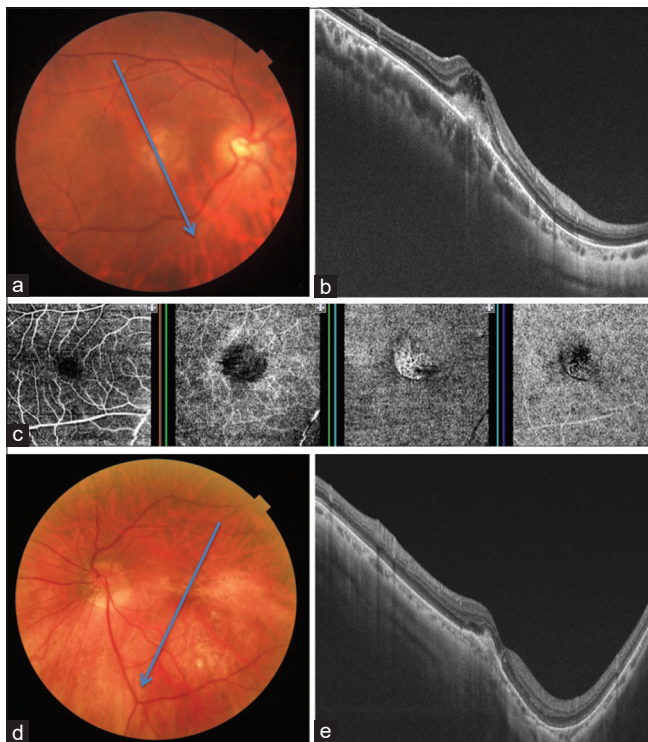


Figure 5: Color fundus image (a, d) showing features suggestive of tilted disc syndrome (TDS) with choroidal neovascular membrane (CNVM-a). Optical coherence tomography (OCT-b, e) vertical scan OU showed inferior steepening with underlying choroidal thinning, and CNVM at the edge of steepening. Associated overlying retinal edema and break in the retinal pigment epithelium is also seen on OCT (b). The OCT angiography (c) shows neovascularisation in outer retinal and choriocapillaris layer corresponding to CNVM. Another eye with TDS showing inactive healed CNVM (d and e)

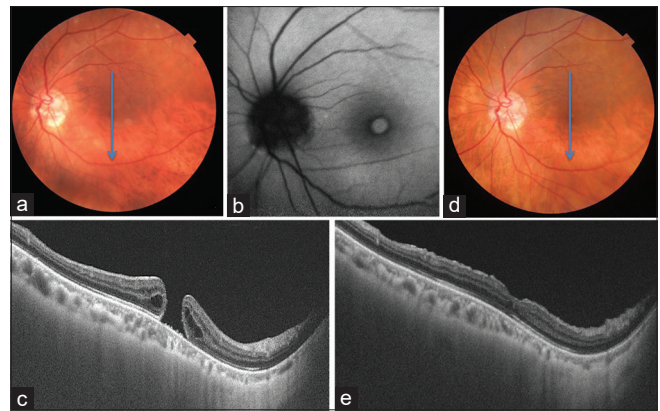


Figure 4: Colour imaging (a) showing tilted disc syndrome (TDS) with macular hole (MH) which appears hyperautofluorescent on fundus autofluorescent (b). Optical coherence tomography (OCT-c) vertical scan shows the inferior localized steepening with thinning of choroid underneath with full-thickness MH at the beginning of steepening. Post-operative fundus image (d) and OCT vertical scan (e) showed type 1 anatomical closure of macular hole

in the contour of eyeball. The edge of the ectasia in relation to fovea can be above, at or below the level of fovea. In our series, 92.31% cases of TDS with macular pathologies had changes at the upper edge of staphyloma. Thus, the TDS cases having upper edge of staphyloma near the fovea are more likely to develop macular complications. This allows us to determine the cases which need regular follow-up. Another novel OCT feature noted in this series was attenuated Ellipsoid zone at the slope of depression. It is difficult to determine if this abnormality is actual or just an artifact because of the change in the angle of incident light on the slope of depression. However, these were more prominent in those eyes with macular pathologies. Thus, acute bending leading to changes in the choroid as well as retina may be the predisposing factor for macular pathologies in TDS.

Macular conditions seen in our study included SRF, PED, CSC, CNVM, and macular hole. The changes in the outer retinal layers along with defect in the RPE or Bruch’s layers may be the cause for the CNVM. However, as documented in prior case reports, poor response to intravitreal anti-vascular endothelial growth factor (VEGF) was observed in our series as well.^[16] The patients with SRF in TDS may be misdiagnosed as CSC. The SRF in TDS, similar to that in DSM, is poorly responsive to treatment and tends to fluctuate over a period of time. In our study, the recently developed SRF subsided within four weeks in one eye when Dorzolamide was prescribed. This indicates the importance of detecting the changes early and the role of RPE function in resolution of SRF, which may be relatively better in patients with recent-onset SRFs. The macular hole achieved closure with vitrectomy, internal limiting membrane (ILM) peeling, and gas tamponade with moderate visual gain. This signifies that pathogenesis of macular hole in TDS may be similar to that of idiopathic macular holes and may be an incidental finding in the setting of TDS. However, the tangential vitreous traction, ILM stiffness, and chorioretinal atrophy within the ectatic area are additional factors which could play a contributing role and also affect the surgical outcome.

The study has some drawbacks. These include a small number of cases and the retrospective nature of the study.

Though the treatment and prognosis of these cases are described, they are studied over a short period of time.

Conclusion

To conclude, this study describes macular associations of TDS using multimodal imaging and highlights the need for recognition of this entity as it is easily confused with myopia and DSM. It also suggests the necessity to follow-up these cases carefully to detect the macular changes earlier.

Declaration of patient consent

The authors certify that they have obtained all appropriate patient consent forms. In the form the patient (s) has/have given his/her/their consent for his/her/their images and other clinical information to be reported in the journal. The patients understand that their names and initials will not be published and due efforts will be made to conceal their identity, but anonymity cannot be guaranteed.

Financial support and sponsorship

Nil.

Conflicts of interest

There are no conflicts of interest.

References

- Young SE, Walsh FB, Knox DL. The tilted disk syndrome. *Am J Ophthalmol* 1976;82:16–23.
- Dorrell D. The tilted disc. *Br J Ophthalmol* 1978;62:16–20.
- Giuffrè G. Chorioretinal degenerative changes in the tilted disc syndrome. *Int Ophthalmol* 1991;15:1–7.
- Prost M, De Laey JJ. Choroidal neovascularization in tilted disc syndrome. *Int Ophthalmol* 1988;12:131–5.
- Stur M. Congenital tilted disc syndrome associated with parafoveal subretinal neovascularization. *Am J Ophthalmol* 1988;105:98–9.
- Nakanishi H, Tsujikawa A, Gotoh N, Hayashi H, Iwama D, Tamura H, *et al.* Macular complications on the border of an inferior staphyloma associated with tilted disc syndrome. *Retina* 2008;28:1493–501.
- Cohen SY, Quentel G, Guiberteau B, Delahaye-Mazza C, Gaudric A, *et al.* Macular serous retinal detachment caused by subretinal leakage in tilted disc syndrome. *Ophthalmology* 1998;105:1831–4.
- Tsuboi S, Uchihori Y, Manabe R. Subretinal neovascularisation in eyes with localised inferior posterior staphylomas. *Br J Ophthalmol* 1984;68:869–72.
- Mauget-Fayssse M, Cornut PL, Quaranta El-Maftouhi M, Leys A. Polypoidal choroidal vasculopathy in tilted disc syndrome and high myopia with staphyloma. *Am J Ophthalmol* 2006;142:970–5.
- Peiretti E, Iranmanesh R, Yannuzzi LA, Fossarello M. Polypoidal choroidal vasculopathy associated with tilted disc syndrome. *Retin Cases Brief Rep* 2008;2:31–3.
- Cohen SY, Dubois L, Ayrault S, Quentel G. T-shaped pigmentary changes in tilted disc syndrome. *Eur J Ophthalmol* 2009;19:876–9.
- Tosti G. Serous macular detachment and tilted disc syndrome. *Ophthalmology* 1999;106:1453–5.
- Cohen SY, Dubois L, Nghiem-Buffer S, Fajnkuchen F, Delahaye-Mazza C, Quentel G, *et al.* Spectral domain optical coherence tomography analysis of macular changes in tilted disc syndrome. *Retina* 2013;33:1338–45.
- Vongphanit J, Mitchell P, Wang JJ. Population prevalence of tilted optic disks and the relationship of this sign to refractive error. *Am J Ophthalmol* 2002;133:679–85.
- Maruko I, Iida T, Sugano Y, Oyama H, Sekiryu T. Morphologic choroidal and scleral changes at the macula in tilted disc syndrome with staphyloma using optical coherence tomography. *Invest Ophthalmol Vis Sci* 2011;52:8763–8.
- Milani P, Pece A, Moretti G, Lino P, Scialdone A. Intravitreal bevacizumab for CNV-complicated tilted disc syndrome. *Graefes Arch Clin Exp Ophthalmol* 2009;247:1179–82.
- Leys AM, Cohen SY. Subretinal leakage in myopic eyes with a posterior staphyloma or tilted disc syndrome. *Retina (Philadelphia, Pa)* 2002;22:659–65.
- Arias L, Monés J. Ranibizumab in the treatment of choroidal neovascularization on the border of an inferior staphyloma associated with tilted disc syndrome. *Clin Ophthalmol* 2010;4:227–31.
- Donati MC, Miele A, Abbruzzese G, Giuntoli M, Giansanti F, Menchini U. Treatment of macular serous neuroretinal detachment in tilted disc syndrome: Report of 3 cases. *Eur J Ophthalmol* 2013;23:267–70.
- Curtin BJ. The posterior staphyloma of pathologic myopia. *Trans Am Ophthalmol Soc* 1977;75:67–86.
- Soudier G, Gaudric A, Gualino V, Massin P, Nardin M, Tadayoni R, *et al.* Long-term evolution of dome-shaped macula: Increased macular bulge is associated with extended macular atrophy. *Retina* 2016;36:944–52.
- Gaucher D, Erginay A, Lecleire-Collet A, Haouchine B, Puech M, Cohen SY, *et al.* Dome-shaped macula in eyes with myopic posterior staphyloma. *Am J Ophthalmol* 2008;145:909–14.
- Byeon SH, Chu YK. Dome-shaped macula. *Am J Ophthalmol* 2011;151:1101.
- Imamura Y, Iida T, Maruko I, Zweifel SA, Spaide RF. Enhanced depth imaging optical coherence tomography of the sclera in dome-shaped macula. *Am J Ophthalmol* 2011;151:297–302.
- Ellabban AA, Tsujikawa A, Matsumoto A, Yamashiro K, Oishi A, Ooto S, *et al.* Three-dimensional tomographic features of dome-shaped macula by swept-source optical coherence tomography. *Am J Ophthalmol* 2013;155:320–8.e2.