

Technology Development Program (No. 10048898) funded by the Ministry of Trade, Industry & Energy (Korea).

## CONFLICTS OF INTEREST

The authors have nothing to disclose.

## REFERENCES

1. Cui HS, Ahn IS, Byun YS, Yang YS, Kim JH, Chung BY, et al. Dietary pattern and nutrient intake of Korean children with atopic dermatitis. *Ann Dermatol* 2014;26:570-575.
2. Schmitt J, von Kobyletzki L, Svensson A, Apfelbacher C. Efficacy and tolerability of proactive treatment with topical corticosteroids and calcineurin inhibitors for atopic eczema: systematic review and meta-analysis of randomized controlled trials. *Br J Dermatol* 2011;164:415-428.
3. von Kobyletzki G, Pieck C, Hoffmann K, Freitag M, Altmeyer P. Medium-dose UVA1 cold-light phototherapy in the treatment of severe atopic dermatitis. *J Am Acad Dermatol* 1999;41:931-937.
4. Gambichler T, Othlinghaus N, Tomi NS, Holland-Letz T, Boms S, Skrygan M, et al. Medium-dose ultraviolet (UV) A1 vs. narrowband UVB phototherapy in atopic eczema: a randomized crossover study. *Br J Dermatol* 2009;160:652-658.
5. Pavlovsky M, Baum S, Shpiro D, Pavlovsky L, Pavlotsky F. Narrow band UVB: is it effective and safe for paediatric psoriasis and atopic dermatitis? *J Eur Acad Dermatol Venereol* 2011;25:727-729.
6. Barolet D. Light-emitting diodes (LEDs) in dermatology. *Semin Cutan Med Surg* 2008;27:227-238.
7. Yeh NG, Wu CH, Cheng TC. Light-emitting diodes-Their potential in biomedical applications. *Renew Sustain Energy Rev* 2010;14:2161-2166.
8. Morita H, Kohno J, Tanaka S, Kitano Y, Sagami S. Clinical application of GaAlAs 830 nm diode laser for atopic dermatitis. *Laser Ther* 1993;5:75-78.
9. Cheong KA, Kim CH, Choi Y, Park CD, Lee AY. Irradiation of light emitting diode at 850nm inhibits T cell-induced cytokine expression. *J Dermatol Sci* 2012;65:27-37.
10. Jung KE, Lee YJ, Ryu YH, Kim JE, Kim HS, Kim BJ, et al. Effects of topically applied rapamycin and mycophenolic acid on TNFB-induced atopic dermatitis-like skin lesions in NC/Nga mice. *Int Immunopharmacol* 2015;26:432-438.

<https://doi.org/10.5021/ad.2017.29.6.799>



# Seven Cases of Senile Gluteal Dermatoses Developed with Ulcer

Min-Jae Gwak, Mu-Hyoung Lee, Min Kyung Shin

*Department of Dermatology, College of Medicine, Kyung Hee University, Seoul, Korea*

Dear Editor:

Senile gluteal dermatoses (SGD) is the hyperkeratotic lichenified skin lesions around of the gluteal cleft which

was first reported in Japan<sup>1</sup>. Distinctive skin lesions of SGD are brownish scaly plaques on the gluteal cleft and both sides of the buttocks assuming a pattern of "three cor-

Received June 30, 2016, Revised October 13, 2016, Accepted for publication October 28, 2016

**Corresponding author:** Min Kyung Shin, Department of Dermatology, Kyung Hee University Medical Center, 23 Kyungheedaero, Dongdaemun-gu, Seoul 02447, Korea. Tel: 82-2-958-8511, Fax: 82-2-969-6538, E-mail: haddal@hanmail.net

This is an Open Access article distributed under the terms of the Creative Commons Attribution Non-Commercial License (<http://creativecommons.org/licenses/by-nc/4.0>) which permits unrestricted non-commercial use, distribution, and reproduction in any medium, provided the original work is properly cited.

Copyright © The Korean Dermatological Association and The Korean Society for Investigative Dermatology

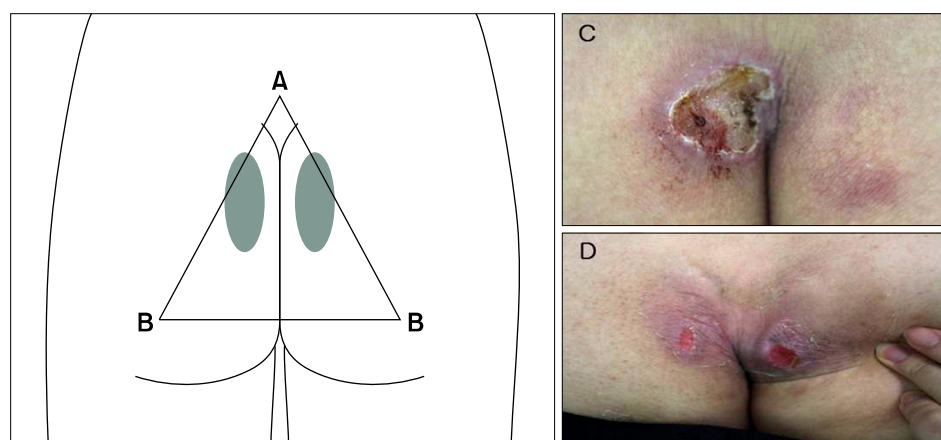
ners of triangle" (Fig. 1). The prevalence is not known but it is thought to be common in Asia, relatively rare in the West countries<sup>2,3</sup>. The etiology is not known exactly, but old age, low body weight, prolonged sitting position, friction, and pressure are known to be related<sup>4</sup>. And the association between systemic diseases and SGD is thought to be not relevant yet.

We retrospectively collected the patients of SGD with ulcers (Table 1) from 2010 to 2014. The mean age of seven patients was 73.3 years (range, 67~87 years), and male/female ratio is 0.4 (2/5), and mean body mass index was 22.4. Duration of SGD was various from 2 weeks to 10 years. All ulcer lesions of SGD were negative for culture of bacteria and fungi. Skin biopsies were performed in three patients around the ulcer lesion and revealed epidermal hyperkeratosis, follicular plugging, and papillary dermal vascular dilatation. The treatments of these skin lesions were daily simple dressing with topical antibiotics. Duration of these treatments was various from 2 weeks to 6 weeks and the ulcers of all cases were recovered completely.

Ulcers in SGD on the cleft of the buttock should be differentiated from other several ulcer-developing dermatologic

conditions as like herpes simplex, lichen simplex chronicus, pilonidal sinus etc. Among them, the differentiation with pressure ulcer is most important. Pressure ulcer has tendency to happen the skin area of bony prominence, especially in the status of prolonged immobilization. In buttock area, pressure ulcers are prone to occur in skin area on the sacrum, ischial tuberosity, and femoral trochanter<sup>5</sup>. But in SGD, ulcers are developed in lower position of gluteal cleft than pressure sore which happen due to force abrasively folded inward in both buttocks (Fig. 1). In the pressure ulcer, the most important etiologic factor is pressure. SGD patients developed with ulcer were all ambulatory unlike the pressure sore. And ulcers in SGD were observed in locations that force both gluteal regions to evert. Therefore, ulcers developed in SGD are more feasible to generate due to friction force chafed against both gluteal region and moisture covered up tightly.

In pressure ulcer, damage caused by pressure and shear force occurs in deeper tissue, in which the cutaneous injuries may be only the "tip of the iceberg" of the deeper lesion, more extensive damage. But, ulcers in SGD are thought to be affected by friction and produced by superficial injury. Duration of ulcer with SGD was relatively



**Fig. 1.** Senile gluteal dermatosis with ulcer (C: Patient no. 2, D: Patient no. 5). The predilection sites of ulcer with senile gluteal dermatoses (dark circles) and 'three corners of triangle' (triangle A: coccyx, B: ischial tuberosity).

**Table 1.** Clinical manifestations in seven patients of SGD with ulcers

Patient no.	Age (yr)	Sex	Symptom	Underlying systemic disease	Duration		Biopsy	Duration of treatment (wk)
					SGD (yr)	Ulcer (wk)		
1	67	F	Tenderness	HTN, RA	10	4	O	3
2	69	F	Pain	DM	Unknown	2	-	4
3	69	M	Tenderness	HTN, DM, LC	2	3	-	4
4	72	M	Pain	-	Unknown	2	-	3
5	74	F	Itching	CVA, HTN, DM	Unknown	4	O	2
6	87	F	Pain	CKD, CHF	Unknown	5	-	6
7	75	F	Pain	HTN, DM	1	Unknown	O	3

SGD: senile gluteal dermatoses, M: male, F: female, HTN: hypertension, RA: rheumatoid arthritis, DM: diabetes mellitus, LC: liver cirrhosis, CVA: cerebrovascular accident, CKD: chronic kidney disease, CHF: congestive heart failure, -: none.

shorter than pressure ulcer and all ulcers with SGD patients were healed completely. As elderly people gradually increase worldwide, it is important that these ulcers should be recognized in SGD patients and distinguished from pressure ulcer.

In conclusion, the ulcers developed with SGD are thought to be produced by mainly friction more than pressure force in elderly peoples, and their locations different from that of pressure ulcers. And it is important to notice that these SGD ulcers have relatively shorter duration and better response of treatment than that of pressure ulcers, so it is necessary to avoid excessive treatment.

## CONFLICTS OF INTEREST

The authors have nothing to disclose.

## REFERENCES

1. Yamamoto T, Mukai H. Hyperkeratotic lichenified skin

lesion of gluteal region. *Nishinohon J Dermatol* 1979;41:798.

2. Liu HN, Wang WJ, Chen CC, Lee DD, Chang YT. Senile gluteal dermatosis-a clinicopathologic study of 12 cases and its distinction from anosacral amyloidosis. *J Eur Acad Dermatol Venereol* 2012;26:258-260.

3. Niiyama S, Sakurai S, Katsuoka K. Hyperkeratotic lichenified skin lesion of gluteal region. *J Dermatol* 2006;33:779-782.

4. Liu HN, Wang WJ, Chen CC, Lee DD, Chang YT. Senile gluteal dermatosis: a clinical study of 137 cases. *Int J Dermatol* 2014;53:51-55.

5. Powers JG, Odo L, Philips TJ. Decubitus (pressure) ulcers. In: Goldsmith LA, Katz SI, Gilchrist BA, Paller AS, Leffell DJ, Wolff K, editors. *Fitzpatrick's dermatology in general medicine*. 8th ed. New York: McGraw-Hill, 2012:1121-1129.

<https://doi.org/10.5021/ad.2017.29.6.801>



# Novel *KIT* Missense Mutation P665S in a Chinese Piebaldism Family

Yan Zheng, Fen Liu<sup>1</sup>, Yao Yang, Yanhua Liang

*Department of Dermatology, Shenzhen Hospital of Southern Medical University, Shenzhen, <sup>1</sup>Department of Histology and Embryology, Institute of Neuroscience, Wenzhou Medical University, Wenzhou, China*

Dear Editor:

Piebaldism (OMIM #172800) is a rare autosomal dominant disorder characterized by stable areas of amelanotic skin and a white forelock. Piebaldism is thought to result from defective proliferation or migration of melanocytes

from the neural crest during development<sup>1</sup>. According to the depigmented patches, piebaldism can be presented in mild, moderate and severe conditions. The mild type may only show a white forelock or smaller leukoderma on the ventral trunk and/or an extremity without a white

Received July 27, 2016, Revised October 10, 2016, Accepted for publication October 31, 2016

**Corresponding author:** Yanhua Liang, Department of Dermatology, Shenzhen Hospital of Southern Medical University, 1333 Xinhua Road, Shenzhen, Guangdong 518100, China. Tel: 86-755-23360448, Fax: 86-755-23360448, E-mail: liangdoctor@163.com

This is an Open Access article distributed under the terms of the Creative Commons Attribution Non-Commercial License (<http://creativecommons.org/licenses/by-nc/4.0>) which permits unrestricted non-commercial use, distribution, and reproduction in any medium, provided the original work is properly cited.

Copyright © The Korean Dermatological Association and The Korean Society for Investigative Dermatology