



2020

Acute Pulmonary Embolism as an Initial Presentation of Klinefelter Syndrome: A Case Report

Follow this and additional works at: <https://www.j-saudi-heart.com/jsha>



Part of the [Cardiology Commons](#)



This work is licensed under a [Creative Commons Attribution-Noncommercial-No Derivative Works 4.0 License](#).

Recommended Citation

El Ouazzani, Ghizlane; Toutai, Chaimae; Alla, Ikbal; Ismaili, Nabila; and El Ouafi, Noha (2020) "Acute Pulmonary Embolism as an Initial Presentation of Klinefelter Syndrome: A Case Report," *Journal of the Saudi Heart Association*: Vol. 32 : Iss. 1 , Article 21.

Available at: <https://doi.org/10.37616/2212-5043.1020>

This Case Report is brought to you for free and open access by Journal of the Saudi Heart Association. It has been accepted for inclusion in Journal of the Saudi Heart Association by an authorized editor of Journal of the Saudi Heart Association.

Acute pulmonary embolism as an initial presentation of Klinefelter syndrome

Ghizlane El Ouazzani*, Chaimae Toutai, Ikbal Alla, Nabila Ismaili, Noha El Ouafi

Department of Cardiology, Mohammed VI University Hospital, University Mohammed First of Oujda, 60049 Oujda, Morocco

Abstract

Venous thromboembolism (VTE) includes deep vein thrombosis and its complications and pulmonary embolism. Cancer, surgery, prolonged immobilization, fractures, paralysis, use of oral contraceptives, and hereditary coagulopathies are classic risk factors for VTE. An increased incidence of VTE has been reported in patients with Klinefelter syndrome (KS), with a reported prevalence of 0.1–0.2% in the general population and up to 3.1% in infertile men. Despite the high rate of thromboembolic disease in patients with KS, the etiology of this phenomenon is not well understood, and most of our current knowledge is limited to small sample studies. We present the case of a 56-year-old man admitted for the management of a pulmonary embolism in whom a KS was accidentally discovered.

Keywords: Klinefelter syndrome, Pulmonary embolism

1. Introduction

Klinefelter syndrome (KS) is an endocrine disorder characterized by gynecomastia, small testes, hypogonadism, and high follicle-stimulating hormone levels, usually with an XXY karyotype. The incidence of KS is approximately 1.5 per 1000 men [1]. Patients with KS appear to be at increased risk of thromboembolic events with a high prevalence of deep vein thrombosis or pulmonary embolism. Although the precise mechanisms underlying this prothrombotic state have not yet been elucidated, it is thought that the increased incidence of thromboembolism is associated with secondary hypofibrinolysis caused by androgen deficiency and the presence of chromosomal abnormalities.

2. Case report

We report the case of a 56-year-old patient with no thromboembolic risk factors, including no

history of trauma, surgery, fever, weight loss, or prolonged travel. There was no family history of venous thromboembolism (VTE). He was admitted to an emergency department for the management of dyspnea New York Heart Association (NYHA) class III. Clinical examination at admission revealed a conscious patient, blood pressure at 120/80 mmHg, SpO₂ at 76% in ambient air and 96% under oxygen, white lower limb edema up to mid-thigh with a positive Homans sign, and bilateral crackles on chest auscultation (Killip II).

Given the intermediate clinical probability of pulmonary embolism (Wells score at 6), a D-dimer test was requested, revealing high levels at 1832 µg/µL. A chest computed tomography angiography revealed a massive pulmonary embolism in the right pulmonary artery; transthoracic echocardiography showed a dilatation of the right ventricle with a systolic dysfunction (TAPSE, 13 mm; S-wave, 8 cm/s); and the troponin level was normal at 12 ng/L (normal value, <26 ng/L). The venous Doppler ultrasound of the lower extremities revealed deep vein thrombosis of the lower left limb. For this low-risk intermediate

Received 27 October 2019; revised 7 December 2019; accepted 10 December 2019.
Available online 17 April 2020

* Corresponding author at: Department of Cardiology, Mohammed VI University Hospital, University Mohammed First of Oujda, 60049 Oujda, Morocco.
E-mail address: elouazzanighizlane@gmail.com (G. El Ouazzani).



pulmonary embolism and deep vein thrombosis, the patient underwent anticoagulation therapy with low-molecular-weight heparin relayed by Sintrom (acenocoumarol) with a target international normalized ratio between 2 and 3. The congestive signs regressed well under diuretic treatment.

During a routine physical examination, the presence of a micropenis and gynecomastia with primary sterility was discovered. Endocrine studies revealed low testosterone levels, normal prolactin levels, and high levels of follicle-stimulating hormone and luteinizing hormone. Chromosome analysis revealed a karyotype of 47,XXY (Figs. 1 and 2).

Thus, the diagnosis of KS was retained, and an endocrinological follow-up was decided as well as a blood test for thrombophilia; however, the patient refused and was eventually lost to follow-up.

3. Discussion

VTE is a common vascular disease that leads to an estimated 300,000 deaths annually [2]. Its pathogenesis is multifactorial, and its two most common clinical manifestations are pulmonary embolism and deep vein thrombosis. The classic risk factors for VTE include cancer, surgery, prolonged immobilization, fracture, paralysis, oral contraceptive use,

Abbreviations

KS	Klinefelter syndrome
VTE	venous thromboembolism

and hereditary coagulopathies. The increased incidence of VTE was also reported in patients with KS [3–5]. The exact mechanism is not completely understood, but it is thought to be related to the inverse relationship between plasminogen activator inhibitor-1 (PAI-1) synthesis and testosterone levels [6]. High levels of PAI-1 produced by endothelial and adipose tissue inhibit tissue plasminogen activators, thereby reducing the cleavage of plasminogen to plasmin. Fibrinolytic mechanisms are significantly affected, which favors a prothrombotic state [7].

This state of hyperestrogenism may play a greater role than hypoandrogenism in the occurrence of thromboembolic disease in patients with KS, as estrogen may alter the levels of procoagulant and anticoagulant proteins, particularly in cases of coexistence of hereditary thrombophilia [8].

Nevertheless, the case reports available in the medical literature on KS and thrombosis show associated, acquired, or genetic thrombophilic

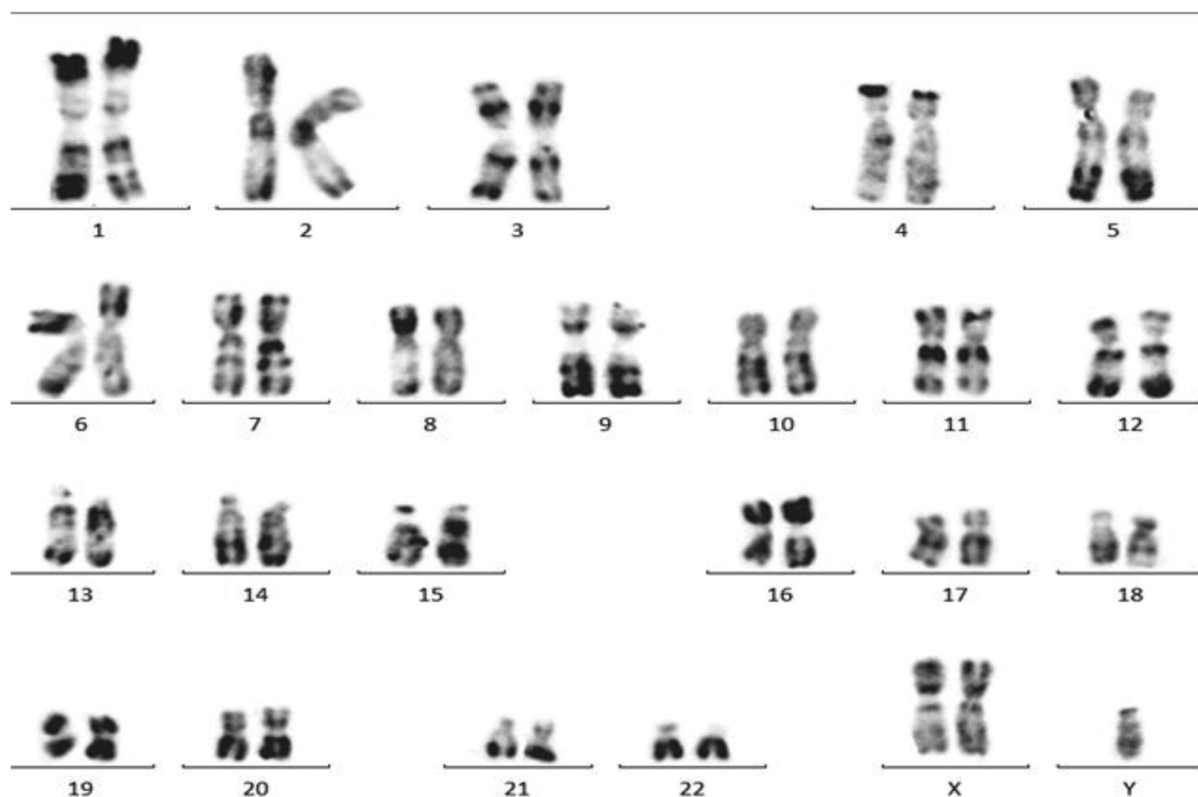


Fig. 1. Chromosomal study: 47,XXY.

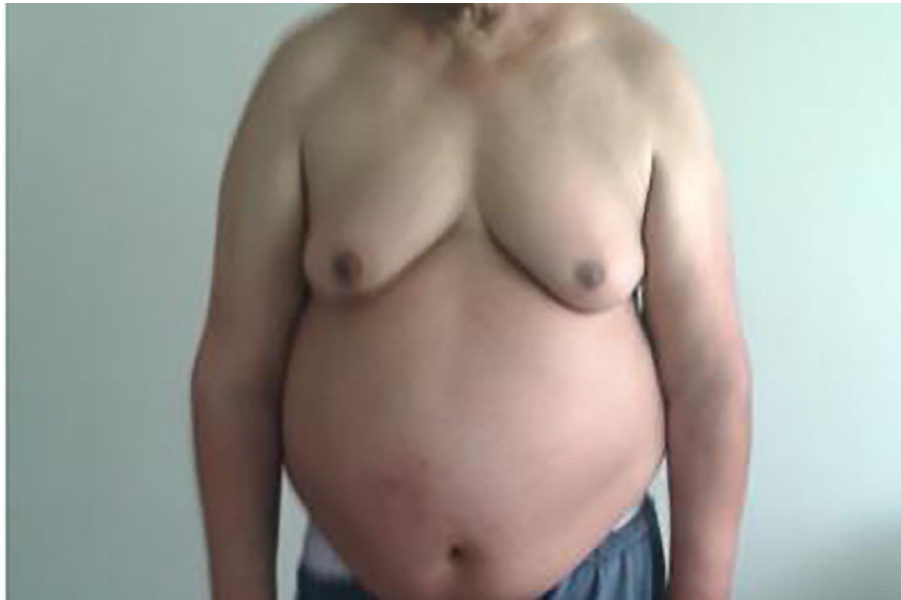

Fig. 2. Gynecomastia in a patient with Klinefelter syndrome.

status, particularly the antiphospholipid antibody syndrome [3,9]; a heterozygous state for factor V Leiden mutation 1691G>A [10]; compound heterozygosity for factor V Leiden 1691G>A and prothrombin 20210G>A mutations [8,11]; increased factor VIII coagulant activity (factor VIII: C) [12]; and homozygous MTHFR 1298A>C mutations [13].

Other hypotheses describe the pathogenesis of thromboembolism in patients with KS, namely, vascular abnormalities [14–17], protein C and S deficiency [18–24], high homocysteine levels [13], and antithrombin III deficiency [14].

It was noted that KS could also be considered to be a cause of recurrent VTE. In this case, oral anti-coagulant therapy for life should be implemented in patients experiencing thromboembolic events [15].

4. Conclusion

KS leads to a state of hypercoagulability secondary to hyperestrogenism and hypoandrogenism, which can trigger thrombotic events in these patients, particularly in the case of a coexisting hereditary thrombotic state secondary to other chromosomal and genetic disorders. However, the mechanism behind this association is yet to be proven. Lifetime anticoagulation should therefore be recommended given the risk of recurrence of thromboembolic disease in these patients.

Conflict of interest

The authors declare no conflict of interest.

References

- [1] Klinefelter HF, Reifenstein EC, Albright F. Syndrome characterized by gynecomastia, aspermatogenesis without Leydigism, increased excretion of follicle stimulating hormone. *J Clin Endocrinol* 1942;2:615–7.
- [2] Tapson VF. Acute pulmonary embolism. *N Engl J Med* 2008; 358:1037–52.
- [3] Campbell WA, Price WH. Venous thromboembolic disease in Klinefelter's syndrome. *Clin Genet* 1981;19:275–80.
- [4] Angel JR, Parker S, Sells RE, Atallah E. Recurrent deep vein thrombosis and pulmonary embolism in a young man with Klinefelter's syndrome and heterozygous mutation of MTHFR-677C>T and 1298A>C. *Blood Coagul Fibrinolysis* 2010;21:372–5.
- [5] Swerdlow AJ, Higgins CD, Schoemaker MJ, Wright AF, Jacobs PA. United Kingdom Clinical Cytogenetics Group. Mortality in patients with Klinefelter syndrome in Britain: a cohort study. *J Clin Endocrinol Metab* 2005;90:6516–22.
- [6] Zollner TM, Veraart JC, Wolter M, Hesse S, Villemur B, Wenke A, et al. Leg ulcers in Klinefelter's syndrome: further evidence for an involvement of plasminogen activator inhibitor-1. *Br J Dermatol* 1997;136:341–4.
- [7] Chung J-W, Lee J-B, Kim B-H, Hong S-P, Son J-Y, Lee Y-S, et al. Recurrent deep vein thrombosis and pulmonary embolism in a patient with Klinefelter's syndrome. *Herz* 2013; 38:306–8.
- [8] Lapecorella M, Marino R, De Pergola G, Scaraggi FA, Speciale V, De Mitrio V. Severe venous thromboembolism in a young man with Klinefelter's syndrome and heterozygosity for both G20210A prothrombin and factor V Leiden mutations. *Blood Coagul Fibrinol* 2003;14:95–8.
- [9] Lanfranco F, Kamischke A, Zitzmann M, Nieschlag E. Klinefelter's syndrome. *Lancet* 2004;364:273–83.
- [10] Smyth CM, Bremner WJ. Klinefelter syndrome. *Arch Intern Med* 1998;158:1309–14.
- [11] Pergola G, Mitrio V, Sciaraffia M, Pannacciulli N, Minenna A, Giorgino F, et al. Low androgenicity is associated with higher plasma levels of prothrombotic factors irrespective of age, obesity, body fat distribution, and related metabolic parameters in men. *Metabolism* 1997;46:1287–93.

- [12] Rosedaal FR, Helmerhorst FM, Vandenbroucke JP. Oral contraceptives hormone replacement therapy and thrombosis. *Thromb Haemost* 2001;86:112–23.
- [13] Mount GR, Roebuck JD. Antiphospholipid syndrome in a 21-year-old with Klinefelter syndrome. *J Clin Rheumatol* 2009;15:27–8.
- [14] Ozbek M, Ozturk MA, Ureten K, Cenedi O, Erdogan M, Haznedaroglu IC. Severe arterial thrombophilia associated with a homozygous MTHFR gene mutation (A1298C) in a young man with Klinefelter syndrome. *Clin Appl Thromb Hemost* 2008;14:369–71.
- [15] Angel JR, Parker S, Sells RE, Atallah E. Recurrent deep vein thrombosis and pulmonary embolism in a young man with Klinefelter's syndrome and heterozygous mutation of MTHFR-677C>T and 1298A>C. *Blood Coagul Fibrinol* 2010;21:372–5.
- [16] Howell R. Hypostatic ulceration and Klinefelter's syndrome. *Br Med J* 1978;2:95–6.
- [17] Verp MS, Simpson JL, Martin AO. Hypostatic ulcers in 47,XXY Klinefelter's syndrome. *J Med Genet* 1983;20:100–1.
- [18] Wierda E, Reesink HJ, Bruining H, van Delden OM, Kloek JJ, Bresser P. Successful pulmonary endarterectomy in a patient with Klinefelter syndrome. *Case Rep Pulmonol* 2012;2012:104195.
- [19] Boos CJ, Matfin G. Klinefelter's syndrome manifesting as an acute pulmonary embolus in a 52-year-old man. *Endocr Pract* 2002;8:68–9.
- [20] Clouse LH, Comp PC. The regulation of hemostasis: the protein C system. *N Engl J Med* 1986;314:1298–304.
- [21] De Morentin HM, Dodiuk-Gad RP, Brenner S. Klinefelter's syndrome presenting with leg ulcers. *Skinmed* 2004;3:274–8.
- [22] Goto Y, Uhara H, Murata H, Koga H, Kosho T, Yamazaki M, et al. Leg ulcers associated with positive lupus anticoagulant in two cases of Klinefelter's syndrome. *Acta Derm Venereol* 2011;91:90–1.
- [23] Igawa K, Nishioka K. Leg ulcer in Klinefelter's syndrome. *J Eur Acad Dermatol Venereol* 2003;17:62–4.
- [24] Miller RA, Tremann JA, Ansell JS. The conservative management of renal vein thrombosis. *J Urol* 1974;111:568–71.