

Dynamic spinal compression revealed by computed tomography myelography in overshunting-associated myelopathy

A case report

Eiichiro Amano, MD^a, Kokoro Ozaki, MD, PhD^{a,*}, Satoru Egawa, MD^b, Motohiro Suzuki, MD^a, Takashi Hirai, MD, PhD^b, Satoru Ishibashi, MD, PhD^a, Takuya Ohkubo, MD, PhD^a, Toshitaka Yoshii, MD, PhD^b, Atsushi Okawa, MD, PhD^b, Takanori Yokota, MD, PhD^a

Abstract

Rationale: OSAM is a rare ventriculoperitoneal (VP) shunt complication where cervical spinal cord compression by epidural venous plexus engorgement is caused by cerebrospinal fluid (CSF) overdrainage. Symmetrically indented deformity of the upper cervical spinal cord and surrounding epidural venous engorgement are characteristic radiological findings. Both of them are typically detected on magnetic resonance imaging (MRI) and enhanced computed tomography (CT).

Patient concerns: The 77-year-old man who underwent the placement of a VP shunt without an antisiphon device to treat post-subarachnoid hemorrhage (SAH) hydrocephalus presented with progressive quadriplegia 10 years postoperatively.

Diagnosis: MRI revealed a symmetrically indented spinal cord from the craniocervical junction (CCJ) to the C2 level and enhanced CT showed the epidural venous engorgement, which were characteristic radiological findings of overshunting-associated myelopathy (OSAM). However, MRI atypically failed to detect the engorged epidural vein and showed no compressive lesion around the spinal cord.

Intervention: In order to reveal how the cervical spinal cord was deformed and compressed by engorged epidural vein, CT myelography was performed.

Outcomes: CT myelography proved that the epidural vein dynamically engorged and compressed the cervical spinal cord immediately after rotation and extension of the neck.

Lessons: CT myelography combined with neck rotation and extension revealed the dynamic change of the epidural venous engorgement, and is useful for evaluation and diagnosis of OSAM especially when epidural venous engorgement was not detectable on MRI.

Abbreviations: CT = computed tomography, MRI = magnetic resonance imaging, OSAM = overshunting-associated myelopathy.

Keywords: epidural venous plexus, Monro–Kellie doctrine, over-drainage, overshunting-associated myelopathy, ventriculoperitoneal shunt

1. Introduction

Overshunting-associated myelopathy (OSAM) is a rare ventriculoperitoneal (VP) shunt complication where the cervical spinal cord is compressed by epidural venous plexus engorgement

caused by cerebrospinal fluid (CSF) overdrainage.^[1] Symmetrically indented deformity of the cervical spinal cord and surrounding epidural venous engorgement are characteristic findings on magnetic resonance imaging (MRI)^[2,3] and enhanced computed tomography (CT).^[1,4]

We report the first case of OSAM with cervical spondylosis where an engorged epidural venous plexus was atypically not observed on MRI; however, dynamic epidural venous engorgement as well as spinal compression could be demonstrated successfully on CT myelography after changing the neck position. The written informed consent was obtained from the patient.

2. Case presentation

A 77-year-old man presented with a history of subarachnoid hemorrhage (SAH) due to the rupture of supratentorial aneurysms 13 years before; his treatment had involved clipping of the aneurysms and placement of a VP shunt without an antisiphon device to treat post-SAH hydrocephalus. He fully recovered without any sequelae. The pressure valve setting of his VP shunt was never changed.

Editor: N/A.

The authors report no conflict of interest concerning the materials or methods used in this study or the findings specified in this paper.

^a Department of Neurology and Neurological Science, ^b Department of Orthopaedics, Graduate School of Medical and Dental Sciences, Tokyo Medical and Dental University, Bunkyo, Tokyo, Japan.

* Correspondence: Kokoro Ozaki, Department of Neurology and Neurological Science, Graduate School of Medical and Dental Sciences, Tokyo Medical and Dental University, Bunkyo, Tokyo 113-8510, Japan (e-mail: k-oznuro@tmd.ac.jp).

Copyright © 2018 the Author(s). Published by Wolters Kluwer Health, Inc. This is an open access article distributed under the Creative Commons Attribution-NoDerivatives License 4.0, which allows for redistribution, commercial and non-commercial, as long as it is passed along unchanged and in whole, with credit to the author.

Medicine (2018) 97:10(e0082)

Received: 4 January 2018 / Accepted: 9 February 2018

<http://dx.doi.org/10.1097/MD.00000000000010082>

Ten years postoperatively, he presented with slowly progressive walking difficulties due to weakness in the lower extremities. Weakness eventually also developed in the upper extremities along with urinary and fecal incontinence. His quadriplegia subsequently worsened; he became bedridden and was hospitalized.

On examination, he had distally dominant quadriplegia with elevated deep tendon reflexes and positive Babinski signs. Hypoesthesia and hypoalgesia were observed below the C3 dermatome region, and marked disturbances in joint position and the vibration senses were observed in the extremities. He reported no headaches, nausea, or dizziness.

2.1. Radiological features and diagnosis

MRI revealed a symmetrically indented spinal cord from the craniocervical junction (CCJ) to the C2 level (Fig. 1A) and stenosis at the C4–C6 levels. Although no compressive lesion between CCJ and the C2 level was evident on both plain and gadolinium-enhanced MRI, enhanced CT showed epidural venous plexus engorgement from CCJ to the C4 level (Fig. 1B). A lumbar puncture revealed low CSF pressure (<1 cm H₂O), while a brain MRI did not show any remarkable findings typical for intracranial hypotension, such as diffuse dural enhancement, slit ventricles, descent of the brain, or enlargement of the pituitary gland. Angiography showed no arteriovenous fistula and confirmed the absence of occlusions in the bilateral internal jugular veins.

In order to see how the upper cervical spinal cord is compressed and deformed by the epidural vein, we performed CT myelography: this revealed a severe compression of the spinal cord from CCJ to the C2 level immediately upon changing the neck position from supine to left-sided rotation and extension, and demonstrated the dynamic engorgement of the epidural vein depending on the neck's position (Fig. 2). Although the absence on the MRI of an engorged epidural vein around the deformed spinal cord distinguished our case from previously reported OSAM cases, considering the history of VP shunt placement, low CSF pressure, the characteristic deformity of the upper cervical spinal cord, and the epidural venous plexus engorgement revealed by CT myelography, OSAM was finally diagnosed.

2.2. Treatment and prognosis

The VP shunt pressure valve setting was changed to the upper limit to prevent overdrainage, and thereafter enhanced CT showed a reduction in the size of the epidural vein (Fig. 1C). We did not ligate the VP shunt due to the risk of recurrent hydrocephalus. Instead, we additionally performed excision of the C1 posterior arch and C3–C7 laminoplasty in order to treat the compressive myelopathy due to OSAM at the CCJ–C4 levels as well as decompression for cervical spondylosis at the C4–C7 levels. While operating, we observed compressive scars on the dural sac at the C1 level, which might have been made by repetitive compression by the engorged epidural vein, although an engorged epidural vein directly compressing the dural sac was not evident in the supine position (Fig. 3). Changing the neck position during the operation was risky and therefore not performed. Following revision of the shunt and after the surgery, his quadriplegia gradually improved and spinal compression was no longer detectable on CT myelography even after changing the neck position. One year after the treatment, the patient can walk with assistance.

3. Discussion

Low CSF pressure due to overshunting, engorged epidural veins, and the symmetrically deformed cervical spinal cord are common characteristics of OSAM.^[5] To our knowledge, this is the first case where dynamic compression of the spinal cord was demonstrated on CT myelography by changing the neck position.

3.1. Pathophysiology and general characteristics of OSAM

According to the Monro–Kellie doctrine, the sum of the CSF, blood, and brain volumes remains constant in the intracranial space.^[6] CSF loss due to overdrainage, lumbar puncture, and other causes leads to an increase in the blood volume in order to compensate for the CSF loss. The increased blood volume results in venous system engorgement in both the cranial cavity and the spinal canal.^[3] This compensatory maintenance of the volume is radiologically confirmed as venous sinus engorgement, abnormal

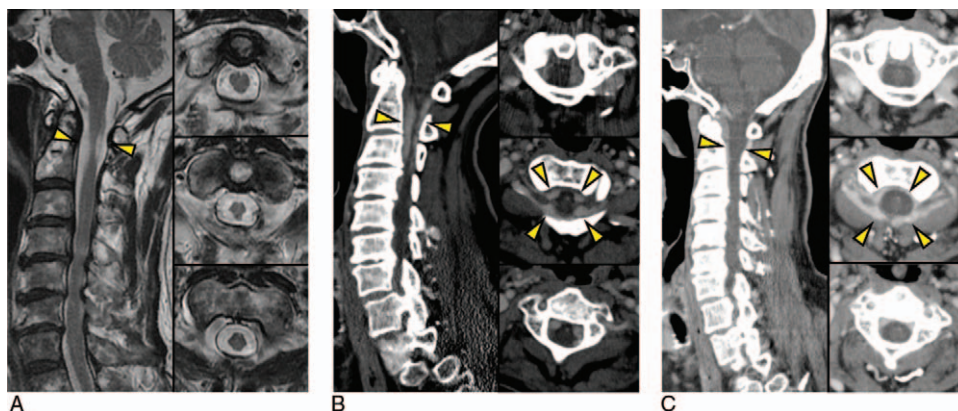


Figure 1. Characteristic computed tomography angiography (CTA) and magnetic resonance imaging (MRI) of the presented overshunting-associated myelopathy case. (A) Plain MRI before changing the pressure valve setting (left, sagittal view; right, coronal view at the C1–C2 levels). No compressive lesion was detected around the deformed spinal cord. Furthermore, gadolinium-enhanced MRI did not show engorged epidural veins (data not shown). (B) Enhanced CT before changing the pressure valve setting (left, sagittal view; right, coronal view at the C1–C2 levels). Engorged epidural veins nearly compressing the spinal cord were observed from CCJ to the C4 level. (C) Enhanced CT after changing the pressure valve setting to the upper limit (left, sagittal view; right, coronal view at the C1–C2 levels). Ventriculoperitoneal shunt intervention resulted in shrunken epidural veins around the spinal cord.

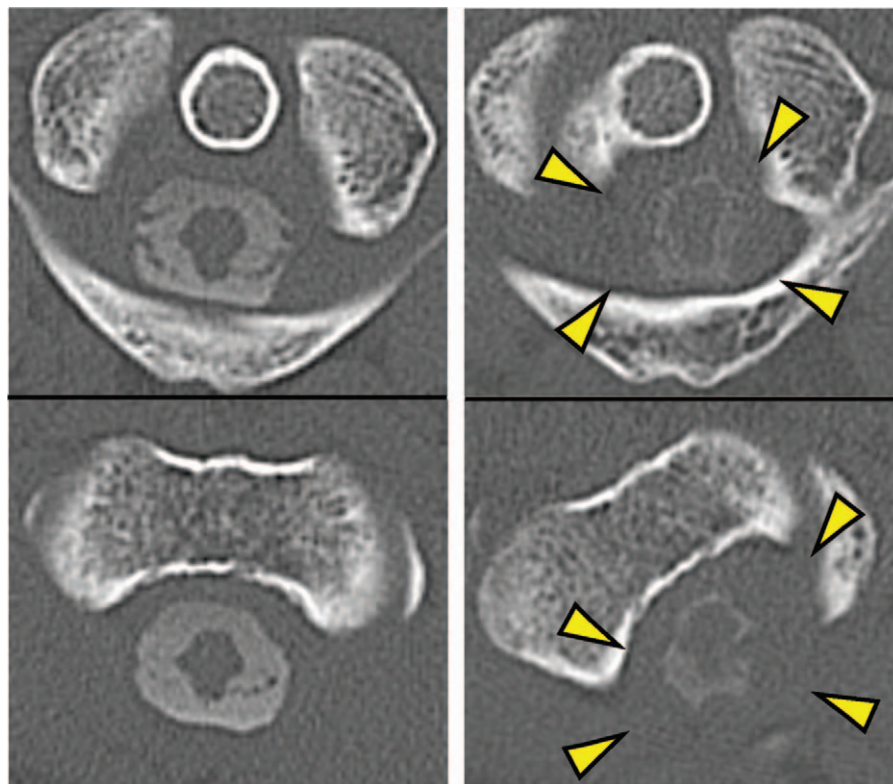


Figure 2. Computed tomography myelography before changing the pressure valve setting and surgical decompression surgery (left column, supine position; right column, left-sided extension). The epidural veins compressed the spinal cord at the C1–C2 levels immediately after changing the neck position.

pachymeningeal enhancement, subdural effusions, and enlargement of the pituitary gland on brain MRI, while confirmed as extra-arachnoid fluid collections, spinal meningeal enhancement, and engorgement of the epidural venous plexus on spinal MRI.^[7] These findings are sometimes absent^[8] but are common characteristics in patients with intracranial hypotension.

In OSAM, epidural venous engorgement is prominent enough to cause compressive myelopathy of the upper cervical spinal

cord, which has a distinct clinical presentation of chronic intracranial hypotension due to overdrainage via the VP shunt. Although patients with postlumbar puncture headache or spontaneous intracranial hypotension headache often show epidural venous engorgement,^[9] these patients do not show compressive myelopathy by epidural veins.

In addition, the absence of headaches is also characteristic for OSAM, although headache is the most common symptom of patients with intracranial hypotension.^[7] The orthostatic headache in intracranial hypotension has been attributed to the traction and distortion of pain-sensitive suspending structures of the brain due to sagging of the brain,^[7] and in OSAM, the absence of headache has been explained by the hypothesis that intracranial hypotension progresses so slowly and chronically that the pain-sensitive nerve endings are not activated.^[4]

Progressive quadriplegia and sensory disturbance are common presentations of OSAM. These symptoms are successfully treated by ligation or exchange of the VP shunt in order to stop the loss of CSF due to overdrainage; this improves the epidural venous engorgement as well.

3.2. Case evaluation

The present case is the first report demonstrating, using CT myelography, how the epidural vein compresses the spinal cord and showing that changing the neck position is a significant aggravating factor in OSAM. In addition, while the indented shape of the upper cervical spinal cord, the engorged epidural vein around it, and improvement of the compression after VP shunt revision as revealed by enhanced CT were compatible with OSAM, this case differs from previous reports on OSAM in that

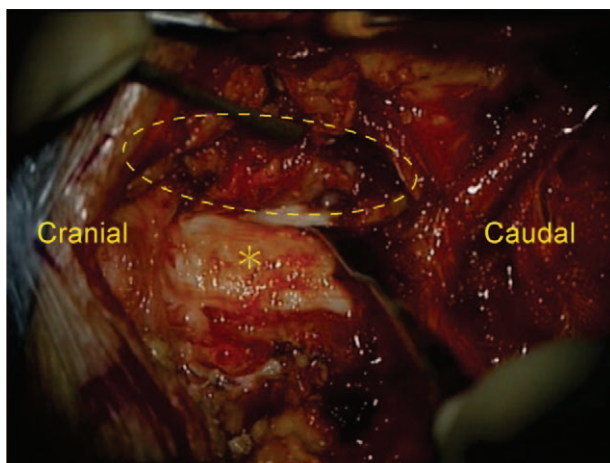


Figure 3. Intraoperative view at the C1–C2 level. After the setting of the pressure valve was changed, decompression surgery was performed. The dotted circle indicates the epidural vein, and the asterisk, the dural sac. Spinal cord compression by the epidural vein was not observed, but the spinal cord was deformed and the dural sac had a compressive scar.

MRI failed to detect the engorged epidural vein while CT myelography and enhanced CT did show it successfully.

The relationship between epidural venous engorgement and neck position in this case is putatively explained by several mechanisms. First, because neck rotation increases the intracranial pressure,^[10] neck rotation might accelerate CSF loss via the VP shunt and worsen overdrainage, resulting in the subsequent venous engorgement according to the Monro–Kellie doctrine. Second, the distribution of the intracranial venous outflow might change with neck position: The main outflow pathway of intracranial blood is putatively the spinal epidural vein in the upright position and the internal jugular vein (IJV) in supine position.^[11,12] Although the dynamics of the venous outflow with changes in neck position in the supine position is unknown, a change in neck position might cause collapse and compression of the IJV by soft tissues around the neck and redistribute the venous flow from the IJV to the epidural vein, exacerbating venous engorgement. Lastly, because the subdural space around the spinal cord is narrowed by neck extension in cervical spondylosis,^[13] congestion of the epidural vein at the C4–C6 levels might also contribute to epidural venous engorgement at the upper levels in this case. The pathophysiology of the dynamic compression dependent on neck position may be complicated, as mentioned above. The deformity of the upper spinal cord of our patient might have been caused by repetitive compression whenever he changed neck position, and we hypothesize that this compression changes so rapidly that CT myelography is superior to MRI for its detection. It is important to recognize that OSAM sometimes does not display an engorged epidural vein on MRI, as shown in this report, and that CT myelography would help in the diagnosis and evaluation of spinal compression by the epidural vein.

This report is limited in that we could not strictly discern whether OSAM or cervical spondylosis was the more severe cause for the neurological disturbance because we performed VP shunt revision against OSAM as well as cervical decompression surgery against both cervical spondylosis and OSAM. We could not compare the outcome of each treatment, but laminoplasty against cervical spondylosis at the C4–C7 levels was imperative. Excision of the C1 posterior arch and the laminoplasty at C3–C7 were possibly partly effective for decompression of the spinal cord deformed by the epidural venous engorgement from CCJ to the C4 level; however, our patient could not have recovered from his severe disabilities without VP shunt revision, as previous reports have shown that VP shunt exchange or ligation is effective for treatment of OSAM. It is reasonable to consider both of these treatment strategies especially in cases of OSAM complicated by cervical spondylosis like the present case, and we should be aware of OSAM when patients show characteristic spinal deformation even without epidural venous engorgement around it on MRI. In

such cases, we should perform CT myelography for accurate evaluation and diagnosis of OSAM.

4. Conclusion

A rare complication of VP shunt placement, OSAM, shows progressive myelopathy with characteristic symmetrical deformity of the upper cervical spinal cord. CT myelography combined with neck rotation and extension is useful for the evaluation and diagnosis of OSAM, especially when spinal compression by the epidural vein is not detectable on MRI.

Acknowledgment

We wish to acknowledge the assistance of the Department of Radiology, Tokyo Medical and Dental University Hospital, Japan.

References

- [1] Miyazaki T, Chiba A, Nishina H, et al. Upper cervical myelopathy associated with low CSF pressure: a complication of ventriculoperitoneal shunt. *Neurology* 1998;50:1864–6.
- [2] Ho JM, Law HY, Yuen SC, et al. Overshunting-associated myelopathy: report of 2 cases. *Neurosurg Focus* 2016;41:E16.
- [3] Wolfe SQ, Bhatia S, Green B, et al. Engorged epidural venous plexus and cervical myelopathy due to cerebrospinal fluid overdrainage: a rare complication of ventricular shunts. *Case report. J Neurosurg* 2007;106:227–31.
- [4] Caruso R, Wierzbichi V, Marrocco L, et al. A poorly known cerebrospinal fluid shunt complication: Miyazaki syndrome. *World Neurosurg* 2015;84:834–8.
- [5] Howard BM, Sribnick EA, Dhall SS. Over-shunting associated myelopathy. *J Clin Neurosci* 2014;21:2242–4.
- [6] Morki B. The Monro-Kellie hypothesis: applications in CSF volume depletion. *Neurology* 2001;56:1746–8.
- [7] Paldino M, Mogilner AY, Tenner MS. Intracranial hypotension syndrome: a comprehensive review. *Neurosurg Focus* 2003;15:EC2.
- [8] Morki B, Atkinson JL, Dodick DW, et al. Absent pachymeningeal gadolinium enhancement on cranial MRI despite symptomatic CSF leak. *Neurology* 1999;53:402–4.
- [9] Yousry I, Forderreuther S, Moriggl B, et al. Cervical MR imaging in postural headache: MR signs and pathophysiological implications. *Am J Neuroradiol* 2001;22:1239–50.
- [10] Williams A, Coyne SM. Effects of neck position on intracranial pressure. *Am J Crit Care* 1993;2:68–71.
- [11] Alperin N, Lee SH, Sivaramakrishnan A, et al. Quantifying the effect of posture on intracranial physiology in humans by MRI flow studies. *J Magn Reson Imaging* 2005;22:591–6.
- [12] Valdueza JM, von Munster T, Hoffman O, et al. Postural dependency of the cerebral venous outflow. *Lancet* 2000;355:200–1.
- [13] Zhang L, Zeitoun D, Rangel A, et al. Preoperative evaluation of the cervical spondylotic myelopathy with flexion-extension magnetic resonance imaging: about a prospective study of fifty patients. *Spine (Phila Pa 1976)* 2011;36:E1134–1139.