

# Peritoneal Mesothelioma: An Unusual Cause of High-Protein Ascites

Matthew Kaspar, MD

*Department of Internal Medicine, Virginia Commonwealth University Medical Center, Richmond, VA*

## Abstract

We present a case illustrating the workup and diagnosis of peritoneal sarcomatous mesothelioma as an unusual etiology of intestinal obstruction and high-protein ascites in an otherwise healthy man. This rare disorder is diagnosed based on immunohistochemistry, which is necessary to differentiate it from other rare sarcomatous carcinomas. In many cases, localized disease can be treated to cure with surgery and intraperitoneal chemotherapy. Advanced disease is often treated for palliation of symptoms.

## Introduction

High-protein ascites, defined as a serum albumin ascites gradient (SAAG) of less than 1.1 mg/dL, typically indicates a cause of ascites not related to portal hypertension. Typical etiologies may include hypoalbuminemic states such as nephrotic syndrome or protein-wasting enteropathy, or any disease process associated with peritonitis, such as chemical irritation from pancreatitis, infectious or autoimmune serositis, or an inflammatory response associated with peritoneal carcinomatosis.<sup>1</sup>

## Case Report

A 45-year-old otherwise healthy African American man presented with a chief complaint of fatigue, increasing abdominal girth, and unintentional weight loss of 9 kg over the past year, which rapidly worsened over the past 3 weeks. Over the last few days, he had developed constipation, intermittent nausea, and vomiting. His history was significant only for employment as a laborer in construction and demolition for approximately 15 years.

Initial physical exam revealed a soft, distended abdomen with fluid wave and bulging flanks, no organomegaly, and active bowel sounds. Laboratory evaluation revealed only a mild elevation of alkaline phosphatase (125 U/L). Paracentesis was performed with removal of approximately 4 L of hazy yellow fluid. The fluid had a SAAG of 0.4 g/dL with total protein of 5.6 g/dL. Cell count with differential was significant for 571 leukocytes with 50% macrophages. There were no malignant cells on fluid cytology. Abdominal CT showed massive ascites, thickened loops of distal jejunum and transverse colon, ill-defined sclerotic lesions in the bodies of multiple thoracic vertebrae, and peritoneal enhancement concerning for carcinomatosis. Tuberculin skin testing read negative after 48 hours. Upper endoscopy and colonoscopy did not reveal any evidence of malignancy.

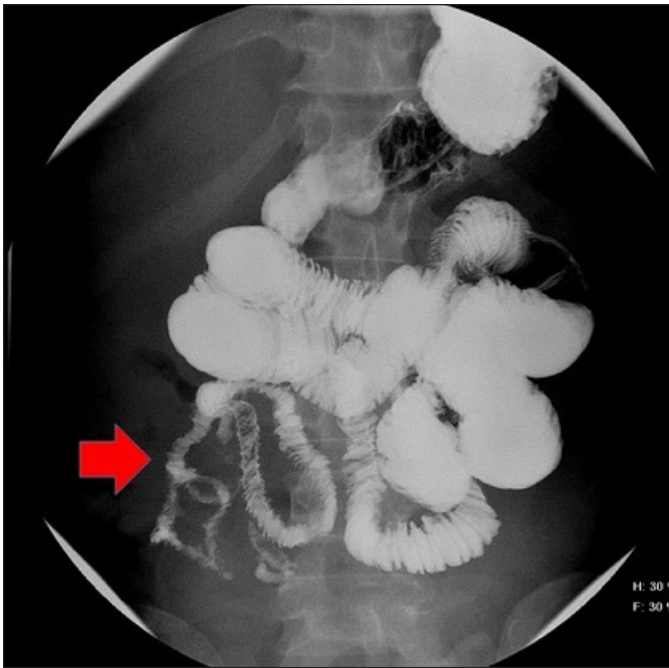
Over the next 7 days, the patient's abdominal pain, vomiting, and constipation progressed to a clinical picture consistent with small bowel obstruction. A nasogastric tube was placed with improvement in patient's nausea and pain. Upper GI series did not reveal obstruction, but showed slow transit time with a long length of luminal narrowing and irregularities in the distal small bowel, concerning for a serosal process such as infection, neoplasm, or carcinomatosis (Figure 1).

*ACG Case Rep J* 2015;3(1):71-73. doi:10.14309/crj.2015.105. Published online: October 9, 2015.

**Correspondence:** Matthew Kaspar, Division of Gastroenterology, Hepatology and Nutrition, Department of Internal Medicine, VCU Medical Center-MCV Campus, West Hospital, 14th Floor, 1200 E Broad Street, P.O. Box 980341, Richmond, VA 23225 (kasparmatt@gmail.com).



**Copyright:** © 2015 Kaspar. This work is licensed under a Creative Commons Attribution-NonCommercial-NoDerivatives 4.0 International License. To view a copy of this license, visit <http://creativecommons.org/licenses/by-nc-nd/4.0>.



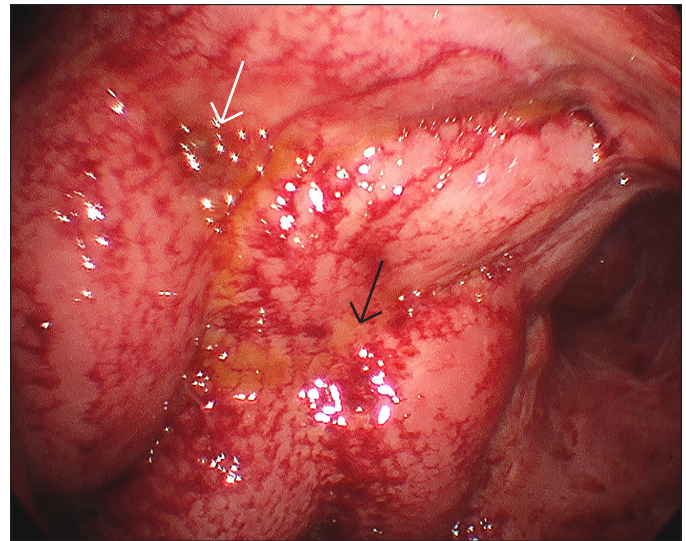
**Figure 1.** Upper GI series showing small bowel follow-through with a long length of small bowel luminal narrowing and fold thickening.

Exploratory laparoscopy to identify the cause of his small bowel obstruction was performed. Gross examination of the peritoneum revealed a frozen abdomen with bowel wall and peritoneal thickening in addition to areas concerning for focal tumor implant (Figure 2). Pathology from peritoneal biopsies stained positive for pancytokeratin, Wilms tumor suppressor gene 1 (WT1), and calretin, and negative for CD34, most consistent with a diagnosis of sarcomatous peritoneal mesothelioma. Chest CT performed after diagnosis did not reveal any thoracic disease.

The patient's obstructive symptoms did not resolve. A percutaneous gastrostomy tube was placed to provide durable decompression of the stomach, and parenteral nutrition was initiated. The patient began therapy with a pemetrexed and cisplatin regimen with a goal of symptom palliation. After approximately 6 months of treatment, the patient achieved some improvement of his obstructive symptoms, allowing removal of the gastrostomy tube and the reintroduction of oral feeding.

## Discussion

Peritoneal sarcomatous mesothelioma is a rare cause of carcinoma-related high-protein ascites. The etiology, gender distribution, pathology, natural history, and treatment options for mesothelioma differ substantially depending on the site of origin. Peritoneal mesothelioma is a rare disease, comprising approximately 20–30% of the 2,500 cases of malignant mesothelioma diagnosed in the United States



**Figure 2.** Diagnostic laparoscopy showing “frozen abdomen” with fibrotic peritoneum and encased bowel (black arrow), and focal areas concerning for tumor implant (white arrow).

each year.<sup>2</sup> Outcomes are typically poor, with 5-year mortality of 29–87%, depending on stage at diagnosis.<sup>3</sup> As with pulmonary mesothelioma, most peritoneal mesothelioma is associated with asbestos exposure.<sup>4</sup> Though the mechanism by which a (presumably) inhaled carcinogen causes peritoneal disease is not known, it is theorized that fibers are inhaled, swallowed as saliva or respiratory secretions, and may migrate through the lumen of the bowel into the peritoneal cavity.<sup>5</sup>

Diagnosis is challenging. Patients typically present with non-specific symptoms such as abdominal pain (33%) and increasing abdominal girth (31%), accompanied by a myriad of other symptoms such as weight loss, dyspnea, and night sweats.<sup>6</sup> There are no tumor markers that can be used to make a diagnosis, and ascites fluid cytology is not a particularly sensitive test.<sup>6,7</sup> As such, peritoneal biopsy with review by an experienced pathologist is an essential component of diagnosis. Distinguishing sarcomatoid mesothelioma from sarcomatoid carcinoma is difficult, and a constellation of pathologic findings, typically with specialized immunohistochemical staining, is required to make the diagnosis.<sup>8</sup>

There is currently no broadly accepted staging system for peritoneal mesothelioma. However, a TMN system has been proposed by The Peritoneal Surface Oncology Group International (PSOGI).<sup>2</sup> In the proposed system, tumor status is determined via surgical exploration, and is based on the total surface area of abdominal serosal surface involved as defined by the Peritoneal Carcinomatosis Index (PCI).<sup>9</sup>

For favorable histologic subtypes and localized disease, surgical debulking with intraperitoneal chemotherapy is the

preferred method of treatment, as it offers the possibility of long-term survival and cure.<sup>10</sup> Pemetrexed, with or without a platinum-based agent, may be offered as a palliative measure for patients with disease too advanced for surgical therapy, providing a survival benefit ranging from 0.4 to 71 months.<sup>11,12</sup>

## Disclosures

Author contributions: M. Kaspar wrote the article and is the article guarantor.

Financial disclosure: None to report.

Informed consent was obtained for this case report.

Received: February 22, 2015; Accepted: June 23, 2015

## References

- Runyon BA, Montano AA, Akriviadis EA, et al. The serum-ascites albumin gradient is superior to the exudate-transudate concept in the differential diagnosis of ascites. *Ann Intern Med.* 1992;117:215-220
- Price B. Analysis of current trends in United States mesothelioma incidence. *Am J Epidemiol.* 1997;145(3):211-8.
- Yan TD, Deraco M, Elias D, et al. A novel tumor-node-metastasis (TNM) staging system of diffuse malignant peritoneal mesothelioma using outcome analysis of a multi-institutional database. *Cancer.* 2011;117:1855-63.
- Delgermaa V, Takahashi K, Park EK, et al. Global mesothelioma deaths reported to the World Health Organization between 1994 and 2008. *Bull World Health Organ.* 2011;89(10):716A-724C.
- Jeong YJ, Kim S, Kwak SW, et al. Neoplastic and non-neoplastic conditions of serosal membrane origin: CT findings. *Radiographics.* 2008;28(3):801-17.
- Chua TC, Chong CH, Morris DL. Peritoneal mesothelioma: Current status and future directions. *Surg Oncol Clin N Am.* 2012;21(4):635-43.
- Sugarbaker PH, Welch LS, Mohamed F, Glehen O. A review of peritoneal mesothelioma at the Washington Cancer Institute. *Surg Oncol Clin N Am.* 2003;12(3):605-21.
- Chirieac LR, Pinkus GS, Pinkus JL, et al. The immunohistochemical characterization of sarcomatoid malignant mesothelioma of the pleura. *Am J Cancer Res.* 2011;1(1):14-24.
- Jacquet P, Sugarbaker PH. Current methodologies for clinical assessment of patients with peritoneal carcinomatosis. In: Sugarbaker PH, ed. *Peritoneal Carcinomatosis: Principles of Management.* Vol 82. Boston, MA: Kluwer Academic Publishers; 1996:359-374.
- Yan TD, Deraco M, Baratti D, et al. Cytoreductive surgery and hyperthermic intraperitoneal chemotherapy for malignant peritoneal mesothelioma: Multi-institutional experience. *J Clin Oncol.* 2009;27(36):6237-42
- Carteni G, Manegold C, Garcia GM, et al. Malignant peritoneal mesothelioma: Results from the International Expanded Access Program using pemetrexed alone or in combination with a platinum agent. *Lung Cancer.* 2009;64(2):211-18.
- Simon GR, Verschraegen CF, Jännee PA, et al. Pemetrexed plus gemcitabine as first-line chemotherapy for patients with peritoneal mesothelioma: Final report of a phase II trial. *J Clin Oncol.* 2008;26(21):3567-72.

## Publish your work in ACG Case Reports Journal

ACG Case Reports Journal is a peer-reviewed, open-access publication that provides GI fellows, private practice clinicians, and other members of the health care team an opportunity to share interesting case reports with their peers and with leaders in the field. Visit <http://acgcasereports.gi.org> for submission guidelines. Submit your manuscript online at <http://mc.manuscriptcentral.com/acgcr>.