

Endoscopic monopolar cauterization of the sphenopalatine artery: a single surgeon's experience

Haitham Odat, Mohannad Al-Qudah

From the Department of Special Surgery, Jordan University of Science and Technology, Irbid, Jordan

Correspondence: Haitham Odat · Department of Special Surgery, Jordan University of Science and Technology, Irbid 22110, Jordan · T: +962798201825 · dr.haithamodat@gmail.com · ORCID: <http://orcid.org/0000-0002-5148-7600>

Ann Saudi Med 2016; 36(6): 422-426

DOI: 10.5144/0256-4947.2016.422

BACKGROUND: Epistaxis is one of the most common otolaryngology emergency conditions, and is usually treated conservatively by different types of nasal packs. A limited number of patients continue to bleed even with tightly fitted anterior and posterior packs in the nose. Such intractable epistaxis is managed by surgery or embolization.

OBJECTIVES: We reviewed the use and outcomes of endoscopic suction monopolar cauterization of the sphenopalatine artery.

DESIGN: Retrospective study.

SETTING: Tertiary academic center.

PATIENTS AND METHODS: Subjects who underwent consecutive monopolar sphenopalatine artery ligation for intractable epistaxis performed by a senior author from August 2010 to December 2014.

MAIN OUTCOME MEASURE(S): Successful management of refractory epistaxis.

RESULTS: In 15 subjects (mean age 45 years; 10 men and 5 women) idiopathic epistaxis was the most common indication for surgery. Six patients had hypertension and three were on anticoagulation. One patient required bilateral cauterization and another had anterior ethmoid artery cauterization. The average operative time was 57 minutes. There was no major intra- or postoperative complications. Two patients underwent endoscopic sinus surgery to treat pathologies that were found during the procedure. All patients had healthy nasal and sinus mucosa during the follow-up period (average 17 months, range 1-70 months), and none suffered recurrent epistaxis.

CONCLUSIONS: Endoscopic monopolar cauterization of sphenopalatine artery is safe and effective for management of refractory epistaxis with minimal complications. It should be considered earlier in the algorithmic treatment of intractable epistaxis.

LIMITATIONS: Retrospective study, small number of patients, and no controls.

Epistaxis is one of the most common otolaryngology emergency conditions, and is usually treated conservatively by different types of nasal packs.^{1,2} A limited number of patients continue to bleed even with tightly fitted anterior and posterior packs in the nose. Such intractable epistaxis is managed by surgery or embolization.³

Different surgical techniques have been described in literature to control intractable epistaxis.³ In the pre-endoscopic era, three methods—internal maxillary artery ligation via a transantral approach, an open

approach for the ethmoidal vessels and external carotid artery ligation were considered the procedures of choice.⁴ The introduction of the endoscope in rhinology allowed for better visualization of the posterior nasal cavity region and skull base, which made non-invasive control of such intractable bleeding feasible. In early endoscopic period, the sphenopalatine artery was difficult to identify in the medial sphenopalatine foramen, and endoscopic diathermy of the bleeding region became a popular procedure.⁵ Later on, complete endoscopic access to the sphenopalatine artery

was described using diathermy or homeostatic clips.^{6,7} Limited studies explore the feasibility of suction monopolar diathermy of the sphenopalatine artery. The aim of this paper was to review the safety and efficacy of monopolar diathermy in controlling intractable nasal bleeding.

PATIENTS AND METHODS

After obtaining our institutional review boards' permission, a retrospective chart review of all consecutive patients who had sinonasal surgery at a tertiary referral center under the senior author (MA) from August 2010 to May 2016 was conducted. Patients who underwent endoscopic suction monopolar cauterization of the sphenopalatine artery with a minimum follow up of one month were included in this study. Charts and electronic records were reviewed for demographic data, presentation, medical and surgical history, surgical technique as well as success rate and complications.

All procedures were performed under general anesthesia. The nasal packs were removed and the nasal cavity irrigated with normal saline to clean all the crust and blood clot. The nose was prepared in the usual way for endoscopic sinus surgery. Then, a standard infundibulotomy and middle meatus antrostomy were performed. The antrostomy was widened to the level of the posterior wall of the antrum. A mucoperiosteal flap was raised from the posterior margin of the antrostomy with freer elevator until the crista ethmoidalis was reached. A bipolar probe was used to free the vascular pedicle from the flap and fracture the ethmoidalis crest from posterior to anterior direction to fully expose the vessels bundle (**Figures 1, 2**). The trunk of sphenopalatine artery and its branches were then cauterized with monopolar diathermy (**Figure 3**). The flap was returned to its original position and gelfoam was placed between the flap and the middle turbinate.

RESULTS

Sixteen sphenopalatine arteries were cauterized by the senior author (MA) for 15 patients (10 men and 5 women). One patient required bilateral cauterization. Five patients had right-sided epistaxis and nine patients had left-sided epistaxis. The mean age of the patients was 45 years, ranging from 22 to 72 years. The etiology of bleeding was idiopathic in ten patients and iatrogenic in five. Six patients had hypertension, three were on anticoagulation medications and one was pregnant in the second trimester. One patient required bilateral cauterization and another had anterior ethmoid artery cauterization. The mean (standard deviation) for operative time was 57 (19) minutes. The mean hospital stay

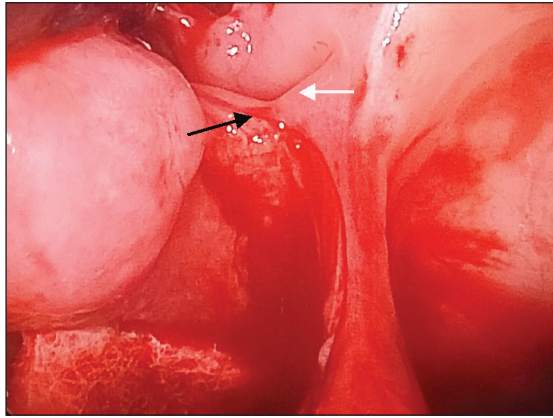


Figure 1. Raised mucoperiosteal flap, the sphenopalatine artery (lower arrow) emerges posterior to the ethmoidalis crest (upper arrow).

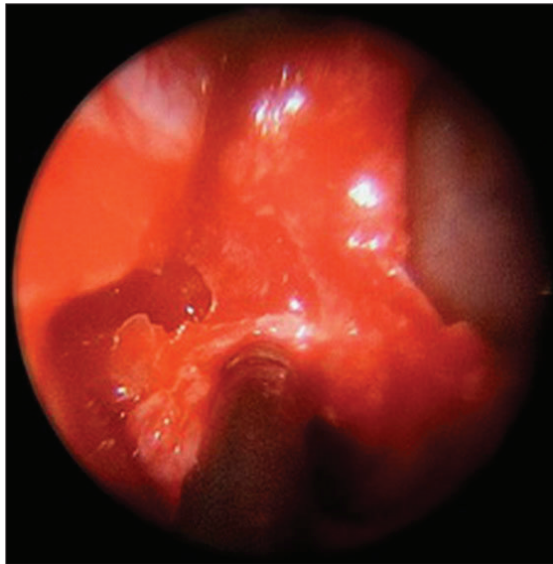


Figure 2. Suction monopolar diathermy applied directly on the sphenopalatine artery. The artery is well exposed after ethmoidalis crest removal.

was 3.7 days, range 3-8 days. All studied cases were discharged one day after the surgery except for one pregnant woman who stayed for monitoring of the fetus based on obstetric consultation. No patient suffered recurrent epistaxis within the follow-up time (mean 17 months, range 1-70 months; August 2010 to May 2016). All patients were found to have healthy nasal and sinus mucosa (**Figure 4**). Two patients underwent endoscopic sinus surgery to treat medical conditions that were found during the procedure, one for nasal polyposis and the other for esthesioneuroblastoma. Adhesion between the inferior turbinate and septum was found in one case which was cut under local anesthesia in the clinic.

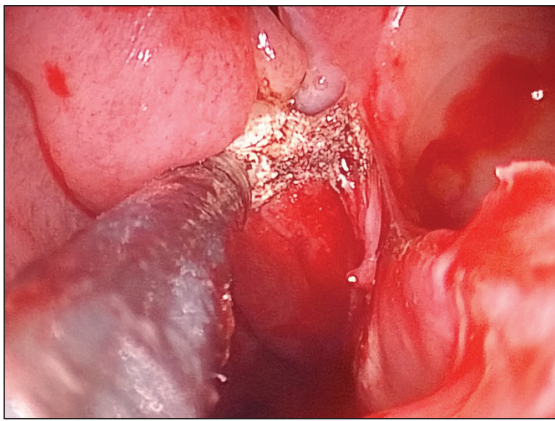


Figure 3. Sphenopalatine region immediately after diathermy.

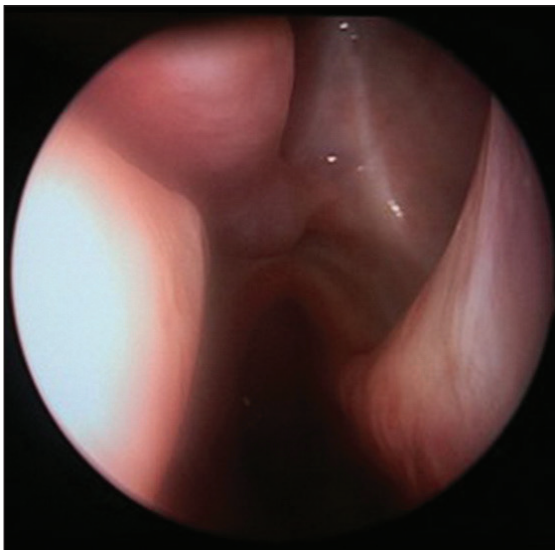


Figure 4. Healed nasal and maxillary sinus mucosa one year after cauterization.

DISCUSSION

Although up to 60 per cent of the general population experience one episode of epistaxis in their lifetime,^{1,2} fewer than 10% seek a physician's attention and one tenth require hospitalization for severe bleeding.⁸ Hypertension, anticoagulation medications, age, nasal trauma, deviated nasal septum, environmental factors, and nasal pathology have been proposed in the pathogenesis; however in the majority of cases the etiology remains idiopathic.

Epistaxis is divided into anterior and posterior based on the site of bleeding. Anterior epistaxis is the most common form, usually mild and easily managed. Posterior nasal bleeding is severe, traditionally treated

with extensive nasal packing using an anterior-posterior pack or a balloon catheter and requires a long hospitalization.^{9,10} Apart from a high failure rate, posterior nasal packing is associated with significant complications such as: bradycardia, hypoxia, life-threatening upper airway obstruction, toxic shock syndrome and infectious endocarditis.¹¹ Recently endoscopic surgical intervention and arterial embolization have been advocated for the management of posterior epistaxis.

Embolization is successful in up to 85% of patients. The procedure requires the presence of an experienced interventional neuroradiologist and carries serious neurological complications.¹² Strong et al reviewed their experience in treating 21 patients with intractable epistaxis. They found transantral maxillary artery (IMA) ligation and percutaneous embolization of the maxillary artery had a similar success rate with a complication rate of 25% to 30%. A cost comparison revealed that surgery was moderately less expensive than embolization.¹³

Prades was the first to describe sphenopalatine artery ligation through a middle meatus antrostomy for dividing the vidian nerve using the surgical microscope in 1976.¹⁴ Twenty years later an endoscopic dual port technique to approach the sphenopalatine artery in the pterygopalatine fossa was reported by White.¹⁵ In this technique a canine fossa puncture was created to view the posterior wall of the maxillary sinus and the posterior wall was osteotomised endonasally through a wide middle meatal antrostomy. He felt that the artery was difficult to identify on the medial side of the sphenopalatine foramen.¹⁵

Recent advances in visualization and instrumentation have made it possible to precisely dissect the pterygopalatine region and expose the sphenopalatine artery. The endoscopic approach to control the sphenopalatine artery replaced older invasive techniques. Different methods and procedures have been described to occlude the artery (**Table 1**).^{5,6,16-24} Monopolar handling in this narrow and posterior region is easier than the two arms bipolar. It is also faster than clipping the artery with needs specially designed forceps and a metal clip. Rockey and Anand reviewed their experience of sphenopalatine artery clipping in ten patients. Two patients had ongoing epistaxis within the first twenty-four hours postoperatively. They attributed this failure to incorrectly closed clips.¹⁹ An additional modification that we have used is the removal of the ethmoidalis crest. Such modification helps to clearly identify the proximal segment of the artery and avoid possible confusion with its branches.

Many authors favour resection of the uncinete pro-

Table 1. Success rates with different methods of endoscopic SPA ligation.

Date	Author	Number	Technique	Success rate	Complications
1997	Sharp et al ¹⁶	11	Clipping	100%	None
1998	Frikart et al ⁵	46	Monopolar	92%	Transient loss of consciousness (2%)
2000	Wormald et al ⁶	13	Clipping	92%	None
2000	Srinivasan et al ¹⁷	10	Bipolar	90%	None
2000	O'Flynn et al ¹⁸	12	clipping	100%	None
2002	Rockey et al ¹⁹	10	Clipping (8)/ Bipolar (2)	77%	Not mentioned
2004	Wiorowski et al ²⁰	10	Bipolar	90%	None
2005	Umapathy et al ²¹	41	Clipping	99%	Not mentioned
2007	Nouraei et al ²²	71	Bipolar	90%	None
2010	Minni et al ²³	42	Bipolar	93%	Minor complications like adhesions and crusting (27%)
2016	McDermott et al ²⁴	45	Clipping (31)/ Bipolar (8)/ Both (6)	87%	Not mentioned
2016	Our study	16	Monopolar	100%	Minor adhesion (6%)

cess and creation of a wide middle meatus anrostomy before sphenopalatine artery ligation^{8,17,18}. This can increase the space for instrumentation, allows for better exposure of surgical landmarks and facilitates artery and collateral vessel identification. Other surgeons use a lateral nasal wall incision posterior to the maxillary sinus to expose the artery.³

Sphenopalatine artery is the end-artery of the internal maxillary artery, a branch of the external carotid artery that supplies the posterior nasal septum and the most of the lateral nasal wall. It enters the nose through the sphenopalatine foramen after leaving pterygopalatine fossa. The foramen is located within the superior meatus, between the middle turbinate and the posterior horizontal end of the lamella of the superior turbinate.²⁵ The sphenopalatine artery usually divides into two or more branches prior to its entry into the nasal cavity. The most consistent are the posterior lateral nasal branch and the nasal septal artery.²⁵ Sphenopalatine artery is nearer to the nasal bleeding points than IMA. The blockage of the sphenopalatine artery is more effective in prevention collateral circulation formation than the distal IMA ligation and so the tissue will have more time to recover.²⁶ Well healed nasal mucosa provides a stronger barrier for fragile vessels to re-bleed.

One of the limitations of this study is the small number of patients; however, this series represents one of the largest studies of a single surgeon's experience of

endoscopic sphenopalatine artery monopolar cauterization. Our results are comparable with these reported using different techniques and arterial occlusion methods.^{3,8,17,18} The majority of studies have reported a success rate above 85%. Warfarin administration, low platelet count on admission, and not using cauterization for sphenopalatine artery ligation have been suggested as possible risk factors for early failure.²² Minor re-bleeding requiring nasal packing, nasal crusting, synechiae, palatal numbness, mucosal atrophy, and acute sinusitis are potential complications.³ We conclude that endoscopic sphenopalatine artery monopolar cauterization is non-invasive, effective, well-tolerated and is a reliable procedure to control intractable epistaxis. Because the technique is not time consuming and has minimal morbidity, it should appear early on the algorithm for management of severe epistaxis.

Acknowledgment

This research was approved by our university IRB committee.

This research received no specific grant from any funding agency in the public, commercial or not-for-profit sectors.

The authors contributed significantly in the study design, writing, data analysis, and article revision. Both au-

thors declare that they did not receive specific funding from the public, commercial or not-for-profit sectors.

Conflict of interest

We declare that we have no conflict of interest.

Compliance with ethical requirements

The study was performed according to the ethical requirements; this article does not contain any experiments with human or animal subjects performed by the authors.

REFERENCES

- Pallin DJ, Chng YM, McKay MP, Emond JA, Pelletier AJ, Camargo CA Jr. Epidemiology of epistaxis in US emergency departments, 1992 to 2001. *Ann Emerg Med* 2005; 46:77-81.
- Kotecha B, Fowler S, Harkness P, Walmsley J, Brown P, Topham J. Management of epistaxis: a national survey. *Ann R Coll Surg Engl* 1996; 78: 444-446.
- Rudmik L, Smith TL. Management of intractable spontaneous epistaxis. *Am J Rhinol Allergy* 2012 ;26:55-60.
- Feusi B, Holzmann D, Steurer J. Posterior epistaxis: systematic review on the effectiveness of surgical therapies. *Rhinology* 2005 ;43:300-4.
- Frikart L, Agrifoglio A. Endoscopic treatment of posterior epistaxis. *Rhinology* 1998; 36:59-61
- Wormald PJ, Wee DT, van Hasselt CA. Endoscopic ligation of the sphenopalatine artery for refractory posterior epistaxis. *Am J Rhinol*. 2000; 14:261-4.
- Pothier DD, Mackeith S, Youngs R. Sphenopalatine artery ligation: technical note. *J Laryngol Otol*. 2005; 119:810-2.
- Ram B, White PS, Saleh HA, Odutoye T, Cain A. Endoscopic endonasal ligation of the sphenopalatine artery. *Rhinology* 2000; 38: 147-9.
- Rudmik L, Smith TL. Management of intractable spontaneous epistaxis. *Am J Rhinol Allergy*. 2012;26:55-60.
- Shikani AH, Chahine KA, Alqudah MA. Endoscopically guided chitosan nasal packing for intractable epistaxis. *Am J Rhinol Allergy* 2011 ;25:61-3.
- Traboulsi H, Alam E, Hadi U. Changing Trends in the Management of Epistaxis. *Int J Otolaryngol*. 2015;2015:263987. doi: 10.1155/2015/263987.
- Christensen NP, Smith DS, Barnwell SL, Wax MK. Arterial embolization in the management of posterior epistaxis. *Otolaryngol Head Neck Surg*. 2005;133:748-53.
- Strong EB, Bell DA, Johnson LP, Jacobs JM. Intractable epistaxis: transantral ligation vs embolization – efficacy review and cost analysis. *Otolaryngol Head Neck Surg*1995;113:674-8.
- Prades J. Microangioma Endonasal de la Fosa PterygomacillarydelMeatoMedio. Spain. Salvat, Spain, 1980.
- White PS. Endoscopic ligation of the sphenopalatine artery: a preliminary description. *J Laryngol Otol* 1996;110:27-30.
- Sharp HR, Rowe-Jones JM, Biring GS, Mackay IS. Endoscopic ligation or diathermy of the sphenopalatine artery in persistent epistaxis. *J Laryngol Otol*. 1997; 111: 1047-50.
- Srinivasan V, Sherman IW, O'Sullivan G. Surgical management of intractable epistaxis: audit of results. *J Laryngol Otol*. 2000;114:697-700.
- O'Flynn PE, Shadaba A. Management of posterior epistaxis by endoscopic clipping of the sphenopalatine artery. *Clin Otolaryngol Allied Sci*. 2000;25:374-7.
- Rockey JG, Anand RA. Critical audit of the surgical management of intractable epistaxis using sphenopalatine artery ligation/diathermy. *Rhinology*. 2002;40:147-9.
- Wiorowski M, Schultz P, Perrot JB, Gentine A, Debry C. Indications and results of cauterization by endoscopic approach of the sphenopalatine artery in severe posterior epistaxis. *Auris Nasus Larynx*. 2004; 31: 131-3.
- Umaphy N, Quadri A, Skinner DW. Persistent epistaxis: what is the best practice? *Rhinology*. 2005; 43: 305-8.
- Nouraei SA, Maani T, Hajioff D, Saleh HA, Mackay IS. Outcome of endoscopic sphenopalatine artery occlusion for intractable epistaxis: A 10-year experience. *Laryngoscope* 2007; 117:1452-6.
- Minni A, Dragonetti A, Gera R, Barbaro M, Magliulo G, Filippo R. Endoscopic management of recurrent epistaxis: the experience of two metropolitan hospitals in Italy. *Acta Otolaryngol*. 2010; 130: 1048-52.
- McDermott AM, O' Cathain E, Carey BW, O'Sullivan P, Sheahan P. Sphenopalatine Artery Ligation for Epistaxis: Factors Influencing Outcome and Impact of Timing of Surgery. *Otolaryngol Head Neck Surg*. 2016; 154: 547-52.
- Lee HY, Kim HU, Kim SS, Son EJ, Kim JW, Cho NH et al. Surgical anatomy of the sphenopalatine artery in lateral nasal wall. *Laryngoscope* 2002;112:1813-8.
- Weaver EM, Chaloupka JC, Putman CM, Roth TC, Horky JK, Sasaki CT. Effect of internal maxillary occlusion on nasal blood flow in swines. *Laryngoscope* 1999;109:8-14.