

Peri-Anal and Genital Localization of Giant Condyloma Acuminatum or Buschke–Lowenstein’s Tumor: A Report of Two Cases

Abstract

Buschke–Löwenstein’s tumor (BLT) is a skin tumor induced by a human papillomavirus (HPV) infection. HPV genotypes 6 and 11, which are of low oncogenic potential, are present in over 90% of condylomas. Genotypes 16 and 18 combine with factors related to immunosuppression and chronic irritation to promote exophytic and endophytic growth and malignant transformation. BLT is most common in men between the ages of 40 and 60, occurring most commonly in the genital area. Perianal localization is less frequent and raises the problem of adequate management to reduce morbidity and the rate of recurrence. We report the cases of two male patients aged 45 and 57 years, who presented with perianal and buttock BLT for which large excisions were performed with satisfactory outcomes. We discuss the epidemiological and therapeutic aspects.

Keywords: Buschke–Löwenstein’s tumor, condyloma, perineum, verrucous carcinoma

Résumé

La tumeur de Buschke Lowenstein (TBL) est une tumeur cutanée viroinduite par l’infection à human papilloma virus (HPV) dont les génotypes 6,11 à faible potentiel oncogène sont présents dans plus de 90% des lésions condylomateuses. Les génotypes 16 et 18 se conjuguent aux facteurs liés à l’immunodépression et à l’irritation chronique et favorisent la croissance exo et endophytique et la transformation maligne. Elle est plus fréquente chez l’homme entre 40 et 60 ans et dans la région génitale. La localisation périanale est moins fréquente et pose le problème de la prise en charge adéquate pour réduire la morbidité et le taux de récurrence. Nous rapportons deux observations de patients âgés de 45 et 57 ans, de sexe masculine, présentant une TBL périanale et fessière pour laquelle une exérèse large et une cicatrisation dirigée étaient effectuées. Nous discutons les aspects épidémiologiques, thérapeutiques et évolutifs.

Mots clés: Condylome, Périnée, Tumeur Buschke Lowenstein, Carcinome verruqueux

Introduction

Condylomas are cutaneous or mucosal lesions induced by human papillomavirus (HPV) infection that produces isolated or clustered pseudoepitheliomatous proliferation.

They usually lie in the genital or perineal area. The increasing frequency runs parallel with risky sexual behaviors, in particular multiple sexual partners and anal coitus. Risky sexual behaviors, inadequate personal hygiene, and chronic infections favor the sexual transmission of HPV, of which genotypes 6, 11, 16, and 18 are involved in the occurrence of condylomatous lesions.^[1,2] They are well known in dermatology and venereology where medical treatment, cryotherapy, or

electrocoagulation are used for isolated or limited number of condylomas.

Many factors related to immunosuppression or chronic irritation can promote the transformation to the extensive form or giant acuminatum condyloma or Buschke–Löwenstein’s tumor (BLT). It is a rare clinical entity, however, with an incidence of less than 0.1% in the population.^[3] It occurs on the penis and scrotum in men, or the vulva in women, and more rarely in the perianal region. BLT is characterized by its vegetative development like a chicken comb, its impressive volume, its cauliflower-like appearance, its invasive, recurrent character, and its degenerative potential in preoperative or postoperative period if lesions persist. The perianal localization raises the problem of

**Diop Balla^{1,2,3},
Papa Abdoulaye
Ba^{2,3}, Ahmet Diouf³,
Baba NDiaye¹,
Serigne Modou
Sarre¹,
Chekna Sylla³**

¹Department of Surgery, Ouakam Military Hospital, Dakar;

²Department of General Surgery, Regional Hospital of Thiès,

³UFR Sciences de la Sante/Iba Der Thiam, University of Thiès, Sénégal

Received: 05-Feb-2021

Accepted: 05-Jan-2022

Published: 05-Mar-2022

Address for correspondence:

Prof. Diop Balla, Ouakam Military Hospital, UFR Sciences de la Sante, Iba Der Thiam University of Thiès, Thiès, Senegal.

E-mail: dballa33@yahoo.fr

Access this article online

Website:

www.jwacs-jcoac.org

DOI: 10.4103/jwas.jwas_5_22

Quick Response Code:



How to cite this article: Balla D, Ba PA, Diouf A, NDiaye B, Sarre SM, Sylla C. Peri-anal and genital localization of giant condyloma acuminatum or Buschke–Löwenstein’s Tumor: A report of two cases. J West Afr Coll Surg 2020;10:42-6.

This is an open access journal, and articles are distributed under the terms of the Creative Commons Attribution-NonCommercial-ShareAlike 4.0 License, which allows others to remix, tweak, and build upon the work non-commercially, as long as appropriate credit is given and the new creations are licensed under the identical terms.

For reprints contact: reprints@medknow.com

which surgical strategy to use, the depth of surgical excision, and whether or not to cover the lesion in order to reduce postoperative morbidity.

We report two cases of patients with perineal giant acuminatum condyloma and discuss the epidemiological and therapeutic aspects.

Case Reports

Case 1

A 44-year-old single male, expatriate living in Europe, was admitted on February 2017 with complaints of a large mass in the perianal region for more than 2 years. The mass had progressively increased in size and was making intimate personal hygiene increasingly difficult to maintain. He smoked cigarettes but did not drink alcohol.

Examination revealed a patient in good general condition who was not pale. Examination of the cardiovascular and respiratory systems and of the abdomen did not reveal any abnormalities. Perineal examination revealed a vegetative mass with cauliflower-like appearance on either side of the anus [Figure 1]. Digital rectal examination did not reveal any rectal extension. Locoregional examination didn't reveal any pathologic lymph nodes. Results of full blood count and renal function tests were normal. Retroviral (HIV1 + 2) and syphilis serology (TPHA) tests were negative.

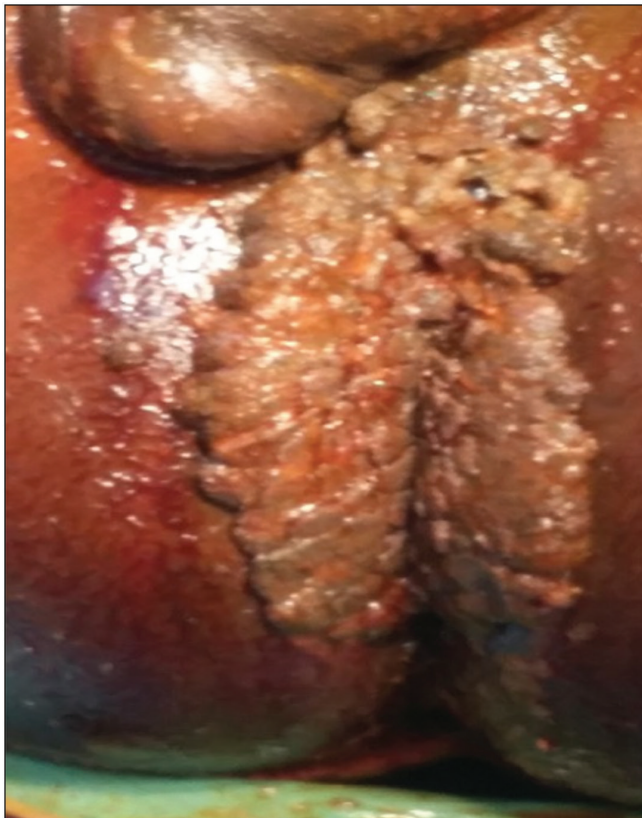

Figure 1: Perineal and perianal condyloma lesion

Rectosigmoidoscopy showed normal-looking anal and rectal canal. Biopsy was not performed. A one-step surgical excision, under locoregional anesthesia, with an electric scalpel, removing the entire tumoral mass was performed [Figure 2A and B]. The wound was left open for healing with twice-daily sitz baths with antiseptic solution combined with analgesics (paracetamol + caffeine) and antibiotics (amoxicillin + clavulanic acid). This allowed for healing after about two-and a half months. Histopathology confirmed BLT. It did not reveal any neoplastic transformation on the slides examined. At 28 months, there was no recurrence and there is an ongoing regular follow-up in the dermatology clinic.

Case 2

A 56-year-old man, a taxi driver, married with children was admitted on July 2019 with complaints of masses that had appeared for more than two years in the perineal, buttock, and genital areas. He did not report any urinary problems. He did not smoke cigarettes or drink alcohol. Clinical examination showed a patient in good general condition with no pallor. Examination of the cardiovascular and respiratory systems and abdomen was normal. The perineum was the site of vegetative, cauliflower-like, tumoral mass, on the circumference of the anus with scattered clusters on the penis, buttocks, and scrotum looking like Buschke–Löwenstein's giant condyloma [Figure 3A and B]. Digital rectal examination showed condylomatous

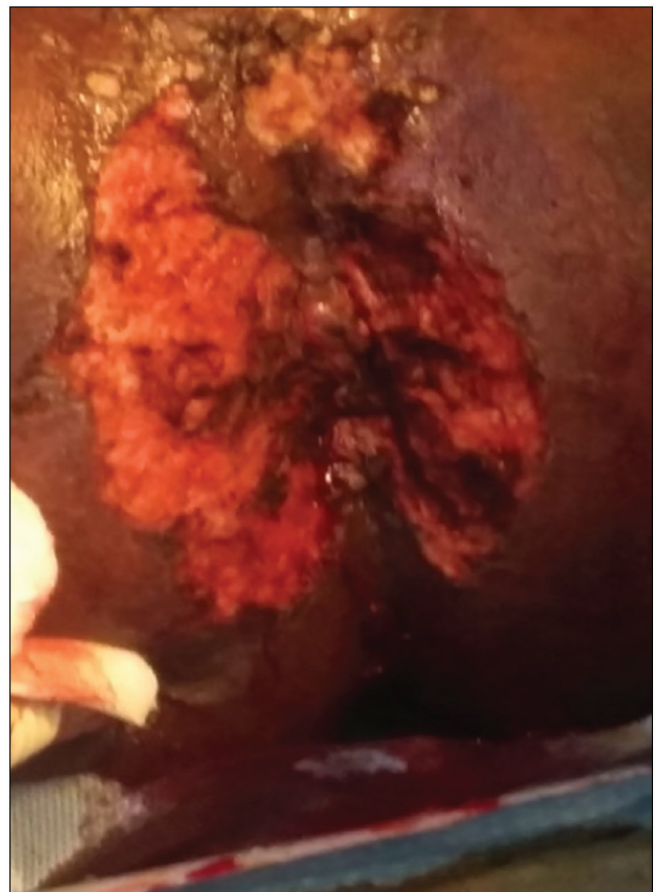


Figure 2: Perianal condyloma excision (postoperative aspect)

lesions on the anal margin. Locoregional examination did not reveal any evidence of pathologic lymph nodes. HIV, hepatitis B, and syphilis serology were negative. Full blood count and renal function tests showed normal results. Proctoscopy did not show any associated rectal lesion. Biopsy was not performed. Surgical excision, under locoregional anesthesia, using cold scalpel, electric scalpel, and aspiration was performed. It removed the perianal, scrotal, penile, and buttocks masses in one step, ensuring adequate excision margins [Figure 4].

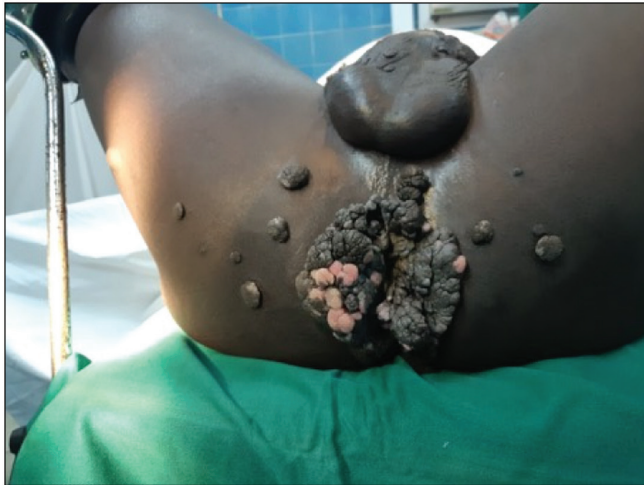

Figure 3: Perianal, buttock, scrotal, and penile cauliflower-like vegetative condyloma

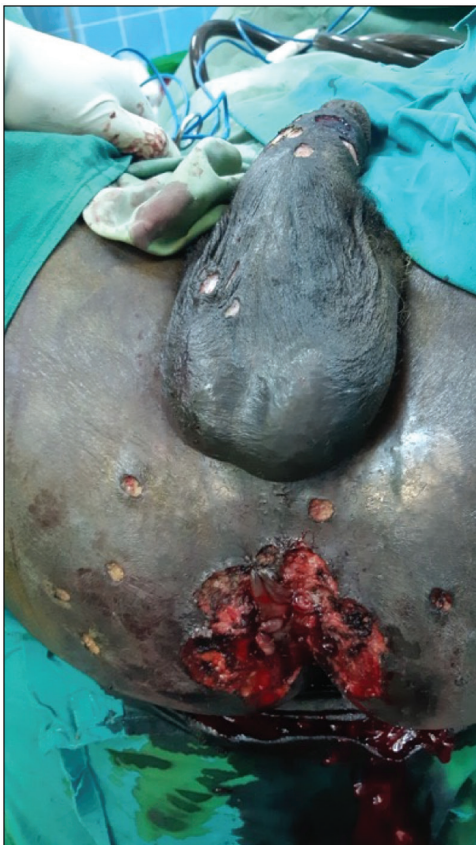

Figure 4: Perineal, buttock, and penile condyloma excision

Postoperatively, regular antiseptic solution for wounds care was performed until healing [Figure 5]. Histopathology confirmed BLT without signs of malignancy [Figure 6]. Regular follow-up has been ongoing and there has been no recurrence after 24 months.

Discussion

Approximately 70 HPV genotypes can infect the skin and mucous membranes, with a preference for transitional mucous membranes where they can cause pseudoepitheliomatous proliferation, tissue dysplasia, and neoplastic transformation.^[4,5] Genotypes 6, 11, 42, 43, and 44, found in more than 90% of cases, produce condylomatous lesions and are associated with a low oncogenic potential. On the contrary, genotypes 16 and 18 are associated with a high risk of dysplasia and squamous cell carcinoma.^[6,7]

Condylomatous lesions take the form of an isolated vegetative mass, initially rounded or filiform, evolving into clusters.^[1,5] The voluminous form or BLTs is much less frequent and is reported as clinical cases or short series in the literature. Evolution to the extensive form is favored by chronic local irritation, poor personal hygiene, and immunosuppression (HIV, immunosuppressive treatment, diabetes, chemotherapy, and alcoholism).^[2,6,8] Association with other sexually transmitted infections is common (HIV, syphilis, and chlamydia).

BLT affects all ages, with the majority of cases occurring between the 4th and 6th decades of life.^[2,9] It is more common in males, with a sex ratio of 2.7:1.^[2,9]

Transmission is primarily sexual through direct sexual contact. The promoting factors are well known and are mostly related to unsafe sexual practices.

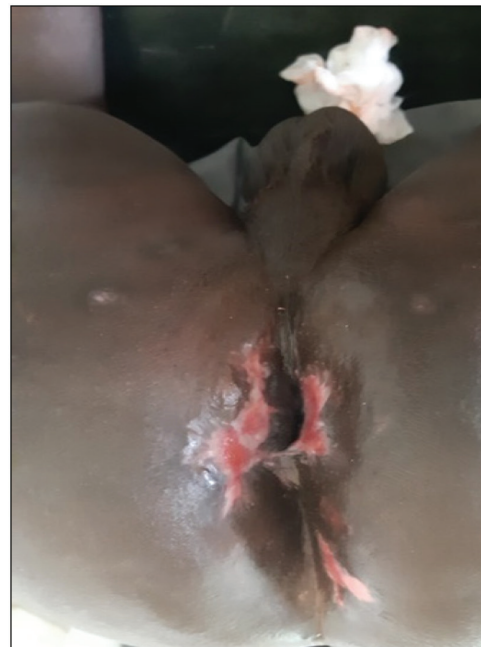

Figure 5: Two months' postoperative results

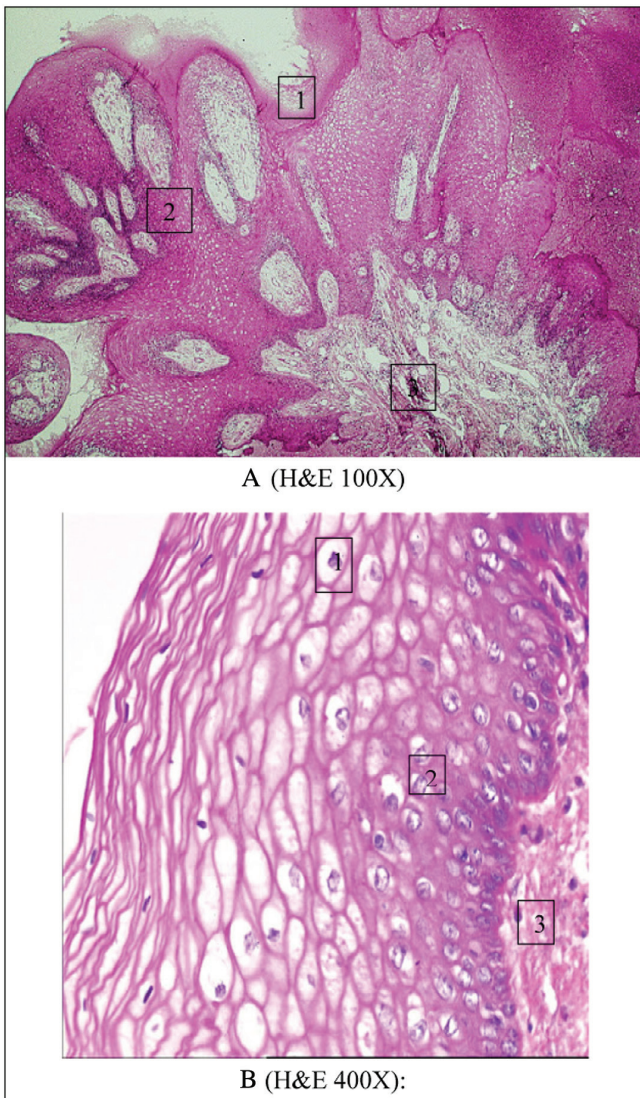


Figure 6: (A and B) Condyloma histological aspects (1 = hyperkeratosis and koilocyte, 2 = squamous epithelium acanthosis, and 3 = underlying connective tissue)

Transmission through water, clothing, gloves, and soiled material is also mentioned.^[10] In the pediatric population, transmission may occur as a result of sexual abuse or through mother-to-child transmission during vaginal delivery when the woman has genital condylomas.^[9]

BLT occurs mainly in wet areas and at mucocutaneous junctions. It is predominant in men on the penis, urethral, and scrotal areas in 94% of cases, and in women on the vulva in 90% of cases.^[11] Anoperineal localization of condyloma occurs in 10%–17% of the cases, favored by anal intercourse and oral sex.^[11,12] It can also be the result of extensive development of a genital condyloma, especially in women. In our two patients, the preferential localization was perianal, which may be consistent with anal coitus. In the second case, the clusters of condylomas were also diffuse on the buttocks, penis, and thighs.

Condylomas can concomitantly invade the anal and rectal mucosa and predispose to long-term recurrence and neoplastic transformation. The work-up should include a search for associated infections (HIV, syphilis, chlamydia, and viral hepatitis) and a lower gastrointestinal endoscopy. Serologies were negative in both patients and the rectal mucosa was normal.

Preoperative biopsy is recommended in order to look for a risk of malignant transformation which can occur in 8.5%–23.8% of cases.^[12] However, it is inconsistently performed and may include false negatives related to the volume of the tumor. The presence of bleeding, basal infiltration, or lymphadenopathy should raise the suspicion of neoplastic transformation and encourage targeted biopsies.^[1]

It is a tumor with both exophytic and endophytic growth that can deeply infiltrate structures, leading to the suspicion of malignant transformation to microinvasive carcinoma or in other cases to invasive keratinizing squamous cell carcinoma.^[4,6]

Therapeutically, the extensive form responds exceptionally well to medical treatment.^[1,11] Topical (podophyllin, imiquimod, 5FU, and bleomycin) or intralesional (5FU, bleomycin, and interferon-alpha) application is prescribed in minor carcinomas. Rare cases of total regression of BLT have been reported by Hum *et al.*^[13] and Dinleyici *et al.*^[14] after application of imiquimod 3.75% three times per week.

Radiotherapy is controversial. Its combination with chemotherapy also gives inconsistent results. It is indicated in degenerated forms or with contraindications to surgery. It may be administered with 5FU/mitomycin or 5FU/cisplatin, and total or partial regression of condylomas has been reported in some series.^[15,16]

Surgical treatment is the gold standard, although it can be disfiguring. The surgical excision must be large and must involve all macroscopic lesions with adequate resection margins. No additional procedure is useful in non-degenerative forms. Protection by smoke aspiration, cold scalpel removal, and coagulation avoids the diffusion of viral particles known to be contagious. In our two patients, the lesions were non-invasive and easily excised with a cold scalpel followed by hemostasis. In the absence of invasion and obvious degeneration, surgical excision is sufficient in most cases and healing by secondary intention is the most widely used method in the literature. It involves twice-daily care (by sitz bath with antiseptic) with a healing time of more than 2 months and sometimes predisposes to cicatrization.^[17,18] Flap coverage shortens the healing time and improves the aesthetic results.^[4,18]

Recurrence may occur in 50% of cases, due to incomplete excision or the progressive development of microscopic lesions.^[9,11] The average recurrence time is 10 months. Topical adjuvant therapy is proposed in cases of remaining lesions with variable results. However, recurrence occurs in 67% of cases after medical treatment.^[11]

Conclusion

BLT in its perianal location is less frequent. It is a tumor of viral origin that may be associated with unsafe sexual practices. It has sometimes impressive exophytic growth and endophytic development that may suggest malignancy. The search for an intrarectal extension by endoscopy is essential. Treatment by wide, sufficiently deep excision is the most effective treatment and reduces the recurrence rate.

Financial support and sponsorship

Nil.

Conflicts of interest

There are no conflicts of interest.

References

1. EL Mejjad A, Dakir M, Tahiri M, Attar H, Cherkaoui A, Araki A, Aboutaie R, Meziane F. Le condylome acuminé géant - tumeur de Buschke Lowenstein (à...propos de 3 cas) *Prog Urol* 2003;13:513-7.
2. Njoumi N, Tarchouli M, Ratbi MB, Elochi MR, Yamoul R, Hachi H, *et al.* La tumeur de Buschke–Lowenstein anorectale: À propos de 16 cas et revue de la littérature. *Pan Afr Med J* 2013;16:131-5.
3. Bocquet H, Bagot M. Tumeurs bénignes d'origine virale. *Dermatologie. Encycl Med Chir. Paris: Elsevier; 1998. p. 12-725.*
4. Zekan J, Petrovic D, El-Safadi S, Banovic M, Hulina D, Hrgovic Z. A surgical approach to giant condyloma (Buschke–Löwenstein tumour) with underlying superficial vulvar carcinoma: A case report. *Oncol Lett* 2013;5:541-3.
5. Stanley M. Immune responses to human papillomavirus. *Vaccine* 2006;24:S16-22.
6. Aubin F, Prétet JL, Jacquard AC, Saunier M, Carcopino X, Jaroud F, *et al.*; EDiTH Study Group. Human papillomavirus genotype distribution in external acuminata condylomata: A Large French National Study (EDiTH IV). *Clin Infect Dis* 2008;47:610-5.
7. Pfister H. The role of human papillomavirus in anogenital cancer. *Obstet Gynecol Clin North America* 1996;23:579-93.
8. Kreuter A, Potthoff A, Brockmeyer NH, Gambichler T, Swoboda J, Stücker M, *et al.*; German Competence Network HIV/AIDS. Anal carcinoma in human immunodeficiency virus-positive men: Results of a prospective study from Germany. *Br J Dermatol* 2010;162:1269-77.
9. Trombetta LJ, Place RJ. Giant condyloma acuminatum of the anorectum: Trends in epidemiology and management: Report of a case and review of the literature. *Dis Colon Rectum* 2001;44:1878-86.
10. Zhenhui X, Bakouboula G, Mabanza A, Bitoky Y. Condylome acuminé et grossesse: Conduite à tenir à propos d'un cas de condylome géant ou tumeur de Buschke–Lowenstein. *Médecine d'Afrique Noire* 1996;43:304-6.
11. Chu QD, Vezeridis P, Libbey NP, Wanebo HJ. Giant condyloma acuminatum (Buschke–Lowenstein tumor) of the anorectal and perianal regions: Analysis of 42 cases. *Dis Colon Rectum* 1994;37:950-7.
12. Reichenbach I, Koebell A, Foliguet B, Hatier M, Mascotti J, Landes P. Tumeur de Buschke et lowenstein à propos d'un cas féminin. *J Gynecol Obstet Biol Reprod* 1995;24:491-5.
13. Hum M, Chow E, Schuurmans N, Dytoc M. Case of giant vulvar condyloma acuminata successfully treated with imiquimod 3.75% cream: A case report. *SAGE Open Med Case Rep* 2018;6:1-5.
14. Dinleyici M, Saracoglu N, Eren M, Kiliç Ö, Ciftci E, Dinleyici EC, *et al.* Giant condyloma acuminata due to human papillomavirus type 16 in an infant successfully treated with topical imiquimod therapy. *Dermatol Reports* 2015;7:6134.
15. Hyacinthe M, Karl R, Coppola D, Goodgame T, Redwood W, Goldenfarb P, *et al.* Squamous-cell carcinoma of the pelvis in a giant condyloma acuminatum: Use of neoadjuvant chemoradiation and surgical resection: Report of a case. *Dis Colon Rectum* 1998;41:1450-3.
16. Tytherleigh MG, Birtle AJ, Cohen CE, Glynne-Jones R, Livingstone J, Gilbert J. Combined surgery and chemoradiation as a treatment for the Buschke–Löwenstein tumour. *Surgeon* 2006;4:378-83.
17. Mingolla GP, Poti O, Carbotta G, Marra C, Borgia G, De Giorgi D. Reconstructive surgery in anal giant condyloma: Report of two cases. *Int J Surg Case Rep* 2013;4:1088-90.
18. Skowrońska-Piekarska U, Kościński Buschke T. Lowenstein tumor resection with simultaneous reconstruction of extensive tissue losses: Case report. *BMC Surg* 2015;15:41.