

Proliferative Fasciitis/Myositis Involving the Facial Muscles Including the Masseter Muscle: A Rare Cause of Trismus

Authors' Contribution:
Study Design A
Data Collection B
Statistical Analysis C
Data Interpretation D
Manuscript Preparation E
Literature Search F
Funds Collection G

ABDEF **Tomoyo M. Nishi**
ABDEF **Shun Yamashita**
ADEF **Yuka N. Hirakawa**
ADEF **Naoko E. Katsuki**
ABDEFG **Masaki Tago**
ADEG **Shu-ichi Yamashita**

Department of General Medicine, Saga University Hospital, Saga City, Saga, Japan

Corresponding Author: Masaki Tago, e-mail: tagomas@cc.saga-u.ac.jp
Conflict of interest: None declared

Patient: Male, 50
Final Diagnosis: Proliferative fasciitis/myositis
Symptoms: Facial swelling • fever • trismus
Medication: —
Clinical Procedure: Biopsy
Specialty: Pathology





Objective: Rare disease
Background: Proliferative fasciitis/myositis is a benign disease that can be treated conservatively. However, some patients are mistakenly treated surgically because of a misdiagnosis of the condition as a malignant tumor.

Case Report: A 50-year-old Japanese man developed swelling in his left cheek 12 days before admission; he developed a fever and trismus 3 days later. He was admitted to our hospital because of worsening of his condition despite treatment with sitafloxacin for 5 days and needle-aspiration drainage. On admission, he had a fever of 38.1°C, swelling in his left cheek spreading to the lower jaw, and several dental caries. Although ceftriaxone and clindamycin were administered for 7 days because an odontogenic infection was suspected, his condition did not improve. T2-weighted magnetic resonance imaging of the facial muscles on Day 5 of hospitalization showed swelling and high-intensity signals in the left masseter, temporalis, and pterygoid muscles. Macroscopic findings from a biopsy of the left temporalis muscle performed on Day 17 showed white and thickened fascia. Histopathological examination revealed fibrous hyperplasia of the fascia, increased fibrous connective tissue between muscle fibers, and infiltration of inflammatory cells, providing not a definite but a compatible diagnosis of proliferative fasciitis/myositis. Beginning on Day 18, the patient's fever lessened with gradual improvement of his facial swelling and trismus.

Conclusions: It is imperative to include proliferative fasciitis/myositis as a possible diagnosis when patients present with facial swelling and trismus of unknown cause.

MeSH Keywords: Fasciitis • Masseter Muscle • Myositis • Pterygoid Muscles • Trismus

Full-text PDF: <https://www.amjcaserep.com/abstract/index/idArt/917193>

 1587  1  4  18



Background

Proliferative fasciitis/myositis is a benign fibroproliferative disease that develops rapidly within 1–3 weeks from onset, eventually resolving spontaneously in approximately 6 weeks [1–3]. Cases of proliferative myositis developing in the head and neck are rare, with only approximately 100 reported cases in the last 45 years [4]. To our knowledge, 28 cases of proliferative fasciitis/myositis in the head and neck have been reported in Japan, 18 of which occurred in the neck muscles including the sternocleidomastoid muscle, and 10 in the facial muscles, as in our patient [5,6]. Cases occurring in the masseter muscle are so rare that only 1 case has been reported in Japan [6]. Because the affected muscles are swollen, involvement of the sternocleidomastoid muscle could result in limited neck movement, and involvement of the masseter muscle could result in trismus [3,6], usually without pain or tenderness [6,7]. Although proliferative fasciitis/myositis is usually treated conservatively, some patients have been treated with wide surgical resection, radiation therapy, or chemotherapy, because of an inaccurate diagnosis resulting from the difficulty of differentiating fasciitis/myositis from mesenchymal malignancies using imaging studies and even histological examination, and the rarity of the disease [7–9].

Patients with proliferative fasciitis/myositis could be seen in general internal medicine departments, especially when patients present with fever, although the condition is usually

diagnosed in otolaryngology and plastic surgery departments, in Japan [1–3,6,8,10,11]. Proliferative fasciitis/myositis is one of the most important diseases to diagnose correctly when patients present with facial swelling or trismus, to avoid excessive treatment.

We report a rare case of proliferative fasciitis/myositis in a patient with facial swelling and trismus secondary to involvement of the facial muscles, which resolved solely with nonsteroidal anti-inflammatory therapy.

Case Report

A 50-year-old man with a smoking history of 540 pack-years, and with no other remarkable history, developed swelling in his left cheek. Three days after onset, he developed a fever, headache, and trismus and visited a primary physician 5 days later. Despite administration of sitafloxacin at 100 mg/day for 5 days, his condition did not improve. After needle puncture was performed at a local dental clinic to drain purulent discharge without success, and because dental infection was suspected because of the swelling of the soft tissue surrounding his left upper and lower teeth, the patient was referred and admitted to the Department of General Medicine of our hospital, Saga University Hospital, Japan. On admission, his body temperature was 38.1°C, his pulse rate was 80 beats/minute, his blood pressure was 122/74 mmHg, his respiratory rate was

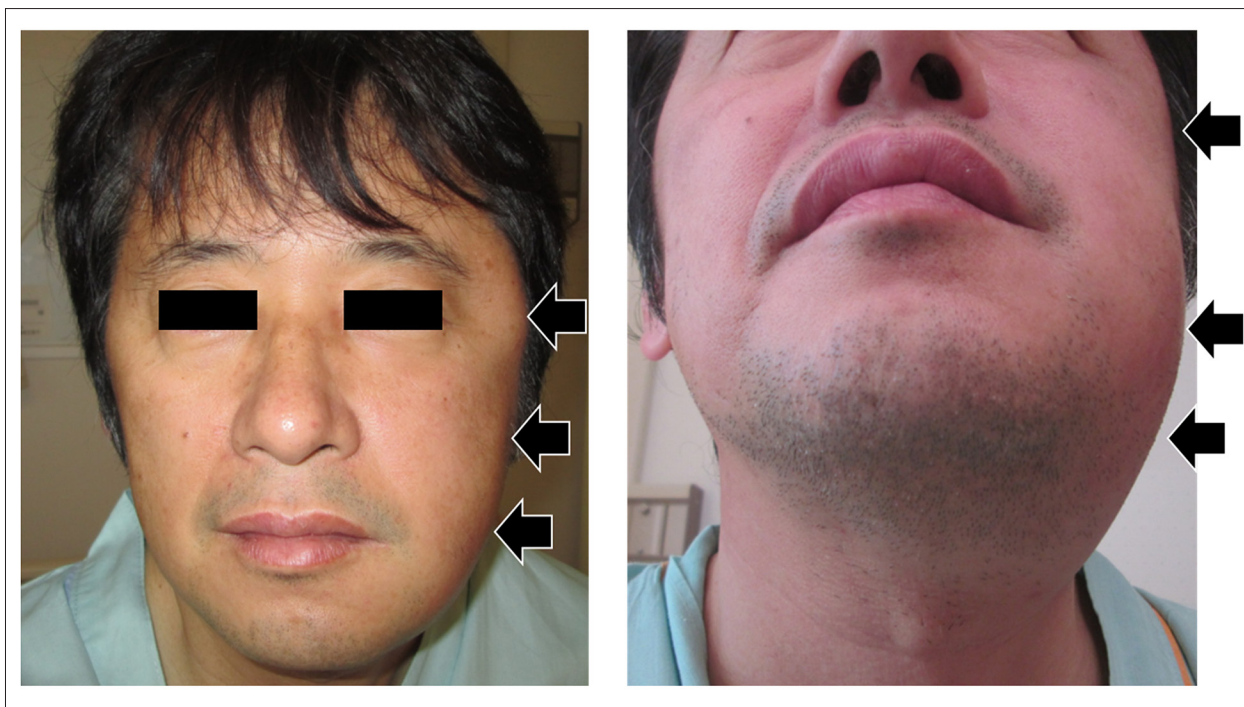


Figure 1. Swelling on the left side of the patient's face. The swelling on the left cheek spreads from the left temporal area to the cheek and lower jaw on the same side (arrows).

Table 1. The patient's laboratory data on admission.

Complete blood count			Biochemistry			Immune evaluation		
White blood cells	12.5	×10 ³ /μL	T-Bil	0.8	mg/dL	RF	7	mg/dL
Neutrophils	87.5	%	AST	36	U/L	ANA	<40	
Lymphocytes	8.3	%	ALT	41	U/L	Anti-SSA/SSB-Ab	<1.0	
Red blood cells	432	×10 ⁴ /μL	LDH	165	U/L	Ferritin	700	ng/mL
Hemoglobin	12.9	g/dL	ALP	563	U/L	sIL-2R	318	U/mL
Hematocrit	37.8	%	γ-GTP	240	U/L	HBs-Ag	319	IU/mL
Platelets	46.6	×10 ⁴ /μL	Amylase	53	U/L	ASL	75	IU/mL
Coagulation system			CK	54	U/L	Procalcitonin	0.05	ng/mL
PT-INR	1.25		Sodium	137	mEq/L	Viral antibodies	(-)	
APTT	43.8	seconds	Potassium	4.0	mEq/L	β-D-Glucan	(-)	
Fibrinogen	674.4	mg/dL	Chloride	99	mEq/L	Bacteriological examination		
FDP	3.7	μg/mL	CRP	12.5	mg/dL	Blood culture	(-)	
D-dimer	0.98	μg/mL	IgG	1170	mg/dl	Urinalysis (qualitative)		
Biochemistry			IgA	417	mg/dl	pH	7.0	
Total protein	6.8	g/dL	IgM	87	mg/dL	Specific gravity	Not measured	
Albumin	3.1	g/dL	IgG4	78.2	mg/dL	Occult blood	(-)	
BUN	10.4	mg/dL	C3	169	mg/dL	Protein	(-)	
Creatinine	0.65	mg/dL	C4	36	mg/dL	White blood cells	(-)	

PT-INR – prothrombin time-international normalized ratio; APTT – activated partial thromboplastin time; FDP – fibrin/fibrinogen degradation products; BUN – blood urea nitrogen; T-Bil – total bilirubin; AST – aspartate aminotransferase; ALT – alanine aminotransferase; LDH – lactate dehydrogenase; ALP – alkaline phosphatase; γ-GTP – γ-glutamyltransferase; CK – creatine kinase; CRP – C-reactive protein; IgG – immunoglobulin G; IgA – immunoglobulin A; IgM – immunoglobulin M; IgG4 – immunoglobulin G4; C3 – complement component 3; C4 – complement component 4; RF – rheumatoid factor; ANA – antinuclear antibody; Anti-SSA/SSB-Ab – anti-Sjögren's-syndrome-related antigen A/anti-Sjögren's-syndrome-related antigen B; sIL-2R – soluble interleukin-2 receptor; HBs-Ag – hepatitis B surface antigen; ASL – antistreptolysin O. Viral antibodies including cytomegalovirus, Epstein-Barr virus, herpes simplex virus, mumps virus, and hepatitis C virus were negative.

12 breaths/minute, and his oxygen saturation was 98% on room air. Physical examination showed numerous dental caries in his oral cavity and swelling of the left cheek reaching to the lower jaw without sensations of burning or tenderness (Figure 1). The patient had no pharyngeal redness, bruit over the carotid arteries, or cervical lymphadenopathy. Laboratory findings on admission are shown in Table 1. The patient had a white blood cell count of 12.5×10³/μL (neutrophils: 87.5%), C-reactive protein level of 12.5 mg/dL, and procalcitonin level of 0.05 ng/mL. He had no increased levels of immunoglobulin G4, antibodies against mumps virus, herpes simplex virus, syphilis, human immunodeficiency virus, mycoplasma, cytomegalovirus, or Epstein-Barr virus and no autoantibodies such as anti-nuclear antibody, anti-Sjögren's-syndrome-related antigen A, anti-Sjögren's-syndrome-related antigen B, myeloperoxidase-antineutrophil cytoplasmic antibody, or proteinase 3-antineutrophil cytoplasmic antibody. Urinalysis showed no abnormalities. Computed

tomography of the patient's head and neck with contrast enhancement showed swelling of the left masseter, temporalis, pterygoid muscles, and soft tissue around the left molar and wisdom tooth and the left masseter muscle, without lymphadenopathy, abscess, or thrombosis in bilateral internal jugular veins (Figure 2). Magnetic resonance imaging (MRI) of the patient's head and neck with contrast enhancement revealed swelling and high-intensity signals on T2-weighted and diffusion-weighted images in the left masseter, temporalis, and pterygoid muscle groups (Figure 3). We didn't perform electromyography. Administration of ceftriaxone at 2 g/day and clindamycin at 1200 mg/day for suspected spreading of an infection from the pericoronitis of the patient's wisdom tooth failed to reduce his fever. Left wisdom tooth extraction was performed with a change in antibiotics to ampicillin/sulbactam at 12 g/day, which did not improve his facial swelling. Because an infectious etiology was considered unlikely at this point, biopsies from the

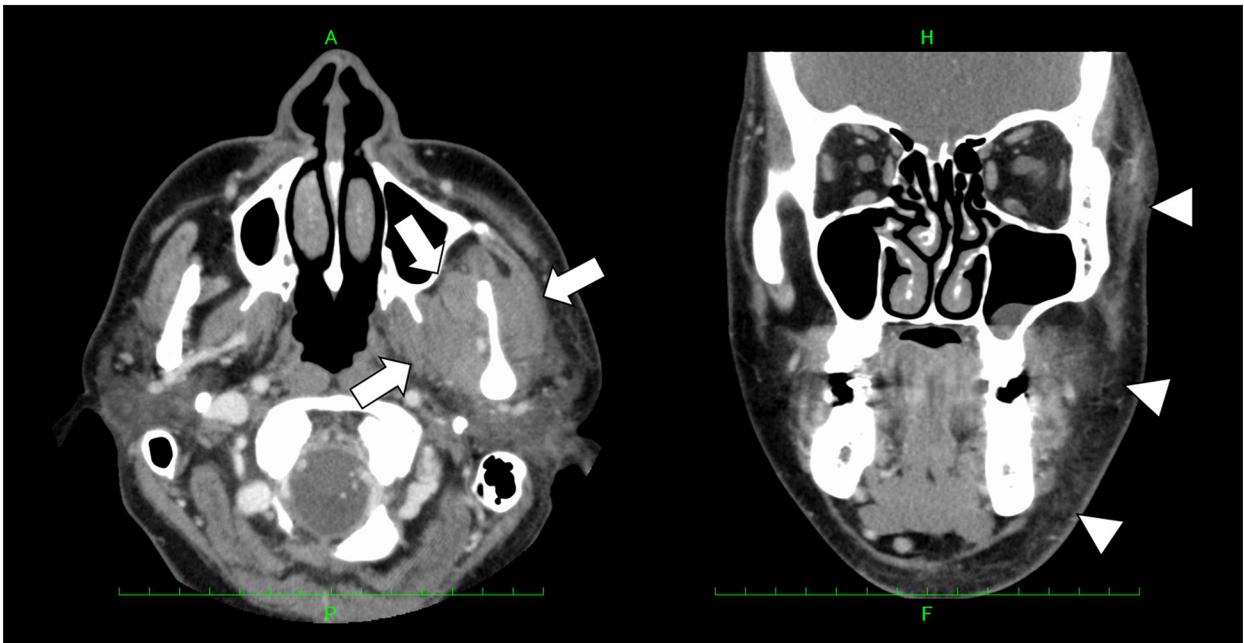


Figure 2. Computed tomography of the patient's head and neck with contrast enhancement performed on Day 1 of hospitalization showing swelling of the left masseter, temporalis, pterygoid muscles (arrows), and soft tissues around the left molar and wisdom tooth and the left masseter muscle (arrowheads) without lymphadenopathy, abscess, or thrombosis in bilateral internal jugular veins.

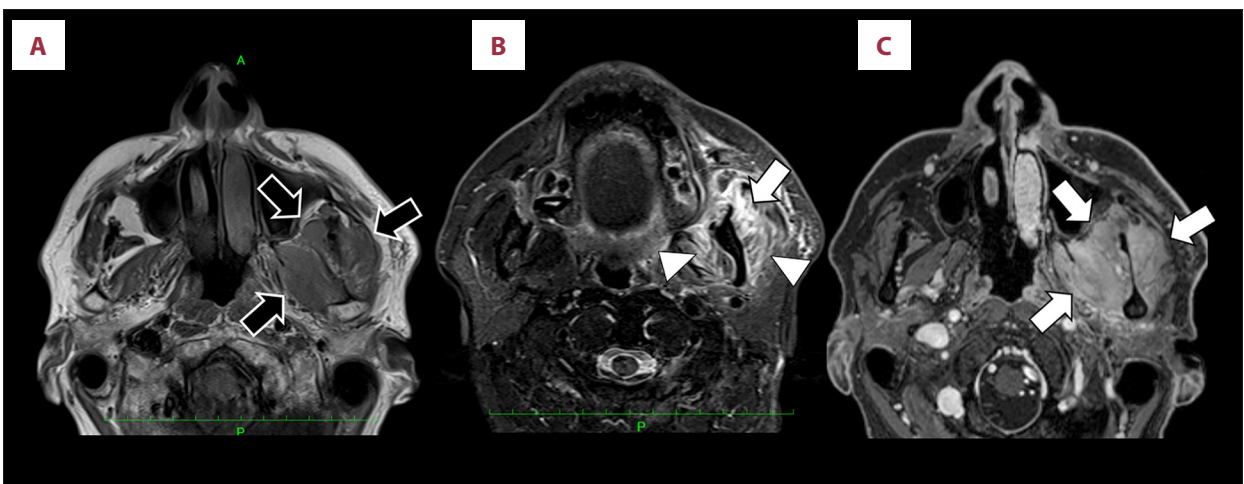


Figure 3. Magnetic resonance imaging of the patient's head and neck with contrast enhancement performed on Day 7 of hospitalization. (A) T1-weighted image, (B) T2-weighted image, (C) fat-suppressed T1-weighted image with contrast enhancement. These images show the swelling; low-intensity signals in the left masseter, temporalis, and pterygoid muscles on T1-weighted images (black arrows, A); high-intensity signals in these muscles on T2-weighted images (white arrow, B); and enhancement by gadolinium on fat-suppressed T1-weighted images (white arrows, C). A checkerboard pattern is seen, which consists of a mixture of low- and high-intensity signals on T2-weighted images created by the presence of residual uninvolved muscle fibers (arrowheads, B).

patient's left temporal region, namely, skin, subcutaneous tissue, temporalis muscle, fascia, and superficial temporal artery, were performed on Day 17 of hospitalization to rule out vasculitis or malignancies. Macroscopically, whitish and thickened fascia of approximately 5-mm thickness was seen. Histopathological

examination showed fibrous thickening of the fascia with full-thickness infiltration of inflammatory cells. Hyperplasia of fibrous connective tissues and infiltration of inflammatory cells without malignant cells were present between muscle fibers (Figure 4). We didn't perform immunohistochemical studies to

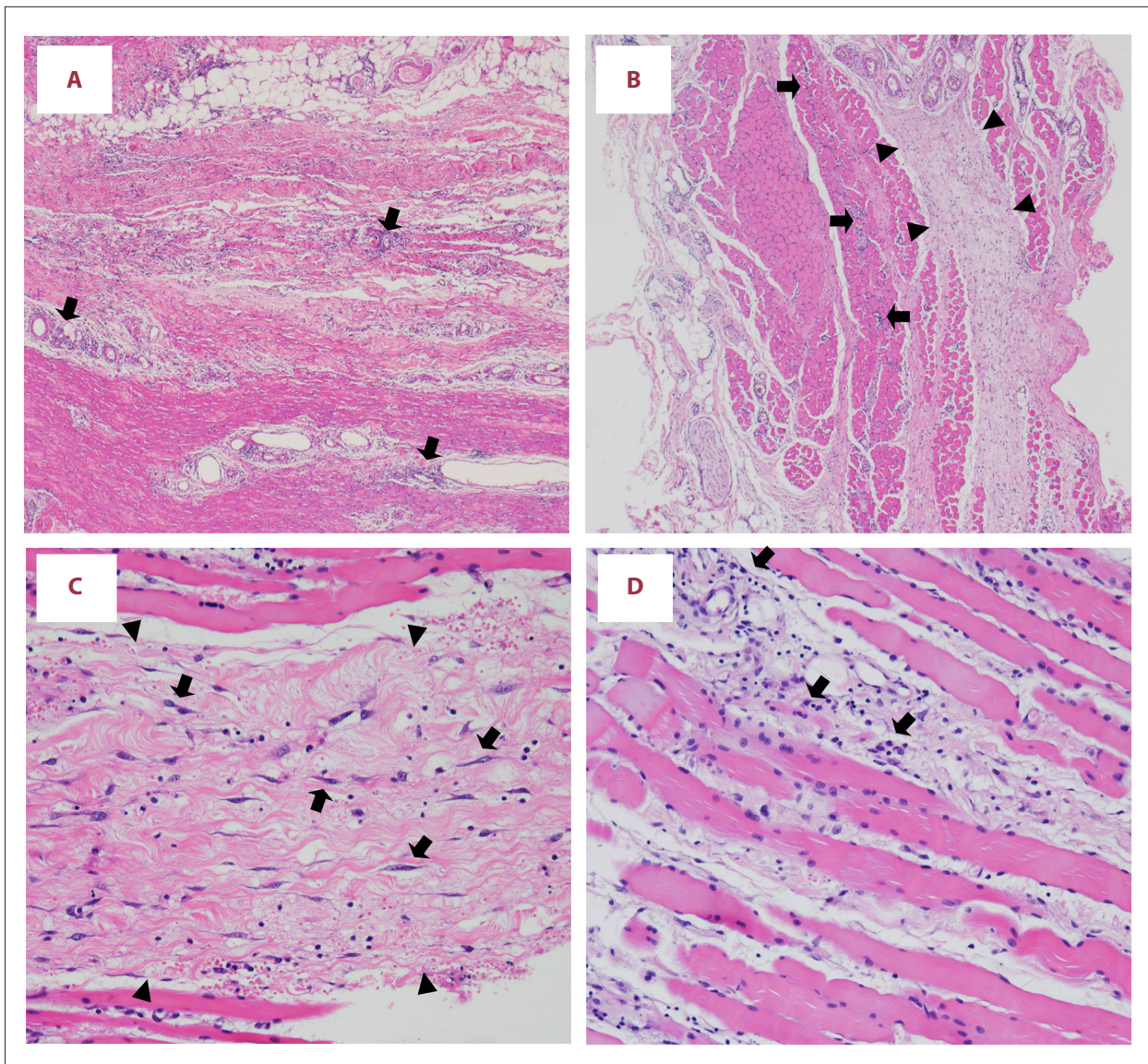


Figure 4. Histopathological findings of the temporalis muscle. (A) temporal fascia (hematoxylin and eosin staining, 2×); (B) temporalis muscle (hematoxylin and eosin staining, 2×); (C, D) temporalis muscle (hematoxylin and eosin staining, 10×). Fibrously thickened fascia with full-thickness infiltration by inflammatory cells is seen (arrows, A). Hyperplasia of fibrous connective tissues (arrowheads, B, C), fibroblasts (arrows, C) and infiltration of inflammatory cells (arrows, B, D) are present between muscle fibers. The type of inflammatory cells are mainly lymphocytes with a few plasma cells and neutrophils.

confirm the increase of sarcolemmal expression of HLA-1 in muscle biopsy. On the basis of these findings, we made the diagnosis of proliferative fasciitis/myositis. Antibiotics were stopped immediately, and administration of loxoprofen at 180 mg/day was started on Day 18 of hospitalization, which reduced the patient's fever. His other symptoms improved gradually, namely, the facial swelling, trismus, increased white blood cell count, and C-reactive protein levels. He was discharged on Day 28 of hospitalization, and no symptoms or signs have recurred in the 2 years since discharge despite discontinuing oral loxoprofen 1 month after discharge.

Discussion

Although proliferative fasciitis/myositis is a difficult disease to distinguish from some malignancies based on clinical or even histopathological findings, there are certain key clinical features to make a correct diagnosis. The peak age of onset of proliferative fasciitis/myositis is in patients' early 50s without significant sexual difference in incidence [1–3,7,10,12]. Lesion swelling begins to decrease an average of 3.5 weeks after onset, and resolves approximately 6 weeks from onset with conservative treatment alone, and recurrence has never been

reported [1]. Although the cause of the disease is considered to be a response of the connective tissue to mechanical stimulation, cases apparently preceded by mechanical injuries account for only 20–30% of cases, and many cases occur without a known cause [12–14]. Our patient presented with some of the key clinical characteristics, namely, his age of 50 years, the timing of decreased swelling beginning approximately 4 weeks from onset, and complete resolution of the swelling at approximately 17 weeks with conservative therapy limited to nonsteroidal anti-inflammatory drugs (NSAIDs), without recurrence.

MRI of proliferative fasciitis/myositis shows low- to iso-intense signals on T1-weighted images and high-intensity signals on T2-weighted images with contrast enhancement by gadolinium on fat-suppressed T1-weighted images [15,16]. A checkerboard pattern may be observed in the lesion as a mixture of low- and high-intensity signals on T2-weighted images, which is considered to be created by the presence of residual uninvolved muscle fibers [16]. In our patient, MRI showed a checkerboard pattern and typical findings without bone infiltration or destruction suggesting malignant tumors (Figure 3). Histopathological findings also showed characteristic features. Macroscopically, a distinguishing pale gray to white color is seen over the lesion reaching from fascia to muscle [2,3,7,12,17], which was also present in our patient. The most diagnostic histopathological characteristics are proliferation of immature fibroblast-like cells and the presence of basophilic ganglion-like giant cells [1,7,12]. Proliferative fasciitis/myositis may be misdiagnosed as a malignant tumor because findings can mimic invasion of normal muscle tissues secondary to the production of abundant collagen fibers [17], and the condition may be confused with malignant fibrous histiocytoma or rhabdomyosarcoma because of the presence of giant cells [7]. In fact, several patients reportedly underwent surgical resection secondary to misdiagnosis of their swellings as malignant tumors because the lesions were adhered to fascia or malignant invasion into surrounding tissues was interpreted in the histopathological findings [9]. In our patient, the macroscopic findings showed no adhesion between fascia and muscle tissues. The histopathological findings showed infiltration of inflammatory cells and proliferation of fibrous connective tissue, which were consistent with proliferative fasciitis/myositis [17,18]. Even without the presence of ganglion-like giant cells, the typical findings

in our patient indicated the diagnosis of proliferative fasciitis/myositis. We believe the reason for the absence of ganglion-like giant cells in our patient was that biopsy was performed on Day 28 of his illness when peak inflammation had passed, which was suggested by the fact that his fever began to decrease on approximately Day 23 of his illness. One published case report of proliferative fasciitis/myositis with a similar clinical course to our patient also showed no basophilic ganglion-like giant cells with a biopsy performed on Day 25 of the patient's illness [6].

Treatments for proliferative fasciitis/myositis consist mainly of symptomatic therapy or watchful waiting [1,3,6]. Although some case reports discuss using analgesic antipyretic agents such as NSAIDs or corticosteroids [1,3,6,10], the effect of these medications was unclear because patients' symptoms improved several weeks after beginning the drugs [3,10]. Although our patient's symptoms and signs began to improve immediately after beginning NSAIDs, improvement might have resulted from the natural course of the disease (spontaneous remission). It might be appropriate to consider watchful waiting and symptomatic treatment for several weeks in a stable patient with facial swelling and trismus, in which malignancy has not been completely ruled out, even by biopsy, if the lesion is localized to the fascia and muscles without definitive findings of malignancy such as bone destruction.

Conclusions

Proliferative fasciitis/myositis, a usually benign illness, should be included as a differential diagnosis when patients present with facial swelling and trismus of unknown cause, to avoid unnecessary invasive treatments.

Acknowledgements

We thank Jane Charbonneau, DVM, from Edanz Group (www.edanzediting.com/ac) for editing a draft of this manuscript.

Conflict of interest

None.

References:

1. Tanimitsu N, Hisayuki A, Nagasawa A: A case of proliferative myositis arising in the sternocleidomastoid muscle. *Pract Otorhinolaryngol*, 2002; 95: 753–59
2. Takahashi E, Mori H, Umeda T, Hata Y: [A case of proliferative fasciitis developing on the fingers]. *J Jpn PRS*, 2006; 26: 118–21 [in Japanese]
3. Sumi I, Kawabata I, Watanabe K, Kinoshita M: A case report of proliferative myositis of bilateral sternocleidomastoid muscles. *Pract Otorhinolaryngol*, 1998; 91: 851–56
4. Fauser C, Nahrig J, Niedermeyer HP, Arnold W: Proliferative myositis: A rare pseudomalignant tumor of the head and neck. *Arch Otolaryngol Head Neck Surg*, 2008; 134: 437–40
5. Itoh K, Mizunaga H, Ishigaki Y et al: A case of proliferative myositis which suspected tumor of the minor salivary glands origin. *Hosp Dent Oral-Maxillofac Surg*, 2006; 18: 915–1664
6. Onuma H, Terayama Y, Sakai N, Sugauma T: A case report of proliferative myositis of the masseter muscle. *Pract Otorhinolaryngol*, 2002; 95: 753–59

7. Enzinger FM, Dulcey F: Proliferative myositis. Report of thirty-three cases. *Cancer*, 1967; 20: 2213–23
8. Kuroda M: [A case of proliferative myositis developing on the trapezius.] *Jpn PRS*, 2009; 29: 563–66 [in Japanese]
9. Oomukai T, Ishida T, Takami M et al: Retrospective study of nodular fasciitis, proliferative fasciitis and proliferative myositis. *Cent JPN J Orthop Traumat*, 1990; 33: 2437–39
10. Mikuni H, Iizuka K, Kawanami M et al: Proliferative myositis of sternocleidomastoid muscle; A case report. *Pract Otorhinolaryngol*, 1991; 84: 1593–97
11. Oka R, Ogawa Y, Ubukata Y: A case report of proliferative myositis of the sternocleidomastoid muscle. *The Journal of the Nissei Hospital*, 1991; 19: 201–3
12. Chung EB, Enzinger FM: Proliferative fasciitis. *Cancer*, 1975; 36: 1450–58
13. Gokel JM, Meister P, Hubner G: Proliferative myositis. *Virchows Arch Abt A*, 1975; 367: 345–52
14. Dehari R, Tsuchiya T, Motoyama T: Proliferative myositis of the forearm. *Jpn J Diagn Pathol*, 2001; 18: 308–10
15. Yiğit H, Turgut AT, Koşar P et al: Proliferative myositis presenting with a checkerboard-like pattern on CT. *Diagn Interv Radiol*, 2009; 15: 139–42
16. Pagonidis K, Raissaki M, Gourtsoyiannis N: Proliferative myositis: Value of imaging. *J Comput Assist Tomogr*, 2005; 29: 108–11
17. Kobayashi S, Omori M, Ootsuki Y: [Proliferative myositis confused with a mesenchymal malignant tumor.] *Japanese Journal of Cancer Clinics*, 1981; 27: 1243–46 [in Japanese]
18. Fujiwara M, Iizuka Y, Yamada S et al: Report of two cases of proliferative myositis. *Jpn Soc Clin Cytol*, 1991; 30: 100–7