

Inferior alveolar nerve canal position among South Indians: A cone beam computed tomographic pilot study

Access this article online

Website:

www.amsjournal.com

DOI:

10.4103/2231-0746.95319

Quick Response Code:



S. M. Balaji, N. R. Krishnaswamy¹, S. Manoj Kumar², Thavarajah Rooban²

Balaji Dental and Craniofacial Hospital, Teynampet, Chennai, ¹Department of Orthodontics and Craniofacial Orthopedics, Ragas Dental College and Hospital, Uthandi, Chennai, ²Quality Diagnostics, Alwarpet, Chennai, Tamil Nadu, India

Address for correspondence:

Prof. S. M. Balaji, Consultant Craniofacial Surgeon and Director,
Balaji Dental and Craniofacial Hospital, 30, KB Dasan Road,
Teynampet, Chennai – 600 018, Tamil Nadu, India.
E-mail: smbalaji@gmail.com

ABSTRACT

Purpose: To document a clinically relevant position of the inferior alveolar nerve (IAN) in complete dentate south Indian patients in the age group of 20–29 years using cone beam computerized tomograms. **Materials and Methods:** The investigators used a cross-sectional study design and a study sample of subjects who had a radiographically identifiable IAN canal with complete set of 28 permanent teeth excluding 3rd molars. Predictor variables were age, tooth position, and side. Outcome variables were the linear distances between the buccal and lingual aspect of the IAN canal, buccal and lingual cortical thickness, IAN canal diameter, and the superior aspect of the IAN canal from the periapex of first and second mandibular molar. Descriptive statistics and Mann–Whitney *U* test were performed. *P* value of ≤ 0.05 was taken as significant. **Results:** The study sample was composed of 10 male and 10 female patients with a mean age of 24.2 ± 3.00 years. On average, the lingual cortical thickness was 1.68 mm at 1st molar and 1.44 at 2nd molar level. Gender and side influenced the outcome with varying statistical significance. **Conclusions:** The range of linear dimension of mandibular canal, cortical bone thickness, and distance between tooth apex and IAN canal have been presented for the South Indian population in the age group of 20–29 years. The implications of the findings will influence on the course of surgery. Further large-scale studies are needed to validate the findings of this study.

Keywords: Cone beam computed tomography, inferior alveolar nerve canal, mandible

INTRODUCTION

Iatrogenic injuries to inferior alveolar nerve (IAN) are a well-documented complication of third molar surgeries, implant placement, osteotomies, or fracture repair. The considerable variation in the course, the shape, curve, and direction of the nerve as well as the terminal segment of IAN complicates the regional anatomy. Hence, it is often difficult to predict the exact position of the nerve, thus impeding a proper preoperative planning.^[1]

A better understanding of the intrabony anatomy of the IAN and its relationship to mandibular molar (MM) anatomical landmarks, particularly with emphasis on the tooth may aid to decrease the risk of inadvertent IAN injury associated with various surgical interventions in the area including sagittal split osteotomies or placement of fixation screws. Several studies have underlined

the unwanted and often avoidable iatrogenic damage to the IAN. It has been reported that in harvesting procedures involving the mandibular ramus, IAN damage may cause sensory deficits in up to 8.3%.^[2] In orthognathic surgeries, this sensory change is reported in up to 65.1% of the cases and after placement of dental implants has been up to 77.8%.^[2] Previous attempts to describe the IAN-MM anatomy have significant limitations. Cadaver findings cannot be translated to patient population owing to differences in age or disease. Skull-based studies lack demographic data or use clinically inconsistent and anatomically irrelevant landmarks or include edentulous mandibles.^[1] Use of two-dimensional imaging modalities and computed tomograms has their own limitations.^[2]

Owing to absence of such IAN studies from this part of the world, this preliminary study was performed as a pilot effort to identify

appropriate sample size. The aim of this study was to identify the linear relationship of the canal to the buccal and lingual cortex (inner and outer) and to the periapex of the molar teeth as well as to compare the difference in parameters in the apical region of the first and second molar in the ipsilateral and contralateral side of the jaw.

MATERIALS AND METHODS

Randomly chosen routine cone beam computed tomography (CBCT)s of 10 males and 10 females in the age group of 20–29 years were considered for this study. The other criterias were as follows: (1) absence of any developmental disturbance or pathology or previous treatment that could influence the IAN or canal or position of tooth including impactions; (2) complete set of 28 teeth excluding 3rd molars; (3) radiographically completely corticized IAN canal bilaterally; and (4) absence of radiological evidence of skeletal/dental malocclusion that could have altered the position of 1st and 2nd MM or IAN.

All the CBCTs were taken by the same trained personnel between November 2010 and February 2011 in the same machine (Kodak Cone Beam Computerized Tomography, 9600) at the same settings. Manufacturer's instructions regarding the positioning and placement were followed. Calibration of the linear measurements had been performed using known dimensions in millimeters. The linear measurements were performed using the software and guides with the same machine.

Using the axial, coronal, and sagittal sections, the exact location of the IAN and tooth was identified for the study. Linear measurements were made in cross sections. Using 200- μ m thick sections, sections at the level of the opening of periapical foramen of the mesial root of the mandibular 1st and 2nd molar were measured by the authors, individually. Mean of the values was considered as the measurement of the particular patient. Kappa value between observers ranged between 0.93 and 0.82 for all values.

All measurements were measured along the center of the IAN canal unless mentioned specifically. The measurements were the shortest distance between the lingual inner and outer cortex (A), inner cortex to outer surface of the IAN canal along lingual side (B), inner cortex to outer IAN canal along the buccal side (C), shortest distance between buccal inner to outer (D), inner cortical width of the IAN canal (E), outer cortex to outer cortex width along the centre of the IAN canal (F), and the shortest distance between the periapex to the superior surface of IAN canal (G). These measurements were modified approach of previously published literature^[3] [Figures 1 and 2].

All the data were entered and analyzed using SPSS, version 16 (SPSS Inc., Chicago, IL). Descriptive statistics of the variables and measurements are presented. Mann–Whitney statistics were presented for comparing the linear measurements between the 1st and 2nd molars as well as between both sides. *P* value of ≤ 0.05 was taken as significant.

RESULTS

The mean age of the study population ($n = 20$) was 24.2 ± 3.00

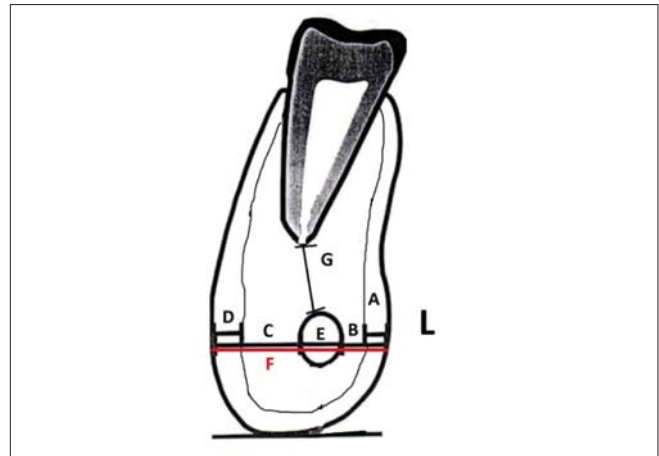


Figure 1: Schematic diagram of various linear measurement parameters: L refers to the lingual side. Distance between the lingual inner and outer cortex (A), inner cortex to outer surface of the IAN canal along lingual side (B), inner cortex to outer IAN canal along the buccal side (C), distance between buccal inner and outer cortex (D), inner cortical width of the IAN canal (E), outer cortex to outer cortex width along the centre of the IAN canal (F), and the shortest distance between the periapex to the superior surface of IAN canal (G)

years. The mean age of males ($n = 10$) was 25.2 ± 3.33 years (20–29 years). The mean age of the females ($n = 10$) was 23.2 ± 2.39 years (20–26 years). Table 1 depicts the mean value of the linear measurements of parameters in the study population and Table 2 depicts the various sites were at the level of the foramen opening of the mesial root of the right and left mandibular 1st and 2nd molar.

Table 3 differentiates the difference in terms of gender among the various parameters. It is observed that the thickness of buccal and lingual cortex significantly varied between genders. The other parameters had no significant role in terms of these linear measurements.

Table 4 depicts the results of Mann–Whitney test on comparing the tooth with respect to its position (1st and 2nd Molar) and side (right and left). The difference of lingual cortex thickness (A) with respect to 1st and 2nd molar in the right quadrant was significant as well as the distance from the lingual cortex to the IAN (B) and the inner cortex to outer surface of the IAN canal along buccal side. The other dimensions were not statistically significant.

DISCUSSION

The various imaging modalities including the periapical, panoramic, occlusal radiography, as well as conventional and computerized tomography have been used to preassess the site of surgeries such as implants. None of these modalities are perfect. Although periapical radiographs provide sufficient diagnostic information in anterior mandible, surgeries of posterior mandible may require more accurate vital diagnostic information to avoid vital structures such as IAN–MM complex. Panoramic views have inherent defect of overlap in anterior region. Two-dimensional radiographs do not provide information such as thickness or location of vital structures in a buccolingual direction. Cross-sectional imaging using conventional spiral,

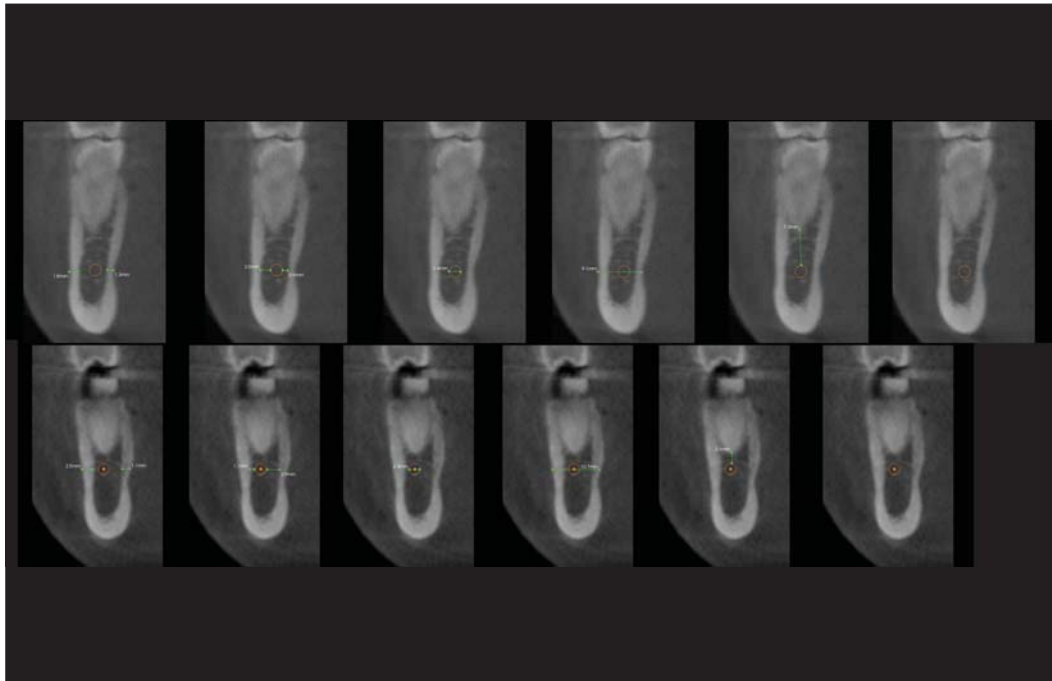


Figure 2: CBCT image showing the dimension and position of Inferior Alveolar Nerve Canal in 36 and 46. Upper row the left side mandibular molar and bottom row the second molar in the same region

Table 1: Descriptive statistics of the linear measurements in the study population in millimeters

Parameters	1 st Molar				2 nd Molar					
	Mean	95% Confidence Interval for Mean		Minimum	Maximum	Mean	95% Confidence Interval for Mean		Minimum	Maximum
		Lower	Upper				Lower	Upper		
A	1.68 ± 0.34	1.57	1.79	1.2	2.3	1.44 ± 0.32	1.33	1.54	0.9	2.3
B	1.64 ± 0.47	1.49	1.78	0.7	2.8	1.47 ± 0.59	1.28	1.65	0.7	3.4
C	3.07 ± 0.85	2.79	3.34	1.1	4.6	3.08 ± 1.11	2.72	3.44	1.1	5.5
D	2.32 ± 0.30	2.22	2.42	1.9	2.8	2.78 ± 0.62	2.58	2.98	2.1	4.6
E	2.35 ± 0.25	2.27	2.42	2	2.8	2.43 ± 0.30	2.33	2.52	2	3
F	10.16 ± 0.89	9.87	10.44	8	11.6	9.91 ± 1.62	9.39	10.42	4.3	11.4
G	6.27 ± 2.77	5.38	7.16	1.7	12.3	5.89 ± 2.54	5.08	6.70	2.5	11.3

Distance between the lingual inner and outer cortex (A), inner cortex to outer surface of the IAN canal along lingual side (B), inner cortex to outer IAN canal along the buccal side (C), distance between buccal inner and outer cortex (D), inner-cortical width of the IAN canal (E), outer cortex to outer cortex width along the centre of the IAN canal (F), and the shortest distance between the periapex to the superior surface of IAN canal (G). All values in are millimeters

linear, hypocycloidal computed tomogram, and magnetic resonance imaging have been used for cross-sectional imaging.^[4] There have been issues with the amount of radiation exposure and the high costs associated with these modalities.^[1]

CBCT has been reported as a well-suited imaging modality for the craniofacial area. It provides clear and accurate images of structures, and therefore is extremely useful for assessing the bone component. As the resultant images displayed are often corrected for magnification, and as a result, accurate measurements can be derived from the reformatted three-dimensional data.^[5]

The CBCT appearance of the mandibular canal usually is a well-defined radiolucent zone, lined by radiopaque borders. The radiographic density of this lucent structure is variable, with the presence of a radiopaque outline being dependent on the canal's cortication. As a result, in few young patients, the mandibular canal is not well visualized. Carter had earlier reported that

radiologically invisible IAN canal may occur because the IAN bundles are not always surrounded by an ossified canal.^[6] Stella had previously reported of the reliability and accuracy of conventional tomography as part of the preimplant evaluation of posterior mandibular sites to the visibility of the IAN canal.^[7]

Although this is a pilot and preliminary study, the values identified in the study are comparable with the values mentioned in the global literature.^[8] The lingual cortex is thicker at the first molar level, while the buccal cortex is much thicker at the second molar level. This probably could be due to consistent remodeling owing to the oral musculature attachments in the region. The mylohyoid line that serves to attach the mylohyoid musculature is oriented at higher position in 2nd molar region than 1st molar region, as this line runs obliquely. Hence, the thickness of lingual cortex is more at first molar level than the 2nd molar level. In the buccal surface, masseter attachment at the posterior region (2nd molar) plays a dominant role. As in the literature, root tip of 2nd molar

is closely associated with the IAN than the 1st molar root tip.^[7] This is because the IAN canal runs obliquely. The IAN canal diameter begins to narrow down at the first molar region than in second molar region, as the thickness of vessels greatly decreases. This is consistent as reported by Humphries SM. Concisely, the parameters studied vary between the 1st molar and 2nd molar.

As identified in the study, females had a mildly thicker buccal and lingual cortical thickness than males. The findings are not in agreement with earlier reports.^[8] Although the difference is less than 0.1 mm, the phenomenon needs to be checked using

a larger sample in a wider age group. However, the overall thickness of mandible is thicker in males than females, which is in agreement with earlier reports.^[8] The thickness of IAN canal increases from 1st molar to 2nd molar. This is also in agreement with published reports.^[8]

The difference in between the right side and left side was remarkable, indicating that the right and left halves are not entirely symmetrical. The right halves value is noted to be always higher than the left values which is consistent with reports from the literature.^[9]

Table 2: Linear Measurement of Parameters at various levels (n =20) in Millimeters

		Mean	Std. Deviation	Minimum	Maximum
Right mandibular 1 st molar	A	1.78	0.31	1.4	2.3
	B	1.64	0.48	0.7	2.5
	C	2.91	0.85	1.1	4.4
	D	2.29	0.30	1.9	2.8
	E	2.33	0.29	2	2.8
	F	10.05	0.97	8	11.3
	G	5.79	2.20	2	8.5
Right mandibular 2 nd molar	A	1.43	0.31	0.9	2.1
	B	1.35	0.38	0.7	2.1
	C	2.72	0.99	1.1	4.2
	D	2.92	0.73	2.1	4.6
	E	2.46	0.31	2	3
	F	9.56	1.99	4.3	11.1
	G	5.95	2.86	2.5	11.3
Left mandibular 1 st molar	A	1.58	0.35	1.2	2.1
	B	1.63	0.47	1.2	2.8
	C	3.22	0.84	2.1	4.6
	D	2.35	0.32	2	2.8
	E	2.36	0.20	2.1	2.7
	F	10.26	0.82	9	11.6
	G	6.75	3.24	1.7	12.3
Left mandibular 2 nd molar	A	1.44	0.33	1.1	2.3
	B	1.58	0.73	0.9	3.4
	C	3.44	1.14	2	5.5
	D	2.64	0.45	2.1	3.5
	E	2.39	0.29	2	2.8
	F	10.25	1.09	7.8	11.4
	G	5.83	2.25	2.7	9.4

Distance between the lingual inner and outer cortex (A), inner cortex to outer surface of the IAN canal along lingual side (B), inner cortex to outer surface of the IAN canal along buccal side (C), inner cortex to outer surface of the IAN canal along buccal side (D), inner-cortical width of the IAN canal (E), outer cortex to outer cortex width along the centre of the IAN canal (F), and the shortest distance between the periapex to the superior surface of IAN canal (G). All values are in millimeters

This pilot study has identified the thickness of the buccal cortical bone in the mandible in the regions of the first and second molars. This will be useful guide when monocortical plating of mandibular fractures with plates placed in the neutral zone of the mandible that is often placed in close proximity to the IAN canal. Furthermore, the values mentioned would also be helpful to relate the position of the IAN canal to the buccal bone at its medial and inferior positions from the root apex.

As this kind of study is performed for the first time in this population, the comparison of the values cannot be done or our claims refuted. The aim of this study was to collect CBCT details of normal patients from archival records, as per the strict inclusion and exclusion criteria's. As CBCTs are reserved only for gross and extensive pathologies or for extensive treatment planning, most of the retrospective CBCTs do not meet the criterias and liberal selection criteria would induce selection bias in the study. Hence, only very small sample size was included for this pilot study. In future, similar studies which compare IAN anatomy of cases with iatrogenic complication could be compared against regular cases; also CBCTs diagnostic efficacy against other modalities could be compared.

CONCLUSION

The range of linear dimension of mandibular canal, cortical bone thickness, and distance between tooth apex and IAN canal have been presented for the South Indian population in the age group of 21-30 years. With the increasing demand for accurate preoperative assessment and planning prior to oral implant surgery or other surgeries of this region, cross-sectional images such as from CBCT may be utilized for obtaining more information on the appearance, location, and course of the canals, and their relation to other anatomical structures in the jaw bone including

Table 3: Mean of the Liner measurements among gender

Parameters	1 st Molar		2 nd Molar		P value
	Male	Female	Male	Female	
A	1.63 ± 0.3	1.74 ± 0.38	1.38 ± 0.29	1.49 ± 0.34	0.001**
B	1.48 ± 0.43	1.79 ± 0.46	1.34 ± 0.36	1.59 ± 0.74	0.156
C	3.2 ± 0.89	2.94 ± 0.81	3.3 ± 1.36	2.87 ± 0.78	0.946
D	2.28 ± 0.3	2.36 ± 0.31	2.84 ± 0.72	2.72 ± 0.5	0.000**
E	2.35 ± 0.27	2.34 ± 0.22	2.4 ± 0.28	2.45 ± 0.32	0.192
F	10.14 ± 1.02	10.18 ± 0.77	10.11 ± 1.58	9.7 ± 1.68	0.396
G	6.15 ± 2.29	6.39 ± 3.24	6.3 ± 2.43	5.48 ± 2.64	0.525

**P ≤ 0.001, highly significant. Distance between the lingual inner and outer cortex (A), inner cortex to outer surface of the IAN canal along lingual side (B), inner cortex to outer surface of the IAN canal along buccal side (C), inner cortex to outer surface of the IAN canal along buccal side (D), inner-cortical width of the IAN canal (E), outer cortex to outer cortex width along the centre of the IAN canal (F), and the shortest distance between the periapex to the superior surface of IAN canal (G). All values are in millimeters.

Table 4: Mann-Whitney U test for comparing the difference of study parameters

Parameter	Comparison	P value						
		A	B	C	D	E	F	G
Right	1 st to 2 nd molar	0.001**	0.035*	0.565	0.001**	0.265	0.883	0.925
Left	1 st to 2 nd molar	0.314	0.265	0.565	0.35	0.758	0.718	0.461
1 st molar	Right to left	0.068	0.461	0.461	0.565	0.529	0.602	0.369
2 nd molar	Right to left	0.968	0.602	0.108	0.265	0.565	0.289	0.758

* $P \leq 0.05$, significant; ** $P \leq 0.001$, highly significant. Distance between the lingual inner and outer cortex (A), inner cortex to outer surface of the IAN canal along lingual side (B), inner cortex to outer IAN canal along the buccal side (C), inner cortex to outer surface of the IAN canal along buccal side (D), innercortical width of the IAN canal (E), outer cortex to outer cortex width along the centre of the IAN canal (F), and the shortest distance between the periapex to the superior surface of IAN canal (G). All values are in millimeters.

the apex of the tooth.

REFERENCES

- Levine MH, Goddard AL, Dodson TB. Inferior alveolar nerve canal position: A clinical and radiographic study. *J Oral Maxillofac Surg* 2007;65:470-4.
- Gerlach NL, Meijer GJ, Mall TJ, Mulder J, Rangel FA, Borstlap WA, et al. Reproducibility of 3 different tracing methods based on cone beam computed tomography in determining the anatomical position of the mandibular canal. *J Oral Maxillofac Surg* 2010;68:811-7.
- Ylikontiola L, Kinnunen J, Oikarinen K. Factors affecting neurosensory disturbance after mandibular bilateral sagittal split osteotomy. *J Oral Maxillofac Surg* 2000;58:1234-9.
- Peter I, Alkurt MT, Michioglu T. The use of 3 different imaging methods for the localization of the mandibular canal in Dental implant planning. *Int J Oral Maxillofac Implants* 2008;23:463-70.
- Angelopoulos C, Thomas S, Hechler S, Parissis N, Hlavacek M. Comparison between digital panoramic radiography and cone-beam computed tomography for the identification of the mandibular canal as part of presurgical dental implant assessment. *J Oral Maxillofac Surg* 2008;66:2130-5.
- Carter RB, Keen EN. Intramandibular course of the inferior alveolar nerve. *J Anat* 1970;108:433-40.
- Stella JP, Tharanon W. A precise radiographic method to determine the location of the inferior alveolar canal in the posterior edentulous mandible: Implications for dental implants. Part I: Technique. *Int J Oral Maxillofac Implants* 1990;5:15-22.
- Fayed MM, Pazera P, Katsaros C. Optimal sites for orthodontic mini-implant placement assessed by cone beam computed tomography. *Angle Orthod* 2010;80:939-51.
- Humphries SM. Comparison of cortical bone thickness between second premolars and first molars in the maxilla and mandible in four ethnic groups. Dissertation submitted to the Faculty of The Graduate School University of Southern California for the Degree MASTER OF SCIENCE (Craniofacial Biology), May 2007. p. 57,58.

Cite this article as: Balaji SM, Krishnaswamy NR, Kumar SM, Rooban T. Inferior alveolar nerve canal position among South Indians: A cone beam computed tomographic pilot study. *Ann Maxillofac Surg* 2012;2:51-5.

Source of Support: Nil, **Conflict of Interest:** None declared.

Staying in touch with the journal

1) Table of Contents (TOC) email alert

Receive an email alert containing the TOC when a new complete issue of the journal is made available online. To register for TOC alerts go to www.amsjournal.com/signup.asp.

2) RSS feeds

Really Simple Syndication (RSS) helps you to get alerts on new publication right on your desktop without going to the journal's website. You need a software (e.g. RSSReader, Feed Demon, FeedReader, My Yahoo!, NewsGator and NewzCrawler) to get advantage of this tool. RSS feeds can also be read through FireFox or Microsoft Outlook 2007. Once any of these small (and mostly free) software is installed, add www.amsjournal.com/rssfeed.asp as one of the feeds.