

## Review Article

# Imaging Diagnosis of Splanchnic Venous Thrombosis

S. Rajesh,<sup>1</sup> Amar Mukund,<sup>2</sup> and Ankur Arora<sup>1</sup>

<sup>1</sup>Department of Radiology, Institute of Liver & Biliary Sciences, D-1 Vasant Kunj, New Delhi 110070, India

<sup>2</sup>Department of Interventional Radiology, Institute of Liver & Biliary Sciences, D-1 Vasant Kunj, New Delhi 110070, India

Correspondence should be addressed to Ankur Arora; aroradrankur@yahoo.com

Received 18 March 2015; Accepted 22 April 2015

Academic Editor: Hao Xu

Copyright © 2015 S. Rajesh et al. This is an open access article distributed under the Creative Commons Attribution License, which permits unrestricted use, distribution, and reproduction in any medium, provided the original work is properly cited.

Splanchnic vein thrombosis (SVT) is a broad term that includes Budd-Chiari syndrome and occlusion of veins that constitute the portal venous system. Due to the common risk factors involved in the pathogenesis of these clinically distinct disorders, concurrent involvement of two different regions is quite common. In acute and subacute SVT, the symptoms may overlap with a variety of other abdominal emergencies while in chronic SVT, the extent of portal hypertension and its attendant complications determine the clinical course. As a result, clinical diagnosis is often difficult and is frequently reliant on imaging. Tremendous improvements in vascular imaging in recent years have ensured that this once rare entity is being increasingly detected. Treatment of acute SVT requires immediate anticoagulation. Transcatheter thrombolysis or transjugular intrahepatic portosystemic shunt is used in the event of clinical deterioration. In cases with peritonitis, immediate laparotomy and bowel resection may be required for irreversible bowel ischemia. In chronic SVT, the underlying cause should be identified and treated. The imaging manifestations of the clinical syndromes resulting from SVT are comprehensively discussed here along with a brief review of the relevant clinical features and therapeutic approach.

## 1. Introduction

Splanchnic venous system includes the mesenteric, splenic, and hepatic beds, the first two serving as the major inflow for the third (Figure 1). Blood flowing through the intestines, spleen, and pancreas is collected by the superior mesenteric vein (SMV) and splenic vein (SV) which join to form the portal vein (PV). Stomach and part of the pancreas drain directly into the portal vein. At the porta hepatis, PV divides into right and left branches that continue to their respective hepatic lobes, ultimately emptying into the hepatic sinusoids. Venous outflow from the liver is through the hepatic veins (HV) which drain into the inferior vena cava (IVC). Consequently, the term splanchnic vein thrombosis (SVT) includes occlusion of veins that form the portal venous system or the hepatic veins (Budd-Chiari syndrome) [1, 2]. Although portal and mesenteric vein thrombosis and Budd-Chiari syndrome are three distinct clinical entities, their etiologies are often shared and clinical presentation may overlap. Moreover, simultaneous involvement of two different regions is fairly frequent due to the common risk factors. Thus, it is only

prudent to discuss them collectively. Once considered to be a rare entity, SVT is increasingly being detected, thanks mainly to the remarkable advancements in imaging technology and increased awareness amongst healthcare providers. The present review appraises the radiological manifestations of SVT and aims to underscore the importance of imaging in decision making and patient selection to improve therapy and outcome in this group of patients.

## 2. Budd-Chiari Syndrome

The term Budd-Chiari syndrome (BCS) refers to the clinical manifestations arising as a consequence of hepatic venous outflow tract obstruction at any level from the small hepatic veins to the cavoatrial junction regardless of the mechanism of obstruction [3] (Figure 2). It follows that cardiac and pericardial diseases as well as sinusoidal obstruction syndrome are excluded from this definition [3, 4].

*2.1. Etiology.* On the basis of etiology, BCS is divided into primary BCS (related to a primarily endoluminal venous

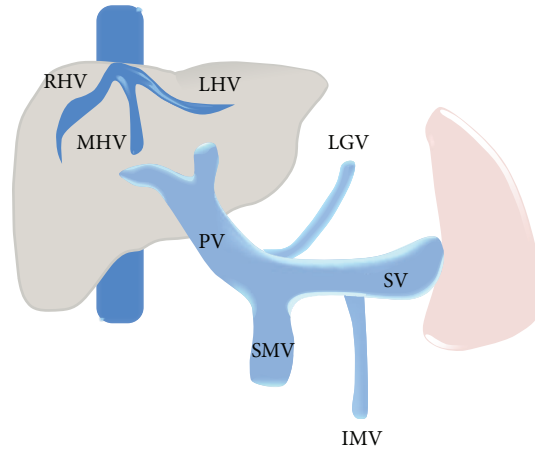


FIGURE 1: Graphic illustration of the splanchnic venous system. RHV: right hepatic vein, MHV: middle hepatic vein, LHV: left hepatic vein, PV: portal vein, SMV: superior mesenteric vein, SV: splenic vein, LGV: left gastric vein, and IMV: inferior mesenteric vein.

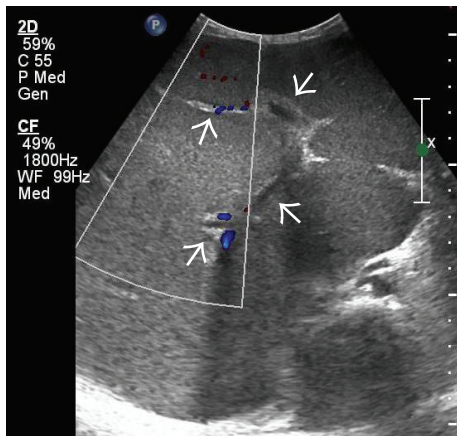


FIGURE 2: Gray-scale US image demonstrating homogeneously hypoechoic and bulbous liver with chinked portal venous radicals (arrows) in a patient with fulminant BCS.

disease, i.e., thrombosis or web) and secondary BCS (caused by infiltration or compression by a lesion outside the venous system, i.e., benign or malignant tumors, cysts, abscesses, etc.) [4] (Box 1). Prevalence of this disease shows marked geographic variation, from being one of the most common causes for hospital admission for liver disease in Nepal to becoming a rare entity in western countries [5, 6]. Based on the level of obstruction, BCS has been classified into three types [7] (Box 2). In the past, IVC was reported to be frequently obstructed in Asians and usually patent in western patients. However, this pattern has changed over the period of time in India, where hepatic vein thrombosis now accounts for the majority of the cases (59%) and obstruction of terminal IVC now accounts for a lesser proportion of cases (16%) [8].

2.2. *Clinical Features.* Clinical presentation of the disease is highly variable and depends on the acuteness and extent of

- |  |
|--|
| <p>Primary BCS</p> <ul style="list-style-type: none"> <li>Hypercoagulable states</li> <li>Inherited                     <ul style="list-style-type: none"> <li>Antithrombin deficiency</li> <li>Protein C, S deficiency</li> <li>Heterozygous Factor V Leiden</li> <li>Prothrombin mutation</li> </ul> </li> <li>Acquired                     <ul style="list-style-type: none"> <li>Myeloproliferative disorders</li> <li>Paroxysmal nocturnal hemoglobinuria</li> <li>Antiphospholipid syndrome</li> <li>Cancer</li> <li>Pregnancy</li> <li>Use of oral contraceptives</li> </ul> </li> <li>Systemic causes                     <ul style="list-style-type: none"> <li>Connective tissue disease</li> <li>Inflammatory bowel disease</li> <li>Behcet disease</li> <li>Sarcoidosis</li> <li>Vasculitis</li> <li>Cancer</li> </ul> </li> </ul> <p>Secondary BCS</p> <ul style="list-style-type: none"> <li>Benign or malignant hepatic tumors</li> <li>Trauma</li> <li>Hepatic abscess</li> <li>Simple or complex hepatic cysts</li> <li>Idiopathic</li> </ul> |
|--|

Box 1: Causes of BCS.

- |   |
|---|
| <ul style="list-style-type: none"> <li>(I) Obstruction of IVC ± hepatic veins</li> <li>(II) Obstruction of major hepatic veins</li> <li>(III) Obstruction of small centrilobular venules</li> </ul> |
|---|

Box 2: Classification of BCS based on the level of obstruction.

the hepatic venous outflow tract obstruction, ranging from complete absence of symptoms to fulminant hepatic failure, through acute, subacute, or chronic progressive development of symptoms over weeks to months [4, 9]. In cases of extensive and acute thrombosis of veins, frequently encountered in the western countries, the patient presents with abdominal pain and distension, jaundice, and hepatomegaly. The etiology in such cases is usually an underlying thrombotic disorder, intake of oral contraceptive pills, or pregnancy [4]. On the other hand, in Asian countries, membranous occlusion of the HV/IVC is more common [10]. Once considered to be congenital in origin, membranous web is now widely accepted to be a result of organized thrombus with focal stenosis being a part of this pathological spectrum [11]. This might be a possible explanation for the majority of Asian patients with BCS having a subacute to chronic course, characterized by insidious onset of portal hypertension, leg edema, gastrointestinal bleed, and nodular liver [12]. The course of manifestations in these patients can be steady or marked by exacerbations and remissions [9].

Since the changes in the liver parenchyma in BCS can be inhomogeneous, a single biopsy may be falsely negative [3]. Thus, a biopsy is usually reserved for cases in which radiological findings are inconclusive, like in the event of involvement of small hepatic veins with patent large veins, although differentiation of this form from sinusoidal obstruction syndrome is not always possible [9]. Also, serial liver biopsies are useful for assessing the severity of disease and determining whether it has progressed after therapeutic interventions.

Early diagnosis of BCS is of critical importance for commencing appropriate therapy. Due to the nonspecific and variable clinical presentation and the fact that biopsy cannot be blindly relied upon, imaging assumes a vital role in the early identification of the disease and accurate assessment of its extent.

**2.3. Imaging Findings.** Hepatic venous outflow tract obstruction causes increase in the sinusoidal and portal pressures, leading to hepatic congestion, necrosis, fibrosis, and eventually florid cirrhosis [13]. Imaging findings at various stages of BCS reflect the progressive pathological changes occurring in the hepatic parenchyma and vasculature. Real-time ultrasound (US) coupled with Doppler is currently considered to be the investigation of choice for the initial evaluation of a patient suspected of having BCS and in experienced hands might be the only modality required to establish the diagnosis in majority of the cases [14]. It demonstrates the hepatic echotexture and morphological changes, status of HV and IVC, and evidence of intrahepatic collaterals. Simultaneously, presence of ascites and splenomegaly can be assessed. Besides, US is widely available and inexpensive and does not impart harmful radiation to the patient or the operator. However, its major limitations are patient's body habitus and operator expertise which may preclude an adequate examination. Computed tomography (CT) and magnetic resonance imaging (MRI) have a complementary role to US and Doppler and serve mainly as problem solving tools. Routine use of cross-sectional imaging in patients with

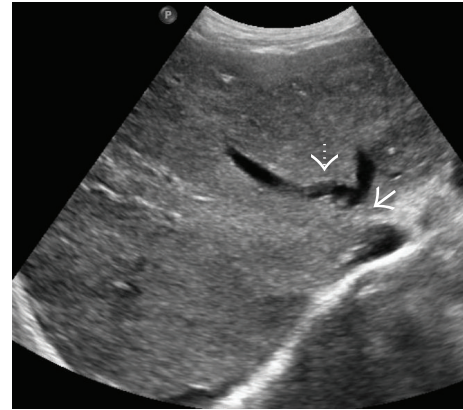


FIGURE 3: Gray-scale image from the US study of a patient with BCS due to obstruction of the common channel of the middle and the left hepatic veins (arrow) showing a more heterogeneous hepatic parenchymal echotexture. Collateral channel can be seen bridging the two hepatic veins proximal to obstruction (interrupted arrow).

BCS to rule out the development of hepatocellular carcinoma or comprehensive assessment of collateral circulation is debatable. Catheter IVC graphy/cavography, which was once considered the standard of reference for evaluation of HV and IVC is now no longer routinely used for diagnostic purpose because noninvasive imaging provides evidence for BCS in most patients. Cavography tends to over diagnose HV thrombosis even when the failure to cannulate the HV might be due to technical failure. Moreover, it fails to provide an assessment of the extent of thrombosis in case of IVC obstruction which can be accurately done by MR venography [15, 16]. In addition, the entire extent of intrahepatic collaterals might not be picked up on cavography. Thus, it is reserved for patients in whom surgical or radiological intervention is contemplated. However, it still remains the gold standard when the hemodynamic significance of a suspected IVC narrowing due to caudate lobe hypertrophy is to be estimated in postsurgical/transplant patients. Pressure gradient across the suspected segment of narrowing is measured and a gradient of  $> 3$  mm Hg is considered hemodynamically significant [17].

**2.3.1. Hepatic Parenchymal Changes.** In the acute stage, congestive changes predominate resulting in global enlargement of the liver [7]. On gray-scale US, the liver is typically enlarged and bulbous and appears homogeneously hypoechoic (Figure 2). However, altered regional echogenicity may be seen secondary to perfusion alterations and hemorrhage [7] (Figure 3).

On the noncontrast enhanced CT scan, liver shows diffuse hypodensity [12] (Figure 4). Postadministration of intravenous contrast, a characteristic “flip-flop” pattern of enhancement is seen in the form of early homogeneous enhancement of the caudate lobe and central portion of liver around IVC and decreased enhancement peripherally (Figure 5). This partially reverses on the equilibrium phase images with the periphery of the liver retaining contrast and showing patchy inhomogeneous enhancement while there is

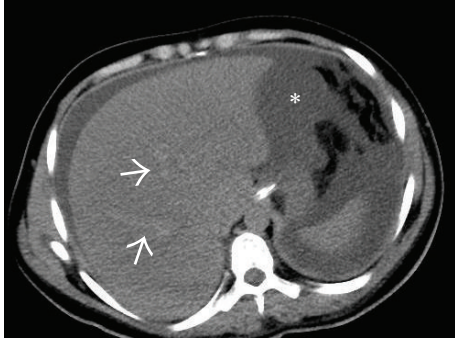


FIGURE 4: Noncontrast-enhanced axial CT scan image showing a diffusely hypodense liver in this patient with acute thrombosis of all the three hepatic veins. On careful inspection, the right and middle hepatic veins can be made out as mildly hyperdense structures (arrows) on the background of this hypodense liver. Ascites can also be seen on this section (asterisk).

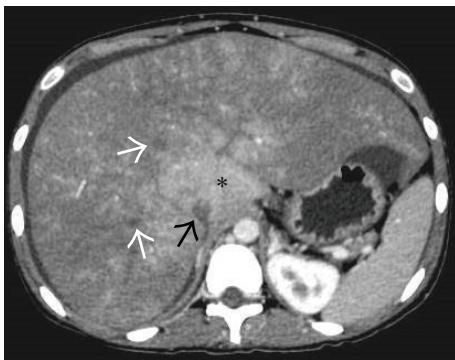

FIGURE 5: Axial CECT image acquired in the portal venous phase showing enhancement of the caudate lobe (asterisk) while rest of the liver parenchyma in the periphery remains predominantly hypoenhancing. Thrombosed right and middle hepatic veins (white arrows) and IVC (black arrow) can also be seen.

washout of contrast from the central portion of liver [12]. These changes are attributed to acute tissue edema in the peripheral portions of liver due to the combined effects of hepatic venous obstruction and diminished portal flow. On MRI, peripheral liver parenchyma is of moderately low signal intensity on T1-weighted images and high signal intensity on T2-weighted images compared to the central portion with decreased enhancement of the peripheral liver after gadolinium administration [15, 16].

As the disease progresses, there is reversal of flow in the portal vein with development of intrahepatic collaterals which permit decompression of liver [18]. Thus, in subacute BCS, a mottled pattern of parenchymal enhancement is seen with no specific predilection for centre or periphery of the liver (Figure 6).

Caudate lobe has separate veins (which may not be affected by the disease process) which drain directly into the IVC at a level lower than the ostia of the main hepatic veins. This may result in compensatory caudate lobe hypertrophy which can be seen in up to 75% cases of BCS and serves

as a useful indirect sign [19] (Figure 7). However, caudate hypertrophy is nonspecific and can be seen in many other cases of cirrhosis of varied etiologies.

In later stages of the disease, morphological changes start appearing in the liver in the form of surface nodularity and coarsened echotexture on US with changes of portal hypertension (Figure 8). This results in decreased T1- and T2-weighted signal intensity at unenhanced MR imaging and in delayed enhancement in contrast-enhanced studies [15, 16]. Attendant volume redistribution starts taking place in the liver resulting in right lobe atrophy with hypertrophy of the left lobe.

Due to focal loss of portal perfusion in patients with BCS, compensatory nodular hyperplasia can occur in areas of hepatic parenchyma that have an adequate blood supply resulting in formation of regenerative nodules [20–23]. They are usually multiple with a typical diameter of between 0.5 and 4 cm [22]. The term large regenerative nodules (LRN) is preferred for these lesions rather than nodular regenerative hyperplasia (NRH) since NRH, by definition, implies that there should be no fibrosis interspersed between the nodules while BCS at a later stage of the disease can result in fibrosis or frank cirrhosis [21, 22]. On multiphase contrast-enhanced CT or MRI, LRN demonstrate marked and homogeneous enhancement on the arterial phase images and remain hyperattenuating to the surrounding hepatic parenchyma on portal venous phase images [22] (Figure 9). Because LRN are mainly composed of normal liver parenchyma, they are not well-appreciated on unenhanced or equilibrium phase CT or T2-weighted MR images [22]. They may appear bright on T1WI due to deposition of copper within some of these nodules; however, they do not contain fat, hemorrhage or calcification [22, 23]. There is no evidence that LRN degenerate into malignancy. Although hepatocellular carcinoma (HCC) is considered to be extremely rare in BCS, it is important to differentiate LRN from HCC since a misdiagnosis may deny a patient the possibility of liver transplant or subject him to unnecessary aggressive treatment for HCC. HCC is usually hypointense to the liver on T1WI and hyperintense on T2WI, along with evidence of heterogeneity, encapsulation, and portal or hepatic venous invasion, none of which are seen in LRN. On multiphase CT or MRI, HCC shows washout of contrast on the portal venous and equilibrium phase images in contradistinction to LRN which remain slightly hyperattenuating. On the hepatobiliary phase, HCC would appear hypointense while LRN would retain contrast on account of it being composed of predominantly normal or hyperplastic hepatocytes [21, 22]. Also, it has been seen that when HCC is encountered in a noncirrhotic liver, it is usually a solitary, large, heterogeneous mass while LRN are almost always multiple, small, and homogeneously enhancing [24]. A marked increase in the number of LRN has been noticed following creation of a portosystemic shunt [20, 22] (Figure 9).

**2.3.2. Vascular Changes.** HV may be normal or reduced in caliber and filled with intraluminal anechoic or echogenic thrombus in the acute phase [7, 12] (Figure 10). HV walls may appear thickened and echogenic. Not uncommonly, there

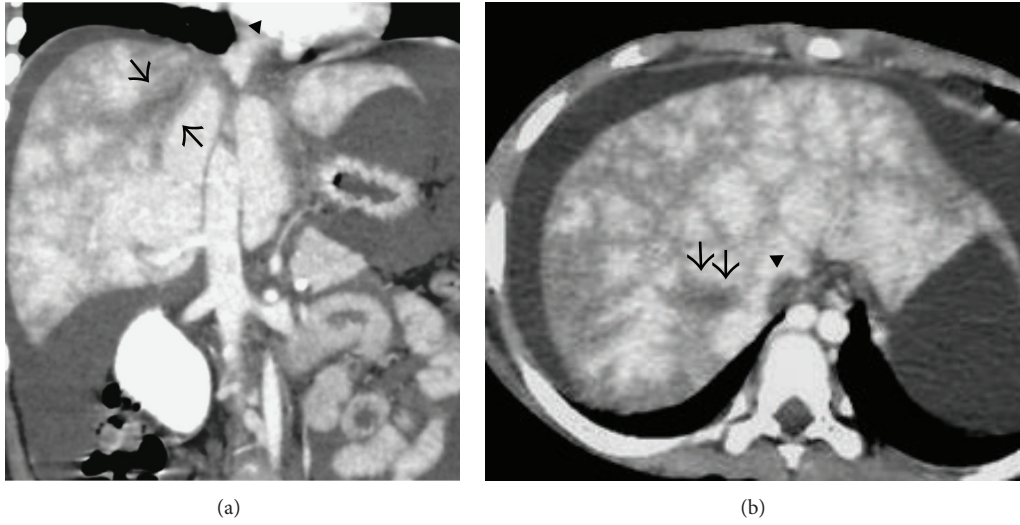


FIGURE 6: Coronal (a) and axial (b) portal venous phase CECT image showing thrombosed right hepatic vein (arrows) and the part of the intrahepatic portion of IVC (arrowheads) with mottled enhancement of the liver parenchyma and ascites.

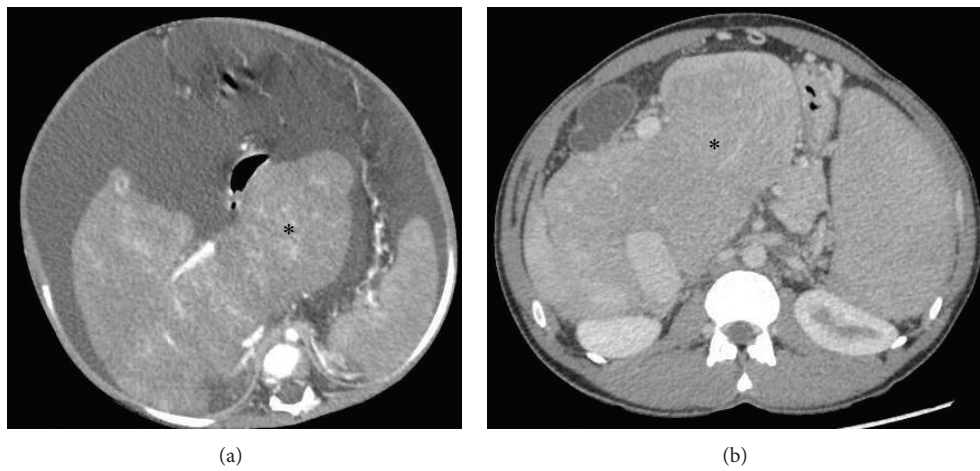


FIGURE 7: Axial CECT images from two different patients with chronic BCS demonstrating markedly hypertrophied caudate lobe (asterisk).

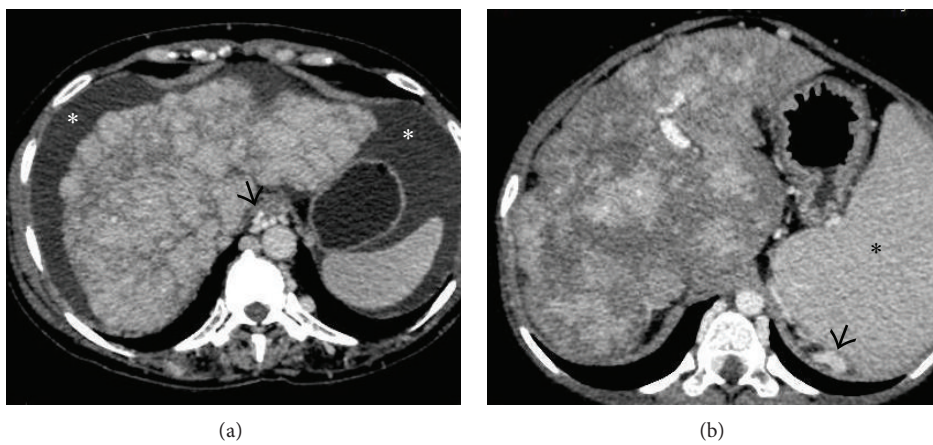


FIGURE 8: Axial images from the CECT scan of two different patients with chronic BCS demonstrating cirrhotic architecture of liver in the form of irregular lobulated outlines and heterogeneous mottled hepatic parenchymal enhancement. Ascites (asterisks in (a)), splenomegaly (asterisk in (b)) and paraesophageal and perisplenic collaterals (arrow in (a) and (b), resp.) can also be seen.

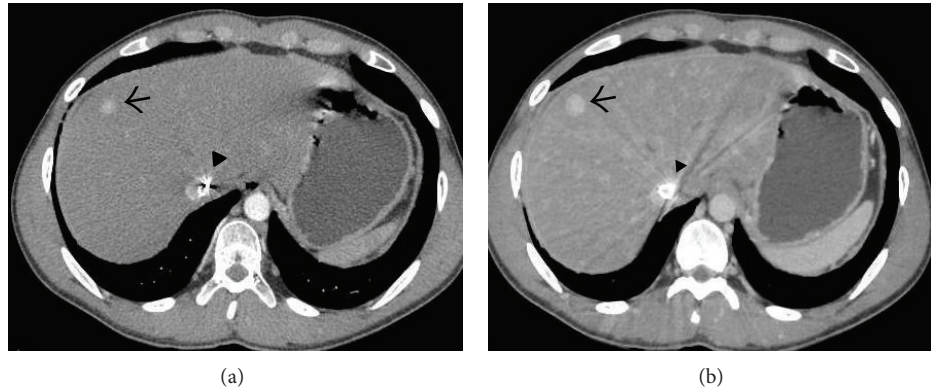


FIGURE 9: Axial CECT images acquired in the arterial (a) and venous (b) phase showing an arterial phase enhancing nodule (arrow in (a)) in liver which retains the contrast in the venous phase (arrow in (b)) consistent with regenerative nodule in this patient who had undergone direct intrahepatic portocaval shunt (DIPS) for BCS.

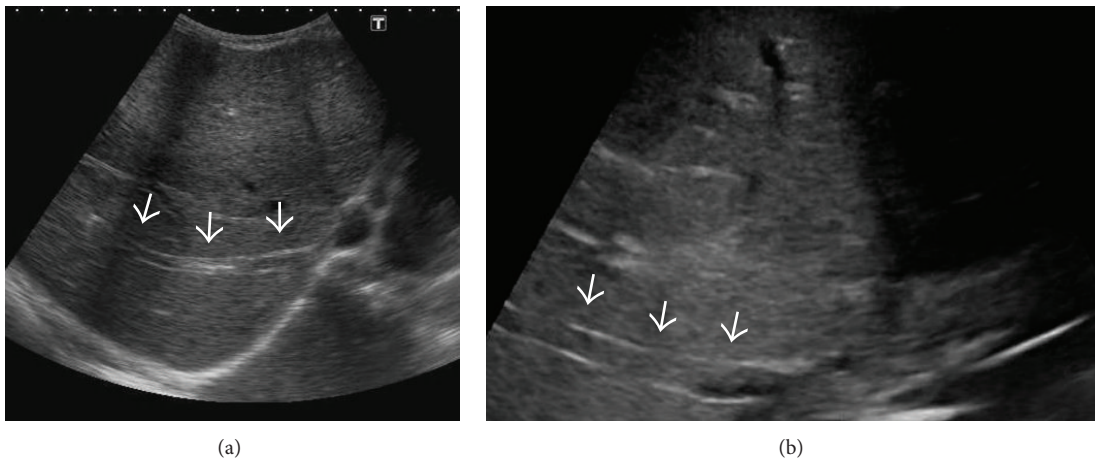


FIGURE 10: Gray-scale US images from two different patients demonstrating echogenic thrombus within the right hepatic vein (arrows).

may be a partial or complete nonvisualization of the HV due to the markedly heterogeneous hepatic parenchyma and altered caliber and echogenicity of the HV [7, 12, 25]. Alternatively, there can be stenosis of the HV, most commonly at or near the ostia, with proximal dilatation [7] (Figures 11 and 12). In cases of chronic thrombosis, the HV may be reduced to an echogenic cord-like structure [26] (Figure 13).

The normal blood flow in the HV is phasic in response to the cardiac cycle (Figure 14). In BCS, flow in the HV changes from phasic to absent, continuous, turbulent, or reversed [7] (Figure 15). Turbulent or high flow is usually seen at or near the site of stenosis.

IVC can be obstructed in its suprahepatic or intrahepatic portion or both. Suprahepatic occlusion is usually due to webs or short segment stenosis while intrahepatic IVC obstruction is commonly secondary to compression caused by an enlarged caudate lobe [7, 27] (Figure 16). Long segment narrowing of intrahepatic IVC without associated caudate lobe enlargement or focal narrowing due to a web or a thrombus can also be observed [7] (Figures 6(a) and 17). On US, membranous web usually appears as an echogenic

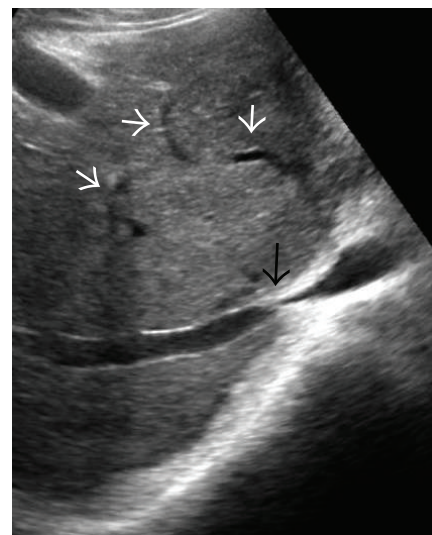


FIGURE 11: Gray-scale US image demonstrating stenosis at the ostium of right hepatic vein (black arrow) with multiple intrahepatic collaterals (white arrows) and heterogeneous hepatic echotexture.

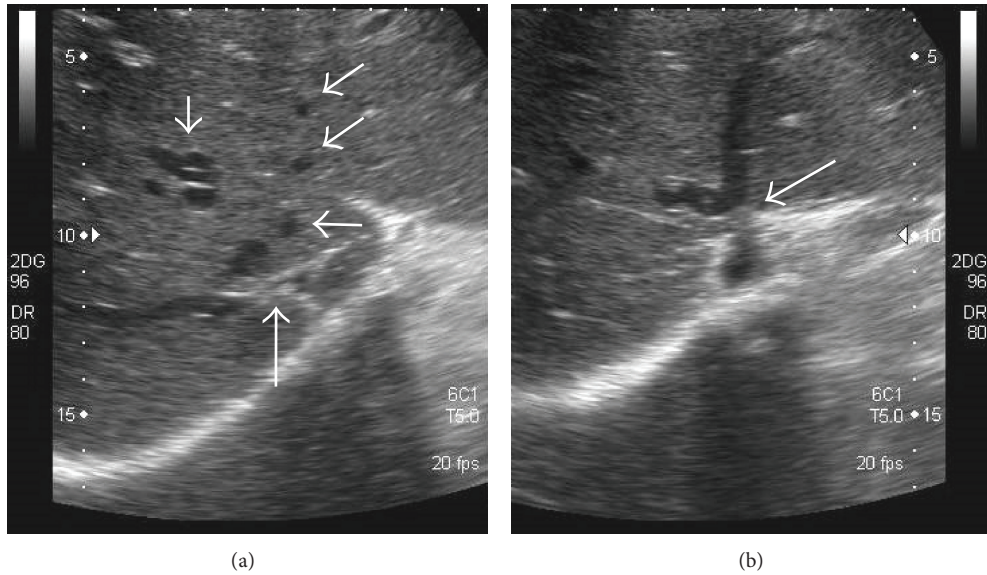


FIGURE 12: Gray-scale US image demonstrating stenosis at the ostium of right hepatic vein (long white arrow in (a)) and the common channel of middle and left hepatic vein (arrow in (b)) with multiple intrahepatic collaterals (small white arrows in (a)).

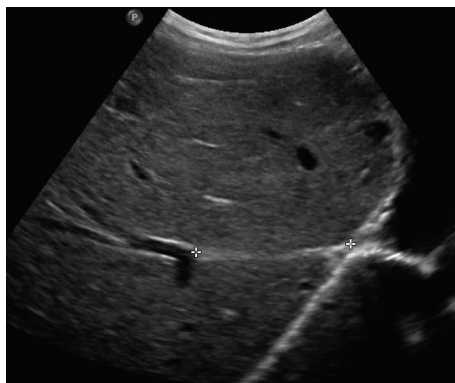


FIGURE 13: Gray-scale US image showing the distal portion of right hepatic vein (marked by calipers) being reduced to a cord-like structure due to chronic thrombosis.

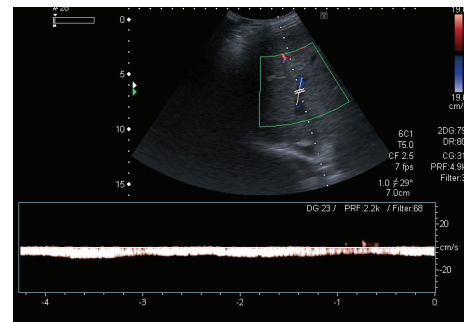


FIGURE 15: Spectral Doppler image in a patient with BCS shows monophasic waveform in the hepatic vein.

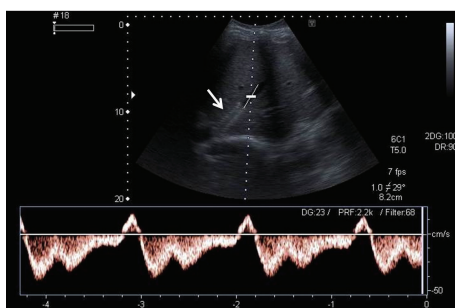


FIGURE 14: Spectral Doppler image posthepatic vein stenting demonstrates restoration of normal triphasic waveform (inverted “M” shape) of the right hepatic vein in a patient with BCS. Arrow denotes the stent in the right hepatic vein.

linear area within the lumen of IVC best seen in deep inspiration (Figure 18(a)). On conventional venography or CT/MRI angiography, they appear as dome shaped linear filling defects (Figures 18(b) and 19). Similarly, hepatic venous web appears as a linear hypodense intraluminal structure with or without proximal dilatation (Figure 20). Short segment stenosis is seen as an area of narrowing with proximal dilatation. In partial IVC obstruction or extrinsic IVC compression, the normally phasic flow in IVC can change to a continuous waveform (called as “pseudoportal” Doppler signal) [28]. In later stages, chronic thrombosis of IVC can evolve into calcification [29] (Figure 21). Establishing the patency of IVC is important before deciding upon the surgical management, if need may arise. If the IVC is patent portocaval or mesocaval shunt can be created while if the IVC is occluded mesoatrial shunt would be required.

Due to the combined effects of decreased portal blood flow in BCS and the underlying thrombophilia, simultaneous

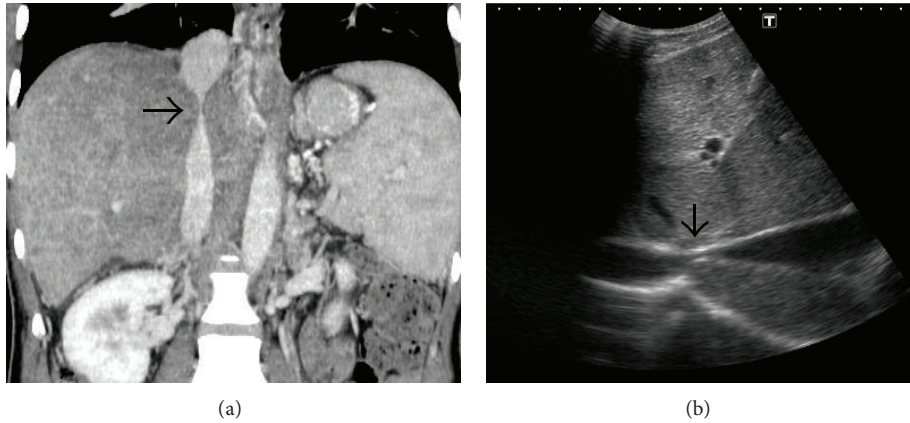


FIGURE 16: Coronal CECT (a) and gray-scale US (b) image demonstrating compression of intrahepatic IVC (arrows) caused by hypertrophy of the caudate lobe.

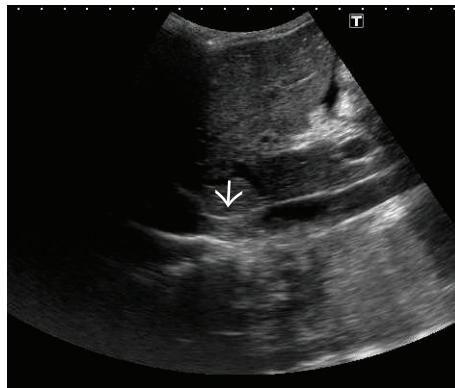


FIGURE 17: Gray-scale US image demonstrating echogenic thrombus in IVC (arrow).

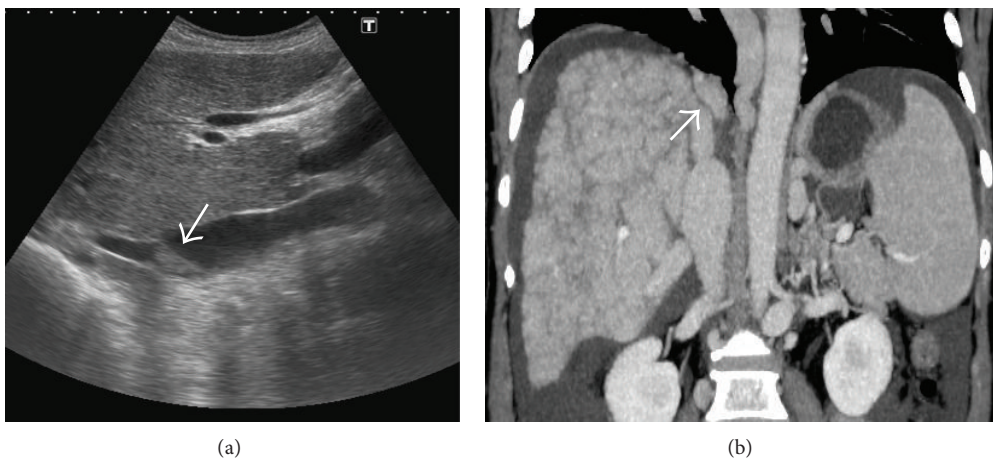


FIGURE 18: Gray-scale US (a) and coronal MIP (b) images demonstrating an IVC web (sequel of chronic focal thrombosis) which appears as a linear echogenic structure on US (arrow in (a)), while on CT, it appears as an intraluminal hypodense linear structure (arrow in (b)).

portal vein thrombosis (PVT) can occur in up to 15% of cases [30]. Portal blood flow on Doppler may be absent, slowed, or reversed [31]. Assessment of PV patency is crucial as a thrombosed portal vein may preclude creation of a portosystemic shunt to decompress the liver in such patients.

Caudate lobe outflow serves as a drainage pathway for intrahepatic venovenous collaterals. Thus, caudate vein may be dilated in BCS. In the appropriate clinical setting, a caudate lobe vein > 3 mm has been reported to be strongly suggestive of BCS [32] (Figure 22).



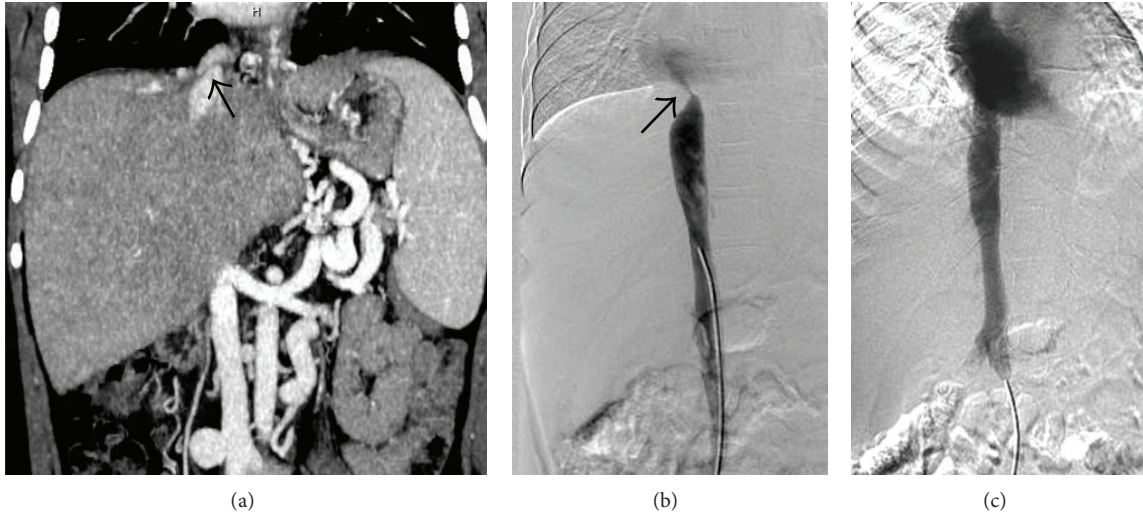


FIGURE 19: Coronal CECT image (a) showing an IVC web (arrow). IVC angiogram (b) of the same patient showing a jet of contrast (arrow) entering the right atrium signifying the obstruction caused by the web. Postangioplasty image (c) shows resolution of the stenosis.

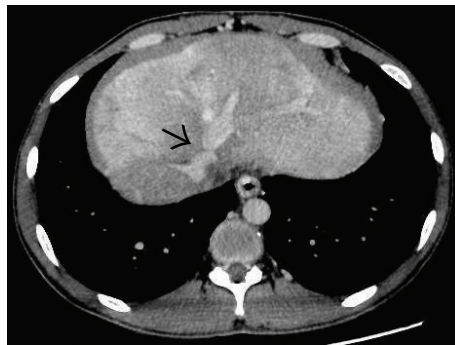


FIGURE 20: Axial CECT image demonstrating a web in the left hepatic vein (arrow) with heterogeneous hepatic parenchymal enhancement.

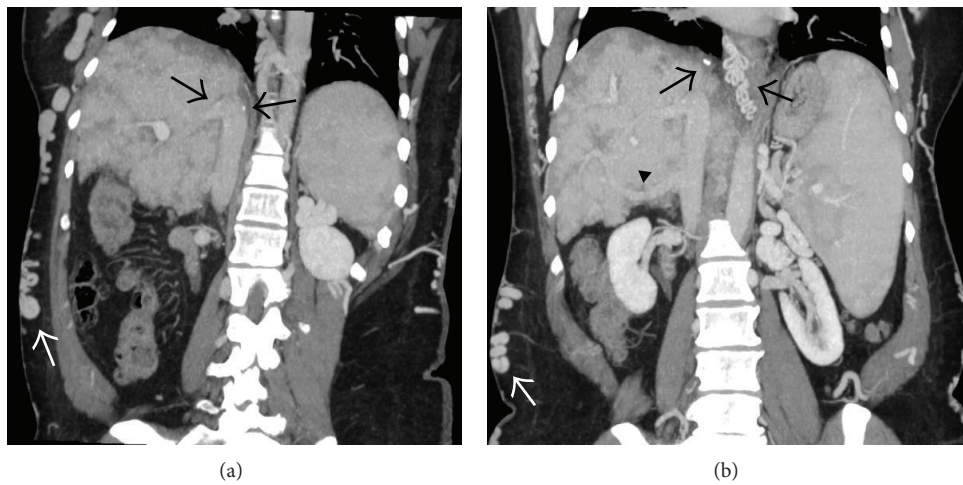


FIGURE 21: Coronal CECT images demonstrating mural calcification involving the IVC (long thin black arrows in (a) and (b)) secondary to chronic thrombosis. Multiple superficial abdominal wall and paraesophageal collaterals (white arrows and short thick black arrow, resp.) along with a prominent accessory vein (arrowhead) can also be seen.

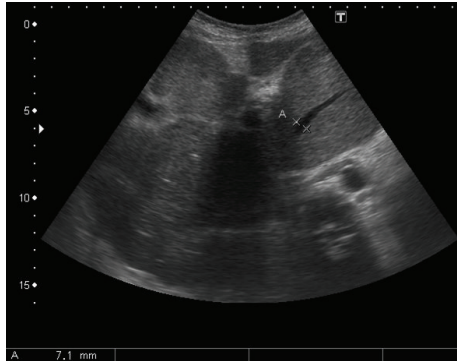


FIGURE 22: Prominent caudate lobe vein (marked by calipers; measuring 7 mm) in setting of BCS.

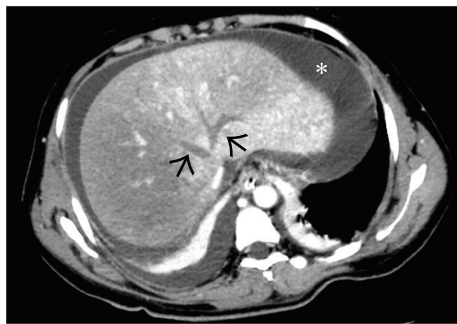


FIGURE 23: Thrombosed middle and left hepatic veins appearing as hypodense nonenhancing structures (arrows) on a background of heterogeneous liver parenchyma and ascites (asterisk).

On CT, the thrombosed HV are hypoattenuating or not visualized in the acute phase, and the IVC is compressed by the hypertrophied caudate lobe [30] (Figures 23 and 16). Ascites and splenomegaly are commonly found. T2\*-weighted gradient-recalled echo sequences can demonstrate absence of flow in the HV and IVC. However, postcontrast T1-weighted images are ideal to reveal the venous occlusion.

But one of the most specific signs of chronic BCS is the visualization of intrahepatic “comma-shaped” bridging venovenous collaterals which communicate between an occluded and nonoccluded HV or caudate lobe vein and reveal a continuous monophasic flow [12] (Figures 24–27). These have been noted in more than 80% of cases of BCS [33]. A “spider web” pattern of intrahepatic collaterals can also be sometimes seen signifying multiple intrahepatic communications between the hepatic veins (Figure 28). In addition, intrahepatic vessels communicating with a systemic vein through surface/subcapsular collaterals can also be observed. In cases of IVC obstruction, extrahepatic collateral channels including abdominal wall varices can develop bypassing the occluded segment [34] (Figure 29). Cho et al. [35] have classified the types of collaterals that can be seen in BCS (Box 3).

Due to the highly variable and nonspecific presentation of the disease, a diagnosis of BCS must be considered in all patients with an acute or chronic liver disease, when the

- |   |
|---|
| <ul style="list-style-type: none"> <li>(1) Intrahepatic collaterals</li> <li>(2) Extrahepatic collaterals               <ul style="list-style-type: none"> <li>(I) Inferior phrenic-pericardiophrenic collaterals</li> <li>(II) Superficial abdominal wall collaterals</li> <li>(III) Left renal-hemiazygous pathway</li> <li>(IV) Vertebro-lumbar azygous pathway</li> </ul> </li> </ul> |
|---|

Box 3: Different types of collateral pathways described in association with BCS (Figures 24–31).

common causes for liver disease have been excluded. Thus, assessment of the patency of HV and IVC should be a part of routine protocol of patients with liver disease, especially in endemic regions.

**2.4. Treatment.** In patients not responding to anticoagulation and nutritional therapy, radiological and surgical interventions may be contemplated including placement of portosystemic shunts and liver transplantation. In patients with short segment occlusion of HV or IVC, balloon angioplasty or stent insertion can be performed [3, 4, 12, 33, 36]. Imaging follow-up at routine intervals is necessary in all these cases to determine the long-term results of intervention. US examination coupled with Doppler is usually adequate to evaluate the patency of the native vessels or stents after intervention (Figure 14). Presence of ascites and any associated liver parenchymal changes can also be simultaneously assessed. However, cross-sectional imaging or catheter angiography may be required in cases of equivocal findings on Doppler or when the symptoms for which the intervention was performed have recurred in spite of an apparently normal Doppler study.

### 3. Portal Vein Thrombosis

Obstruction of PV or its branches may be secondary to thrombosis or due to encasement or infiltration by a tumor (Box 4). It can present acutely with sudden onset of right upper quadrant pain, nausea, and/or fever. However, in most patients, PVT occurs slowly and silently with patients presenting with vague abdominal pain and features of portal hypertension. It is often not discovered until gastrointestinal hemorrhage develops, or unless the thrombosis is detected during routine surveillance for a known underlying pathologic condition. In third world countries, it accounts for up to 30% and 75% of cases of portal hypertension in adults and children, respectively [37]. Thus, from a clinical standpoint, PVT can be divided into acute or chronic [38]. PVT occurring in children and in patients with cirrhosis can be considered separately as their features and management differ from the other group of patients [9].

**3.1. Etiology.** Several etiological causes, either of local or systemic origin, might be responsible for PVT development (Box 4), although more than one factor is often identified [39]. A local risk factor can be identified in up to 30% of

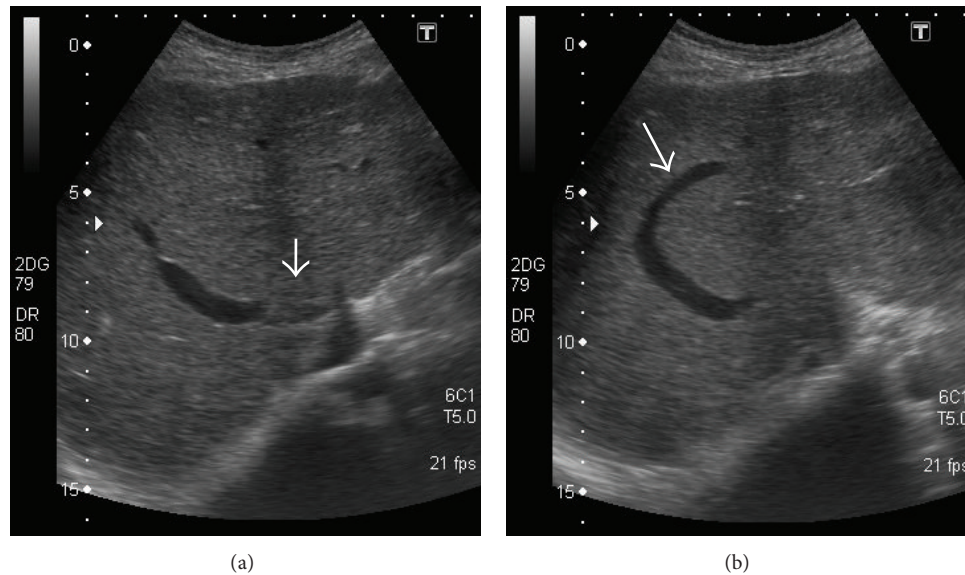


FIGURE 24: Gray-scale US images demonstrating thrombosed distal portion of right hepatic vein (arrow in (a)) with a typical *comma-shaped* venovenous collateral (arrow in (b)).

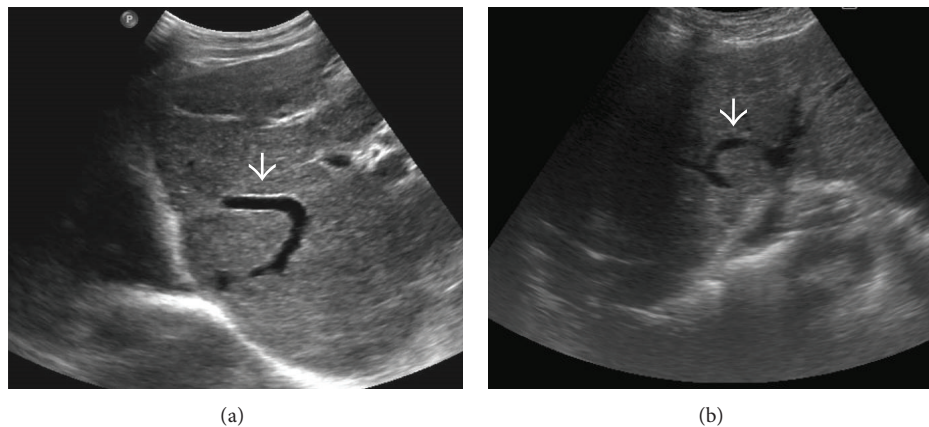


FIGURE 25: Other examples of *comma-shaped* collaterals (arrows) on US.

cases of PVT: cirrhosis and malignant tumors accounting for the majority of them [9, 39–42]. In the rest of the patients, the most common local factor for PVT is an inflammatory focus in the abdomen [38, 43, 44]. However, presence of cirrhosis, malignancy, and other intra-abdominal causes such as inflammation do not exclude the presence of systemic risk factors and the two may often coexist [9]. Local factors are usually recognized at the acute stage of PVT than the chronic stage [38]. Systemic risk factors are similar in prevalence in patients with acute and chronic PVT. An inherited or acquired hypercoagulable state is the usual culprit [39, 45–48].

**3.2. Acute Portal Vein Thrombosis.** Acute formation of a thrombus within the portal vein can be complete or eccentric, leaving a peripheral circulating lumen. The thrombus can also

involve the mesenteric veins and/or the splenic vein. In cases of complete acute thrombosis, the patient usually presents with abdominal pain of sudden onset. Peritoneal signs, however, are usually absent except when an inflammatory focus is the cause of PVT or when PVT is complicated by intestinal ischemia. Acute PVT associated with an intra-abdominal focus of infection is frequently referred to as acute pylephlebitis. Clinical features of pylephlebitis include a high, spiking fever with chills, a painful liver, and sometimes shock. Small liver abscesses are common in this setting.

Depending on the extension, PVT can be classified into four categories [49]: (1) confined to the PV beyond the confluence of the SV; (2) extended to the SMV, but with patent mesenteric vessels; (3) extended to the whole splanchnic venous system, but with large collaterals; or (4) with only fine collaterals. This classification is useful to

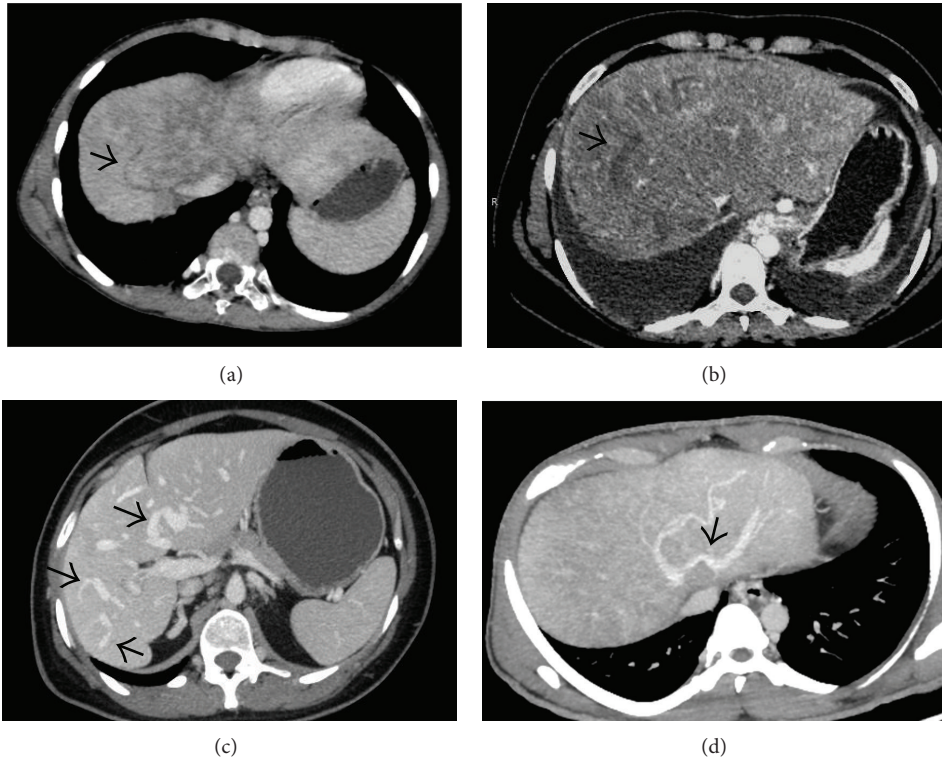


FIGURE 26: Axial CECT images from four different patients demonstrating *comma-shaped* intrahepatic collaterals (arrows) demonstrating varying degrees of patency.

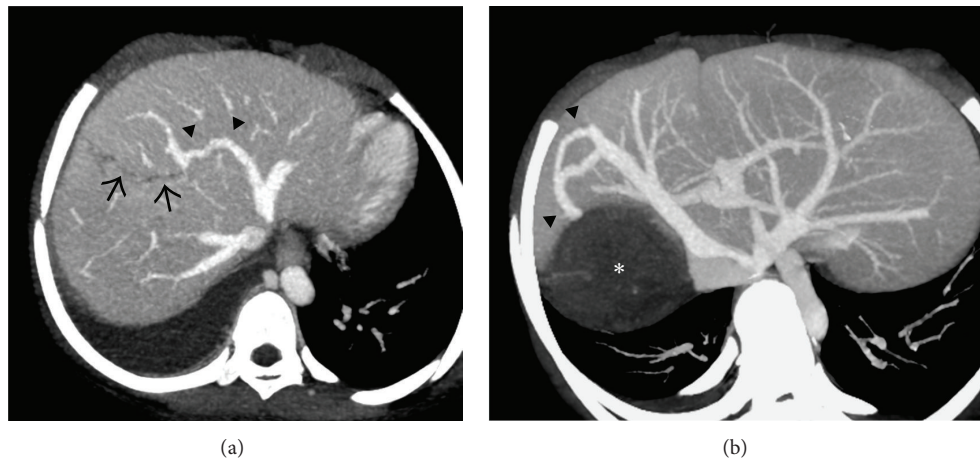


FIGURE 27: Secondary BCS in two different patients. (a) Axial maximum-intensity-projection (MIP) CECT image in a patient with past history of blunt trauma to the abdomen demonstrating a liver laceration (arrows) which had caused thrombosis of the middle hepatic vein with resultant *comma-shaped* intrahepatic venovenous collateral (arrowheads) between the left hepatic vein and the remnant middle hepatic vein. (b) Axial MIP image from the CECT scan of a young woman with hydatid cyst of liver (asterisk) causing thrombosis of the right hepatic vein and formation of intrahepatic collateral (arrowheads) between the middle and right hepatic vein.

evaluate a patient's operability and clinical outcome. Another classification proposed by Yerdel et al. [50] is also widely accepted (Figure 32).

Liver function is usually preserved in patients with acute PVT unless the patient has an underlying liver disease such

as cirrhosis. This is because of two reasons: (1) compensatory increase in hepatic arterial blood flow (hepatic artery buffer response) and (2) rapid development of a collateral circulation from pre-existing veins in the porta hepatis (venous rescue) [51–54]. The hepatic artery buffer response

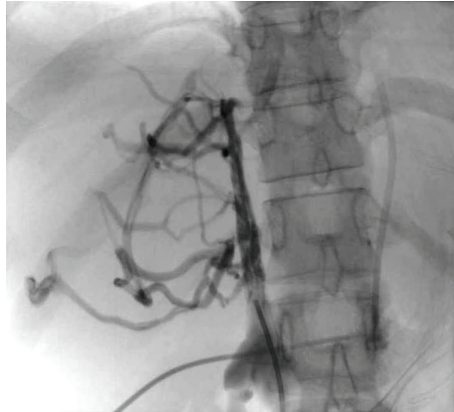


FIGURE 28: Spider web pattern of collaterals in BCS on catheter angiography.

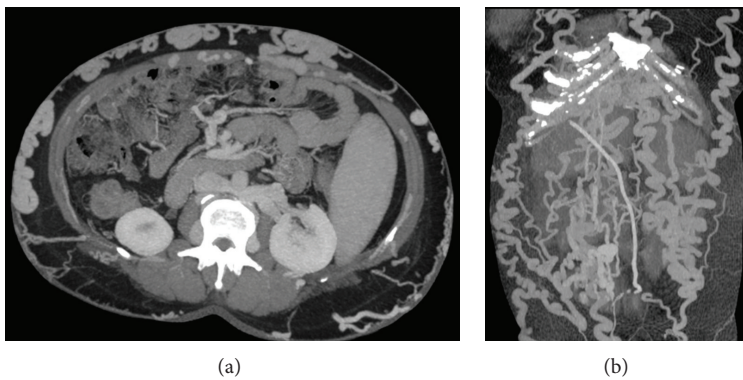


FIGURE 29: Axial (a) and coronal (b) MIP images showing multiple abdominal wall collaterals in a patient with IVC thrombus.

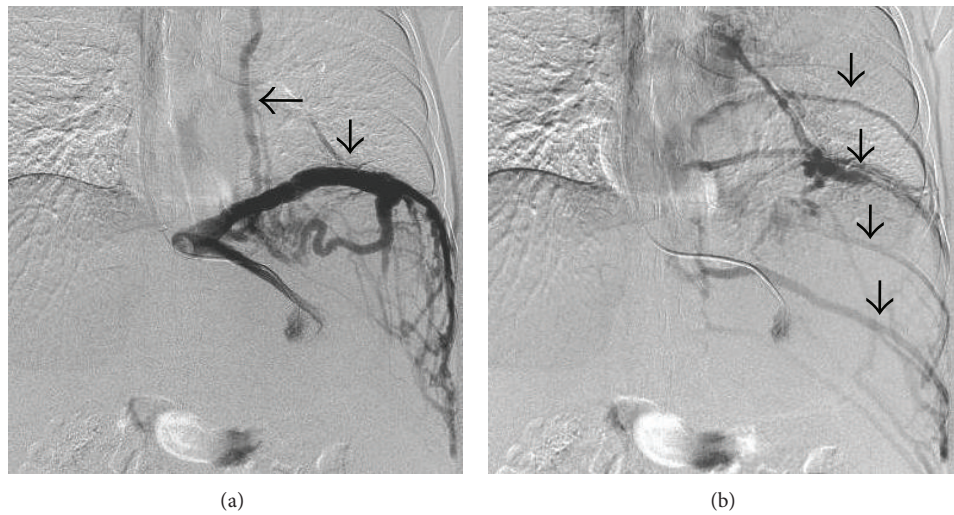


FIGURE 30: Angiogram performed via a catheter inserted in the left hepatic vein demonstrates drainage through the inferior phrenic vein (vertical arrow in (a)) and pericardiophrenic collateral (horizontal arrow) with delayed opacification of the intercostal veins as well (vertical arrows in (b)).

manifests on imaging in the form of increased hepatic parenchymal enhancement of the involved segment in the arterial phase with attendant hypertrophy of the adjoining artery. Formation of collaterals begins in a few days after portal vein obstruction and finalizes within 3 to 5 wk [53, 54]. As long as there is no extension of the thrombus to mesenteric

venous arches, all manifestations of acute PVT are completely reversible, either by recanalization or by development of a cavernoma [9].

It is clear from the above discussion that PVT is an ongoing process. Hence, a clear distinction between acute or chronic thrombus cannot always be made due to a

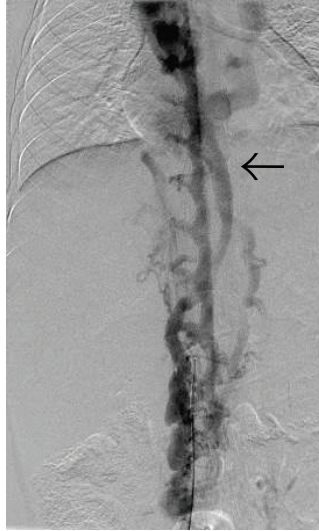


FIGURE 31: IVC angiogram demonstrating opacification of the intervertebral venous plexus and hemiazygous vein (arrow).

<p>Cirrhosis          Abdominal malignancies (hepatic, pancreatic etc.)          Hypercoagulable states (both inherited and acquired; see Box 1)          Myeloproliferative disorders          Local inflammation            Umbilical vein catheterization            Appendicitis            Diverticulitis            Pancreatitis            Cholecystitis            Duodenal ulcer            Inflammatory bowel disease            Tubercular lymphadenitis          Traumatic/Iatrogenic            Splenectomy, gastrectomy, colectomy, cholecystectomy            Liver transplantation            Abdominal trauma            Surgical/radiological porto-systemic shunting</p>
---

Box 4: Causes of portomesenteric venous thrombosis.

considerable overlap between the two clinical situations. Formation of portal cavernoma has been suggested to be a marker of chronicity but it has been debated [55, 56].

**3.3. Imaging Diagnosis.** Imaging diagnosis of acute PVT can be readily made using noninvasive methods.

**3.3.1. US and Doppler.** Ultrasound is a reliable noninvasive technique with a high degree of accuracy for the detection of PVT and is the investigation of choice. It has a reported sensitivity and specificity ranging between 60% and 100% [57]. Gray-scale ultrasound usually demonstrates hyperechoic material within the vessel lumen with occasional distension of the vein [39, 58, 59] (Figure 33(a)). Many times, a recently formed thrombus is virtually anechoic; hence

an ultrasound Doppler is required for its demonstration. Doppler imaging will show absence of flow in part or all of the lumen [60]. Attendant hypertrophy of the hepatic artery can also be demonstrated (Figure 33(b)).

Endoscopic ultrasound (EUS) may have comparable sensitivity and specificity to colour Doppler (81% and 93%, resp.) in the diagnosis of PVT and appears to be more accurate than US or CT scan in assessment of portal invasion by tumours [61–63]. However, it is difficult to optimally visualize the intrahepatic portion of portal vein by EUS which remains a drawback.

Recently, contrast-enhanced ultrasound (CEUS) has also been utilized to differentiate benign and malignant PVT using independent criteria [64, 65] (Figure 34). Use of pulsatile flow in a portal vein thrombus as the criterion for diagnosing malignant PVT yielded sensitivity of 82.5% and

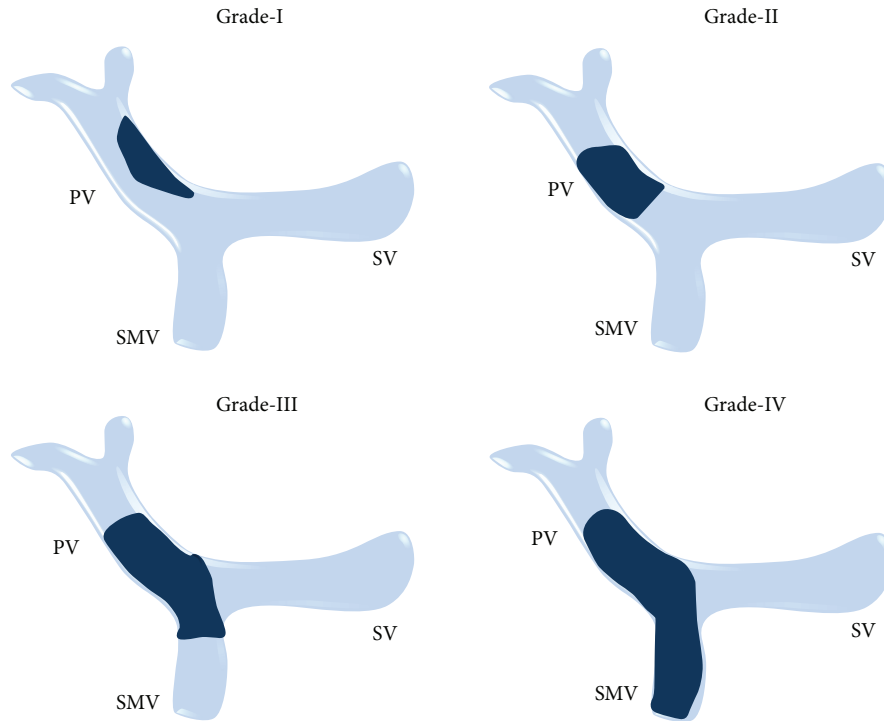


FIGURE 32: Classification of PVT proposed by Yerdel et al.

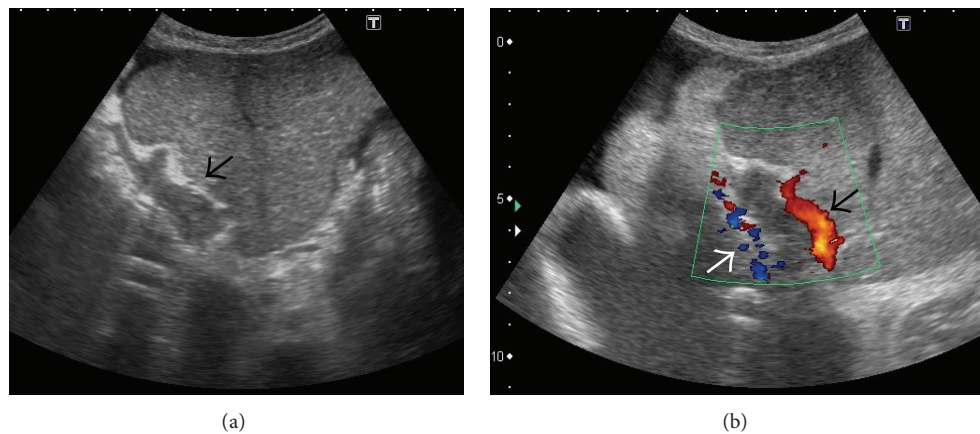


FIGURE 33: Gray-scale US image showing thrombosed left portal vein (arrow in (a)). On application of colour Doppler (b), hypertrophy of the accompanying branch of hepatic artery can be seen (black arrow in (b)) with opening up of periportal collateral venous channels (white arrow).

specificity of 100%, whereas positive enhancement of the PVT itself as a criterion for diagnosing malignancy yielded overall sensitivity and specificity of 100% for each [64]. In another study, CEUS could conclusively differentiate between benign and malignant PVT in 37 of 38 patients (97% sensitivity) [65].

**3.3.2. CT.** A CT scan without contrast can show hyperattenuating material in the PV [66–68] (Figure 35(a)). After injection of contrast agent, lack of luminal enhancement is seen (Figure 35(b)). In addition, increased hepatic parenchymal enhancement in the arterial phase which becomes isodense

to the liver in the portal venous phase is common and is described as transient hepatic enhancement difference [68–70] (Figures 36 and 37). Rim enhancement of the involved vessel may be noted due to flow in the dilated vasa vasorum or thrombophlebitis [71] (Figure 38). In contrast with a bland thrombus that is seen as a low density, nonenhancing defect within portal veins, a tumour thrombus enhances following contrast administration [72]. For the assessment of thrombus extension within the portal venous system as well into the mesenteric veins, CT or MR angiography is more sensitive techniques than Doppler sonography, because the mesenteric

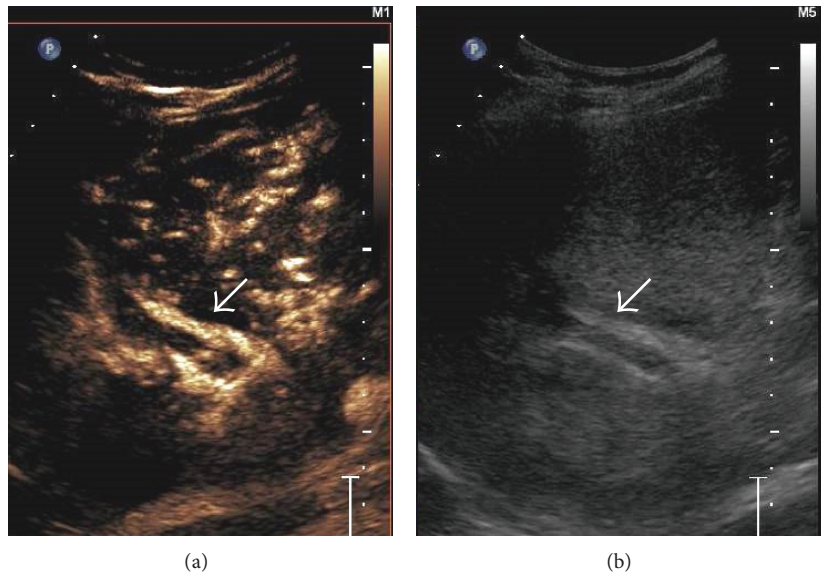


FIGURE 34: Side-by-side contrast-enhanced US (a) and gray-scale image (b) demonstrating absence of enhancement of the portal vein thrombus in the arterial phase (arrow in (a)) signifying benign nature of the thrombus.

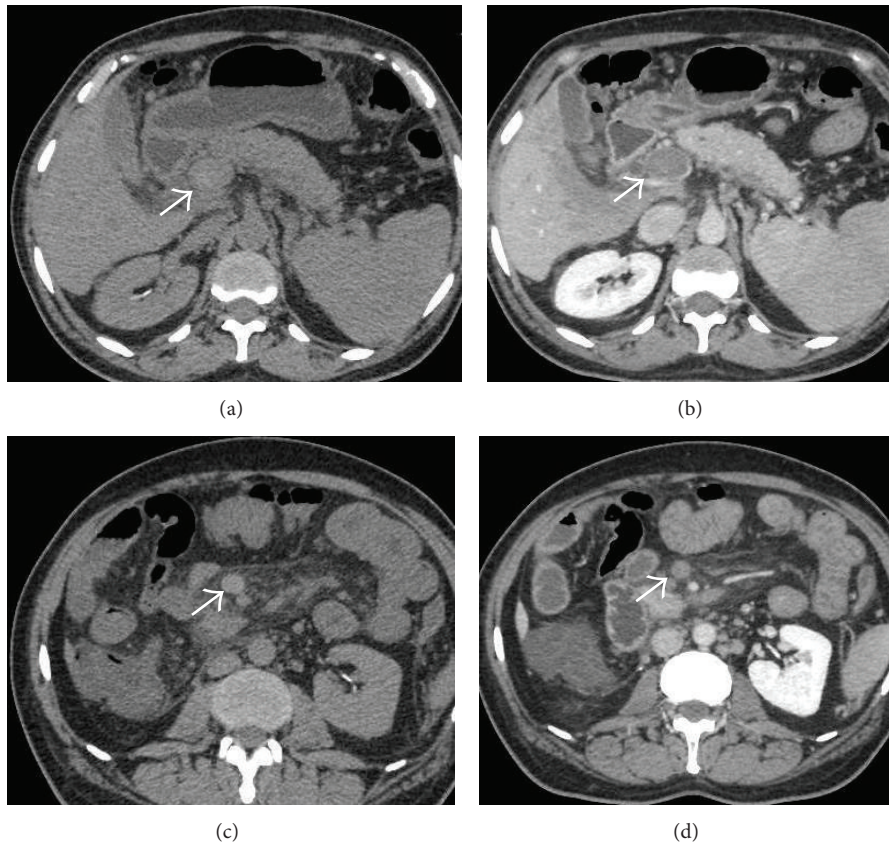


FIGURE 35: Axial NCCT (a) and CECT (b) images demonstrating mildly hyperdense thrombus occluding the main portal vein (arrows). Corresponding images at a caudal level in the same patient showing hyperdense thrombus in the SMV with associated fat stranding in the adjoining mesentery.



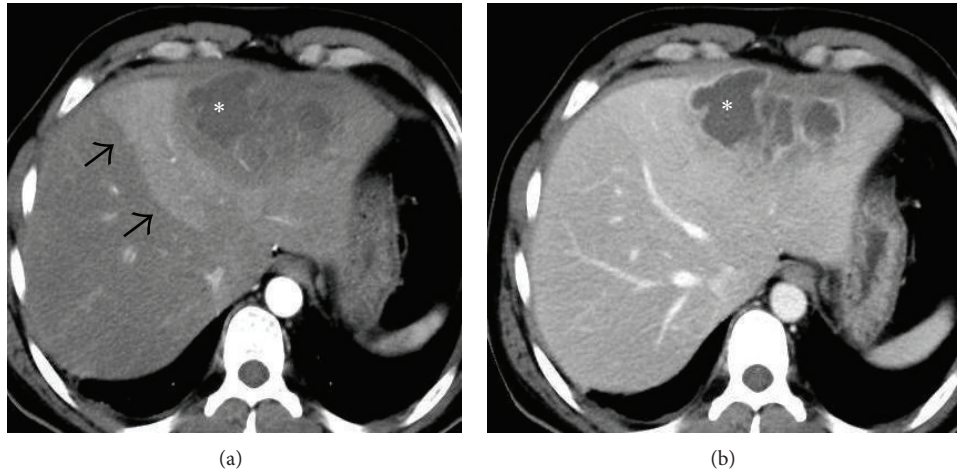


FIGURE 36: Axial CECT images obtained in the arterial (a) and venous (b) phases showing an abscess in the left lobe (asterisk) which had caused acute thrombosis of the left portal vein (pylephlebitis). Associated hepatic artery buffer response is seen in the form of increased enhancement of the left hepatic lobe in the arterial phase (arrows in (a)) which becomes essentially isodense on the portal venous phase.

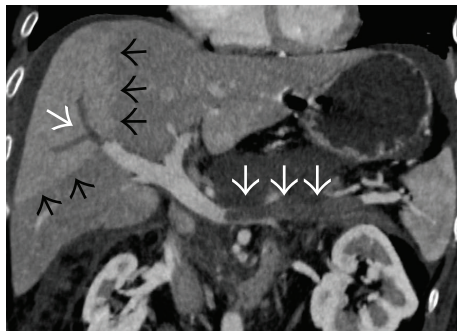


FIGURE 37: Coronal oblique CECT image of a patient with acute necrotizing pancreatitis demonstrates thrombosed splenic vein (thick white arrows) and a segmental branch of right portal vein (thin white arrow) with hepatic artery buffer response in the form of differential hyperenhancement of the affected liver segment (black arrows).

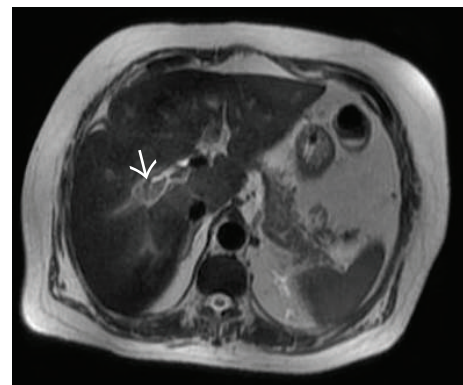


FIGURE 39: Axial T2-weighted MR image demonstrating mildly hyperintense thrombus (arrow) in the right portal vein.

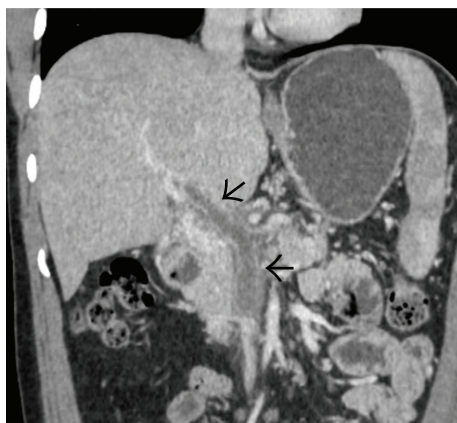

FIGURE 38: Coronal oblique CECT image demonstrating thrombosed portal vein as well as the SMV (arrows) with rim-enhancement of their walls.

veins are more difficult to visualize with ultrasound [73]. Also changes in the bowel wall (described later) can be better appreciated on cross-sectional imaging than US.

**3.3.3. MRI.** MRI is equally sensitive in detection of PVT. At spin-echo MR, the clot appears isointense on T1-weighted images, the clot appears isointense to hyperintense on T1-weighted images, and usually has a more intense signal on T2 images, while older clots appear hyperintense only on T2-weighted images [51] (Figure 39). Tumor thrombi can be differentiated from bland thrombi because they appear more hyperintense on T2-weighted images, demonstrate diffusion restriction, and enhance with gadolinium (Figures 40 and 41). Gradient-echo MR might help to better evaluate any equivocal findings on spin-echo MR image [51]. Contrast-enhanced MR angiography (CE-MRI) is superior to Doppler US in detecting partial thrombosis and occlusion of the main portal venous vessels [57]. It also identifies portosplenic collaterals more adequately than colour Doppler.

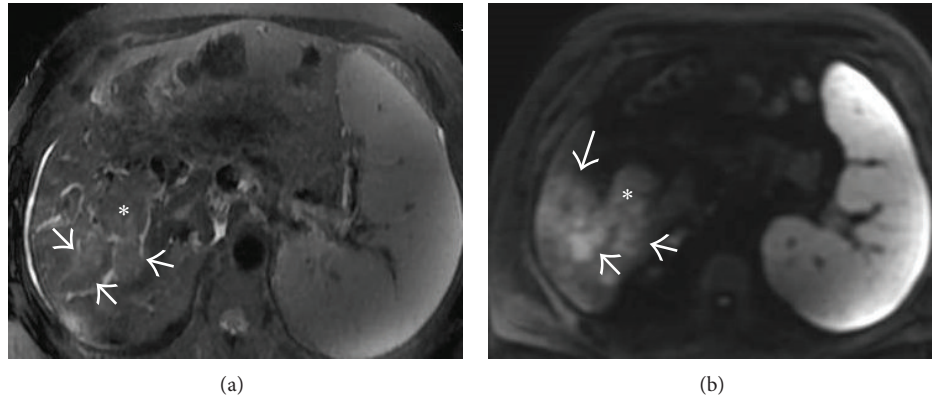


FIGURE 40: (a) Axial T2-weighted fat saturated image in a patient with liver cirrhosis and multifocal hepatocellular carcinoma showing occlusive heterogeneously hyperintense tumor thrombus (asterisk and arrows) expanding the right portal vein. It shows diffusion restriction (asterisk and arrows in (b)). One of the tumoral masses can also be seen on this image (thick arrow).

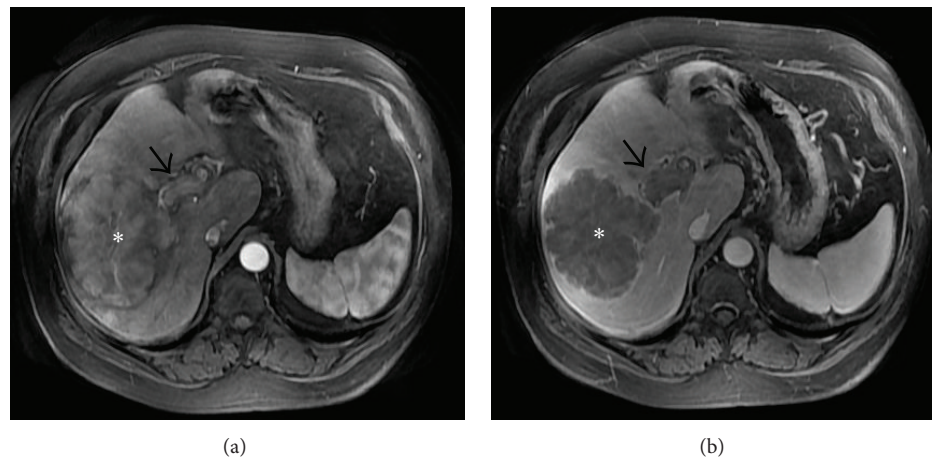


FIGURE 41: Axial CEMRI images obtained in the arterial (a) and venous (b) phases showing a lobulated lesion showing arterial phase enhancement (asterisk in (a)) with washout of contrast on the venous phase. Associated enhancing right portal vein tumor thrombus (arrows) is present.

**3.4. Treatment.** The goal of treatment in acute PVT is recanalization of the thrombosed vein using anticoagulation and thrombolysis (either transcatheter or surgical) to prevent the development of portal hypertension and intestinal ischemia. When local inflammation is the underlying cause for the PVT, appropriate antibiotic therapy is warranted with correction of the causal factors, if needed [9].

**3.5. Chronic Portal Vein Thrombosis.** When acute PVT is asymptomatic and goes undetected, patients present later in life and are diagnosed either incidentally on imaging done for unrelated issues or when investigations for portal hypertension related complications are carried out. In patients with chronic PVT, the actual thrombus is commonly not visualized. Rather, the obstructed portal vein is replaced by a network of portoportal collateral veins bypassing the area of occlusion (portal cavernoma) [54]. However, these collaterals are not sufficient and do not normalize hepatopetal blood flow and hence eventually portal hypertension develops [74].

The development of a collateral circulation, with its attendant risk of variceal hemorrhage, is responsible for most of

the complications and is the most common manifestation of PV obstruction [74]. Bleeding is generally well-tolerated and bleed-related mortality in patients with PVT is much lower than in patients with cirrhosis, probably due to preserved liver function and because the patients are usually younger [44, 75–80]. Usually the gastroesophageal varices are large in size and gastric varices are particularly more frequently seen in 30–40% patients [81]. Ectopic varices are significantly more frequent in patients with chronic PVT than in patients with cirrhosis and occur commonly in the duodenum, anorectal region, and gallbladder bed [82–84]. Collaterals can also develop along the gastroepiploic pathway (Figure 42). Other sequelae of the subsequent portal hypertension, such as ascites, are less frequent.

### 3.6. Imaging Features and Diagnosis

**3.6.1. US and Doppler.** Portal cavernoma produces a distinctive tangle of tortuous vessels in the porta hepatis which can be easily demonstrated on US and Doppler [85] (Figure 43). Gall bladder wall varices can also be seen which should not

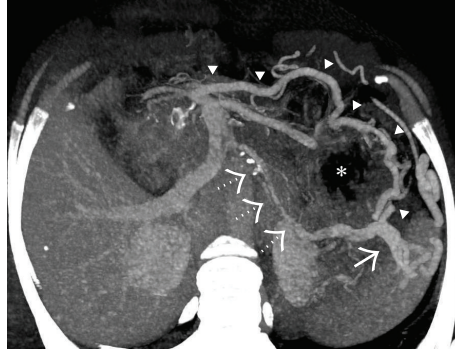

FIGURE 42: Axial MIP image showing a severely attenuated and partially calcified retropancreatic splenic vein (interrupted arrows) resulting in formation of a prominent gastroepiploic collateral channel (arrowheads) between the SMV and the remnant splenic vein at splenic hilum (solid arrow) along the greater curvature of stomach. Asterisk denotes the gastric lumen.

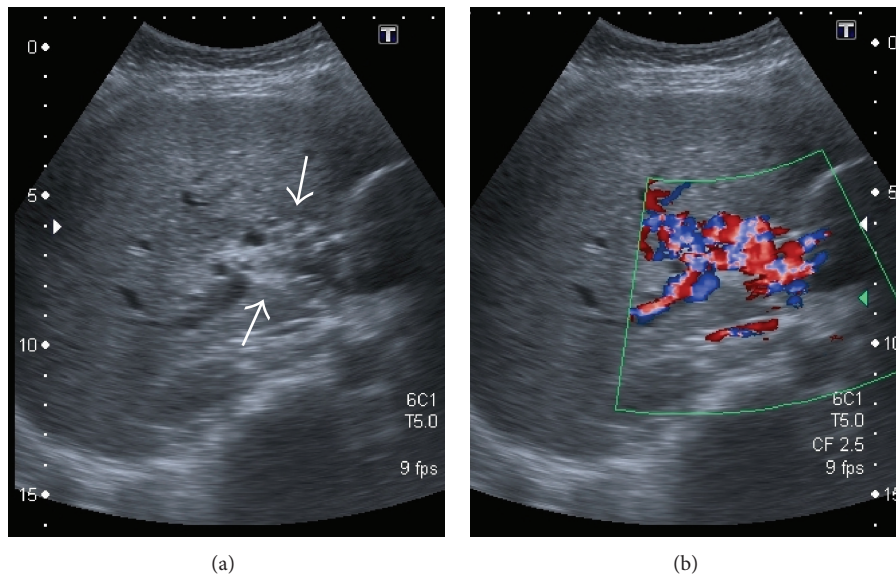


FIGURE 43: Gray-scale US (a) image showing replacement of the main portal vein by an ill-defined echogenic area containing multiple subtle anechoic tubular structures. On application of colour Doppler (b) turbulent flow can be seen within these anechoic structures consistent with portal cavernoma.

be confused with acute cholecystitis. For the diagnosis of chronic PVT, Doppler USG has a sensitivity and specificity above 95% and should be the initial imaging investigation of choice in these patients [86, 87].

**3.6.2. CT and MRI.** Cross-sectional imaging can assess the true extent of the periportal collaterals as well associated manifestations of chronic PVT like splenomegaly, portosystemic collaterals, and shunts in relation to portal venous system [68, 88]. They also give anatomical road-map prior to shunt surgery [87]. In the absence of cirrhosis, there might be an enlarged caudate lobe, together with an atrophic left lateral segment or right lobe of the liver and hypertrophied hepatic artery [89, 90]. Typically, the umbilical vein is not dilated as it connects to the left portal vein branch downstream of the obstruction [9].

**3.7. Portal Hypertensive Biliopathy/Portal Cavernoma Cholangiopathy.** Periportal collaterals can produce compression and deformation of the biliary tract (both extra- and intrahepatic) and gall bladder wall resulting in the so-called portal hypertensive biliopathy [91, 92] (Figure 44) also called as portal cavernoma cholangiopathy. These collateral veins are caused by reopening of the two preformed venous systems near the extrahepatic bile ducts-epicholedochal (ECD) venous plexus of Saint [93] and the paracholedochal (PACD) veins of Petren [94]. The ECD plexus of Saint forms a mesh on the surface of the common bile duct (CBD) while the PACD venous plexus of Petren runs parallel to the CBD. Engorgement of these collaterals can cause compressive and ischemic changes on the biliary tree manifesting as indentations, strictures, intrahepatic biliary radicles dilatation, and intraductal lithiasis (Figures 45–47). Dilatation of epicholedochal veins results in thickened and enhancing

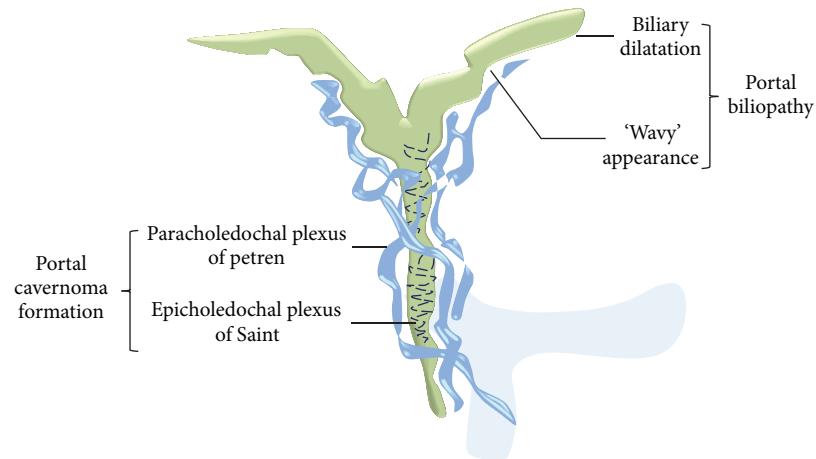


FIGURE 44: Graphic illustration demonstrating opening up of epi- and paracholedochal venous collaterals in chronic PVT causing portal biliopathy.

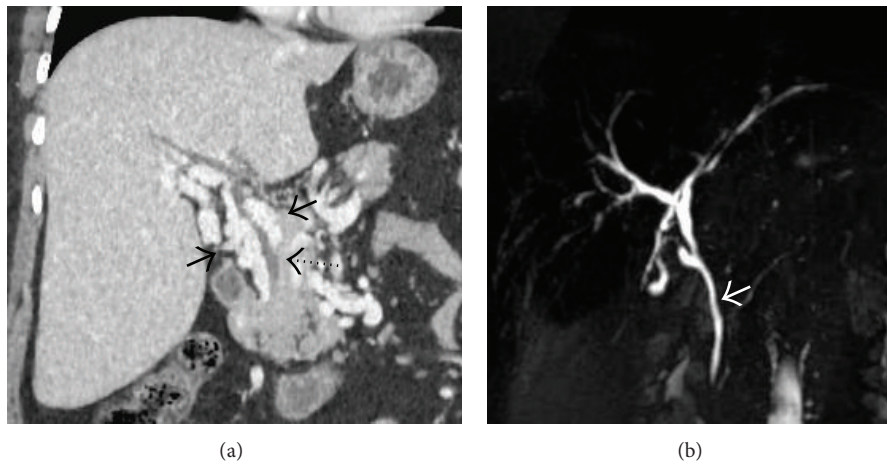


FIGURE 45: Coronal oblique CECT image (a) showing multiple paracholedochal collaterals (solid black arrows) causing extrinsic compression over the CBD (interrupted arrow). (b) 2D MRCP image of the same patient demonstrating undulating margins of CBD (arrow) due to the compression.

bile duct walls on cross-sectional images and may simulate a mass (pseudocholangiocarcinoma sign) [91] (Figure 48). The left hepatic duct is involved more commonly (38–100%) and severely [87]. Portal biliopathy usually remains asymptomatic (62–95%) [87]. Common symptoms are jaundice, biliary colic, and recurrent cholangitis and are seen with longstanding disease and presence of stones [95–99]. Various sequelae like choledocholithiasis, cholangitis, and secondary biliary cirrhosis can develop in longstanding disease [87]. MRCP is the first line of investigation [100]. ERCP is only recommended if a therapeutic intervention is contemplated [100]. MRCP is also helpful in differentiating choledochal varices from stones. Endoscopic ultrasonography may also show the characteristic lesions of portal biliopathy [101, 102]; however, it is not recommended as a part of routine work-up.

**3.8. Treatment.** Therapy for chronic PVT basically revolves around management of complications of portal hypertension

including gastrointestinal bleeding, hypersplenism, and ascites [9]. Prevention of extension of thrombosis and treatment of portal biliopathy are other facets of treatment [9].

**3.9. Extrahepatic Portal Venous Obstruction.** It is a distinct clinical entity characterized by obstruction of extrahepatic PV with or without involvement of intrahepatic PV branches in the setting of a well preserved liver function. It does not include isolated thrombosis of SV or SMV [87, 100].

PVT seen in cirrhosis or HCC usually involves the intrahepatic PV radicals and is not associated with portal cavernoma formation or development of portal hypertension, both of which are integral to the definition of EHPVO [87]. It is a primarily childhood disorder but can present at any age. Patients usually present with symptoms or complications of secondary portal hypertension including variceal bleeding

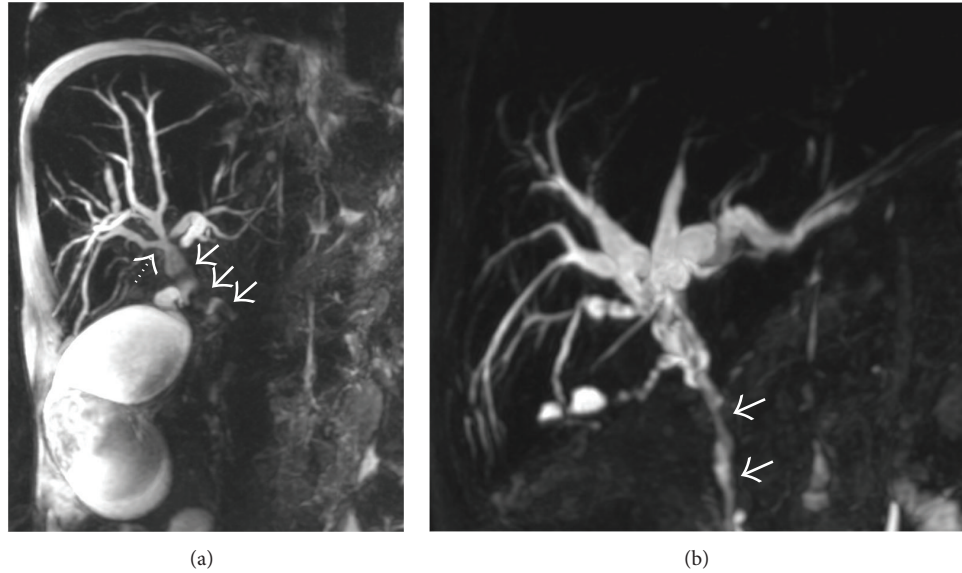


FIGURE 46: (a) Thick-slab 3D MRCP image of a patient with portal biliopathy demonstrating extrinsic vascular impression over CBD by the paracholedochal collaterals (solid arrows). The distal CBD is narrowed by these collaterals with resultant upstream biliary dilatation. Undulating margins of biliary system can also be seen (interrupted arrow) with a grossly distended gall bladder. (b) 3D MRCP image from another patient showing wavy contour of the mid- and distal CBD due to portal biliopathy with resultant narrowing and gross bilobar biliary dilatation.

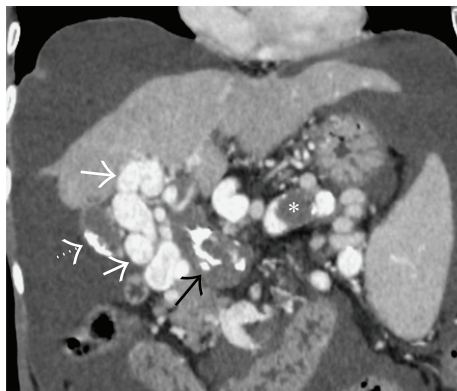


FIGURE 47: Coronal oblique CECT image showing chronic, partially calcified, occlusive thrombus involving the main portal vein (black arrow) with multiple tortuous periportal collateral channels (solid white arrows). Splenic vein is also partially thrombosed (asterisk). Gall bladder calculi (interrupted arrow) and ascites can also be seen.

ascites and feature of hypersplenism. Jaundice can develop due to portal biliopathy but is usually not severe [87].

**3.10. Treatment.** Therapeutic approach is primarily focused on management of an acute episode of variceal bleeding followed by secondary prophylaxis [87]. Other issues such as hypersplenism, growth retardation, portal biliopathy, and minimal hepatic encephalopathy need to be individualized depending on the age of presentation, site and nature of obstruction, and clinical manifestations [87].

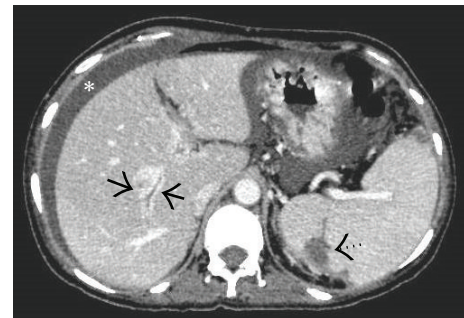


FIGURE 48: Axial CECT image of a patient with EHPVO showing multiple tiny paracholedochal collaterals appearing as continuous enhancement of one of the biliary radicals in right hepatic lobe (arrows) mimicking cholangiocarcinoma (pseudocholangiocarcinoma sign). Splenic infarct is also seen due to associated splenic vein thrombosis (interrupted arrow) along with ascites (asterisk).

**3.11. Portal Vein Thrombosis in Patients with Cirrhosis.** PVT is most common in patients with preexisting cirrhosis. The prevalence of PVT increases with the severity of the cirrhosis, being less than 1% in patients with compensated cirrhosis [103], but 8%–25% in candidates for liver transplantation [104]. In patients with cirrhosis, portal venous obstruction is commonly related to invasion by hepatocellular carcinoma [105]. Neoplastic obstruction should always be considered, especially when the portal vein is larger than 23 mm in diameter, when thrombus demonstrates arterial phase enhancement (known as *threads-and-streaks* pattern of enhancement) [70, 105] (Figure 49), when pulsatile flow is seen on Doppler

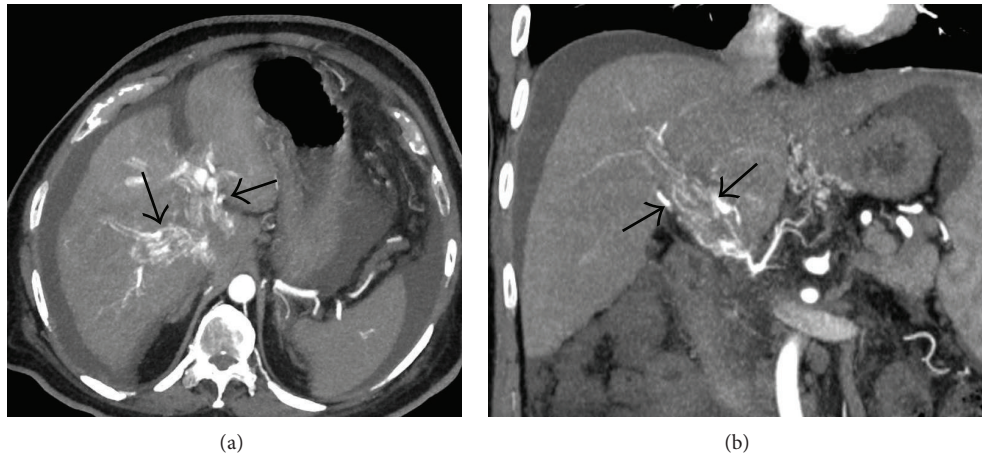


FIGURE 49: Axial (a) and coronal (b) MIP images of a patient with liver cirrhosis and multifocal hepatocellular carcinoma demonstrating multiple thin streaks of arterial phase enhancement within the main portal vein (arrows in (b)) as well as its intrahepatic branches (arrows in (a)) consistent with tumor thrombus (*threads-and-streaks* sign).

ultrasound, and when serum alpha fetoprotein levels are increased [106].

#### 4. Mesenteric Vein Thrombosis

Although arterial causes of acute mesenteric ischemia are far more common than venous causes, venous thrombosis still accounts for about 5%–20% of cases of mesenteric ischemia and remains an important cause of acute bowel infarction [107–110]. They are most often the result of a thrombosis of the SMV [111]. Owing to their nonspecific clinical presentation, imaging plays a critical role in the early diagnosis of MVT. With the improvements in contrast and spatial resolution, both in CT and MRI, bowel wall abnormalities resulting from a lack of venous drainage can be assessed accurately, while correctly depicting the mesenteric arterial circulation.

**4.1. Clinical Features.** Patients with acute MVT usually present with abdominal pain out of proportion to the physical findings, nausea, vomiting, and constipation, with or without bloody diarrhea [110]. Abdominal symptoms may then gradually worsen with the development of peritonitis, which indicates intestinal infarction and can be seen in one-third to two-thirds of patients with acute MVT [112]. Abdominal distension can be present in up to 50% of cases [110]. Patients with chronic MVT are often asymptomatic due to extensive venous collateralization and are unlikely to develop intestinal infarction. Complications such as variceal bleeding can occur in late stages secondary to portal hypertension. Weight loss, food avoidance, vague postprandial abdominal pain, or distention may be present. The pain usually occurs within the first hour after eating, diminishing over the next 1-2 hours. Chronic thrombosis of the portomesenteric vasculature is usually detected as an incidental finding during evaluation of other abdominal pathologic conditions, such as portal hypertension, malignancy, or chronic pancreatitis [110].

**4.2. Classification of MVT.** MVT is classified on the basis of etiology into either primary or secondary [111]. It is considered primary, or idiopathic, when no predisposing factor can be found. Due to an increased awareness of predisposing disorders and improvements in imaging technology, the incidence of idiopathic MVT continues to decline [113, 114]. Patients with a predisposing condition such as prothrombotic and myeloproliferative disorders, neoplasms, diverse inflammatory conditions, recent surgery, portal hypertension, and miscellaneous causes such as oral contraceptives or pregnancy are said to have secondary MVT (Box 4).

**4.3. Anatomy of the Mesenteric Venous System.** Multiple small veins (*venae rectae*) originate from the bowel wall and join to form venous arcades. Small bowel and the proximal colon as far as the splenic flexure are drained by these venous arcades through the pancreaticoduodenal, jejunal and ileal, ileocolic, right colic, and middle colic veins. The confluence of these veins forms the SMV. The inferior mesenteric vein (IMV) can drain either directly into the SV, into the SMV, or into the angle of the splenoportal confluence. It drains the splenic flexure, descending colon, sigmoid colon, and part of the rectum.

**4.4. Pathophysiology of Bowel Ischemia.** The location and extent of venous thrombosis and the status of collateral circulation are important predictors of bowel ischemia and subsequent infarction. It has been demonstrated that patients with thrombosis of the *venae rectae* and venous arcades are at greater risk of developing bowel abnormalities than the ones with thrombosis confined to the SMV close to the splenoportal confluence [115].

Etiology of the thrombosis often determines the location of the thrombosis. Intra-abdominal infections like pancreatitis affect the larger veins first while hematological disorders

involve the smaller veins first followed by the larger venous trunks [112].

When the thrombus evolves slowly and there is enough time for the collaterals to develop, bowel infarction is unlikely [116].

#### 4.5. Imaging

**4.5.1. Plain Radiography/Barium Studies.** Most often, a non-specific pattern of dilated, fluid-filled bowel loops can be demonstrated on these studies. Submucosal hemorrhage leading to mural thickening and the so-called “thumbprinting,” bowel separation due to mesenteric thickening, pneumatosis intestinalis, and portomesenteric venous gas can occasionally be seen in late-stage disease. However, the findings are often nonspecific and of little or no use in diagnostic evaluation [117, 118].

**4.5.2. US and Doppler.** Doppler US allows direct real-time evaluation of the mesenteric veins and provides flow information of the visceral vessels; however, compared to the pivotal role played by Doppler US in the detection of PVT, visualization of mesenteric veins is often hampered by poor acoustic window due to the overlying bowel gases. Nevertheless, the segment of superior mesenteric vein adjoining the splenoportal confluence can frequently be imaged in experienced hands. Bowel wall thickening and free intraperitoneal fluid can also be detected providing a clue to the underlying venous abnormality.

**4.5.3. CT.** Widely considered to be the imaging investigation of choice, CT permits optimal evaluation of vascular structures, the bowel wall, and the adjacent mesentery. Multidetector row CT scanners have now enabled volumetric acquisitions in a single breath hold, eliminating motion artifact and suppressing respiratory misregistration allowing sensitivity rates of up to 95% in the detection of MVT [119]. Helical CT angiography and three-dimensional gadolinium-enhanced MR angiography should be considered the primary diagnostic modalities for patients with a high clinical suspicion of mesenteric ischemia.

Data acquisition should be performed at peak venous enhancement, with the delay between the start of injection and the commencement of image acquisition tailored for that purpose. Protocols typically use 55–70-second delays following administration of 125–150 mL of intravenous contrast medium at a rate of 3.5–5 mL/sec through a peripheral vein. Imaging is completed with coronal and sagittal reformation, with the creation of (curved) MIP images that allow the entire course of the thrombosed vein to be viewed on a single image. Unenhanced data acquisition preceding the portal phase is especially useful for detecting mural hemorrhage.

**4.5.4. Venous Abnormalities.** Thrombus appears as a well-demarcated, persistent, partial, or complete intraluminal filling defect, which may be surrounded by rim-enhancing venous walls [71] (Figure 50). It has been reported that thrombosis shown on a noncontrast-enhanced CT scan has

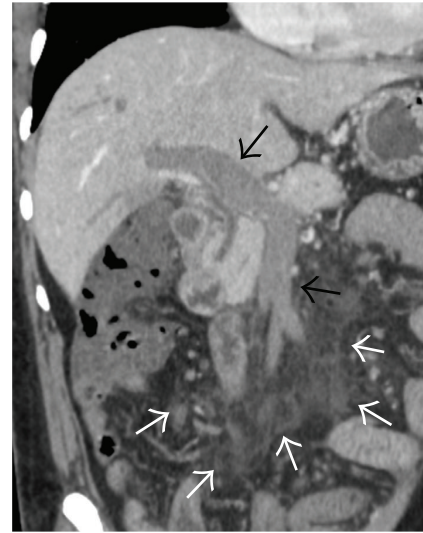


FIGURE 50: Coronal MIP image showing complete portomesenteric vein thrombosis (black arrows) with associated mesenteric stranding (white arrows).

a low density during the acute period (within 1 wk of the onset of the disease). It has a high density during the subacute period (1–3 wk after disease onset) with a CT value higher than the values for the abdominal aorta (called as the “mesenteric vein angiographic phenomenon”) (Figure 35). It has a low density during the chronic period (>3 wk) and is accompanied by lateral branch angiogenesis [120]. In case of tumoral infiltration, the thrombus may enhance following intravenous contrast administration.

Depending on the extent and amount of thrombus, enlargement of the affected vein may be seen. Marked venous enlargement can be seen in tumoral thrombus. It also serves as a useful sign to indicate acute thrombus because in chronic thrombus there tends to be atrophy of vein. Due to the congestion caused by thrombosis, engorgement of the mesenteric veins can also be seen.

**4.5.5. Bowel Abnormalities.** Associated bowel abnormalities most commonly manifests as mural thickening [121]. Wall thickening may result from intramural edema which appears as hypoattenuating bowel wall or intramural hemorrhage which causes increased attenuation of the affected bowel wall [121, 122] (Figure 51). Both of these findings are more common and prominent with venous congestion than with arterial occlusion [122].

The bowel wall may be stratified into two or three thickened walls referred to as the halo sign or target sign (Figure 52). The inner mucosal and outer muscularis propria rings of high attenuation are separated by submucosal layer of low attenuation representing edema [111].

Abnormal enhancement is also a specific sign of bowel ischemia in patients with MVT. In normal subjects, a smooth homogeneous inner rim of enhancement can be seen during the venous phase of CT. Prolonged venous congestion impedes the arterial supply, with subsequent decrease of

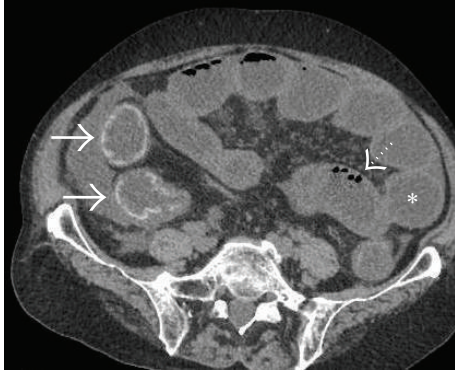


FIGURE 51: Axial NCCT image showing submucosal bowel wall hemorrhage appearing as linear hyperdense rim (solid arrows). Small bowel dilatation (asterisk) and pneumatosis intestinalis (interrupted arrow) can also be seen.

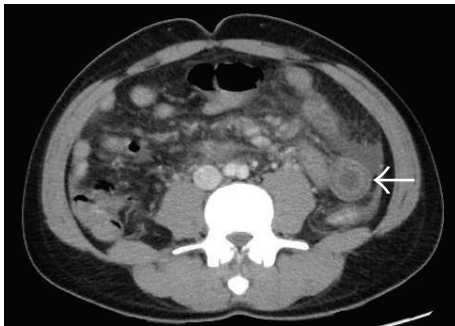


FIGURE 52: Axial CECT image demonstrating *halo sign* in one of the jejunal loops due to inner mucosal and outer muscularis propria rings of high attenuation separated by submucosal layer of low attenuation representing edema in a patient with SMV thrombosis. Extensive mesenteric stranding and minimal ascites can also be seen.

bowel wall enhancement which has been reported as highly specific for venous bowel infarction [121, 123] (Figure 53).

Bowel dilatation is a nonspecific but important sign which can result either from aperistaltic bowel (as a reflex response to ischemic injury) or transmural bowel infarction resulting in total loss of contractile function [111] (Figure 54).

In late stages, intramural gas can be seen (pneumatosis intestinalis) which may dissect into the venous system resulting in portal or mesenteric venous gas (Figures 51 and 54). Intrahepatic portal vein gas should be differentiated from aerobilia. The distribution of hepatic gas in patients with aerobilia is central, around the portal hilum, and does not extend to within 2 cm of the liver capsule [124]. Gas in mesenteric vein branches should be differentiated from pneumoperitoneum. Pneumoperitoneum does not have a linear, ramifying configuration and can be present in the antimesenteric border of the intestine. However, these signs are nonspecific and can be seen in non-ischemic causes like infection [125, 126]. Even in patients with bowel ischemia, they are not highly predictive of transmural infarction since

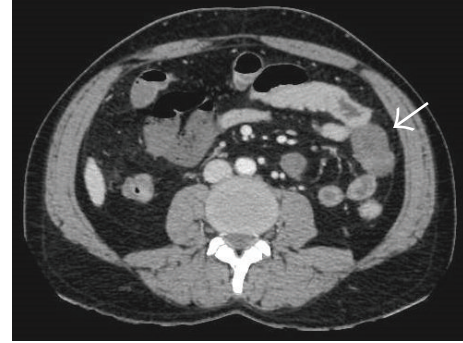


FIGURE 53: Axial CECT image showing nonenhancing loop of jejunum (arrow) due to SMV thrombosis.

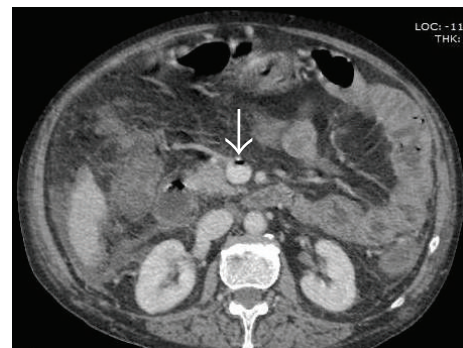

FIGURE 54: Axial CECT image showing nondependent focus of portal venous gas (arrow) with mesenteric stranding and ascites.

partial ischemia of bowel wall may also be present. Frank perforation will lead to free intraperitoneal air.

**4.5.6. Mesenteric Abnormalities.** Due to the underlying venous congestion and/or superimposed inflammatory process, mesenteric fat stranding is frequently seen with MVT (Figures 50, 52, and 54). Compared to arterial occlusion, this finding is far more common and more pronounced in cases of venous thrombosis [122]. Free intraperitoneal fluid or ascites can be seen in late stages (Figures 51, 52, and 54).

**4.5.7. MRI.** With the advent of 3D gadolinium-enhanced MR angiographic techniques with short acquisition times (single breath hold), sensitivity of MRI in detecting MVT equals that of MDCT with the added advantages of improved soft tissue resolution, lack of ionizing radiation, and better safety profile of paramagnetic agents compared with that of iodinated contrast agents. However, severity of stenosis can be overestimated on MR angiography since it indirectly relies on detection of vascular signal which can be degraded due to turbulence. Also, MR angiography is less sensitive for detection of calcification, spatial resolution is lower compared with that of CT angiography, and stents cannot be visualized due to the signal void caused by metallic material [117]. Such protocols take 30–60 minutes to complete, considerably longer than with CT angiography [117]. Thus MR



is usually reserved for patients in whom CT angiography is contraindicated.

**4.5.8. Catheter Angiography.** Conventional angiography is reserved for cases with equivocal findings on noninvasive imaging and is also used in conjunction with transcatheter therapeutic techniques in management of symptomatic portal and mesenteric venous thrombosis.

**4.6. Treatment.** Systemic anticoagulation for the prevention of thrombus propagation is the current mainstay therapy for patients with acute mesenteric venous thrombosis without bowel ischemia [112]. Transcatheter thrombolysis (either percutaneous or through transjugular route) has also been attempted in some cases to good effect [120]. When intestinal infarction has already developed and the patient has features of peritonitis, emergency laparotomy for resection of the necrotic parts of the gut should be performed [127].

## 5. Conclusions

With the advancements in imaging technology, the rate of detection of splanchnic venous thrombosis has gradually increased. The consequences of these thromboses can be severe, including fulminant liver failure, bowel infarction, and variceal bleeding, with high mortality rates. Clinical features are often nonspecific and overlap with many other abdominal emergencies. Since this entity is still relatively rare, no uniform treatment protocols are established. Conservative medical treatment is often ineffective, especially in cases with extensive thrombosis and organ damage, underlining the need for a prompt diagnosis and commencement of therapy. Ultrasound coupled with Doppler is highly effective in detecting hepatic and portal venous and IVC thrombosis with attendant findings of ascites, splenomegaly, and liver parenchymal changes. Cross-sectional imaging serves primarily as a problem solving tool and in evaluation of associated complications like varices and portal biliopathy. However, for mesenteric venous thrombosis, contrast-enhanced MDCT and MRI are superior not only in detection of the primary vascular abnormality but also in delineating the changes in bowel wall and mesentery. Catheter angiography is now reserved essentially for cases in which therapeutic intervention is planned.

## Conflict of Interests

The authors declare that there is no conflict of interests regarding the publication of this paper.

## References

- [1] V. de Stefano and I. Martinelli, "Splanchnic vein thrombosis: clinical presentation, risk factors and treatment," *Internal and Emergency Medicine*, vol. 5, no. 6, pp. 487–494, 2010.
- [2] V. de Stefano, T. Za, A. Ciminello, L. Betti, and E. Rossi, "Causes of adult splanchnic vein thrombosis in the mediterranean area," *Mediterranean Journal of Hematology and Infectious Diseases*, vol. 3, no. 1, Article ID e2011063, 2011.
- [3] H. L. A. Janssen, J.-C. Garcia-Pagan, E. Elias, G. Mentha, A. Hadengue, and D.-C. Valla, "Budd-Chiari syndrome: a review by an expert panel," *Journal of Hepatology*, vol. 38, no. 3, pp. 364–371, 2003.
- [4] D.-C. Valla, "Primary Budd-Chiari syndrome," *Journal of Hepatology*, vol. 50, no. 1, pp. 195–203, 2009.
- [5] D. Valla, "Hepatic venous outflow tract obstruction etiology: Asia versus the West," *Journal of Gastroenterology and Hepatology*, vol. 19, supplement, pp. 204–211, 2004.
- [6] S. M. Shrestha, K. Okuda, T. Uchida et al., "Endemicity and clinical picture of liver disease due to obstruction of the hepatic portion of the inferior vena cava in Nepal," *Journal of Gastroenterology and Hepatology*, vol. 11, no. 2, pp. 170–179, 1996.
- [7] N. Chaubal, M. Dighe, V. Hanchate, H. Thakkar, H. Deshmukh, and K. Rathod, "Sonography in Budd-Chiari syndrome," *Journal of Ultrasound in Medicine*, vol. 25, no. 3, pp. 373–379, 2006.
- [8] D. N. Amarapurkar, S. J. Punamiya, and N. D. Patel, "Changing spectrum of Budd-Chiari syndrome in India with special reference to non-surgical treatment," *World Journal of Gastroenterology*, vol. 14, no. 2, pp. 278–285, 2008.
- [9] L. D. DeLeve, D. C. Valla, and G. Garcia-Tsao, "American association for the study liver diseases. Vascular disorders of the liver," *Hepatology*, vol. 49, no. 5, pp. 1729–1764, 2009.
- [10] B. K. De, K. K. De, S. Sen et al., "Etiology based prevalence of Budd-Chiari syndrome in eastern India," *The Journal of the Association of Physicians of India*, vol. 48, no. 8, pp. 800–803, 2000.
- [11] K. Okuda, "Inferior vena cava thrombosis at its hepatic portion (obliterative hepatocavopathy)," *Seminars in Liver Disease*, vol. 22, no. 1, pp. 15–26, 2002.
- [12] A. Mukund and S. Gamanagatti, "Imaging and interventions in Budd-Chiari syndrome," *World Journal of Radiology*, vol. 3, no. 7, pp. 169–177, 2011.
- [13] R. Parker, "Occlusion of the hepatic veins in man," *Medicine*, vol. 38, pp. 369–402, 1959.
- [14] M. A. Zimmerman, A. M. Cameron, and R. M. Ghobrial, "Budd-Chiari syndrome," *Clinics in Liver Disease*, vol. 10, no. 2, pp. 259–273, 2006.
- [15] T. C. Noone, R. C. Semelka, E. S. Siegelman et al., "Budd-Chiari syndrome: spectrum of appearances of acute, subacute, and chronic disease with magnetic resonance imaging," *Journal of Magnetic Resonance Imaging*, vol. 11, no. 1, pp. 44–50, 2000.
- [16] P. Soyer, A. Rabenandrasana, J. Barge et al., "MRI of Budd-Chiari syndrome," *Abdominal Imaging*, vol. 19, no. 4, pp. 325–329, 1994.
- [17] T. Kubo, T. Shibata, K. Itoh et al., "Outcome of percutaneous transhepatic venoplasty for hepatic venous outflow obstruction after living donor liver transplantation," *Radiology*, vol. 239, no. 1, pp. 285–290, 2006.
- [18] Y.-H. Gai, S.-F. Cai, W.-B. Guo et al., "Sonographic classification of draining pathways of obstructed hepatic veins in Budd-Chiari syndrome," *Journal of Clinical Ultrasound*, vol. 42, no. 3, pp. 134–142, 2014.
- [19] A. E. A. Mahmoud, A. Mendoza, A. N. Meshikhes et al., "Clinical spectrum, investigations and treatment of Budd-Chiari syndrome," *The Quarterly Journal of Medicine*, vol. 89, no. 1, pp. 37–43, 1996.
- [20] V. Vilgrain, M. Lewin, C. Vons et al., "Hepatic nodules in Budd-Chiari syndrome: imaging features," *Radiology*, vol. 210, no. 2, pp. 443–450, 1999.

- [21] G. Brancatelli, M. P. Federle, L. Grazioli, R. Golfieri, and R. Lencioni, "Large regenerative nodules in Budd-Chiari syndrome and other vascular disorders of the liver: CT and MR imaging findings with clinicopathologic correlation," *American Journal of Roentgenology*, vol. 178, no. 4, pp. 877–883, 2002.
- [22] G. Brancatelli, M. P. Federle, L. Grazioli, R. Golfieri, and R. Lencioni, "Benign regenerative nodules in Budd-Chiari syndrome and other vascular disorders of the liver: radiologic-pathologic and clinical correlation," *Radiographics*, vol. 22, no. 4, pp. 847–862, 2002.
- [23] R. Soler, E. Rodríguez, F. Pombo, J. González, S. Pombo, and C. Prada, "Benign regenerative nodules with copper accumulation in a case of chronic Budd-Chiari syndrome: CT and MR findings," *Abdominal Imaging*, vol. 25, no. 5, pp. 486–489, 2000.
- [24] C. B. Winston, L. H. Schwartz, Y. Fong, L. H. Blumgart, and D. M. Panicek, "Hepatocellular carcinoma: MR imaging findings in cirrhotic livers and noncirrhotic livers," *Radiology*, vol. 210, no. 1, pp. 75–79, 1999.
- [25] G. Brancatelli, V. Vilgrain, M. P. Federle et al., "Budd-Chiari syndrome: spectrum of imaging findings," *American Journal of Roentgenology*, vol. 188, no. 2, pp. W168–W176, 2007.
- [26] X. Bargalló, R. Gilabert, C. Nicolau, J. C. García-Pagán, J. R. Ayuso, and C. Brú, "Sonography of Budd-Chiari syndrome," *American Journal of Roentgenology*, vol. 187, no. 1, pp. W33–W41, 2006.
- [27] H. Ferral, G. Behrens, and J. Lopera, "Budd-Chiari syndrome," *American Journal of Roentgenology*, vol. 199, no. 4, pp. 737–745, 2012.
- [28] M. S. Keller, K. J. W. Taylor, and C. A. Riely, "Pseudoportal Doppler signal in the partially obstructed inferior vena cava," *Radiology*, vol. 170, no. 2, pp. 475–477, 1989.
- [29] V. Virmani, N. Khandelwal, M. Kang, M. Gulati, and Y. Chawla, "MDCT venography in the evaluation of inferior vena cava in Budd-Chiari syndrome," *Indian Journal of Gastroenterology*, vol. 28, no. 1, pp. 17–23, 2009.
- [30] S. D. Murad, D. C. Valla, P. C. De Groen et al., "Pathogenesis and treatment of Budd-Chiari syndrome combined with portal vein thrombosis," *American Journal of Gastroenterology*, vol. 101, no. 1, pp. 83–90, 2006.
- [31] O. Buckley, J. O'Brien, A. Snow et al., "Imaging of Budd-Chiari syndrome," *European Radiology*, vol. 17, no. 8, pp. 2071–2078, 2007.
- [32] X. Bargalló, R. Gilabert, C. Nicolau, J. C. García-Pagán, J. Bosch, and C. Brú, "Sonography of the caudate vein: value in diagnosing Budd-Chiari syndrome," *American Journal of Roentgenology*, vol. 181, no. 6, pp. 1641–1645, 2003.
- [33] A. Plessier and D. C. Valla, "Budd-Chiari syndrome," *Seminars in Liver Disease*, vol. 28, no. 3, pp. 259–269, 2008.
- [34] X. Qi and G. Han, "Images in clinical medicine. Abdominal-wall varices in the Budd-Chiari syndrome," *The New England Journal of Medicine*, vol. 370, no. 19, article 1829, 2014.
- [35] O. K. Cho, J. H. Koo, Y. S. Kim, H. C. Rhim, B. H. Koh, and H. S. Seo, "Collateral pathways in Budd-Chiari syndrome: CT and venographic correlation," *American Journal of Roentgenology*, vol. 167, no. 5, pp. 1163–1167, 1996.
- [36] A. Mancuso, "Budd-chiari syndrome management: lights and shadows," *World Journal of Hepatology*, vol. 3, no. 10, pp. 262–264, 2011.
- [37] N. K. Arora, R. Lodha, S. Gulati et al., "Portal hypertension in north Indian children," *Indian Journal of Pediatrics*, vol. 65, no. 4, pp. 585–591, 1998.
- [38] B. Condat, F. Pessione, M. H. Denninger, S. Hillaire, and D. Valla, "Recent portal or mesenteric venous thrombosis: increased recognition and frequent recanalization on anticoagulant therapy," *Hepatology*, vol. 32, no. 3, pp. 466–470, 2000.
- [39] M.-H. Denninger, Y. Chait, N. Casadevall et al., "Cause of portal or hepatic venous thrombosis in adults: the role of multiple concurrent factors," *Hepatology*, vol. 31, no. 3, pp. 587–591, 2000.
- [40] P. Chamouard, E. Pencreach, F. Maloisel et al., "Frequent factor II G20210A mutation in idiopathic portal vein thrombosis," *Gastroenterology*, vol. 116, no. 1, pp. 144–148, 1999.
- [41] M. Primignani, I. Martinelli, P. Bucciarelli et al., "Risk factors for thrombophilia in extrahepatic portal vein obstruction," *Hepatology*, vol. 41, no. 3, pp. 603–608, 2005.
- [42] M. Ögren, D. Bergqvist, M. Björck, S. Acosta, H. Eriksson, and N. H. Sternby, "Portal vein thrombosis: prevalence, patient characteristics and lifetime risk: a population study based on 23,796 consecutive autopsies," *World Journal of Gastroenterology*, vol. 12, no. 13, pp. 2115–2119, 2006.
- [43] R. M. Plemmons, D. P. Dooley, and R. N. Longfield, "Septic thrombophlebitis of the portal vein (pylephlebitis): diagnosis and management in the modern era," *Clinical Infectious Diseases*, vol. 21, no. 5, pp. 1114–1120, 1995.
- [44] L. J. Webb and S. Sherlock, "The aetiology, presentation and natural history of extra-hepatic portal venous obstruction," *The Quarterly Journal of Medicine*, vol. 48, no. 192, pp. 627–639, 1979.
- [45] M. Bhattacharyya, G. Makharia, M. Kannan, R. P. H. Ahmed, P. K. Gupta, and R. Saxena, "Inherited prothrombotic defects in Budd-Chiari syndrome and portal vein thrombosis: a study from North India," *American Journal of Clinical Pathology*, vol. 121, no. 6, pp. 844–847, 2004.
- [46] A. E. A. Mahmoud, E. Elias, N. Beauchamp, and J. T. Wilde, "Prevalence of the factor V Leiden mutation in hepatic and portal vein thrombosis," *Gut*, vol. 40, no. 6, pp. 798–800, 1997.
- [47] V. Ahuja, N. Marwaha, Y. Chawla, and J. B. Dilawari, "Coagulation abnormalities in idiopathic portal venous thrombosis," *Journal of Gastroenterology and Hepatology*, vol. 14, no. 12, pp. 1210–1211, 1999.
- [48] T. Egesel, Y. Büyükasik, S. V. Dündar, A. Gürgey, S. Kirazli, and Y. Bayraktar, "The role of natural anticoagulant deficiencies and factor V Leiden in the development of idiopathic portal vein thrombosis," *Journal of Clinical Gastroenterology*, vol. 30, no. 1, pp. 66–71, 2000.
- [49] N. V. Jamieson, "Changing perspectives in portal vein thrombosis and liver transplantation," *Transplantation*, vol. 69, no. 9, pp. 1772–1774, 2000.
- [50] M. A. Yerdel, B. Gunson, D. Mirza et al., "Portal vein thrombosis in adults undergoing liver transplantation: risk factors, screening, management, and outcome," *Transplantation*, vol. 69, no. 9, pp. 1873–1881, 2000.
- [51] F. R. Ponziani, M. A. Zocco, C. Campanale et al., "Portal vein thrombosis: insight into physiopathology, diagnosis, and treatment," *World Journal of Gastroenterology*, vol. 16, no. 2, pp. 143–155, 2010.
- [52] J. M. Henderson, G. T. Gilmore, G. J. Mackay, J. R. Galloway, T. F. Dodson, and M. H. Kutner, "Hemodynamics during liver transplantation: the interactions between cardiac output and portal venous and hepatic arterial flows," *Hepatology*, vol. 16, no. 3, pp. 715–718, 1992.
- [53] K. Ohnishi, K. Okuda, T. Ohtsuki et al., "Formation of hilar collaterals or cavernous transformation after portal vein obstruction by hepatocellular carcinoma. Observations in ten patients," *Gastroenterology*, vol. 87, no. 5, pp. 1150–1153, 1984.

- [54] A. M. de Gaetano, M. Lafortune, H. Patriquin, A. de Franco, B. Aubin, and K. Paradis, "Cavernous transformation of the portal vein: patterns of intrahepatic and splanchnic collateral circulation detected with Doppler sonography," *The American Journal of Roentgenology*, vol. 165, no. 5, pp. 1151–1155, 1995.
- [55] X. Qi, G. Han, M. Bai, and D. Fan, "Stage of portal vein thrombosis," *Journal of Hepatology*, vol. 54, no. 5, pp. 1080–1082, 2011.
- [56] R. de Franchis, "Revising consensus in portal hypertension: report of the Baveno V consensus workshop on methodology of diagnosis and therapy in portal hypertension," *Journal of Hepatology*, vol. 53, no. 4, pp. 762–768, 2010.
- [57] Y. Chawla, A. Duseja, and R. K. Dhiman, "Review article: the modern management of portal vein thrombosis," *Alimentary Pharmacology and Therapeutics*, vol. 30, no. 9, pp. 881–894, 2009.
- [58] G. Kocher and A. Himmelmann, "Portal vein thrombosis (PVT): a study of 20 non-cirrhotic cases," *Swiss Medical Weekly*, vol. 135, no. 25–26, pp. 372–376, 2005.
- [59] L. Belli, M. Puttini, and A. Marni, "Extrahepatic portal obstruction: clinical experience and surgical treatment in 105 patients," *Journal of Cardiovascular Surgery*, vol. 21, no. 4, pp. 439–448, 1980.
- [60] D. van Gansbeke, E. F. Avni, C. Delcour, L. Engelholm, and J. Struyven, "Sonographic features of portal vein thrombosis," *American Journal of Roentgenology*, vol. 144, no. 4, pp. 749–752, 1985.
- [61] L. Lai and W. R. Brugge, "Endoscopic ultrasound is a sensitive and specific test to diagnose portal venous system thrombosis (PVST)," *American Journal of Gastroenterology*, vol. 99, no. 1, pp. 40–44, 2004.
- [62] M. Sugiyama, H. Hagi, Y. Atomi, and M. Saito, "Diagnosis of portal venous invasion by pancreaticobiliary carcinoma: value of endoscopic ultrasonography," *Abdominal Imaging*, vol. 22, no. 4, pp. 434–438, 1997.
- [63] W. R. Brugge, M. J. Lee, P. B. Kelsey, R. H. Schapiro, and A. L. Warshaw, "The use of EUS to diagnose malignant portal venous system invasion by pancreatic cancer," *Gastrointestinal Endoscopy*, vol. 43, no. 6, pp. 561–567, 1996.
- [64] N. Ueno, H. Kawamura, H. Takahashi et al., "Characterization of portal vein thrombus with the use of contrast-enhanced sonography," *Journal of Ultrasound in Medicine*, vol. 25, no. 9, pp. 1147–1152, 2006.
- [65] M. Dănilă, I. Sporea, A. Popescu, R. Şirli, and M. Şendroi, "The value of contrast enhanced ultrasound in the evaluation of the nature of portal vein thrombosis," *Medical Ultrasonography*, vol. 13, no. 2, pp. 102–107, 2011.
- [66] A. M. Bach, L. E. Hann, K. T. Brown et al., "Portal vein evaluation with US: comparison to angiography combined with CT arterial portography," *Radiology*, vol. 201, no. 1, pp. 149–154, 1996.
- [67] H. R. Parvey, B. Raval, and C. M. Sandler, "Portal vein thrombosis: imaging findings," *American Journal of Roentgenology*, vol. 162, no. 1, pp. 77–81, 1994.
- [68] D. Mathieu, N. Vasile, and P. Grenier, "Portal thrombosis: dynamic CT features and course," *Radiology*, vol. 154, no. 3, pp. 737–741, 1985.
- [69] S. Colagrande, N. Centi, G. La Villa, and N. Villari, "Transient hepatic attenuation differences," *American Journal of Roentgenology*, vol. 183, no. 2, pp. 459–464, 2004.
- [70] W.-P. Chen, J.-H. Chen, J.-I. Hwang et al., "Spectrum of transient hepatic attenuation differences in biphasic helical CT," *American Journal of Roentgenology*, vol. 172, no. 2, pp. 419–424, 1999.
- [71] V. Virmani, S. Ramanathan, V. S. Virmani, A. Kielar, A. Sheikh, and J. Ryan, "Non-neoplastic hepatic vascular diseases: spectrum of CT and MRI appearances," *Clinical Radiology*, vol. 69, no. 5, pp. 538–548, 2014.
- [72] O. A. Catalano, G. Choy, A. Zhu, P. F. Hahn, and D. V. Sahani, "Differentiation of malignant thrombus from bland thrombus of the portal vein in patients with hepatocellular carcinoma: application of diffusion-weighted MR imaging," *Radiology*, vol. 254, no. 1, pp. 154–162, 2010.
- [73] M. T. Heller and A. Hattoum, "Imaging of acute conditions affecting the hepatic vasculature," *Emergency Radiology*, vol. 19, no. 4, pp. 329–339, 2012.
- [74] A. Kumar, P. Sharma, and A. Arora, "Review article: portal vein obstruction—epidemiology, pathogenesis, natural history, prognosis and treatment," *Alimentary Pharmacology and Therapeutics*, vol. 41, no. 3, pp. 276–292, 2015.
- [75] L. Amitrano, M. A. Guardascione, M. Scaglione et al., "Prognostic factors in noncirrhotic patients with splanchnic vein thromboses," *American Journal of Gastroenterology*, vol. 102, no. 11, pp. 2464–2470, 2007.
- [76] C. Merkel, M. Bolognesi, S. Bellon et al., "Long-term follow-up study of adult patients with non-cirrhotic obstruction of the portal system: comparison with cirrhotic patients," *Journal of Hepatology*, vol. 15, no. 3, pp. 299–303, 1992.
- [77] B. Condat, F. Pessione, S. Hillaire et al., "Current outcome of portal vein thrombosis in adults: risk and benefit of anticoagulant therapy," *Gastroenterology*, vol. 120, no. 2, pp. 490–497, 2001.
- [78] H. L. A. Janssen, A. Wijnhoud, E. B. Haagsma et al., "Extrahepatic portal vein thrombosis: aetiology and determinants of survival," *Gut*, vol. 49, no. 5, pp. 720–724, 2001.
- [79] A. Plessier, S. Darwish-Murad, M. Hernandez-Guerra et al., "Acute portal vein thrombosis unrelated to cirrhosis: a prospective multicenter follow-up study," *Hepatology*, vol. 51, no. 1, pp. 210–218, 2010.
- [80] J. C. Garcia-Pagán, M. Hernández-Guerra, and J. Bosch, "Extrahepatic portal vein thrombosis," *Seminars in Liver Disease*, vol. 28, no. 3, pp. 282–292, 2008.
- [81] S. K. Sarin, J. D. Sollano, Y. K. Chawla et al., "Consensus on extra-hepatic portal vein obstruction," *Liver International*, vol. 26, no. 5, pp. 512–519, 2006.
- [82] S. Ganguly, S. K. Sarin, V. Bhatia, and D. Lahoti, "The prevalence and spectrum of colonic lesions in patients with cirrhotic and noncirrhotic portal hypertension," *Hepatology*, vol. 21, no. 5, pp. 1226–1231, 1995.
- [83] Y. Chawla and J. B. Dilawari, "Anorectal varices—their frequency in cirrhotic and non-cirrhotic portal hypertension," *Gut*, vol. 32, no. 3, pp. 309–311, 1991.
- [84] Y. Chawla, J. B. Dilawari, and S. Katariya, "Gallbladder varices in portal vein thrombosis," *American Journal of Roentgenology*, vol. 162, no. 3, pp. 643–645, 1994.
- [85] N. Ueno, A. Sasaki, T. Tomiyama, S. Tano, and K. Kimura, "Color Doppler ultrasonography in the diagnosis of cavernous transformation of the portal vein," *Journal of Clinical Ultrasound*, vol. 25, no. 5, pp. 227–233, 1997.
- [86] F. N. Tessler, B. J. Gehring, A. S. Gomes et al., "Diagnosis of portal vein thrombosis: value of color Doppler imaging," *The American Journal of Roentgenology*, vol. 157, no. 2, pp. 293–296, 1991.

- [87] R. Khanna and S. K. Sarin, "Non-cirrhotic portal hypertension—diagnosis and management," *Journal of Hepatology*, vol. 60, no. 2, pp. 421–441, 2014.
- [88] B. Kreft, H. Strunk, S. Flacke et al., "Detection of thrombosis in the portal venous system: comparison of contrast-enhanced MR angiography with intraarterial digital subtraction angiography," *Radiology*, vol. 216, no. 1, pp. 86–92, 2000.
- [89] S. L. Novick and E. K. Fishman, "Portal vein thrombosis: spectrum of helical CT and CT angiographic findings," *Abdominal Imaging*, vol. 23, no. 5, pp. 505–510, 1998.
- [90] M. Seeger, R. Günther, H. Hinrichsen et al., "Chronic portal vein thrombosis: transcapsular hepatic collateral vessels and communicating ectopic varices," *Radiology*, vol. 257, no. 2, pp. 568–578, 2010.
- [91] E. M. Walser, B. R. Runyan, M. G. Heckman et al., "Extrahepatic portal biliopathy: proposed etiology on the basis of anatomic and clinical features," *Radiology*, vol. 258, no. 1, pp. 146–153, 2011.
- [92] A. Arora and S. K. Sarin, "Multi-modality imaging of primary Extra-Hepatic Portal Vein Obstruction (EHPVO): what every radiologist should know," *The British Journal of Radiology*. In press.
- [93] J. H. Saint, "The epicholedochal venous plexus and its importance as a means of identifying the common duct during operations on the extrahepatic biliary tract," *The British Journal of Surgery*, vol. 48, pp. 489–498, 1961.
- [94] T. Petren, "Die extrahepatischen gallenwegsvenen und ihre pathologisches anatomische bedeutung," *Verhandlungen der Anatomischen Gesellschaft*, vol. 41, pp. 139–143, 1932.
- [95] R. Chandra, D. Kapoor, A. Tharakan, A. Chaudhary, and S. K. Sarin, "Portal biliopathy," *Journal of Gastroenterology and Hepatology*, vol. 16, no. 10, pp. 1086–1092, 2001.
- [96] R. K. Dhiman, P. Puri, Y. Chawla et al., "Biliary changes in extrahepatic portal venous obstruction: compression by collaterals or ischemic?" *Gastrointestinal Endoscopy*, vol. 50, no. 5, pp. 646–652, 1999.
- [97] R. K. Dhiman, A. Behera, Y. K. Chawla, J. B. Dilawari, and S. Suri, "Portal hypertensive biliopathy," *Gut*, vol. 56, no. 7, pp. 1001–1008, 2007.
- [98] M. S. Khuroo, G. N. Yattoo, S. A. Zargar et al., "Biliary abnormalities associated with extrahepatic portal venous obstruction," *Hepatology*, vol. 17, no. 5, pp. 807–813, 1993.
- [99] B. Nagi, R. Kochhar, D. Bhasin, and K. Singh, "Cholangiopathy in extrahepatic portal venous obstruction: radiological appearances," *Acta Radiologica*, vol. 41, no. 6, pp. 612–615, 2000.
- [100] R. de Franchis and Baveno V Faculty, "Revising consensus in portal hypertension: report of the Baveno v consensus workshop on methodology of diagnosis and therapy in portal hypertension," *Journal of Hepatology*, vol. 53, no. 4, pp. 762–768, 2010.
- [101] B. Condat, V. Vilgrain, T. Asselah et al., "Portal cavernoma-associated cholangiopathy: a clinical and MR cholangiography coupled with MR portography imaging study," *Hepatology*, vol. 37, no. 6, pp. 1302–1308, 2003.
- [102] J. L. Umphress, R. E. Pecha, and S. Urayama, "Biliary stricture caused by portal biliopathy: diagnosis by EUS with Doppler US," *Gastrointestinal Endoscopy*, vol. 60, no. 6, pp. 1021–1024, 2004.
- [103] K. Okuda, K. Ohnishi, K. Kimura et al., "Incidence of portal vein thrombosis in liver cirrhosis. An angiographic study in 708 patients," *Gastroenterology*, vol. 89, no. 2, pp. 279–286, 1985.
- [104] C. Francoz, J. Belghiti, V. Vilgrain et al., "Splanchnic vein thrombosis in candidates for liver transplantation: usefulness of screening and anticoagulation," *Gut*, vol. 54, no. 5, pp. 691–697, 2005.
- [105] M. E. Tublin, G. D. Dodd III, and R. L. Baron, "Benign and malignant portal vein thrombosis: differentiation by CT characteristics," *The American Journal of Roentgenology*, vol. 168, no. 3, pp. 719–723, 1997.
- [106] S. Rossi, L. Rosa, V. Ravetta et al., "Contrast-enhanced versus conventional and color doppler sonography for the detection of thrombosis of the portal and hepatic venous systems," *American Journal of Roentgenology*, vol. 186, no. 3, pp. 763–773, 2006.
- [107] R. Y. Rhee, P. Glociczki, C. T. Mendonca et al., "Mesenteric venous thrombosis: still a lethal disease in the 1990s," *Journal of Vascular Surgery*, vol. 20, no. 5, pp. 688–697, 1994.
- [108] W. Wiesner, B. Khurana, H. Ji, and P. R. Ros, "CT of acute bowel ischemia," *Radiology*, vol. 226, no. 3, pp. 635–650, 2003.
- [109] M. Trompeter, T. Brazda, C. T. Remy, T. Vestring, and P. Reimer, "Non-occlusive mesenteric ischemia: etiology, diagnosis, and interventional therapy," *European Radiology*, vol. 12, no. 5, pp. 1179–1187, 2002.
- [110] R. Y. Rhee and P. Glociczki, "Mesenteric venous thrombosis," *The Surgical Clinics of North America*, vol. 77, no. 2, pp. 327–338, 1997.
- [111] R. Duran, A. L. Denys, I. Letovanec, R. A. Meuli, and S. Schmidt, "Multidetector CT features of mesenteric vein thrombosis," *Radiographics*, vol. 32, no. 5, pp. 1503–1522, 2012.
- [112] S. Kumar, M. G. Sarr, and P. S. Kamath, "Mesenteric venous thrombosis," *The New England Journal of Medicine*, vol. 345, no. 23, pp. 1683–1688, 2001.
- [113] T. R. S. Harward, D. Green, J. J. Bergan, R. J. Rizzo, and J. S. T. Yao, "Mesenteric venous thrombosis," *Journal of Vascular Surgery*, vol. 9, no. 2, pp. 328–333, 1989.
- [114] R. A. Abdu, B. J. Zakhour, and D. J. Dallis, "Mesenteric venous thrombosis: 1911 to 1984," *Surgery*, vol. 101, no. 4, pp. 383–388, 1987.
- [115] C. C. Johnson and A. H. Baggenstoss, "Mesenteric vascular occlusion; study of 99 cases of occlusion of veins," *Proceedings of the Staff Meetings. Mayo Clinic*, vol. 24, no. 25, pp. 628–636, 1949.
- [116] H. Laufman, "Gradual occlusion of the mesenteric vessels. Experimental study," *Surgery*, vol. 13, no. 3, pp. 406–410, 1943.
- [117] M. S. Bradbury, P. V. Kavanagh, R. E. Bechtold et al., "Mesenteric venous thrombosis: diagnosis and noninvasive imaging," *Radiographics*, vol. 22, no. 3, pp. 527–541, 2002.
- [118] A. Theodoropoulou and I. E. Koutroubakis, "Ischemic colitis: clinical practice in diagnosis and treatment," *World Journal of Gastroenterology*, vol. 14, no. 48, pp. 7302–7308, 2008.
- [119] S. Acosta, A. Alhadad, and O. Ekberg, "Findings in multidetector row CT with portal phase enhancement in patients with mesenteric venous thrombosis," *Emergency Radiology*, vol. 16, no. 6, pp. 477–482, 2009.
- [120] F.-Y. Liu, M.-Q. Wang, Q.-S. Fan, F. Duan, Z.-J. Wang, and P. Song, "Interventional treatment for symptomatic acute-subacute portal and superior mesenteric vein thrombosis," *World Journal of Gastroenterology*, vol. 15, no. 40, pp. 5028–5034, 2009.
- [121] S. S. Lee, H. K. Ha, S. H. Park et al., "Usefulness of computed tomography in differentiating transmural infarction from non-transmural ischemia of the small intestine in patients with acute mesenteric venous thrombosis," *Journal of Computer Assisted Tomography*, vol. 32, no. 5, pp. 730–737, 2008.

- [122] R. Whitehead, "The pathology of ischemia of the intestines," *Pathology Annual*, vol. 11, pp. 1–52, 1976.
- [123] C. K. Chou, "CT manifestations of bowel ischemia," *American Journal of Roentgenology*, vol. 178, no. 1, pp. 87–91, 2002.
- [124] J. H. Wang, A. Furlan, D. Kaya, S. Goshima, M. Tublin, and K. T. Bae, "Pneumatosis intestinalis versus pseudo-pneumatosis: review of CT findings and differentiation," *Insights into Imaging*, vol. 2, no. 1, pp. 85–92, 2011.
- [125] W. Wiesner, K. J. Mortelé, J. N. Glickman, H. Ji, and P. R. Ros, "Pneumatosis intestinalis and portomesenteric venous gas in intestinal ischemia: correlation of CT findings with severity of ischemia and clinical outcome," *American Journal of Roentgenology*, vol. 177, no. 6, pp. 1319–1323, 2001.
- [126] L. Y. Kernagis, M. S. Levine, and J. E. Jacobs, "Pneumatosis intestinalis in patients with ischemia: correlation of CT findings with viability of the bowel," *American Journal of Roentgenology*, vol. 180, no. 3, pp. 733–736, 2003.
- [127] J. L. Bobadilla, "Mesenteric ischemia," *The Surgical Clinics of North America*, vol. 93, no. 4, pp. 925–940, 2013.