

Indications for Surgical Removal of the Eye in Rural Areas in Cameroon

Giles Kagmeni^{1,2}, Christelle Domngang Noche³, Georges Nguéfack-Tsague² and Peter Wiedemann⁴

¹University Teaching Hospital Yaounde (UTHY), Cameroon. ²University of Yaoundé I, Faculty of Medicine and Biomedical Sciences, Cameroon. ³University of Mountains, Bangangté, Cameroon. ⁴Eye Clinic and Polyclinic of Leipzig University, Germany.

ABSTRACT

OBJECTIVE: To determine the main clinical indications for surgical removal of the eye in rural areas in Cameroon.

DESIGN: Retrospective non-comparative case series.

PARTICIPANTS: A total of 253 patients presenting to the Manna eye clinic Nkongsamba who underwent destructive eye surgery (DES) between January 2006 and December 2010 were reviewed.

MAIN OUTCOME MEASURE: Age, gender, occupation, prior medication, visual acuity, operation indications, and type of operation.

RESULTS: There were 58.10% (n = 147) men and 41.90% (n = 106) women. Median age was 29 years (interquartile range: 14–69 years); age ranged from 10 to 88 years. A total of 67.19% (n = 170) of participants were farmers and lived in rural zones. In all, 79.05% (n = 200) confessed to have tried a medication before the presentation. Surgical indications included infective causes (perforated corneal ulcer 33.20% (n = 84) and endophthalmitis 18.20% (n = 46)), trauma 17.40% (n = 44), painful blind eyes 11.50% (n = 29), malignancy 10.70% (n = 27), and others 9.10% (n = 23).

CONCLUSION: The most common causes of DES in this series could be avoided. Therefore, preventive measures including extensive health education of the public and traditional healers on the risks linked to the use of traditional medicines in ophthalmology and the late presentation of eye disease, quality control of the campaigns that offer free cataract operations in the country.

KEY WORDS: evisceration, enucleation, exenteration

CITATION: Kagmeni et al. Indications for Surgical Removal of the Eye in Rural Areas in Cameroon. *Ophthalmology and Eye Diseases* 2014;6:27–30 doi: 10.4137/OED.S14019.

RECEIVED: January 2, 2014. **RESUBMITTED:** April 1, 2014. **ACCEPTED FOR PUBLICATION:** April 7, 2014.

ACADEMIC EDITOR: Joshua Cameron, Editor in Chief

TYPE: Original Research

FUNDING: Authors disclose no funding sources.

COMPETING INTERESTS: Authors disclose no potential conflicts of interest.

COPYRIGHT: © the authors, publisher and licensee Libertas Academica Limited. This is an open-access article distributed under the terms of the Creative Commons CC-BY-NC 3.0 License.

CORRESPONDENCE: dr.kagmeni@gmx.net

This paper was subject to independent, expert peer review by a minimum of two blind peer reviewers. All editorial decisions were made by the independent academic editor. All authors have provided signed confirmation of their compliance with ethical and legal obligations including (but not limited to) use of any copyrighted material, compliance with ICMJE authorship and competing interests disclosure guidelines and, where applicable, compliance with legal and ethical guidelines on human and animal research participants.

Introduction

Destructive surgery of the eyeball is a heavy, traumatic, and dramatic intervention that has a crippling effect on the psychology of the patient. Enucleation involves the surgical removal of the entire globe, including the sclera, and it is achieved by dividing the extraocular muscles and optic nerve. Evisceration refers to the removal of the intraocular contents, leaving the sclera and optic nerve intact.¹ Contrary to the objective of cataract surgery, which aims at improving vision, the main goal of destructive eye surgery (DES) is to improve the quality of life of the patient. Many eye diseases, either by their nature (malignancy) or by their gravity (infection, trauma), lead the ophthalmologists to make the ultimate decision to either totally or partially ablate the eyeball. This

procedure may have a significant impact on the patient's quality of life. In one hospital-based study conducted in Nigeria, Mpyet et al.² showed that eye trauma was the most frequent indication for DES in the urban milieu. In the United States, Yousuf et al.³ also reported ocular trauma as the first indication of the mutilation of the eyeball. The purpose of the present study was to determine the main clinical indications of DES in a rural zone in Cameroon, thereby proposing some useful preventive solutions.

Materials and Methods

In this retrospective, noncomparative, and consecutive case series, the medical records of all patients who underwent DES at the Manna Eye Clinic in Nkongsamba, Cameroon between



January 2006 and December 2010 were reviewed. The local ethics committee approved the study (N. Ref: 1756/L/Udm/ISSS). Participants' written informed consent was obtained after explaining the nature of the procedure to all patients (or their legal relatives) before surgery. Epidemiological data (age, sex, profession, residence, and previous treatment), as well as clinical data (visual acuity, slit lamp examination, and indication of surgery), were analyzed. Removal of the eyeball was performed under local anesthesia without orbital implant. Patients were assessed at one week and three weeks postoperatively; at the six-week follow-up visit, patients were evaluated for prosthesis and a prescription for protective glasses. Further follow-up visits were scheduled at two months and every four months thereafter. All patients less than 10 years old presenting with an indication for DES were sent to the general hospital, which houses a facility for general anesthesia; thus, these patients were excluded from the study. Data were analyzed using Epi Info™ 3.5.1 (Centers for Disease Control and Prevention, Atlanta, GA, USA). Qualitative variables were presented in percentages (%). Quantitative variables were not normally distributed, and were thus presented as the median (interquartile range). The chi-squared test was used to compare the proportions. *P*-values < 0.05 were considered statistically significant.

Results

Between January 2006 and December 2010, 12,475 patients were operated on at the Manna Eye Clinic in Nkongsamba, Cameroon, among which 253 (2%) underwent eyeball destruction. There were 147 (58.10%) males and 106 (41.90%) females. The patients' ages ranged from 10 to 88 years; their median age was 29 years (interquartile range: 14–69 years). A total of 170 patients (67.19%) were farmers.

All patients included in the study were blind in the affected eye at the time of presentation, with a visual acuity of no light perception. A total of 200 patients (79.05%) confirmed self-medicating their condition with various medicines before their medical consultation. Specifically, 146 (73%) patients reported using traditional eye medicines (TEM), whereas 54 (27%) patients used unknown medicines bought from the roadside. In 78 patients (30.83%), surgery was indicated after the failure of conservative treatment (tarsorrhaphy, retrobulbar injection of alcohol, conjunctiva flap). DES was indicated as a primary surgical intervention in 173 (69.17%) cases. Operations included evisceration (*n* = 181; 71.54%), enucleation (*n* = 69; 27.27%), and exenteration (*n* = 3; 1.18%). Eye prosthesis was fitted to 93 patients.

The main indications for DES are shown in Table 1. Infective causes (perforated cornea ulcer (33.2%) and endophthalmitis (18.2%)) were the most frequent indication of DES (*P* = 0.00). These infective causes were associated to many factors; the main factors are presented in Table 2.

Discussion

The Manna Eye Clinic in Nkongsamba is one of the largest eye centers in Cameroon, which is characterized by a highly

Table 1. Indications for DES.

| INDICATIONS | FREQUENCY (n) | PERCENTAGE (%) |
|---------------------------|---------------|----------------|
| Infective | | |
| -Perforated corneal ulcer | 84 | 33.2 |
| -Endophthalmitis | 46 | 18.2 |
| Trauma | 44 | 17.4 |
| Painful blind eye | 29 | 11.5 |
| Malignancy | 27 | 10.7 |
| Staphyloma | 23 | 9.1 |
| Total | 253 | 100 |

rural patient population. The low cost and the high quality of the services offered explain its high volume of visits. In this study, DES represented 2% of all surgeries. In a retrospective study, Pandey⁴ reported an incidence of DES of 1.40%. The male preponderance reported in our study was similar to that described by other authors.^{4,5} This could be related to the activities of the male gender. The young age reported in the current study is consistent with that observed in the previous literature.⁶ This age group is the most economically active and productive population. The use of TEM or drug abuse as auto-medication before their presentation at the clinic has also been reported by Nwosu⁷ in Nigeria. Sociocultural beliefs, poverty, and difficulty accessing eye care services could explain this behavior.

In our survey, as well as in some previous studies,^{8,9} all patients (100%) were blind in the affected eye before surgery. The eyeball was then removed to save the other eye, save the patient's life, or enhance the quality of life of the patient. A conservative approach must be attempted before the mutilation of the eyeball can be performed. However, in three-quarters of our patients, eye removal was indicated, as the patients presented with advanced ophthalmic disease with very poor visual prognosis.

Eye infective diseases are the predominant cause of DES in our milieu (51.20%). Several sources in Africa^{10,11} have also reported infective diseases as the leading indication for eye removal. Perforated corneal ulcer (Figure 1), which is the most common infective cause, is favored by activities in the rural zones. The most common associated factors identified were sociocultural belief, mismanagement with TEM, drug abuse, and late presentation. Perforation of a corneal ulcer will inevitably lead

Table 2. Factors associated with infective causes.

| | PERFORATED CORNEA ULCER n (%) | ENDOPHTHALMITIS n (%) |
|------------------|-------------------------------|-----------------------|
| TEM | 61 (72.61%) | 20 (43.47%) |
| Unknown medicine | 23 (27.38%) | 10 (21.76%) |
| Postoperative | | 16 (34.78%) |

to the loss of the visual organ in our milieu because there is no center that performs penetrating keratoplasty in Cameroon. DES appears to be a cleaning surgery aimed at enhancing the quality of life of the patient. Tahiri et al.¹² reported that perforated corneal ulcer was the fifth cause of DES in Morocco.

Endophthalmitis represents the second infective indication of eye mutilation in our study. It primarily occurred in two main contexts: either it resulted as neglected or poorly managed eye trauma by traditional practitioners or it appeared in the perioperative setting. The recrudescence of postoperative endophthalmitis in our milieu is linked to multiple campaigns for free cataract surgery organized in the country. These sporadic and massive campaigns in favor of cataract surgery present a flaw: the absence of acceptable postoperative follow-up. Patients are seen only on the first day following the surgery, as the campaign generally lasts for only a week, and all late and long-term postoperative complications are not taken into account with these nongovernmental organization campaigns. Other factors that may increase the postoperative endophthalmitis rate include eye drop administration and conservation.

Eye traumas represent the second indication for DES in our series. It is dominated by open globe injury with uveal prolapse, globe rupture, perforation, and intraocular foreign body because of farming or hunting accidents, land brawls, and diver's aggressions. Erdurman et al.¹³ reported that 28% of patients with ocular injuries resulting from improvised explosive devices required DES as a primary surgical intervention. Several investigators^{2,13} have reported eye trauma as one of the most common indication for DES in the urban milieu. The main goal of a destructive procedure is the prevention of sympathetic ophthalmia which, from a pathophysiological perspective, is believed to be an immunologic response to the exposure of previously sequestered intraocular tissue.¹⁴ Painful blind eye, despite the maximal use of an analgesic, represented the most frequently accepted causative diagnoses for DES in our series. Painful blind eye represents the second most common cause of mutilation of the eyeball in Nepal.⁹ The pain intensity pushed many patients to request mutilation of their eye, with the aim of achieving both pain control and an improvement in cosmesis. However, Agarwal and Dubey¹⁵ reported a significant regression of the iris, angle neovascularization, and pain control following intracameral Avastin® (Genentech, Inc., San Francisco, CA, USA) in a dose of 0.25 mg/0.02 mL.

Tumors accounted for 10.70% ($n = 27$) of all the cases in our study, and they were mostly common in immunocompromised patients. Invasive squamous cell carcinoma and advanced periorbital malignancy were the most common tumors. Several authors who included children in their series found that retinoblastoma was the most frequent tumor leading to DES.⁵ Evisceration (Fig. 2) was performed most commonly ($P = 0.033$). Similar findings were also reported in other series.^{3,16} Exenteration (Fig. 3) was performed in three patients presenting with invasive tumors. Removable acrylic prosthesis was fitted only to 36.75% of our patients (Fig. 4). In

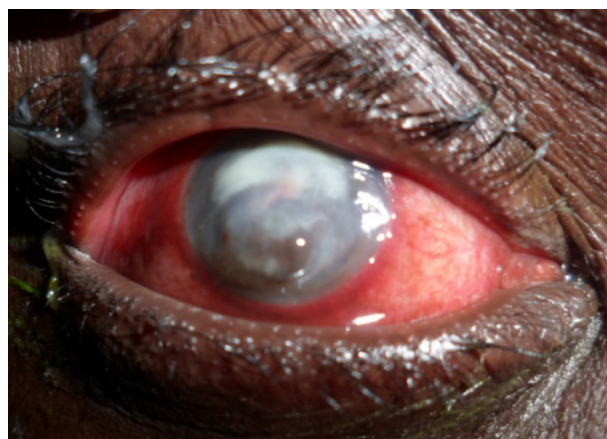


Figure 1. Perforated corneal ulcer after the use of traditional eye medicine (TME).

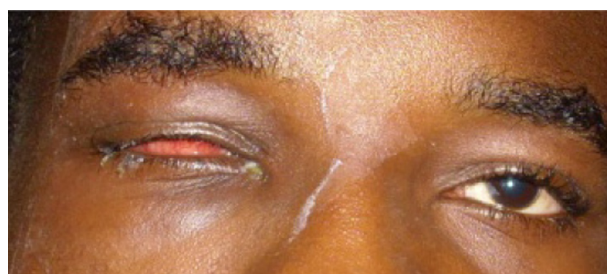

Figure 2. Eviscerated right eye six week after surgery.

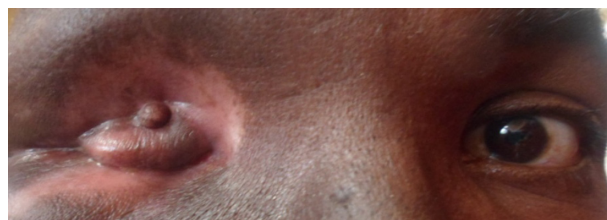


Figure 3. Partial exenteration for invasive squamous cell carcinoma by immunocompromised patient (at 6 months follow-up visit).

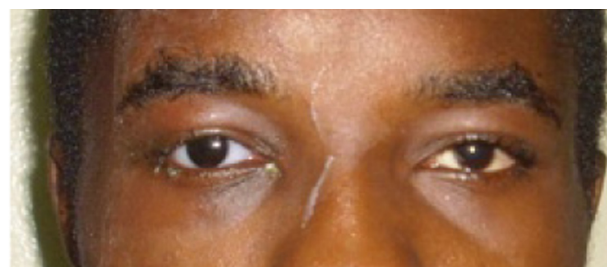

Figure 4. Eviscerated right eye six week after surgery with eye prosthesis.

a rural milieu, patients are more likely to refuse eye prosthesis because of sociocultural behaviors.

In summary, DES, an act of last resort, is frequently performed in our rural milieu. In fact, the members of the population see it as a failure for the ophthalmologist, who must ultimately



save sight. This study demonstrated that the most common indication for removing the eye in the rural areas in Cameroon was because of infective causes, which could thus be avoided. Therefore, preventive measures must be carried out to mitigate eye morbidity. These include providing extensive health education to the public and traditional healers on the risks linked to the use of traditional medicines in ophthalmology, and to patients' late presentation to the clinic; providing education to non-ophthalmologic health care workers at the primary care level about the management of eye problems before referring the patient to the clinic; educating practitioners regarding early presentation of eye disease; providing quality control of the surgery; and offering postoperative care as a part of the campaigns that offer free cataract operations in the country. A center for corneal graft should be created in our country.

Author Contributions

GK conceived and designed the experiments. GK and GNT analyzed the data. GK and CDN wrote the first draft of the manuscript. GK, CDN, GNT, and PW contributed to the writing of the manuscript. GK, CDN, GNT, and PW were responsible for manuscript results and conclusions. GK and PW jointly developed the structure and arguments for the paper. GK, GNT, and PW made critical revisions and approved the final version. All authors reviewed and approved the final manuscript.

REFERENCES

1. Iliff CE, Iliff WJ, Iliff NT. *Oculoplastic Surgery*. Philadelphia, PA: WB Saunders Co; 1979:203–22.
2. Mpyet C, Wade P, Ramyil A. Indications for surgical removal of the eye in adults: a five-year review. *Niger J Med*. 2008;17(1):107–9.
3. Yousuf SJ, Jones LS, Kidwell ED. Enucleation and evisceration: 20 years of experience. *Orbit*. 2012;31(4):211–5.
4. Pandey PR. A profile of destructive surgery in Nepal Eye Hospital. *Kathmandu Univ Med J (KUMJ)*. 2006;4(1):65–9.
5. Adeoye AO, Onakpoya OH. Indication for eye removal in Ile-Ife, Nigeria. *Afr J Med Sci*. 2007;36(4):371–5.
6. Keenan TD, Sargent NJ. Enucleation and evisceration in the Palestinian territories. *Middle East Afr J Ophthalmol*. 2011;18(2):170–2.
7. Nwosu SN. Destructive ophthalmic surgical procedures in Onitsha, Nigeria. *Niger Postgrad Med J*. 2005;12(1):53–6.
8. Ducasse A, Segal A, Favre F, Burette A. La chirurgie mutilante du globe oculaire, sa fréquence et ses indications. Etude sur cinq ans au CHR de Reins. *Bull Soc Ophthalmol Fr*. 1990;1:113–5. [French].
9. Limbu B, Saiju R, Ruit S. A retrospective study on the causes for evisceration at Tilganga Eye Centre. *Kathmandu Univ Med J (KUMJ)*. 2009;7(26):115–9.
10. Monsudi KF, Ayanniyi AA, Balarabe AH. Indications for destructive ocular surgeries in Nigeria. *Nepal J Ophthalmol*. 2013;5(9):24–7.
11. Eballé AO, Dohvoma VA, Koki G, Oumarou A, Bella AL, Mvogo CE. Indications for destructive eye surgeries at the Yaounde Gynaeco-Obstetric and Paediatric Hospital. *Clin Ophthalmol*. 2011;5:561–5.
12. Tahiri H, Benaty AD, Chehchaoui CM, El Bakkali M, Berraho A. L'enucléation: enquête épidémiologique marocaine à propos de 183 cas service d'ophtalmologie 'O' CHU. *Bull Soc Belge Ophthalmol*. 2004;113:2270–5. [French].
13. Erdurman FC, Hurmeric V, Gokce G, Durukan AH, Sobaci G, Altinsoy HI. Ocular injuries from improvised explosive devices. *Eye (Lond)*. 2011;25(11):1491–8.
14. Phan LT, Hwang TN, McCullev TJ. Evisceration in the modern age. *Middle East Afr J Ophthalmol*. 2012;19(1):24–33.
15. Agarwal M, Dubey S. Intra-cameral injection of bevacizumab (Avastin) to treat anterior chamber neovascular membrane in a painful blind eye. *Indian J Ophthalmol*. 2008;56(3):258–9.
16. Rasmussen ML, Prause JU, Johnson M, Kamper-Jørgensen F, Toft PB. Review of 345 eye amputations carried out in the period 1996–2003, at Rigshospitalet, Denmark. *Acta Ophthalmol*. 2010;88(2):218–21.