

Trauma and reconstruction

The bull's-eye sign: A hallmark radiologic sign of complete ureteropelvic junction disruption after blunt renal trauma



Samuel R. Donnenfeld^a, Sorena Keihani^{a,*}, Jason B. Young^b, Sarah Majercik^c, James M. Hotaling^a, Jeremy B. Myers^a, for the Genito-Urinary Trauma Study Group¹

^a Division of Urology, Department of Surgery, University of Utah, Salt Lake City, UT, United States

^b Division of Trauma and Acute Care Surgery, Department of Surgery, University of Utah, Salt Lake City, UT, United States

^c Division of Trauma and Surgical Critical Care, Intermountain Medical Center, Murray, UT, United States

ARTICLE INFO

Article history:

Received 13 December 2017

Accepted 17 January 2018

Available online 28 January 2018

Keywords:

Ureteropelvic junction

Trauma

Reconstruction

Ureter

Urinary extravasation

1. Introduction

Complete ureteropelvic junction (UPJ) disruption is a rare finding after blunt abdominal trauma. High clinical suspicion and close attention to imaging studies are needed to avoid missing a UPJ disruption during initial evaluation. In high grade renal trauma, the best imaging modality to detect collecting system injury and urinary extravasation is computed tomography (CT) scan with delayed excretory phase imaging. Presence of urinary extravasation with lack of contrast material in the distal ureter may suggest a ureteral injury or complete UPJ disruption. We report a case of UPJ disruption with distinct radiologic finding of “bull's-eye” sign after blunt abdominal trauma, which was diagnosed and successfully repaired.

2. Case presentation

A 33-year-old male was transferred to our Emergency Department via air ambulance after sustaining a crush injury to his abdomen by a large boulder, which rolled during navigation of a mountain side. He was hypotensive, tachycardic, and had metabolic acidosis upon arrival. After initial fluid and blood product resuscitation, imaging studies were performed and the patient was diagnosed with multiple rib fractures, left pneumothorax and hemothorax, splenic lacerations, colon injury, and left renal laceration. An abdomen/pelvis contrast CT scan with excretory phase revealed collecting system injury with urinary extravasation and a grade IV left renal injury with devascularization of the upper 1/3 of the kidney. Presence of contrast material surrounding the left ureter and extending caudally created a “bull's-eye” appearance at the proximal ureter just inferior to the UPJ disruption (Fig. 1). This bull's-eye sign and lack of intraluminal contrast in the ipsilateral distal ureter suggested complete UPJ disruption.

The patient was taken to the operating room for emergency exploratory laparotomy and underwent chest tube placement, left hemicolectomy, splenectomy, and temporary abdominal closure. At this time, a retrograde uretero-pyelogram revealed complete disruption of the UPJ. A left ureteral stent was placed through the proximal ureter into the peri-renal space; the following day imaging confirmed that the distal end of the stent was outside of the renal pelvis. The patient was taken to the operating room for colostomy, left UPJ repair, and abdominal wall closure. The diagnosis of complete UPJ disruption was confirmed and reconstruction was performed using a parachute anastomosis after removing about 1 cm of nonviable ureter. This was technically challenging because of a deep, intrarenal pelvis (Fig. 2). A ureteral stent was left in place traversing the repair. There was no urinary leakage from the repair, as evidenced by a peri-renal drain with normal creatinine within its fluid.

Renal ultrasound, three weeks post-operatively, showed resolving hypoechoic fluid collection along the inferior margin of the left kidney. The stent was removed following a normal renal ultrasound performed three months post-operatively.

* Corresponding author. Division of Urology, Department of Surgery, University of Utah School of Medicine, 30 North 1900 East, Salt Lake City, UT 84132, United States.

E-mail address: sorena.keihani@hsc.utah.edu (S. Keihani).

¹ <http://www.turnsresearch.org/page/aast-gu-trauma-study-group-author-list-renal-trauma>.

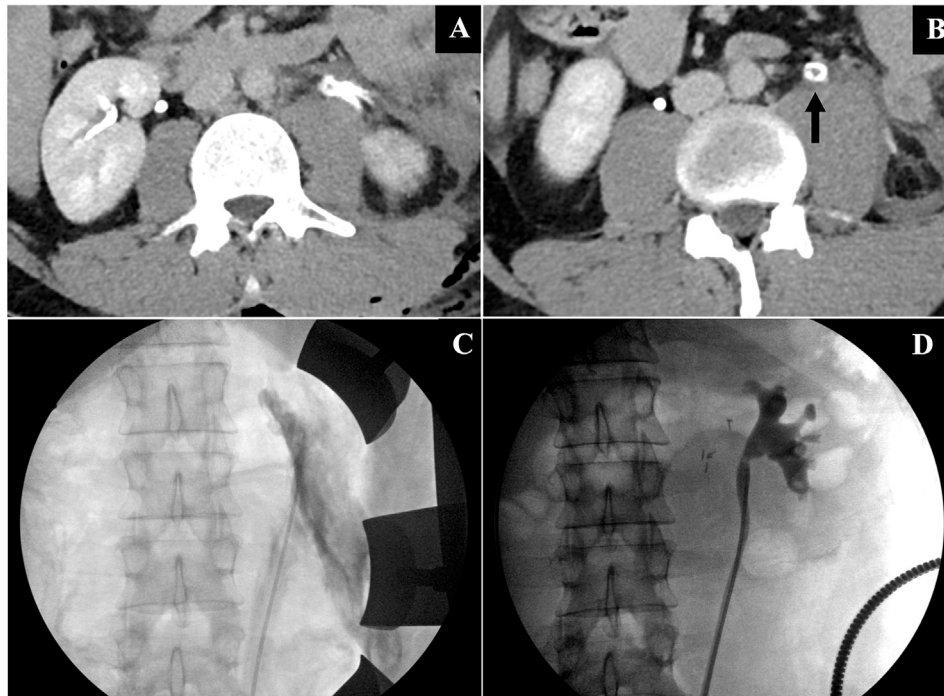


Fig. 1. A) Delayed excretory phase CT-scan with contrast material extravasation on the left side and filling defect in the center of the left ureter; B) Circumferential contrast extravasation with “bull’s-eye” sign in the left ureter; C) Initial retrograde ureteropyelogram showing disruption of the UPJ with contrast extravasation; D) Retrograde ureteropyelogram 8 months post-repair showing well-healed ureteropelvic junction.

Dimercaptosuccinic acid (DMSA) functional scan was performed at this time, which showed a differential function of 35% for the left kidney.

Upon colostomy reversal at 8 months post-trauma, a retrograde uretero-pyelogram showed a normal caliber ureter without obstruction, and a well-healed UPJ without evidence of narrowing or contrast extravasation (Fig. 1D). A basic metabolic panel including blood urea nitrogen (BUN) and creatinine (Cr) was within normal limits (BUN: 9 mg/dL, Cr: 1.1 mg/dL).

3. Discussion

Collecting system lacerations occur in about 2%–18% of blunt renal injuries. UPJ injuries and complete ureteral disruptions are even less common and usually prompt endoscopic or surgical interventions. Excretory phase imaging, with sufficient delay to allow contrast accumulation in the collecting system, is needed to avoid missing these injuries. Imaging findings such as lack of contrast

material in the distal ureter can suggest UPJ disruption and may warrant further evaluation with retrograde uretero-pyelogram. Our patient had findings consistent with UPJ disruption on initial presentation and a filling defect in the left ureter with “circumferential contrast” and a “bull’s-eye” sign which is highly suggestive of complete UPJ disruption. It is noteworthy that a blood clot extending distally in the ureter may mimic the same view of an unopacified ureter and “bull’s-eye” and should be considered in the differential diagnosis when such a finding is present on excretory phase CT scan (Fig. 3).

Complete UPJ disruption is more common in children presumably due to greater kidney mobility, which exerts more sheer stress on the ureters during blunt trauma and acceleration/deceleration injuries.¹ Although these injuries are less common in adults, rapid deceleration injuries and falls from a height should lead to higher index of clinical suspicion.^{2,3} Predisposing factors, such as hydronephrosis, duplex renal collecting system, and other anatomical malformations may lead to an increased likelihood of experiencing

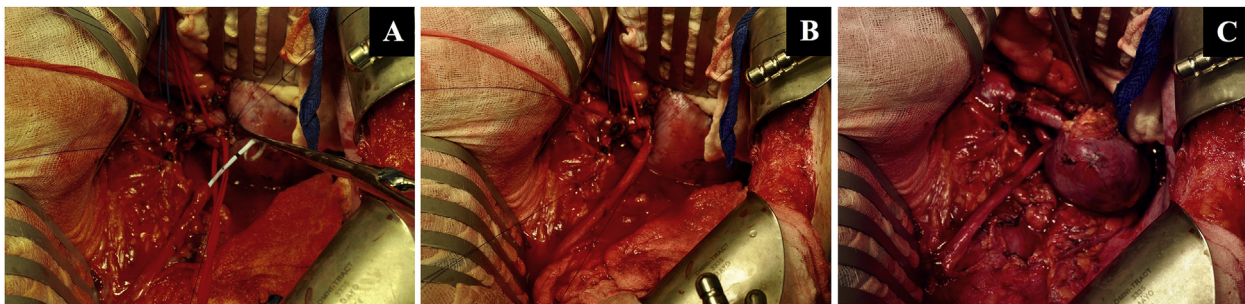


Fig. 2. A) The disrupted ureteropelvic junction with previously placed ureteral stent. The proximal parachute anastomosis has been completed and the intrarenal nature of the pelvis is evident; B) Bringing the ureteropelvic junction together with distal parachute stitches in place; C) The completed anastomosis.

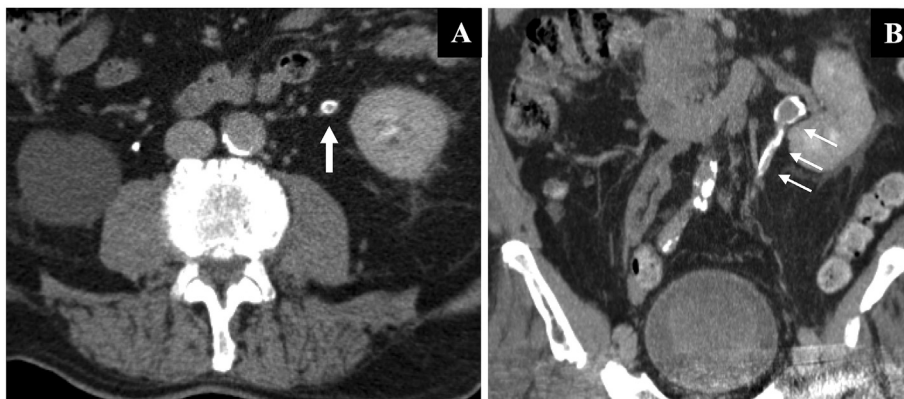


Fig. 3. A) Filling defect in the center of left ureter following renal trauma in a different patient; B) Coronal view shows blood clots expanding in the left ureter causing the filling defect.

such an event.⁴

The American Urological Association (AUA) urotrauma guidelines, recommend obtaining an intravenous contrast CT scan with excretory images for stable patients with suspected renal or ureteral trauma.⁵ For partial ureteral disruptions, placement of a ureteral stent is recommended as the first-line management; percutaneous nephrostomy with delayed repair is reserved for conditions when ureteral stenting is unsuccessful or not feasible.⁵ Immediate open ureteral repair should be considered for management of complete ureteral injuries and when percutaneous nephrostomy or periureteral drains do not provide adequate drainage.⁵ A small deep intrarenal pelvis, and a retracted ureter, are among the conditions that make primary repair more difficult.³ In our patient, failed ureteral stenting, the severity of the injury, and a deep intrarenal pelvis, led to our decision for an open ureteral repair.

Historically, most UPJ disruptions were missed during the initial evaluation.² A delayed diagnosis is associated with higher complication rates and more invasive interventions such as nephrectomy. Earlier identification of UPJ disruption can substantially decrease morbidity in this population. In our patient, a grade IV renal injury with upper pole devascularization and UPJ disruption was effectively managed with reconstruction and led to acceptable functional outcomes; this was evidenced by 35% differential function of the injured kidney and a wide open ureteral repair at 8-months post injury.

4. Conclusion

Complete UPJ disruption can be effectively diagnosed and repaired during the acute trauma. We describe a characteristic “bull’s-eye” sign of extraluminal flow of contrast around an unopacified ureter. When this radiologic sign is encountered, a retrograde uretero-pyeloogram can help in discerning between an intraluminal blood clot and a UPJ disruption.

Conflicts of interest

None.

References

1. Dar TI, Rather MH, Khawaja AR, Mir MA, Nazir SS. Post traumatic isolated ureteropelvic junction avulsion in a child. *Curr Urol*. 2017;10(3):160–162.
2. Boone TB, Gillling PJ, Husmann DA. Ureteropelvic junction disruption following blunt abdominal trauma. *J Urol*. 1993;150(1):33–36.
3. Pumberger W, Stoll E, Metz S. Ureteropelvic junction disruption following blunt abdominal trauma. *Pediatr Emerg Care*. 2002;18(5):364–366.
4. Ashebu SD, Dahniya MH, Aduh P, Ramadan S, Bopaiah H, Elshebiny YH. Rupture of the renal pelvis of a ureteropelvic junction hydronephrosis after blunt abdominal trauma. *Australas Radiol*. 2004;48(2):256–258.
5. Morey AF, Brandes S, Dugi 3rd DD, et al. Urotrauma: AUA guideline. *J Urol*. 2014;192(2):327–335.