

Distal Biceps Tendon Repair Using a Double Tension Slide Technique



Kyle R. Sochacki, M.D., Zachary T. Lawson, Ph.D., Robert A. Jack, M.D., David Dong, B.S., Andrew B. Robbins, Ph.D., Michael R. Moreno, Ph.D., and Patrick C. McCulloch, M.D.

Abstract: Distal biceps tendon ruptures are thought to be secondary to an acute forceful eccentric load on a degenerative tendon. Nonoperative treatment following rupture leads to significantly decreased forearm supination and elbow flexion strength. There are several techniques described in the literature for repair. This article describes, with video illustration, distal biceps tendon repair using a double tension slide technique with 2 No. 2 high-tension nonabsorbable composite sutures.

Distal biceps tendon ruptures have increased in incidence over the past decade and are thought to be secondary to an acute forceful eccentric load on a degenerative tendon.^{1,2} Nonoperative treatment following rupture leads to significantly decreased forearm supination and elbow flexion strength.³⁻⁶ As such, primary operative repair is recommended for active patients because it can restore function to near normal levels.^{3,5-9}

Several different methods of distal biceps tendon repairs have evolved over the years, including the bone tunnel technique, suture anchor repair,

interference screw, and cortical button.^{4,5,10-21} Biomechanical studies have compared the different repair methods with suspensory cortical button frequently having the highest load to failure.^{11-13,22-24} The tension slide technique with inference screw was then developed by Sethi et al. demonstrating greater load to failure and less gap formation compared with traditional fixation with cortical button.²⁵

However, there have been reports of interference screw failure following its use in distal biceps repair with increased risk of fracture through the bone tunnel.^{26,27} This has led to several surgeons abandoning the use of interference screws and relying on single suture tension slide technique fixation with a cortical button. In an ideal setting, this has been shown to have good strength.²⁵ In this technique, the 2 strands of a single suture are tied to each other. As such, rupture of either strand or loss of knot security would yield complete loss of initial fixation. Concerns over the strength of single suture fixation led the current authors to develop the double tension slide technique (DTS) using 2 sutures with a cortical button. This article describes the DTS distal biceps tendon repair technique (Video 1).

Surgical Technique

The patient is placed in the supine position on a hand table. The injured arm is then prepared and draped using the surgeon's preferred method similar to other distal bicep tendon repairs, and a sterile tourniquet is placed on the upper arm.

From the Houston Methodist Orthopedic and Sports Medicine (K.R.S., R.A.J., D.D., P.C.M.), Houston, Texas, U.S.A.; Department of Biomedical Engineering (Z.T.L., M.R.M.) and Department of Mechanical Engineering (A.B.R., M.R.M.), Texas A&M University, College Station, Texas, U.S.A.

The authors report the following potential conflicts of interest or sources of funding: P.C.M. reports speaker's bureau/paid presentation by Vericel/Aastrom Biosciences; research support from DePuy, A Johnson & Johnson Company, and Arthrex/Medinc of Texas; and medical/orthopaedic publications editorial/governing board for the Journal of Knee Surgery and Orthobullets.com. Full ICMJE author disclosure forms are available for this article online, as supplementary material.

Received September 24, 2019; accepted January 25, 2020.

Address correspondence to Patrick C McCulloch; Houston Methodist Orthopedic and Sports Medicine, 6445 Main Street, Suite 2500, Houston, Texas 77030, U.S.A. E-mail: pcculloch@houstonmethodist.org

© 2020 by the Arthroscopy Association of North America. Published by Elsevier. This is an open access article under the CC BY-NC-ND license (<http://creativecommons.org/licenses/by-nc-nd/4.0/>).

2212-6287/191188

<https://doi.org/10.1016/j.eats.2020.01.023>

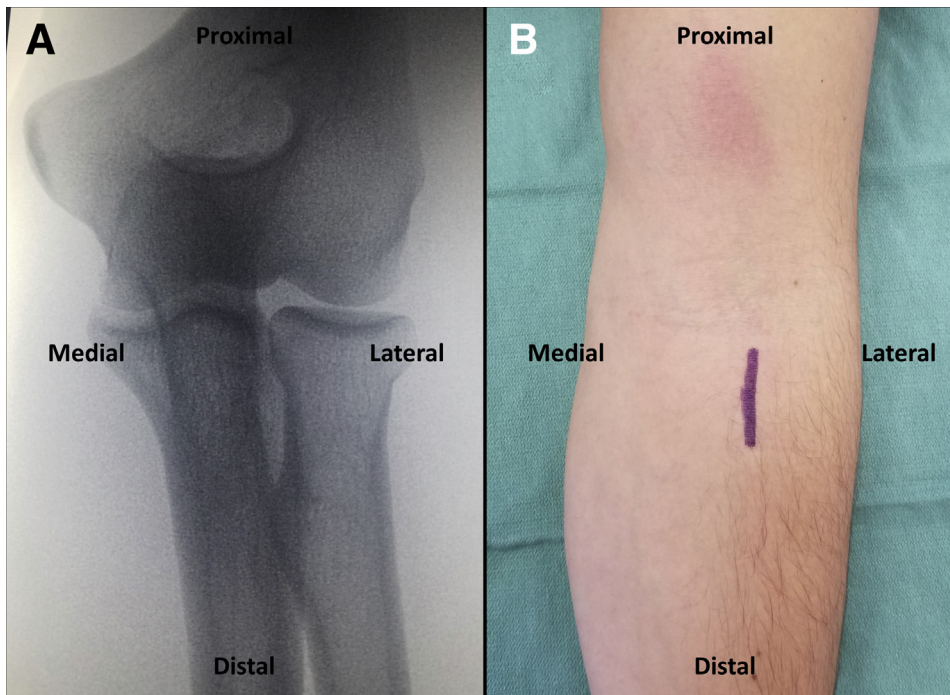


Fig 1. (A) Intraoperative fluoroscopy of right elbow demonstrating location of radial tuberosity localization prior to incision. (B) Intraoperative image of right arm with planned 3-cm incision along medial border of brachioradialis centered over the radial tuberosity.

Fluoroscopy is used to identify the site of the radial tuberosity. An approximate 3-cm incision is then made along the medial border of the brachioradialis centered over radial tuberosity distal to the flexion crease (Fig 1). Blunt dissection is carried down to the radial tuberosity and proximally to identify the tendon stump. During dissection, the lateral antebrachial cutaneous nerve is identified and protected. Adhesions are released from the tendon, and the tendon stump is then debrided to normal healthy appearing tendon.

The double tension slide technique is performed with 2 No. 2 high tension nonabsorbable composite suture (FiberWire, Arthrex, Naples, FL). The authors prefer to use a blue suture and tiger suture for ease of suture management. The first suture is passed through the distal biceps tendon starting at the medial and distal aspect of the tendon running proximally 2.5 cm in a locking fashion and then back distally exiting 1 cm from the distal tendon (Fig 2). This is then then repeated with the second suture starting at the lateral and distal aspect of the tendon (Fig 3). The 2 central

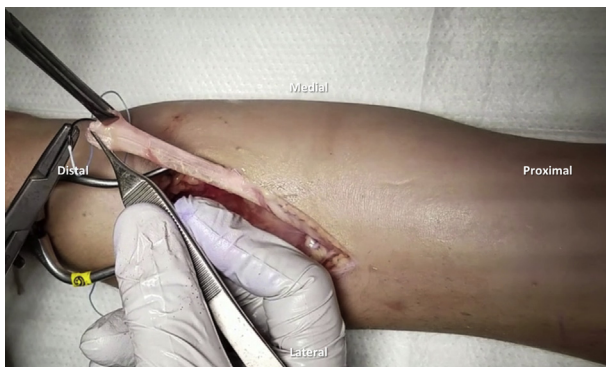

Fig 2. Right elbow. The first suture is passed through the distal biceps tendon starting at the medial and distal aspect of the tendon running proximally 2.5 cm in a locking fashion and then back distally exiting 1 cm from the distal tendon.

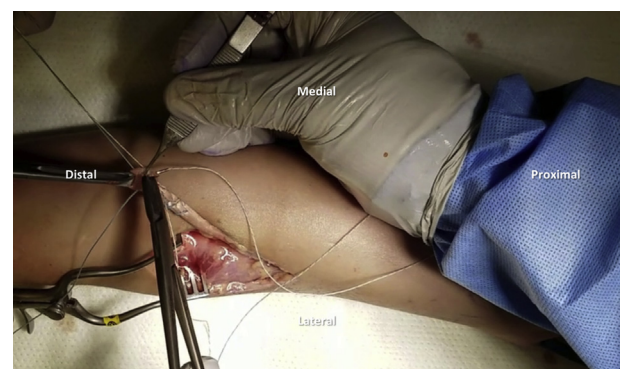


Fig 3. Right elbow. The second suture is passed through the distal biceps tendon starting at the lateral and distal aspect of the tendon.

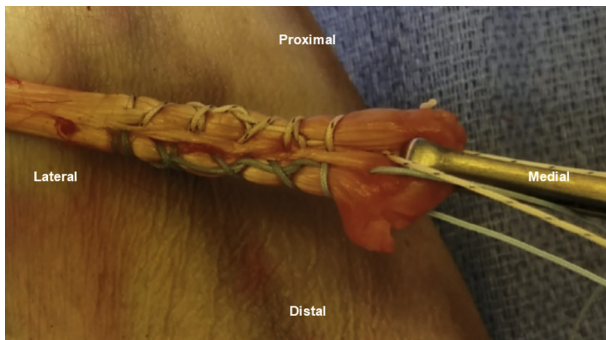


Fig 4. Right elbow with biceps tendon stumped pulled proximal out of the wound. This demonstrates the finished product after both sutures have been passed through the distal biceps tendon. Both sutures exit 1 cm from the distal tendon.

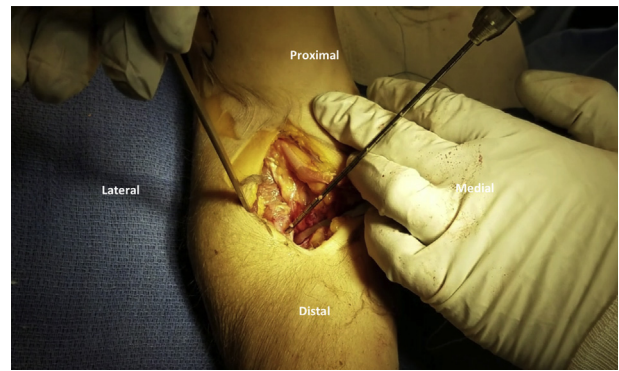


Fig 6. With the right arm in maximal supination a 3.2-mm guide pin is drilled through the center of the radial tuberosity from anterior to posterior taking care to avoid the posterior interosseous nerve (PIN). This is done using fluoroscopy.

strands of the sutures are then threaded through the cortical button (BicepsButton, Arthrex) in opposite directions. The central strand of the medial (tiger) suture is inserted through the medial hole and then back through the lateral hole. The central strand of the lateral (blue) suture is then inserted through the lateral hole and then back through the medial hole

(Fig 4). Both strands that are passed through the biceps button are then facing toward the distal biceps tendon (Fig 5).

With the arm in maximal supination a 3.2-mm (Arthrex) guide pin is drilled through the center of the radial tuberosity from anterior to posterior taking care to avoid the posterior interosseous nerve. This is done using fluoroscopy (Fig 6). The anterior cortex is then reamed with an 8.0-mm cannulated reamer (Arthrex) (Figs 7 and 8). The guide pin is removed and the button inserter was used to pass the biceps button through the 3.2-mm hole in the tuberosity from anterior to posterior (Fig 9). The button is then released from the holder and the biceps button is “flipped” against the posterior cortex of the radius. The 2 limbs of suture passed through the button are then toggled to dock the biceps tendon into the bone socket (Figs 10 and 11). Once the biceps tendon is fully seated in the socket, the 2 limbs of the same suture are tied together for both the medial (tiger) and

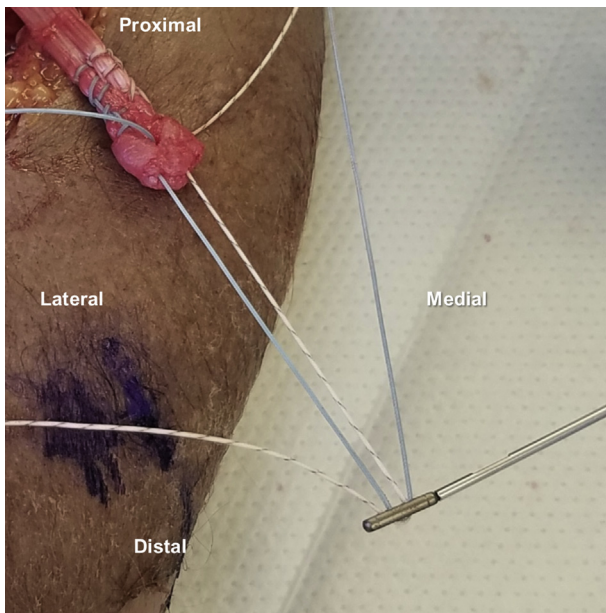


Fig 5. Right elbow. The 2 central strands of the sutures are threaded through the cortical button in opposite directions. The central strand of the medial (tiger) suture is inserted through the medial hole and then back through the lateral hole. The central strand of the lateral (blue) suture is then inserted through the lateral hole and then back through the medial hole. Both strands that are passed through the biceps button are then facing toward the distal biceps tendon.

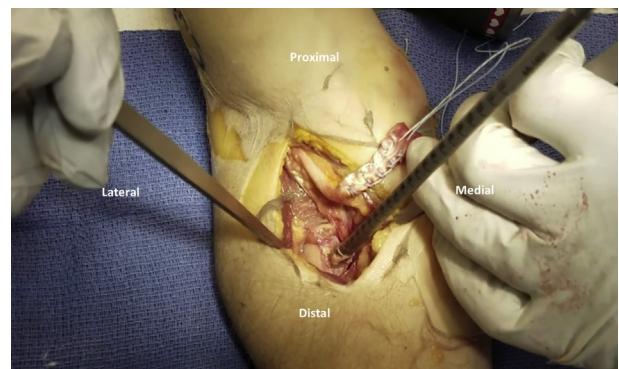


Fig 7. Right elbow. The anterior cortex is then reamed with an appropriately sized cannulated reamer.

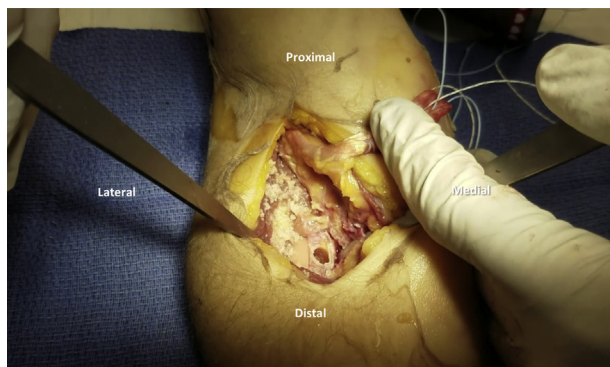


Fig 8. Right elbow. The guide pin is then removed leaving a unicortical bone socket for the tendon to be docked into.

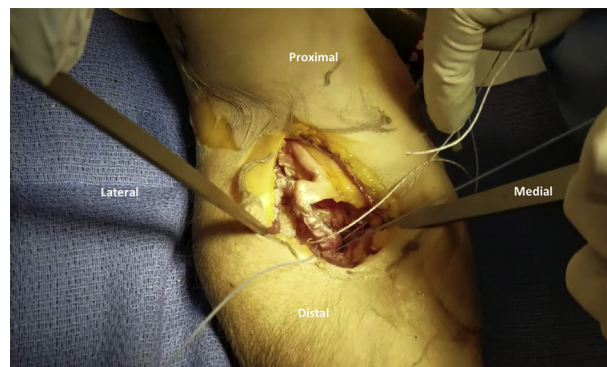


Fig 10. Right elbow. The 2 limbs of suture passed through the button are then toggled to dock the biceps tendon into the bone socket.

lateral (blue) sutures. Finally, the sutures that passed through the button (1 tiger and 1 blue) are tied together to reinforce the construct (Figs 12 and 13). Final anteroposterior and lateral fluoroscopy views are used to demonstrate that the button is in an appropriate position and the tendon is reduced into the socket (Fig 14).

The wound is then irrigated and closed in a layered fashion with absorbable suture followed by a posterior long arm splint with the arm in neutral rotation and flexed to its resting tension following the repair. The splint is kept in place for one week followed by

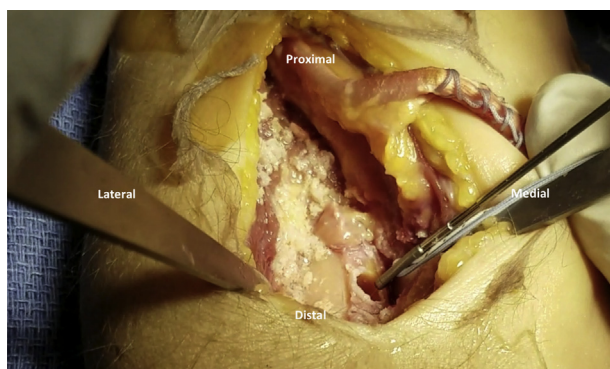


Fig 9. Right elbow. After reaming the appropriate-sized tunnel in the radial tuberosity, the button inserter is used to pass the biceps button through the 3.2-mm hole in the tuberosity from anterior to posterior. The button is then released from the holder and the biceps button is “flipped” against the posterior cortex of the radius.

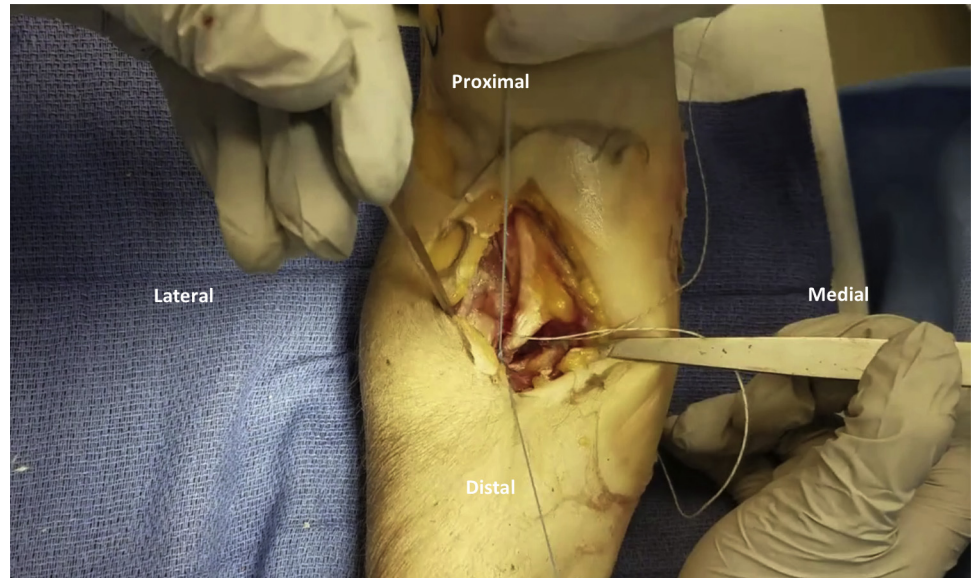
placement of a hinged elbow brace for 6 weeks. The brace is set so that the patient can obtain full flexion but extension is limited to the resting tension of the repair. Extension is advanced 20° per week until full extension is achieved. The elbow brace is then removed after 6 weeks and the patient is allowed to use the arm for all activities of daily living with limited weight bearing until 3 months postoperatively. At that time, the patient can start progressive biceps strengthening exercises.

Discussion

Several single- and 2-incision techniques for distal biceps tendon repairs have been described with bone tunnels, suture anchors, interference screws, and cortical buttons.^{4,5,10-17} Sethi et al. demonstrated that the single incision tension slide technique with interference screw had the strongest biomechanical properties.²⁵ However, reports of interference screw failure with increased risk of fracture through the bone tunnel led the current authors to abandon its use and develop the DTS technique.^{12,26,27}

The DTS technique maintains the many potential advantages to the tension slide technique without the risk of bone tunnel fracture with an interference screw (Table 1). Intuitively, the addition of a second suture would likely increase the strength of the repair, but this had not been previously investigated. Furthermore, the redundancy of a second suture should provide a failsafe if either strand of the initial sutures was damaged by the needle, abrasion against the bone, or loss of knot security at the button. By passing 2 sutures through the tendon, the present technique increases the cross-sectional area of

Fig 11. Right elbow. The tendon is then confirmed to be completely docked into the tunnel after tensioning the sutures.



tendon in contact with suture to reduce the force transmitted through the individual passes of the suture and reduce failure at the tendon-suture interface.

One possible risk and limitation to the presented technique is that the use of 2 sutures increases the cost of the repair compared with just a single suture (Table 1). However, if factoring in the cost savings from

not using an interference screw, the final cost of the repair construct may be similar. Additionally, the use of a second suture increases the surgical time compared with passing a single suture through the distal biceps tendon. However, the increased surgical time is likely outweighed by the improved biomechanical strengths of the DTS technique compared with the tension slide technique.

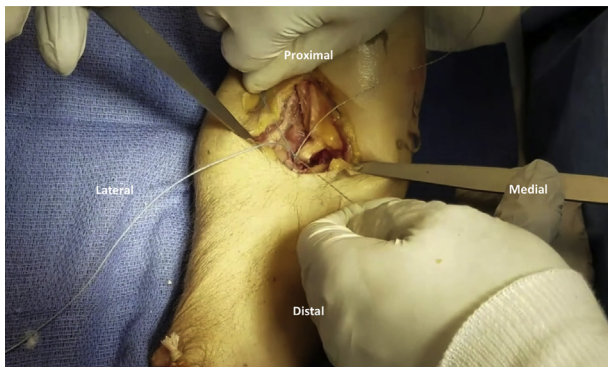

Fig 12. Right elbow. Once the biceps tendon is fully seated in the socket, the 2 limbs of the same suture are tied together for both the medial (tiger) and lateral (blue) sutures. Finally, the sutures that passed through the button (1 tiger and 1 blue) are tied together to reinforce the construct.

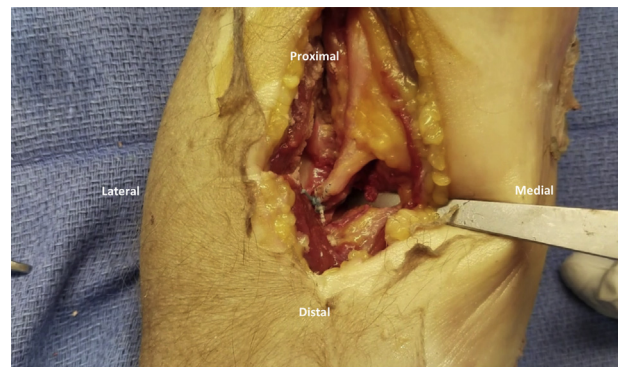


Fig 13. Right elbow. The limbs of the sutures are then cut leaving a short tail.

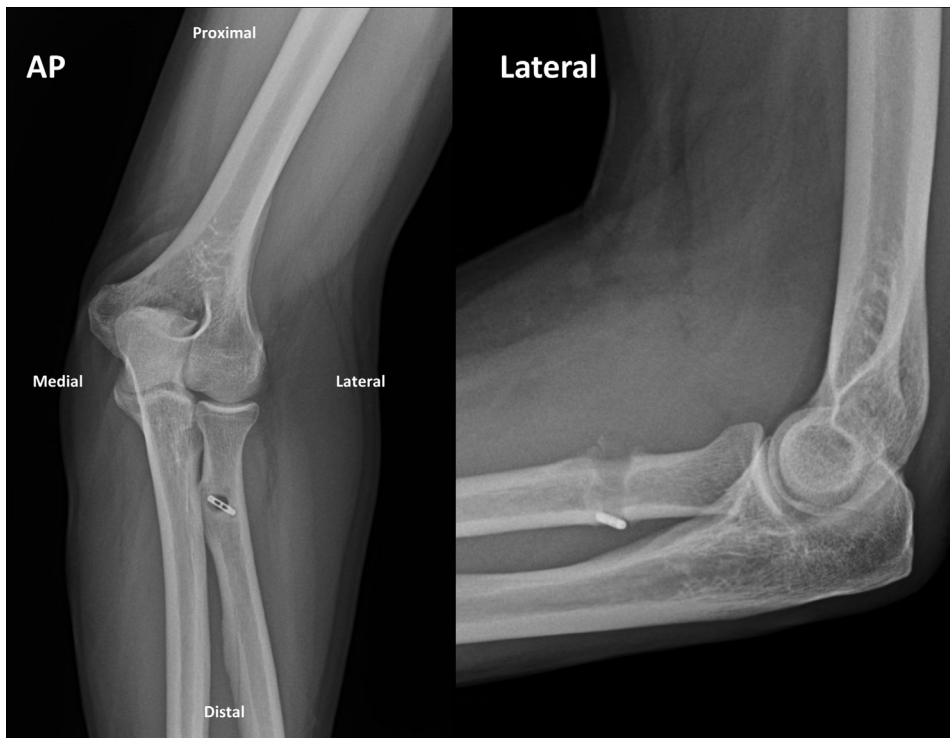


Fig 14. Final anteroposterior and lateral fluoroscopy views of the right elbow are used to demonstrate that the button is in an appropriate position and the tendon is reduced into the socket.

Table 1. Advantages, Risks, and Limitations of the Double Tension Slide Technique

Advantages	Risk and Limitation
Simple	Increased cost and time of second suture
No need for interference screw and associated increased risk of fracture	
Two sutures provide a fail-safe in case of single suture breakage or failure	

References

1. Safran MR, Graham SM. Distal biceps tendon ruptures: incidence, demographics, and the effect of smoking. *Clin Orthop Relat Res* 2002;275-283.
2. Seiler JG 3rd, Parker LM, Chamberland PD, Sherbourne GM, Carpenter WA. The distal biceps tendon. Two potential mechanisms involved in its rupture: arterial supply and mechanical impingement. *J Shoulder Elbow Surg* 1995;4:149-156.
3. Baker BE, Bierwagen D. Rupture of the distal tendon of the biceps brachii. Operative versus non-operative treatment. *J Bone Joint Surg Am* 1985;67:414-417.
4. Berlet GC, Johnson JA, Milne AD, Patterson SD, King GJ. Distal biceps brachii tendon repair. An in vitro biomechanical study of tendon reattachment. *Am J Sports Med* 1998;26:428-432.
5. Morrey BF, Askew LJ, An KN, Dobyns JH. Rupture of the distal tendon of the biceps brachii. A biomechanical study. *J Bone Joint Surg Am* 1985;67:418-421.
6. Pearl ML, Bessos K, Wong K. Strength deficits related to distal biceps tendon rupture and repair. A case report. *Am J Sports Med* 1998;26:295-296.
7. Barnes SJ, Coleman SG, Gilpin D. Repair of avulsed insertion of biceps. A new technique in four cases. *J Bone Joint Surg Br* 1993;75:938-939.
8. D'Alessandro DF, Shields CL Jr, Tibone JE, Chandler RW. Repair of distal biceps tendon ruptures in athletes. *Am J Sports Med* 1993;21:114-119.
9. Leighton MM, Bush-Joseph CA, Bach BR Jr. Distal biceps brachii repair. Results in dominant and nondominant extremities. *Clin Orthop Relat Res* 1995:114-121.
10. Bain GI, Prem H, Heptinstall RJ, Verhellen R, Paix D. Repair of distal biceps tendon rupture: a new technique using the Endobutton. *J Shoulder Elbow Surg* 2000;9:120-126.
11. Lemos SE, Ebrahimzadeh E, Kvitne RS. A new technique: in vitro suture anchor fixation has superior yield strength to bone tunnel fixation for distal biceps tendon repair. *Am J Sports Med* 2004;32:406-410.
12. Mazzocca AD, Burton KJ, Romeo AA, Santangelo S, Adams DA, Arciero RA. Biomechanical evaluation of 4 techniques of distal biceps brachii tendon repair. *Am J Sports Med* 2007;35:252-258.
13. Pereira DS, Kvitne RS, Liang M, Giacobetti FB, Ebrahimzadeh E. Surgical repair of distal biceps tendon ruptures: a biomechanical comparison of two techniques. *Am J Sports Med* 2002;30:432-436.

14. Barlow JD, McNeilan RJ, Speeckaert A, Beals CT, Awan HM. Use of a bicortical button to safely repair the distal biceps in a two-incision approach: a cadaveric analysis. *J Hand Surg Am* 2017;42:570.
15. Camp CL, Voleti PB, Corpus KT, Dines JS. Single-incision technique for repair of distal biceps tendon avulsions with intramedullary cortical button. *Arthrosc Tech* 2016;5:e303-e307.
16. Shields E, Olsen JR, Williams RB, Rouse L, Maloney M, Voloshin I. Distal biceps brachii tendon repairs: a single-incision technique using a cortical button with interference screw versus a double-incision technique using suture fixation through bone tunnels. *Am J Sports Med* 2015;43:1072-1076.
17. Watson JN, Moretti VM, Schwindel L, Hutchinson MR. Repair techniques for acute distal biceps tendon ruptures: a systematic review. *J Bone Joint Surg Am* 2014;96:2086-2090.
18. Hammarstedt JE, Savin DD, Goldberg BA. Single-incision anatomic repair technique for distal biceps tendon rupture using tunneling device. *Arthrosc Tech* 2017;6:e945-e950.
19. Kodde IF, Baerveldt RC, Mulder PG, Eygendaal D, van den Bekerom MP. Refixation techniques and approaches for distal biceps tendon ruptures: a systematic review of clinical studies. *J Shoulder Elbow Surg* 2016;25:e29-e37.
20. Savin DD, Watson J, Youderian AR, Lee S, Hammarstedt JE, Hutchinson MR, et al. Surgical management of acute distal biceps tendon ruptures. *J Bone Joint Surg Am* 2017;99:785-796.
21. Woodall BM, Youn GM, Elena N, et al. Anatomic single-incision repair of distal biceps tendon ruptures using intramedullary soft anchors. *Arthrosc Tech* 2018;7:e1177-e1180.
22. Henry J, Feinblatt J, Kaeding CC, et al. Biomechanical analysis of distal biceps tendon repair methods. *Am J Sports Med* 2007;35:1950-1954.
23. Sethi PM, Tibone JE. Distal biceps repair using cortical button fixation. *Sports Med Arthrosc Rev* 2008;16:130-135.
24. Kettler M, Lunger J, Kuhn V, Mutschler W, Tingart MJ. Failure strengths in distal biceps tendon repair. *Am J Sports Med* 2007;35:1544-1548.
25. Sethi P, Obopilwe E, Rincon L, Miller S, Mazzocca A. Biomechanical evaluation of distal biceps reconstruction with cortical button and interference screw fixation. *J Shoulder Elbow Surg* 2010;19:53-57.
26. Mellano CR, Frank RM, Shin JJ, et al. Subpectoral biceps tenodesis with PEEK interference screw: a biomechanical analysis of humeral fracture risk. *Arthroscopy* 2018;34:806-813.
27. Naidu SH. Interference screw failure in distal biceps Endobutton repair: case report. *J Hand Surg Am* 2010;35:1510-1512.