

Contents lists available at [ScienceDirect](#)

International Journal of Surgery Case Reports

journal homepage: www.casereports.com

The open retrograde approach as an alternative for failed percutaneous access for difficult below the knee chronic total occlusions—A case series

K. Saravana*, Y.K. Tan, S. Kum, T.Y. Tang

Vascular Unit, Changi General Hospital, Singapore

ARTICLE INFO

Article history:

Received 24 May 2015

Accepted 29 August 2015

Available online 24 September 2015

Keywords:

Retrograde approach

Chronic total occlusion (CTO)

Angiography

Critical limb ischaemia (CLI)

ABSTRACT

Retrograde puncture via patent pedal vessels can be attempted in failed antegrade approach for infrapopliteal long chronic total occlusion. However in cases where the pedal vessels are unable to be visualized via duplex ultrasonography or fluoroscopy an open approach offers an additional option to a vascular surgeon for successful recanalization. Our case report highlights 3 cases where successful hybrid open retrograde approach was able to achieve recanalization of long chronic total occlusion.

PRESENTATION OF CASES: The three cases in our series presented with critical limb ischaemia. All three cases had undergone duplex imaging of the affected arterial system. As the antegrade approach to cross the lesion failed a retrograde approach was attempted in all 3 cases. However when the usual modality of retrograde puncture via the use of ultrasound or fluoroscopy failed we proceeded with an open approach. **DISCUSSION:** Retrograde approach usually offers a better chance of successfully crossing a chronic total occlusion lesion. However puncturing a distal vessel successfully and traversing a catheter or guidewire across proves to be a challenge. An open approach offers an additional pathway for puncturing the target vessel when duplex imaging or fluoroscopic guidance fails.

CONCLUSION: Open approach is usually attempted as a last resort by many endovascular surgeons. However procedural time, contrast and radiation usage could have been cut short in cases where the distal target vessels pose a technical challenge for approach via a percutaneous method.

© 2015 The Authors. Published by Elsevier Ltd. on behalf of Surgical Associates Ltd. This is an open access article under the CC BY-NC-ND license (<http://creativecommons.org/licenses/by-nc-nd/4.0/>).

1. Introduction

Critical limb ischaemia (CLI) needs straight line blood flow to the foot for adequate revascularization. Five-year follow up on CLI revascularization with either an endovascular or open surgery—first approach showed that both methods had equivalent limb salvage rates and amputation-free survival in properly selected cases [1]. Success rate for endovascular treatment of infrapopliteal stenosis is up to 100% but failure rate for occlusion-type lesions ranges from 20 to 40% [2,3].

Our case report highlights three patients who underwent successful recanalization of long tibial chronic total occlusion (CTO) for tissue loss using a hybrid procedure of below knee angioplasty and open retrograde access. Iyer et al. first described this open exposure of pedal vessels and subsequent direct open puncture of

pedal arteries as an alternative approach for failed percutaneous antegrade access [4].

2. Methodology

All three cases underwent an open cutdown surgical approach of the artery at the foot and direct needle cannulation of the target tibial vessel. Attempt was initially made of cannulating the artery percutaneously using a retrograde approach either under ultrasound or fluoroscopic guidance. The failure of percutaneous angiographic retrograde approach was due to either a poor fluoroscopic window despite adequate contrast instillation proximally or poor visualization of patent lumen within the target vessel with the ultrasound approach because of heavy wall calcification. The adjunct use of intra-arterial nitroglycerin to relieve vasospasm and improve flow for distal puncture was also unsuccessful.

3. Case 1

A 29-year old male chronic smoker (10 pack years) with a negative vasculitis screen presented with a three-week history of poor healing of a right third toe ulcer. An arterial duplex ultrasound and

* Corresponding author at: Changi General Hospital, 2, Simei Street 3, Singapore 2219889, Singapore.

E-mail addresses: drsara75@gmail.com, saravana007@hotmail.com (K. Saravana).

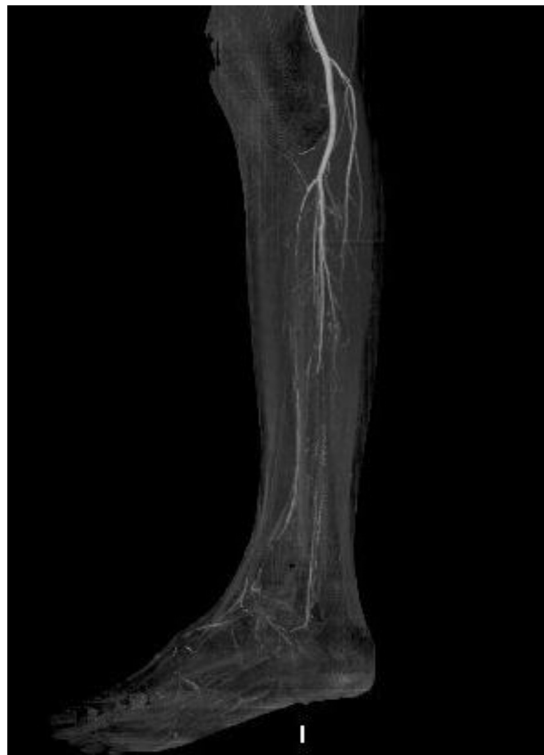

Fig. 1. CTA imaging of below knee vessels.

CT Angiogram (Fig. 1) found that the anterior tibial artery (ATA), which was the target angiosome vessel, was occluded. Segments of the plantar artery were also occluded. The angiographic images of the distal posterior tibial artery (PTA) (Fig. 2) were suggestive of underlying Buerger's disease.

The patient underwent a tibial angioplasty. An attempt to reopen the ATA antegradely resulted in the guidewire traversing subintimally in the mid ATA and was unable to re-enter the true lumen distally. Retrograde attempt with fluoroscopy was technically difficult as the visible target dorsalis pedis artery (DPA) was too small. An ultrasound guided approach could not find a sufficient patent lumen. In view of poor imaging quality from both techniques but with a potential target distal DPA, a decision was made for an open approach.

As the patient had preoperatively undergone a popliteal nerve block, the skin overlying the DPA was cut longitudinally for 3 cm (Fig. 2b). The artery was identified but not dissected out and looped as traditionally performed. The surrounding tissue around the vessel provides a stable platform for direct puncture. Using the transpedal/micropuncture 4 Fr needle kit (Angiodynamics Inc., NY) the DPA was punctured and back bleeding was obtained. A V18 (0.018") (Boston Scientific, MA, USA) wire (Fig. 2c) was used to traverse the occluded point of the distal ATA supported with a 2.6 Fr angled CXI (Cook, Bloomington, USA) catheter. The wire was retrieved via an antegradely passed Berenstein 2 catheter (Angiodynamics Inc., NY) at the proximal ATA (transluminally). Subsequently an antegradely passed CXI catheter was passed just proximal to the puncture point of the DPA and the V18 wire was retrieved. The puncture point was closed with a 7/0 prolene stitch. A PT2 0.014" (Boston Scientific, MA, USA) wire was passed antegradely and passed beyond the puncture point and into the tarsal branch of the DPA. A 0.014" 2 mm × 80 mm Nanocross (EV3, Covidien, Plymouth, USA) balloon angioplasty was performed across the puncture followed by 0.014" 2.5/3.0 mm tapered balloon (EV3, Covidien, Plymouth, USA) to the ATA (Fig. 3). Check angiogram

revealed good run off to the DPA and the metatarsal artery and a palpable DPA was present. He underwent a third toe ray amputation with good bleeding from the raw edges of the wound. Patient was subsequently placed on double antiplatelet therapy, a statin and was advised to stop smoking. During his routine follow up in the clinic (8 weeks post angioplasty) the wound had healed and he still had a palpable DPA.

4. Case 2

A 62-year old female with end stage renal failure on haemodialysis, diabetes, hypertension and hyperlipidaemia, presented with a 3-week history of left fourth toe wet gangrene. Duplex imaging and on table angiogram (Fig. 4) revealed PTA and ATA occlusions but ATA reconstituted distally by the peroneal artery (main run off). Plantar arch was also incomplete. Vein mapping showed no suitable conduit for bypass.

An antegrade angioplasty of the ATA was attempted with multiple wires and supporting catheters and balloons, which proved unsuccessful. The vessel wall was moderately calcified and an attempt at retrograde percutaneous technique using an ultrasound also failed. As the patient was already under regional anaesthesia (popliteal nerve block), DPA was exposed by surgical cutdown and directly punctured with a 4F micropuncture set (Angiodynamics Inc., NY). A 2.6 Fr angled CXI (Cook, Bloomington, USA) crossing catheter over a V18 (Boston Scientific, USA) wire was used to guide the wire transluminally towards the proximal ATA, where it was snared with 4 Fr Berenstein 2 (Angiodynamics Inc., NY) catheter. The angled 2.6 Fr CXI (Cook, Bloomington USA) catheter was then inserted antegrade up to the retrograde puncture point at which point the v18 wire was exchanged with an antegrade PT2 (0.014" Boston Scientific) guidewire to traverse into the DPA. The puncture point was closed with 7/0 prolene stitch (Ethicon, USA). Post dilatation with a 0.014" balloon angioplasty showed significant recoil (>50%) at the DPA. A Maris deep (Medtronic MN, USA) niti-

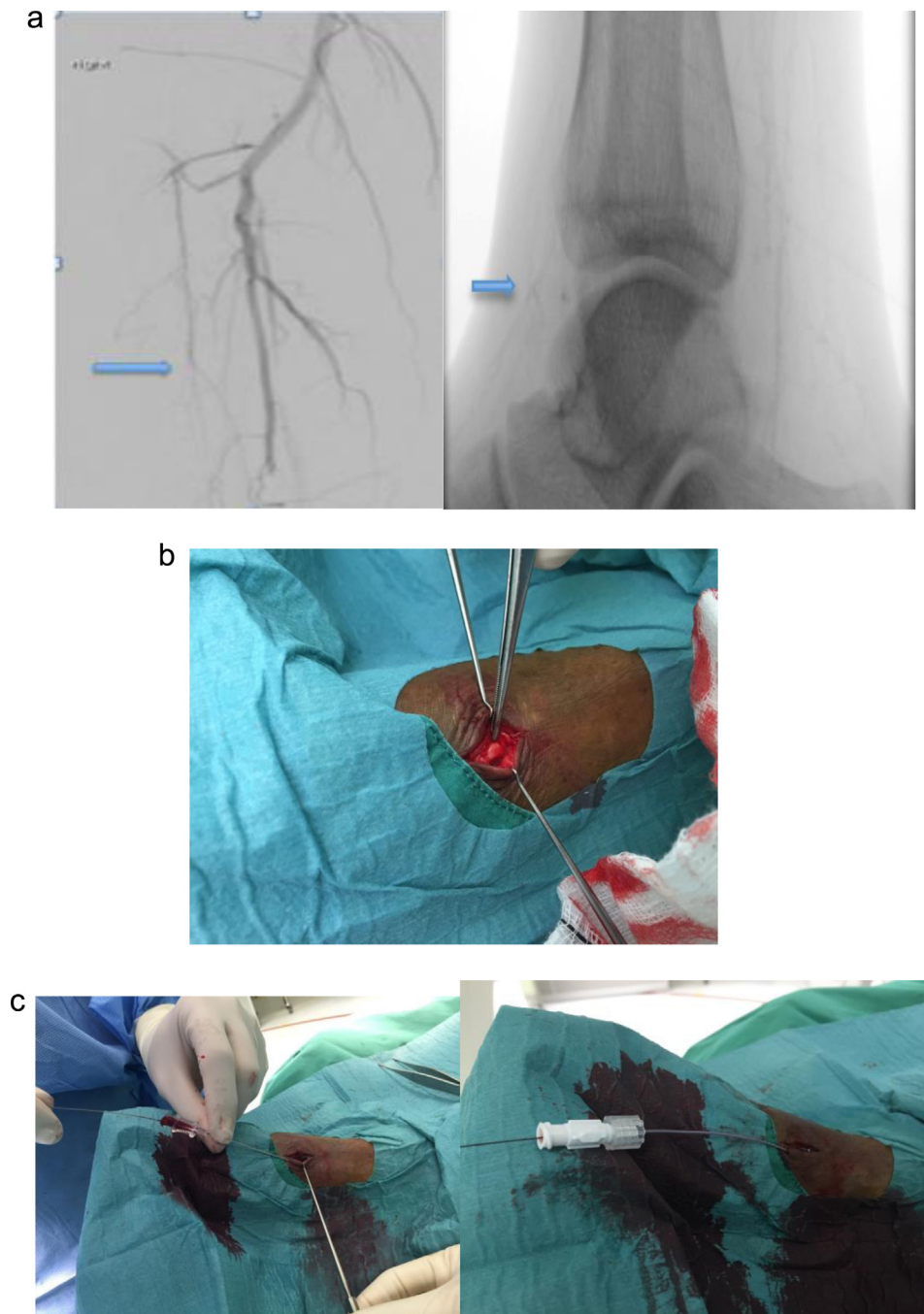


Fig. 2. (a) The below knee angiogram shows that the ATA is stenotic proximally and occluded at mid segment (long arrow). Peroneal artery is the main run off vessel. Distal ATA is reconstituted by the peroneal artery (short arrow). (b) Open approach to view distal anterior tibial artery. (c) Transpedal puncture kit and passage of 0.018" V18 wire.

not self-expanding stent 3 mm × 80 mm was deployed across the ATA to proximal DPA. However the distal DPA still showed significant stenosis with poor outflow therefore a 3mm × 28 mm Xience Prime (Abbott, Santa Clara, USA) drug eluting stent was deployed across the distal DPA (covering the puncture point). Subsequent angiogram showed rapid outflow to the digital vessels (Fig. 5). The third, fourth and fifth toes were amputated, which showed brisk back-bleeding.

One month post intervention the wound showed poor healing and a surveillance duplex scan showed the ATA and DPA stents were thrombosed. Patient underwent a successful antegrade passage of guidewire across the blocked stent and into the metatarsal artery. On angiogram it was discovered the proximal ATA stenosis was the

cause of early occlusion and this was treated with a proximal stent. The wound had healed completely at two months follow-up.

5. Case 3

A 64-year old male with diabetes and hypertension was admitted with a 3-weeks history of left heel gangrene. He had absent popliteal and pedal pulses. Duplex imaging revealed multi-level peripheral artery disease with left superficial femoral, tibioperoneal trunk (TPT) stenosis and PTA occlusion. He underwent an antegrade femoral angiogram and successful balloon angioplasty of his SFA, popliteal and TPT. However, the guide wire was not able to re-enter the true lumen of the distal PTA, despite using a sup-

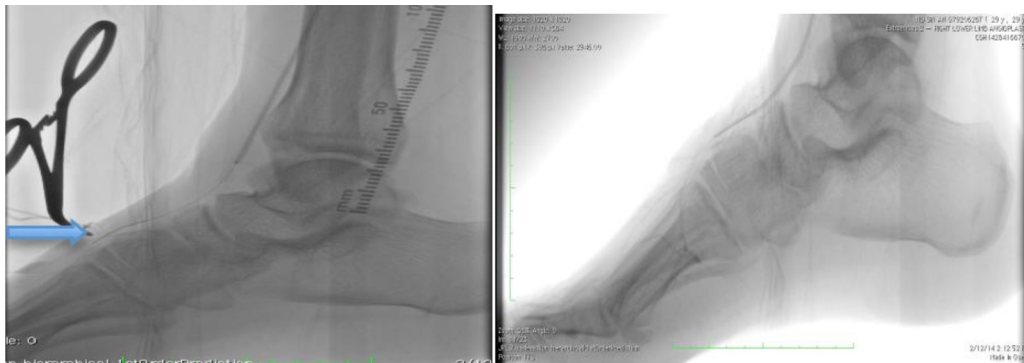

Fig. 3. Guidewire crossing the puncture point and the angioplasty of the ATA and DPA vessels.

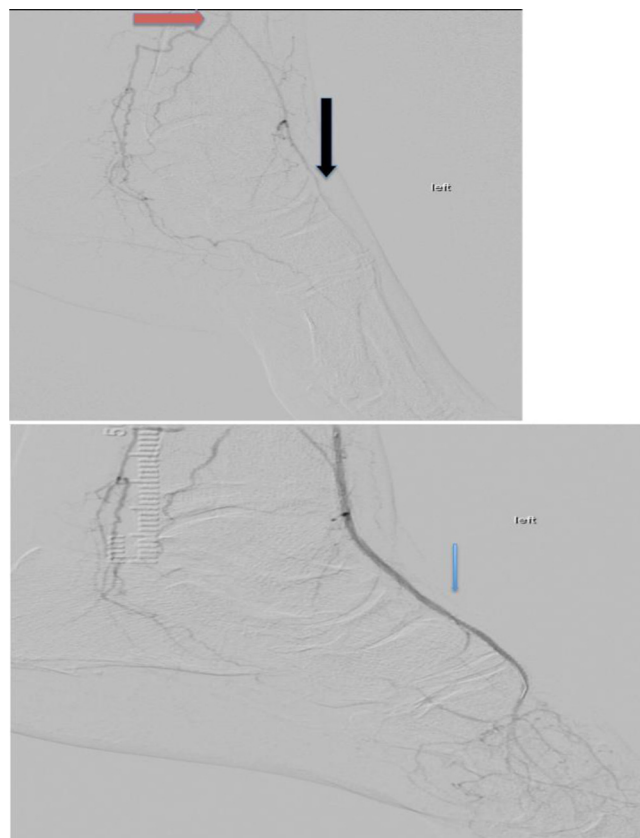


Fig. 4. Distal ATA (black arrow) reconstituted by peroneal artery (red arrow). Diseased DPA post pasty (blue arrow).

porting catheter and a multitude of wires (Fig. 6a and b). As the PTA vessel was calcified, attempt via retrograde ultrasound guided puncture was unsuccessful due to a poor ultrasonic window. Fluoroscopic guided puncture was also attempted but failed. The PTA was dissected out and punctured under direct vision with a micropuncture set (4Fr Angiodynamics Inc., NY). A V18 (0.018" Boston Scientific, MA, USA) wire on a supporting catheter was used and the wire stayed intraluminally and was retrieved at the distal end of the proximal PTA with an antegradely passed 4F Berenstein Catheter (Angiodynamics Inc., NY). After crossing the distal puncture site with a lower profile wire, balloon angioplasty of the whole length of the PTA was performed. There was good flow into the medial plantar artery on completion (Fig. 6c and d). The heel looked well perfused by the PTA and it was debrided. The patient was started on dual antiplatelet and the wound healed completely 10 weeks after revascularization.

The open surgical cutdown wounds in all three cases healed without any complications.

6. Discussion

The technical success of antegrade or retrograde approach angioplasty for revascularizing lower limb vessels is determined by factors such as lesion length, calcification, distal vessel run off and operator experience. Although subintimal crossing of below the knee CTO lesions is a useful technique, it is associated with major complications. Inability to re-enter the true lumen after subintimal passage and extension of the subintimal passage beyond the occluded segment, compromises collateral vessels and restricts potential surgical bypass targets [5]. Repeated attempts and prolonged procedural time increases the risk of radiation exposure, contrast induced nephropathy and risk of hematoma related com-

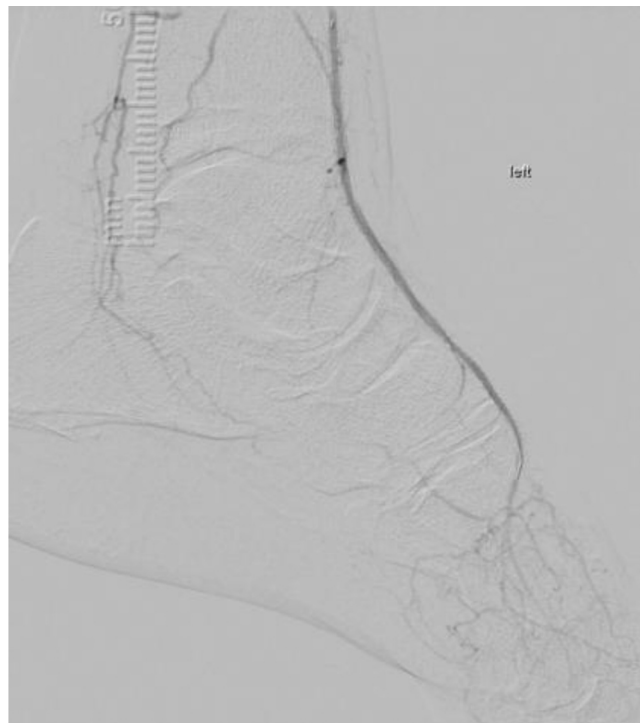


Fig. 5. Post stenting of DPA across the retrograde puncture point.

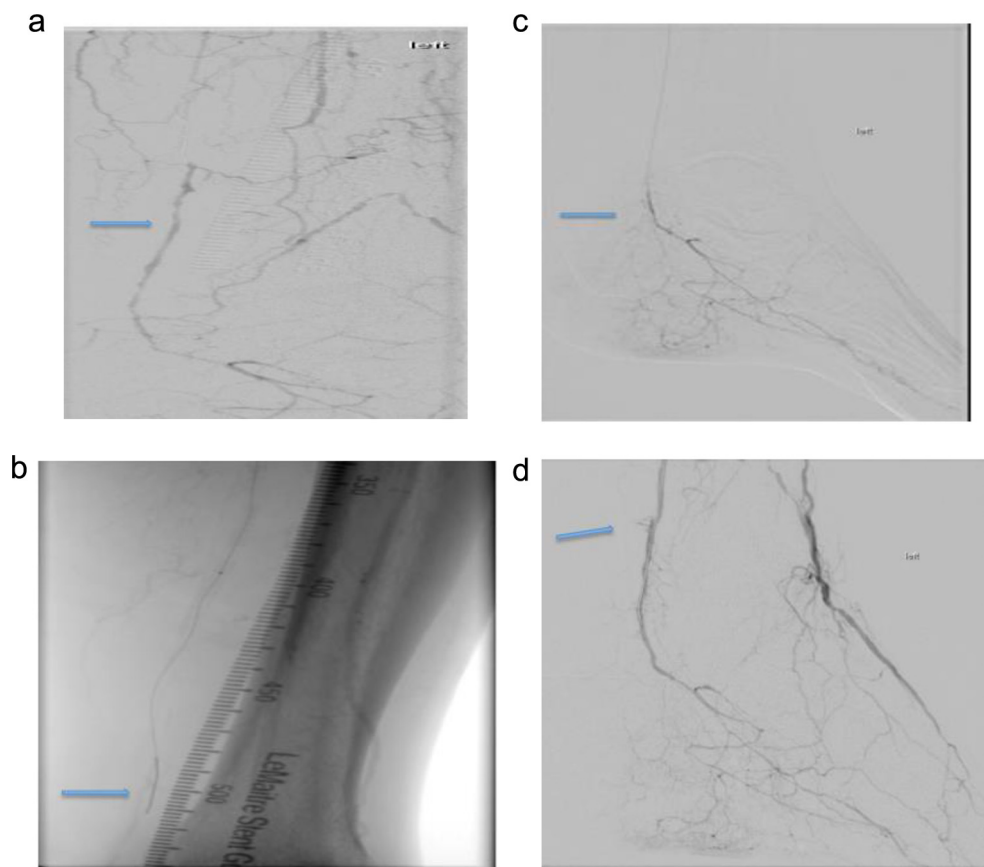


Fig. 6. (a) Angiogram of left distal PTA. (b) Unsuccessful attempt at passage of wire towards distal PTA. (c) Crossing the PTA beyond the retrograde puncture point. (d) Post angioplasty of PTA.

plications such as nerve compression and compartment syndrome to the patients.

The retrograde approach usually offers a higher success rate of crossing the CTO lesion because the distal atheroma cap is often softer in composition [6]. The CTO lesions of less than a year old are usually composed of soft cholesterol laden foam cells lesions and those that are more than one year old are usually composed of fibrocalcific iron and hemosiderin deposits thus forming the “hard plaque” variety [6]. Walker et al. showed that retrograde pedal access after a failed antegrade approach was successful in 96% of patients (Rutherford 4–6 with occlusive disease) and those with vessel diameters >1.5 mm [7].

Case 1 had Buerger's disease (Rutherford 5) where surgical revascularization is usually not possible because of diffuse distal disease with inadequate runoff. The angiographic findings showed absence of arterial calcification and presence of “cockscrew” vessels. Graziani et al. showed in his series of 20 consecutive cases using extended angioplasty of a single tibial and foot arteries, was able to achieve a technical success rate of 95%. Amputation free survival at 2 years was 84.2% [8].

The second case involved a diabetic with end stage renal failure with Rutherford 5 toe gangrene and extensive medial calcification of the tibial vessel. Estimated rates of major lower extremity amputations in the dialysis population has been estimated to be 4.3% after 1 year and 13% among the dialysis patients with diabetes [9]. Technical success for endovascular revascularization in this group of patients with tibial disease has been reported as high as 42% [10]. In our second patient although the retrograde open approach was successful the wound healing was delayed because of restenosis at the proximal anterior tibial artery. However the secondary revascularization procedure was successful as the distal run off was still patent.

7. Conclusion

Successful endovascular antegrade or retrograde options with myriad of devices can be a costly adventure. However limb salvage can still be carried out with a hybrid procedure such as this open retrograde approach in patients with poor quality autologous venous conduits for bypass and unsuccessful percutaneous retrograde puncture. The open technique provides an additional option to a vascular surgeon for revascularization in an otherwise doomed percutaneous approach. The success of this approach is also determined by the relatively good outflow distal to the puncture point.

Competing interests

None.

Funding

None.

Ethical approval

As this was a case report series no ethical approval was required.

Consent

A written and signed consent to publish this case report was obtained from the patient or next of kin prior to submission.

Authors contribution

Dr Saravana Kumar—study concept and design, data collection and writing of the paper.

Dr Tang Tjun Yip, Dr Steven Kum, Dr Tan Yih Kai—correction and final approval for publication.

Guarantor

Dr Saravana Kumar.

References

- [1] K. Garg, P. kaszubski, R. Morizadeh, C.B. Rockman, M. Adelman, Endovascular-first approach is not associated with worse amputation free survival in appropriately selected patients with critical limb ischaemia, *J. Vasc. Surg.* 59 (February (2)) (2014) 551–552.
- [2] G. Dorros, M.R. Jaff, A.M. Dorros, et al., Tibioperoneal (outflow lesion) angioplasty can be used as primary treatment in 235 patients with critical limb ischaemia: five year follow-up, *Circulation* 104 (2001) 2057–2062.
- [3] D.J. Spinosa, D.A. Leung, N.L. Harthun, et al., Simultaneous antegrade and retrograde access for subintimal recanalization of peripheral arterial occlusion, *J. Vasc. Interv. Radiol.* 14 (2003) 1449–1454.
- [4] S.S. Iyer, G. Dorros, R. Zaitoun, et al., Retrograde recanalization of an occluded posterior tibial artery by using posterior tibial cutdown: two case reports, *Catheter. Cardiovasc. Diagn.* 20 (1990) 251–253.
- [5] K.A. Hausseger, B. Georgieva, H. Portugaler, J. Tauss, G. Stark, The outback catheter: a new device for true lumen reentry after dissection during recanalization of arterial occlusions, *Cardiovasc. Interv. Radiol.* 27 (2004) 26–30.
- [6] J.C. George, Trayer Troy, R. Kovach, Wired for success: guidewire escalation and techniques for successful crossing of chronic total occlusions, *Endovasc. Today* (2014) 16–19, Suppl. March.
- [7] C. Walker, Durability of PTAs using pedal artery approaches, in: Paper Presented at: 37th Annual VEITH Symposium, November 18, 2010; New York City, NY, 2015.
- [8] L. Graziani, L. Morelli, F. Parini, L. Franceschini, P. Spano, et al., Clinical outcomes after extended endovascular recanalization in buergers disease in 20 consecutive diseases, *Ann. Vasc. Surg.* 3 (April (26)) (2012) 387–395.
- [9] I.P. Casserly, Interventional management of critical limb ischaemia in renal patients, *Adv. Chronic Kidney Dis.* 15 (4) (2008) 384–395.
- [10] D. Silverberg, T. Yalon, Rimon Uri, E.R. Reinitz, D. Yakubovitch, et al., Endovascular treatment of lower extremity ischaemia in chronic renal failure patients on dialysis: early and intermediate term results, *IMAJ* 15 (December) (2013) 734–738.

Open Access

This article is published Open Access at sciedirect.com. It is distributed under the [IJSCR Supplemental terms and conditions](#), which permits unrestricted non commercial use, distribution, and reproduction in any medium, provided the original authors and source are credited.